



Endoscopic through-the-scope suturing

Linda Y. Zhang, MBBS,¹ Michael Bejjani, MD,¹ Bachir Ghandour, MD,¹ Mouen A. Khashab, MD¹

Background and Aims: There is growing interest in closure of larger mucosal defects, given the increasing use of endoscopic resection for early GI neoplasia and the advent of submucosal endoscopy, including peroral endoscopic myotomy. Existing closure methods include through-the-scope clips, over-the-scope clips, and over-the-scope suturing. Although over-the-scope clips and over-the-scope suturing allow closure of large defects, both require endoscope removal for device application and may have difficulty in treating lesions in the proximal colon or the small intestine. Hence, a significant gap exists for a through-the-scope device capable of closing larger defects. The novel X-Tack system (Apollo Endosurgery, Austin, Tex, USA) offers through-the-scope suturing (TTSS), which eliminates the need to withdraw the endoscope from the patient before applying therapy.

Methods: We demonstrate the possible indications for endoscopic mucosal adhesion with TTSS through a video case series. We present 5 cases to illustrate the use of TTSS in the closure of a duodenal EMR defect, a cecal EMR defect, mucostomy after esophageal and gastric peroral endoscopic myotomy, and, finally, for primary closure of a gastrogastroic fistula.

Results: All defects were successfully closed with 1 to 2 TTSS systems. There were no postprocedure adverse events, including bleeding or perforation, at a median of 30 (range 14-30) days of follow-up.

Conclusions: TTSS is a valuable addition to mucosal closure devices, which allows closure through a gastroscope or a colonoscope, without requiring endoscope removal for device application. Likely applications include larger or more distant defects and those located within tight spaces. Pending further clinical evaluation, important areas for research include assessment of the learning curve, comparative trials with other closure devices, and cost-effectiveness analysis. (VideoGIE 2022;7:46-51.)

INTRODUCTION

Multiple devices are available for mucosal closure, including through-the-scope clips (TTSCs), over-the-scope clips (OTSCs), and endoscopic suturing. Each has benefits and limitations to its use. The closure of larger defects has become of particular interest given the increasing use of endoscopic resection for early GI neoplasia and the advent of submucosal endoscopy, including peroral endoscopic myotomy (POEM). Conventional TTSCs can usually achieve successful closure of linear defects up to 2 cm in diameter. OTSCs can be used, but precise placement is crucial; improper positioning can limit subsequent rescue, and placing several end-to-end can be technically challenging.

The OverStitch (Apollo Endosurgery, Austin, Tex, USA) over-the-scope suturing (OTSS) system has been widely used since receiving its initial U.S. Food and Drug Administration approval in 2008 as an endoscopic suturing device. In expert hands, the device is able to achieve full-thickness bites and, in doing so, is highly effective in closing

large defects, perforations, and fistulas and for performing primary endoscopic bariatric surgery. The current device, however, can only be used with a gastroscope. Furthermore, the endoscope must first be removed to mount the device. As with any over-the-scope device, the effective diameter of the device-mounted gastroscope is increased, which can lead to difficulty in reaching or maneuvering in tight spaces. Finally, OTSS is technically challenging and carries a significant learning curve.

Hence, the 2 available devices for closure of larger defects both require endoscope removal for application before reinsertion to the target site, which can be cumbersome and time consuming. Furthermore, this may not be possible for more proximally located colonic lesions. Thus, a significant gap exists for a through-the-scope device capable of closing larger defects.

The X-Tack through-the-scope suture (TTSS) system received U.S. Food and Drug Administration approval in December 2020 for endoscopic approximation of soft tissue, including closure of EMR or endoscopic submucosal

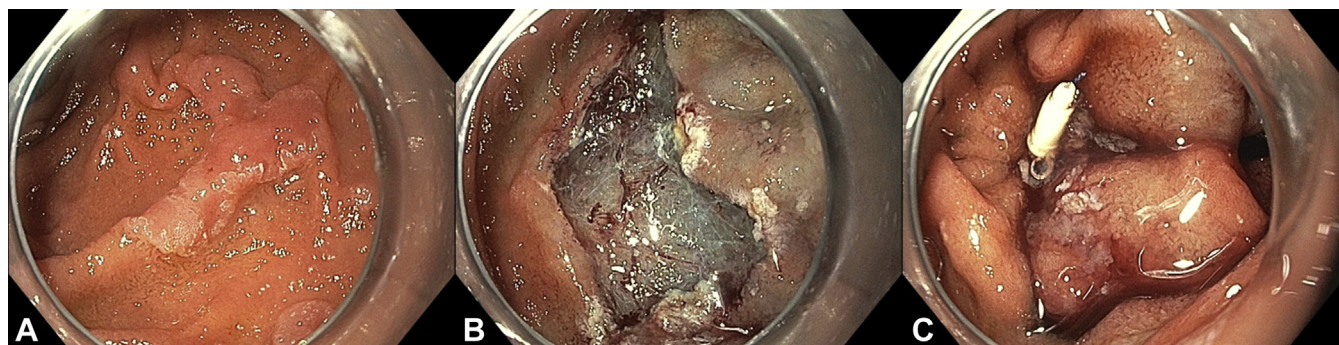


Figure 1. Duodenal endoscopic mucosal resection (EMR) closure. **A**, A 15-mm Paris IIa laterally spreading lesion is seen in the second part of the duodenum. **B**, Post-EMR defect. **C**, The defect is entirely closed with the through-the-scope suturing system.

dissection (ESD) sites, fistula closure, perforation, or leaks. TTSS eliminates the need to withdraw the endoscope from the patient before applying therapy. The system comes in 2 lengths: 160 cm for the gastroscope and 235 cm for the colonoscope. The device requires a minimum working channel diameter of 2.8 mm. The current model contains 4 individual helical tacks pre-strung on a 3-0 polypropylene suture. The length of the tack is designed to reach into but not through the muscularis propria (in contrast to the full-thickness sutures offered by the OTSS system). Once all tacks are deployed, tension on the suture approximates the tacks, thereby closing the tissue defect. A suture cinch, deployed in a similar manner to the OTSS system, secures the sutures in place.

PATIENTS AND METHODS

We performed a review of cases that underwent TTSS for endoscopic mucosal adhesion to demonstrate the use of TTSS in various indications (Video 1, available online at www.giejournal.org). This study received institutional ethics review board approval. All patients gave consent as per standard care before the procedure.

Case 1

A 56-year-old man with a history of familial adenomatous polyposis was referred for ongoing management of duodenal adenomas. He had a history of multiple large duodenal adenomas requiring EMR, complicated by post-EMR bleeding on several occasions. At endoscopy, a 15-mm Paris 0-IIa laterally spreading lesion was seen in the second part of the duodenum, separate from the ampulla (Fig. 1). EMR was performed with complete removal of the lesion. The defect was then closed with TTSS using the gastric length X-Tack system. One system was used, with placement of the 4 tacks in a “Z” pattern resulting in complete closure. There were no postprocedure adverse events, including bleeding or perforation, at 30 days’ follow-up.

Case 2

An 81-year-old man was referred for removal of a large cecal tubulovillous adenoma. He was taking high-dose aspirin for coronary artery disease and had multiple prior stents placed. He was also a Jehovah’s Witness with strict denial of use of any blood products. At colonoscopy, a 20-mm Paris 0-IIa+Is lesion was seen in the cecum, extending to the appendiceal orifice (Fig. 2). EMR was performed with complete removal of the lesion. A colonic-length TTSS system was used to close the device with placement of 4 tacks in a figure 8 pattern. There were no postprocedure adverse events, including bleeding or perforation, at 30 days’ follow-up.

Case 3

A 73-year-old woman was reviewed for dysphagia, regurgitation, and weight loss, with an Eckhardt score of 10. High-resolution manometry and contrast esophagogram confirmed the presence of type 1 achalasia, and she proceeded to POEM. During POEM, a 2-cm mucosal incision was made on the anterior esophageal wall to allow submucosal tunneling and myotomy. The procedure was uneventful, and the mucosal incision was closed with TTSS using 4 tacks in a “Z” pattern (Fig. 3). An esophagogram the following day showed no extraluminal passage of contrast, and the patient was placed on a soft diet. The patient remained well with no evidence of postprocedure adverse events at 2 weeks’ follow-up.

Case 4

A 64-year-old man presented with a history of median arcuate ligament syndrome, with residual symptoms of gastroparesis despite celiac artery release. He had been dependent on jejunal feeds via a PEG tube with jejunal extension. A gastric emptying study showed near-complete stasis of radiotracer in the stomach, consistent with severe gastroparesis. He was a poor candidate for further surgical intervention owing to significant comorbidities, including nonischemic cardiomyopathy with an ejection fraction of 25%, supraventricular tachycardia, and prior

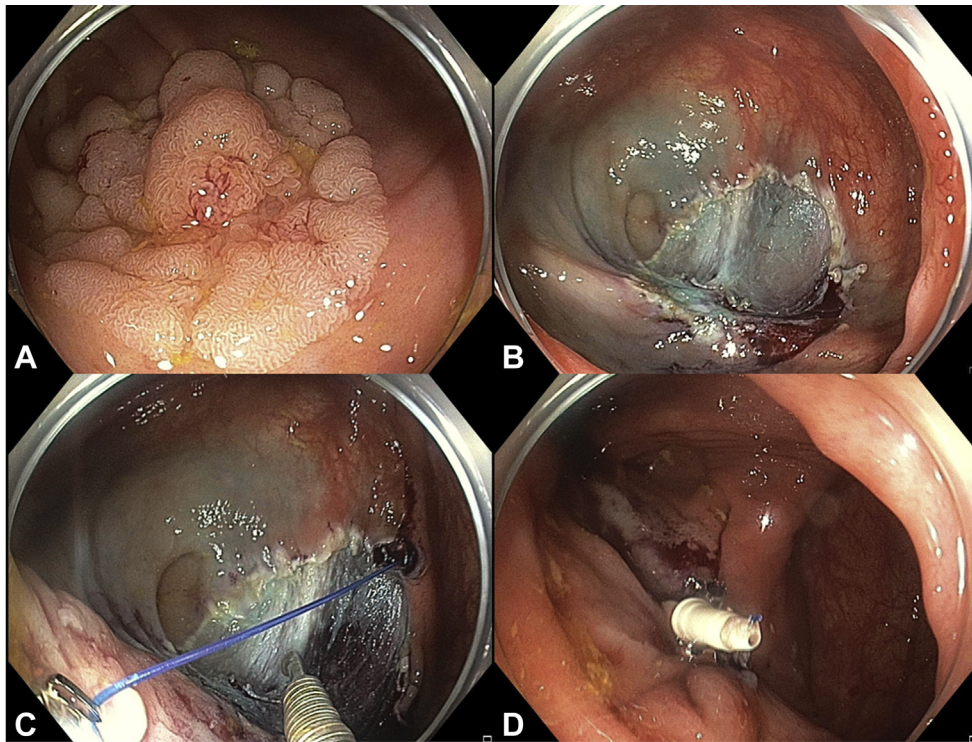


Figure 2. Colonic endoscopic mucosal resection (EMR) closure. **A**, A 20-mm Paris IIa + Is laterally spreading lesion is seen in the cecum, extending to the appendiceal orifice. **B**, Post-EMR defect. **C**, Two tacks are placed directly opposite each other for a figure 8 closure. **D**, Defect closed with through-the-scope suturing.

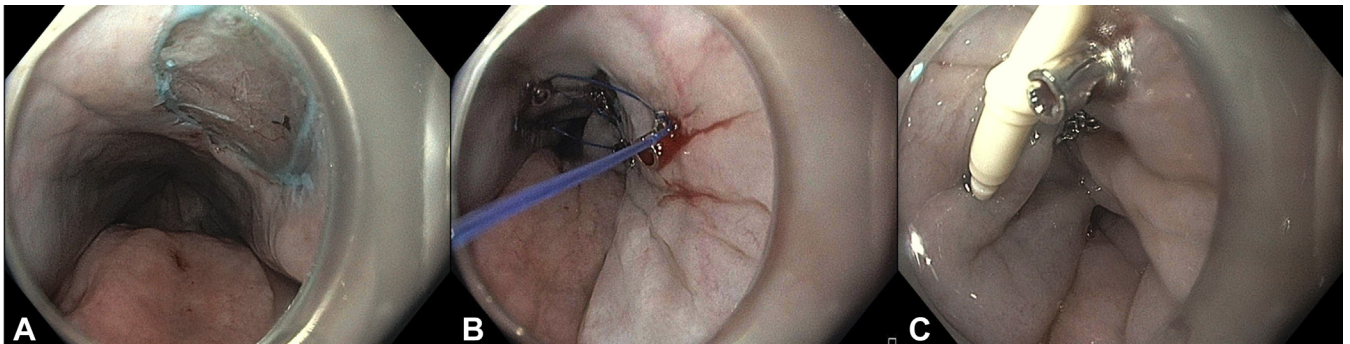


Figure 3. Closure of peroral endoscopic myotomy (POEM) mucosal incision. **A**, A 2-cm mucosal incision was made as part of the POEM procedure. **B**, A “Z” pattern was used for closure. **C**, The defect was completely closed after approximation of tacks and cinching of the suture.

acute necrotizing pancreatitis complicated by pancreatic fluid collections requiring necrosectomy. He thus underwent gastric peroral endoscopic myotomy. A 2-cm mucosal incision was made at the greater curvature to allow for submucosal tunneling and myotomy. The incision was then closed with TTSS (Fig. 4). After placement of the first system in a “Z” shaped pattern, the superior aspect of the incision was inadequately closed. Thus, a second system was placed in a “Z” pattern overlapping the incompletely closed defect and the first TTSS system. After placement of the final cinch, the defect was completely closed. An upper GI

series the following day showed no extraluminal contrast. The patient was tolerating a full fluid diet with no evidence of postprocedure adverse events. At a follow-up upper endoscopy 2 weeks later for adjustment of his PEG tube with jejunal extension, the TTSS cinch was visualized in position at the gastric antrum.

CASE 5

A 70-year-old woman with history of Roux-en-Y gastric bypass underwent EUS-directed transgastric ERCP (EDGE)

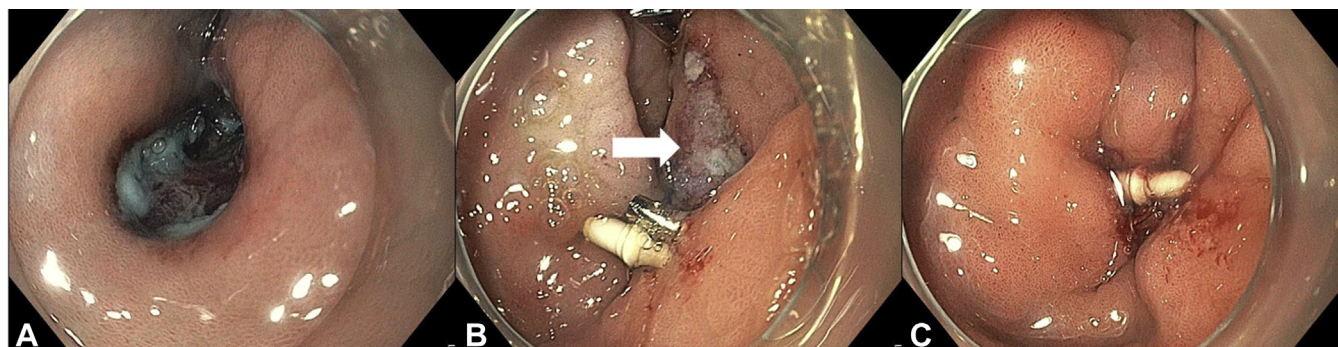


Figure 4. Closure of gastric peroral endoscopic myotomy (G-POEM) mucosal incision. **A**, A 2-cm mucosal incision was made in the antrum as part of the G-POEM procedure. **B**, After placement and cinching of the first 4 tacks, the superior aspect of the defect (*white arrow*) was seen to be incompletely closed. **C**, A second system with 4 further tacks was placed for complete closure of the defect.

for treatment of choledocholithiasis. At her index procedure, a gastrogastrostomy was created with placement of a 20-mm cautery-enhanced lumen-apposing metal stent (LAMS). The LAMS was dilated to 20 mm with a through-the-scope balloon and then secured to the gastric pouch by using the OverStitch device to place 2 interrupted sutures on the proximal phalange. Same-procedure ERCP was performed with biliary sphincterotomy, removal of bile duct stones, and placement of a fully covered metal stent to maintain duct patency pending cholecystectomy. The patient proceeded to a laparoscopic cholecystectomy and returned 2 months later for bile duct clearance and LAMS removal. She reported a 10-pound weight increase since the EDGE procedure, and thus primary closure of the gastrogastrostomy was planned. At endoscopy, the biliary covered metal stent was removed, and occlusion cholangiogram after several balloon sweeps confirmed duct clearance. The LAMS was then removed, leaving the gastro-gastric fistula (*Fig. 5*). The fistula tract was treated with argon plasma coagulation to aid mucosal adhesion. TTSS was then used to close the tract in a figure 8 pattern. The gastrojejunal opening was in close proximity to the tract, and care was taken to ensure this was not affected by the closure. Intraprocedural contrast injection under fluoroscopy confirmed complete closure with no contrast passage into the excluded stomach. An upper GI series at 6 weeks postprocedure confirmed durable closure with no contrast passage into the excluded stomach.

RESULTS

All cases were successfully performed with complete closure of mucosal defects using 1 to 2 TTSS systems. Median time for TTSS closure was 9.2 minutes (range 6.1–18.7). No postprocedure adverse events were noted within the short follow-up duration.

DISCUSSION

GI mucosal defects, whether due to an adverse event (eg, perforation, leak, or fistula), after endoscopic resection (eg, EMR or ESD), or as a routine part of a procedure (eg, mucosal incision during POEM) are commonly encountered. The most commonly used options for endoscopic closure include TTSC, OTSC, and OTSS. TTSC closure can be compromised by surface irregularity, angle of approach, defect configuration, and width. Although the TTSC is rotatable, orientation can often be challenging. Furthermore, TTSCs are often limited in the closure of larger defects owing to a restricted opening distance between the 2 jaws and superficial closing force, with 1 study showing that 1 in 3 TTSC closures was incomplete in the setting of large (>20 mm) nonpedunculated polyps.¹

OTSCs and OTSS brought new power for flexible endoscopic closure, expanding the ability to endoscopically close perforations, large resections, and fistulas. The OTSC provides more durable closure than standard clips owing to its wider mouth, ability to grasp larger amounts of tissue, and greater compressive force that enables even full-thickness closure. Food and Drug Administration approval is for the closure of defects <2 cm in size. Although placement of 2 adjacent clips has been reported for larger defects,² this can be cumbersome, and removal or adjustment requires a specialized device designed for this purpose. In experienced hands, OTSS allows the placement of full-thickness sutures, which can be highly effective for large defect closures.³ However, the technique is technically challenging with a significant learning curve. Furthermore, as with any over-the-scope device, endoscope removal is required before device application and the subsequent device–scope combination is of a significantly larger diameter, which can lead to difficulty reaching or maneuvering within tight spaces.

The introduction of the TTSS system therefore nicely fills the gap for a through-the-scope device capable of closing larger defects. A preclinical study comparing TTSS to TTSCs

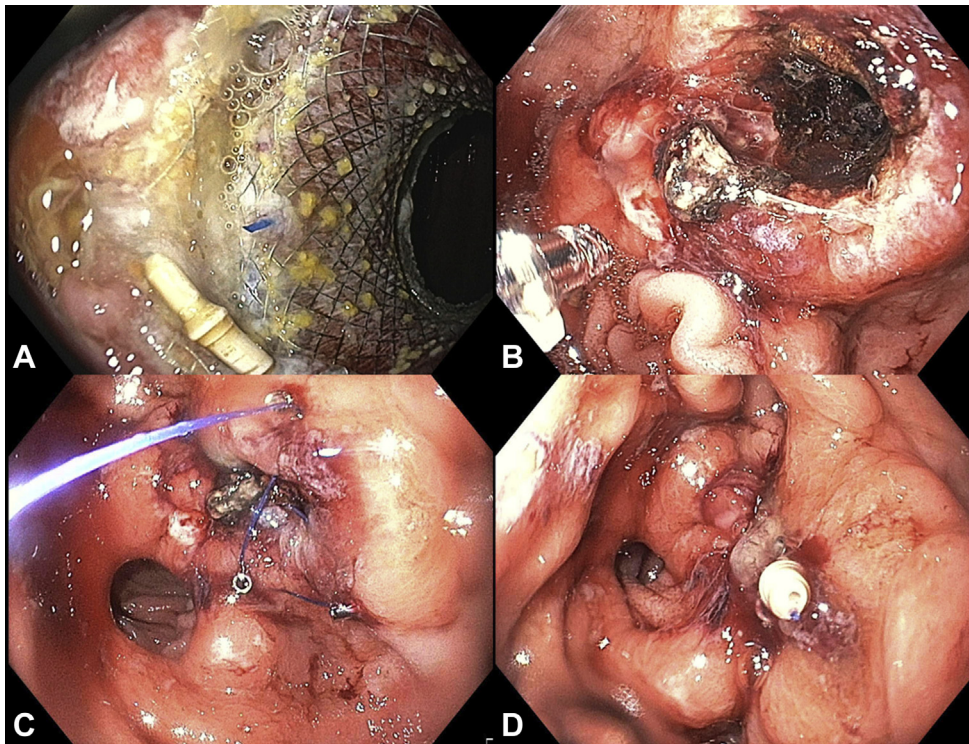


Figure 5. Primary closure of gastrogastrostomy after EUS-directed transgastric ERCP (EDGE) procedure. **A**, A lumen-apposing metal stent (LAMS) in situ in the gastrogastrostomy tract. **B**, After LAMS removal, the gastrogastrostomy tract was treated with argon plasma coagulation for mucosal adhesion. **C**, A “Z” pattern was used for closure. The gastrojejunal opening was in close proximity and was avoided during closure. **D**, Complete closure of gastrogastrostomy tract, leaving the gastrojejunal opening patent.

showed improved immediate technical success.⁴ TTSS was also successful in closing 2 resections where TTSCs had failed. Hernandez-Lara et al⁵ nicely demonstrated TTS setup and use in a case report.⁵ Clinical trials are awaited, and this is the first case series to document its use in humans. A clear advantage of TTSS is the ability to use the device as the need arises, without endoscope withdrawal and reinsertion. Furthermore, the technique is significantly less technically challenging than the OTSS version, although this is yet to be assessed formally. The ability to seamlessly combine multiple systems aids in the closure of large lesions. Important technical points we noted in our early use include the following: (1) Care must be taken when providing tension on the suture or during cinching because the thinner suture is prone to breakage, and (2) the tacks can “slide” through mucosa, particularly if edematous or inflamed. Thus, leaving a 5- to 10-mm margin of normal tissue is crucial. For closure pattern, we favored a “Z” pattern for linear defects and a figure 8 for circular or irregular defects. However, the ideal closure pattern has not been studied and should be addressed in future trials. In case 4, 2 TTSS systems were required for closure. The rate of successful defect closure using 1 system should be addressed in future studies. This will be critical because the additional cost and time in deploying a second system may be a significant limiting factor to TTSS uptake. It should be noted, however, that TTSS can be used in combination

with other closure modalities. A small residual defect after deployment of a TTSS system can be closed with other devices such as TTSCs, and vice versa.

An important point to highlight is that although OTSS allows full-thickness bites, TTSS is designed for mucosal closure. This is a crucial distinction that limits the use of TTSS for bariatric indications, large full-thickness defects, or chronic fistulae. We presented in case 5 a gastrogastrostomy fistula that was successfully closed after argon plasma coagulation and TTSS. We believe mucosal apposition from the TTSS and argon plasma coagulation-induced scarring were both significant contributors to closure success. It is critical that argon plasma coagulation is applied not only to the mucosal surface but also along the entire fistula tract. Currently, TTSS is not intended for use in the setting of active bleeding but rather for defect closure to prevent delayed bleeding and/or leak. Finally, TTSS should be avoided in patients with allergies to surgical steel or polypropylene.

TTSS is a valuable addition to mucosal closure devices. Likely applications include larger or more distant defects and those located within tight spaces. However, widespread uptake of TTSS will rely significantly on cost-effectiveness analysis. Pending further clinical evaluation, important areas for future research include assessment of the learning curve, comparative trials with other closure devices, and cost-effectiveness analysis.

DISCLOSURES

Dr Khashab is a consultant for Boston Scientific, Olympus, Medtronic, and GI Supply.

All other authors disclosed no financial relationships relevant to this publication.

Abbreviations: EDGE, EUS-directed transgastric ERCP; ESD, endoscopic submucosal dissection; G-POEM, gastric peroral endoscopic myotomy; LAMS, lumen-apposing metal stent; OTSC, over-the-scope clip; OTSS, over-the-scope suturing; POEM, peroral endoscopic myotomy; TTSC, through-the-scope clip; TTSS, through the scope suturing.

REFERENCES

1. Albéniz E, Álvarez MA, Espinós JC, et al. Clip closure after resection of large colorectal lesions with substantial risk of bleeding. *Gastroenterology* 2019;157:1213-21.e4.
2. Kirschniak A, Traub F, Kueper MA, et al. Endoscopic treatment of gastric perforation caused by acute necrotizing pancreatitis using over-the-scope clips: a case report. *Endoscopy* 2007;39:1100-2.
3. Kantsevov SV, Bitner M, Mitrakov AA, et al. Endoscopic suturing closure of large mucosal defects after endoscopic submucosal dissection is technically feasible, fast, and eliminates the need for hospitalization (with videos). *Gastrointest Endosc* 2014;79:503-7.
4. Hernandez A, Marya NB, Sawas T, et al. Gastrointestinal defect closure using a novel through-the-scope helix tack and suture device compared to endoscopic clips in a survival porcine model (with video). *Endosc Int Open* 2021;9:E572-7.
5. Hernandez-Lara A, Garcia Garcia de Paredes A, Rajan E, et al. Step-by-step instruction: using an endoscopic tack and suture device for gastrointestinal defect closure. *VideoGIE* 2021;6:243-5.

Johns Hopkins Medical Institutions, Baltimore, Maryland (1).

Copyright © 2022 American Society for Gastrointestinal Endoscopy. Published by Elsevier Inc. This is an open access article under the CC BY-NC-ND license (<http://creativecommons.org/licenses/by-nc-nd/4.0/>).

<https://doi.org/10.1016/j.vgie.2021.08.006>

Endoscopyedia

Endoscopyedia has a new look! Check out the redesign of the official blog of *GIE* and *VideoGIE*. Keep up with the latest news and article discussions and post your comments or questions to *VideoGIE* authors. Visit us at www.endoscopyedia.com.