



Since January 2020 Elsevier has created a COVID-19 resource centre with free information in English and Mandarin on the novel coronavirus COVID-19. The COVID-19 resource centre is hosted on Elsevier Connect, the company's public news and information website.

Elsevier hereby grants permission to make all its COVID-19-related research that is available on the COVID-19 resource centre - including this research content - immediately available in PubMed Central and other publicly funded repositories, such as the WHO COVID database with rights for unrestricted research re-use and analyses in any form or by any means with acknowledgement of the original source. These permissions are granted for free by Elsevier for as long as the COVID-19 resource centre remains active.



ELSEVIER



www.elsevierhealth.com/journals/jinf

REVIEW

# Post-infectious encephalitis in adults: Diagnosis and management

R. Sonnevile <sup>a,\*</sup>, I. Klein <sup>b</sup>, T. de Broucker <sup>c</sup>, M. Wolff <sup>a</sup>

<sup>a</sup> Department of Critical Care Medicine and Infectious Diseases, Bichat–Claude Bernard Hospital, Université Paris 7, 46 Rue Henri Huchard, 75877 Paris Cedex 18, France

<sup>b</sup> Department of Radiology, Bichat–Claude Bernard Hospital, Université Paris 7, 46 Rue Henri Huchard, 75877 Paris Cedex 18, France

<sup>c</sup> Department of Neurology, Delafontaine Hospital, 2 Rue du Docteur Delafontaine, 93200 Saint Denis, France

Accepted 22 February 2009

Available online 14 April 2009

## KEYWORDS

Encephalitis;  
Acute disseminated  
encephalomyelitis;  
Demyelination;  
Post-infectious;  
Vaccination

**Summary** Many important central nervous system (CNS) syndromes can develop following microbial infections. The most severe forms of post-infectious encephalitis include acute disseminated encephalomyelitis (ADEM), acute hemorrhagic leukoencephalitis and Bickerstaff's brainstem encephalitis. ADEM is an inflammatory demyelinating disorder of the CNS. It typically follows a minor infection with a 2–30 days latency period and is thought to be immune-mediated. It is clinically characterized by the acute onset of focal neurological signs and encephalopathy. Patients can require intensive care unit admission because of coma, seizures or tetraplegia. Cerebrospinal fluid analysis usually shows lymphocytic pleocytosis but, unlike viral or bacterial encephalitis, no evidence of direct CNS infection is found. There are no biologic markers of the disease and cerebral magnetic resonance imaging is essential to diagnosis, detecting diffuse or multifocal asymmetrical lesions throughout the white matter on T2- and FLAIR-weighted sequences. High-dose intravenous steroids are accepted as first-line therapy and beneficial effects of plasma exchanges and intravenous immunoglobulins have also been reported. Outcome of ADEM is usually favorable but recurrent or multiphasic forms have been described.

© 2009 The British Infection Society. Published by Elsevier Ltd. All rights reserved.

## Introduction

Many important central nervous system (CNS) syndromes can develop following microbial infections. These include acute disseminated encephalomyelitis (ADEM), Bickerstaff's brainstem encephalitis, transverse myelitis and cerebellitis. Although rare, these syndromes can be severe or fatal, and

\* Corresponding author. Tel.: +33 1 40257703; fax: +33 1 40258837.

E-mail address: rsonnevile@yahoo.com (R. Sonnevile).

patients may require ICU admission because of coma, seizures or tetraplegia. The description of ADEM as a multifocal post-infectious or post-vaccinal demyelinating central nervous system disease emerged simultaneously with the increasing availability of magnetic resonance imaging (MRI).<sup>1,2</sup>

A small number of clinical studies of ADEM in adults have been published during the last decade allowing a better delineation of the disease<sup>3–6</sup> altogether with numerous pediatric studies.<sup>1,7–11</sup>

Acute encephalitis is a complex neurological syndrome that is associated with significant morbidity and mortality. Post-infectious encephalitis differs from acute infectious encephalitis or meningitis by the usual failure to isolate infectious agents from neural tissue and by the predominance of inflammation and demyelination. In a recent study about etiologies associated with encephalitis, a confirmed, probable or possible infectious etiologic agent was identified for 29% of cases. A non-infectious etiology was found for 8% of cases, and no etiology was found for 63% of cases. In the same study, 120 (8%) of a total of 1570 patients had multifocal white matter lesions noted on neuroimaging, consistent with a post-infectious disease process.<sup>12</sup> The aim of this article is to describe characteristics of these severe post-infectious CNS disorders and to offer an update on their management.

### Acute disseminated encephalomyelitis

Acute disseminated encephalomyelitis (ADEM) is usually a monophasic inflammatory demyelinating disorder of the CNS that occurs within days to weeks of a viral illness or a vaccination. The preceding infection is typically a benign upper respiratory tract infection or a non-specific febrile illness.<sup>1</sup> Historically, most cases were associated with exanthematous diseases (measles, varicella and rubella) and mortality was high, up to 25%.<sup>13</sup> ADEM has also been described after various definite infections or vaccinations that are reported in Table 1. It is predominantly a pediatric disease with an incidence of 0.4–0.8/100,000,<sup>8,14</sup> but has also been reported in adult patients<sup>3–6</sup> though incidence studies are not available. The age of onset remains young in the adult population with a mean age of 32–51 years.<sup>3–6</sup>

ADEM can be distinguished from acute viral encephalitis because the disease is not the result of primary tissue invasion by an infectious organism. It is thought to be immune-mediated and is characterized neuropathologically by perivenular inflammation and demyelination. The lesions are located around small veins in the cerebral white matter, brainstem, spinal cord, and are composed of lymphocytes and mononuclear cells. Gray matter may also be involved, particularly basal ganglia, thalami and brainstem. Axons and arteries are relatively preserved.<sup>15</sup> The involvement of the immune system in ADEM is thought to imply either the molecular mimicry phenomenon, consisting in structural homology between a pathogen and myelin proteins of the host leading to T-cell activation and specific auto-immune CNS response.<sup>16</sup> Alternatively, the direct aggression of the central nervous system by a pathogen may cause an infection-induced myelin antigen release associated with blood–brain barrier rupture.<sup>14</sup>

### Clinical presentation

Neurologic symptoms usually develop after a minor infection or vaccination, with a latency period of 2–30 days.<sup>14</sup> ADEM is clinically characterized by the acute onset (maximal neurological deficit reached within hours to days of onset) of focal neurological signs and encephalopathy. Patients can present with a clinical picture of severe CNS infection with impaired consciousness, fever and sometimes evidence of neck stiffness. Fever is not a constant feature since its frequency may be as low as 15%<sup>4</sup> but is present in 75% of the severe cases.<sup>3</sup> In the same way generalized seizures have been reported with an incidence ranging from 4% to 30% in adults.<sup>3,4</sup> Main neurological findings in adult patients illustrate the name of disseminated encephalomyelitis. They consist of focal deficits in 77–85% of cases (motor weakness, e.g., paraplegia or hemiplegia), sensory disturbances in 65–75% of cases, aphasia in 8–15% of cases,

**Table 1** Infections and vaccinations associated with acute disseminated encephalomyelitis.<sup>14,16,24,37</sup>

Infections
<b>VIRUS</b>
Smallpox (1/1000)
Rubella (1/20,000)
Varicella (1/10,000)
Mumps
Influenza A and B
HIV
HTLV-1
Hepatitis A and B
HSV, EBV, CMV, HHV6
Coxsackie
Coronavirus
<b>BACTERIA</b>
Streptococcus
Chlamydiae
Campylobacter
<i>Mycoplasma pneumoniae</i>
Legionella
Leptospira
<i>Borrelia burgdorferi</i>
<i>Rickettsia rickettsii</i>
Vaccinations
<b>Rabies</b>
- Neural type (Semple) vaccine (1/300–1/7000)
- Non-neural (Human Diploid Cell) vaccine (<1/75,000)
Diphtheria–Tetanus (0.9/100,000)
Poliomyelitis
Chickenpox (3/665,000)
Smallpox (0.1/100,000)
Japanese encephalitis (0.2/100,000)
B hepatitis (10 cases)
Influenza
Yellow fever
Frequency is indicated in brackets when known.

cranial nerve abnormalities (facial or oculomotor nerve palsy) in 40–50% of cases, and cerebellar and brainstem dysfunction (15–38% and 62% of cases, respectively).<sup>4</sup> Optic neuritis (uni- or bilateral) was reported with an incidence of 6% in a recent series of 60 adult patients with severe acute demyelinating disease.<sup>6</sup>

Spinal cord lesions of myelitis are found in approximately 15–68% of adult patients and are clinically characterized at the initial stage of the disease by para or tetraplegia (depending on lesion location) with deep tendon reflexes abolition and acute urinary retention.<sup>3–6</sup>

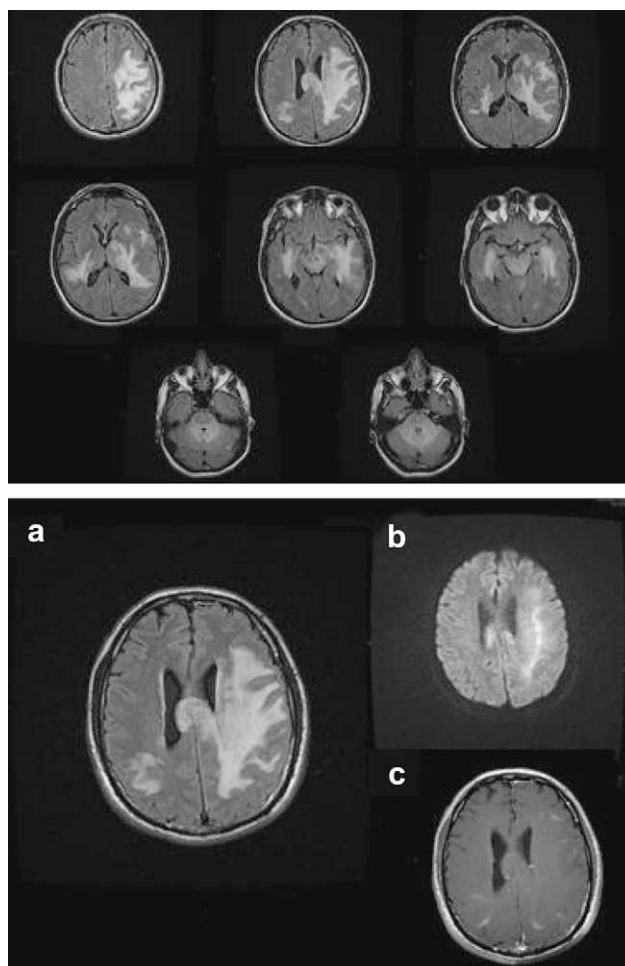
Peripheral nervous system involvement in adult patients has also been reported, with an incidence ranging from 25% to 44%.<sup>3,5</sup> Clinical examination shows evidence of polyradiculoneuropathy with abolition of deep tendon reflexes.

All the above-mentioned symptoms and signs can be observed in the same patient within 5 different patterns as reported in the study of Marchioni<sup>5</sup> where the neurological symptomatology of 60 patients was distributed as follows: encephalitis: 20%, encephalomyelitis: 13.3%, myelitis: 23.3%, encephalomyeloradiculitis: 26.7%, and myeloradiculitis: 16.7%. Because lesions can sometimes be clinically asymptomatic, a systematic neuroimaging work-up should be performed when ADEM is suspected.

### Neuroimaging

Cerebral computed tomography scans performed at admission show abnormalities only in 30% of patients, essentially supratentorial readily visible diffuse or large focal hypodensities of the cerebral white matter.<sup>3</sup> MRI of the brain should therefore be systematically performed when post-infectious encephalitis is suspected. For some authors, the diagnosis of ADEM has to be debated if MRI shows no abnormality.<sup>14</sup> MRI lesions are identified on morphological T2-weighted and fluid-attenuated inversion recovery (FLAIR) sequences. Although no specific MRI criteria have been identified, 4 MRI lesion patterns are generally recognized, but in all cases lesions are multifocal and involve mainly the supratentorial white matter: (1) multifocal lesions of less than 5 cm, (2) confluent multifocal lesions of more than 5 cm, (3) multifocal lesions involving basal ganglia, and (4) multifocal hemorrhagic and oedematous lesions in the Weston Hurst disease.<sup>17</sup> Although patchy areas of increased signal intensity are stated to involve 50% or more of total white matter in children,<sup>11,18</sup> no lesion volume has been proposed in adult ADEM patients. ADEM lesions in such patients are typically large, multiple, and asymmetric. Severe and extensive T2 lesions usually contrast with a relatively small mass effect. The distribution of lesions involves the subcortical and central white matter and cortical gray–white junction of both cerebral hemispheres and infratentorial areas.<sup>16</sup> A pattern of diffuse demyelination can be seen in the most severe cases in adults with large demyelinating lesions of the white matter extending to the corpus callosum and to the contralateral hemisphere (Fig. 1).<sup>3,14,16</sup>

Deep gray matter (thalami and basal ganglia) involvement is reported in 15–60% of cases in adults.<sup>3,4</sup> Although cortical gray matter lesions can be detected in the earliest stages of multiple sclerosis (MS),<sup>19</sup> deep gray matter

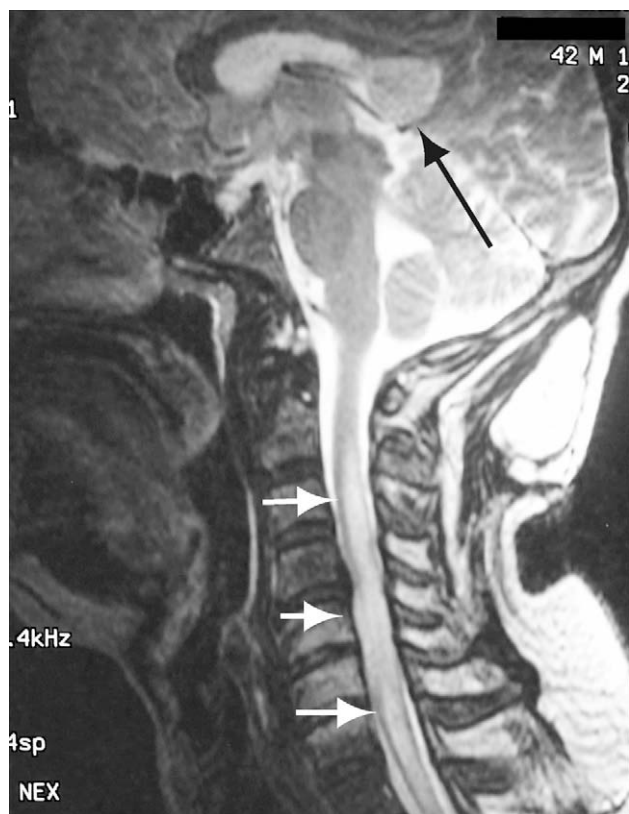

**Figure 1** Acute disseminated encephalomyelitis: FLAIR-weighted images (top panel) obtained in a 55-year-old patient admitted to the ICU for fever and impaired consciousness. CSF analysis showed evidence of aseptic meningitis. Note a characteristic pattern of extensive and diffuse hyperintense lesions affecting the brainstem and supratentorial regions with a comparatively small mass effect. Lesions not only affect the white matter but also para-hippocampal gyrus, left thalamus and typically cross over the corpus callosum. In the same patient (bottom), isotropic diffusion (b) is less sensitive than T2 FLAIR sequences (a), showing hyperintensities with a non-specific increased ADC (not shown). Note also partial "open-ring" enhancement on T1-weighted post-contrast corresponding image (c).

involvement appears to be a reliable criteria to differentiate ADEM from MS in patients with a diagnosis of acute demyelination of the CNS.<sup>6</sup>

Spinal cord lesions, consisting of focal or diffuse myelitis, are seen in up to 63% of patients<sup>5</sup> (Fig. 2). Enhancement of the lesions is variable. If present, it is usually moderate with a linear and open-ring pattern, involving all the lesions at the same time.<sup>17</sup>

There are few data on the value of diffusion MRI in the diagnosis of ADEM. Lesions may have a bright signal on the isotropic b1000 diffusion sequence with variable apparent diffusion coefficients. Diffusion coefficient may vary with the stage of the disease, being restricted at the acute



**Figure 2** Acute disseminated encephalomyelitis: T2-weighted image obtained in a 42-year-old patient admitted to the ICU for bilateral diaphragmatic palsy 8 days after an acute myelopathy. Spinal cord hyperintensity and swelling involving more than 3 segments (white arrows). Corpus callosum hyperintensity and swelling (black arrow).

phase then increasing in the chronic stage.<sup>20</sup> For some authors, decreased initial diffusion may lead to a poor prognosis.<sup>21</sup> Proton MR spectroscopy may show a non-specific progressive NAA/choline ratio decrease.<sup>20</sup>

### Cerebrospinal fluid

Cerebrospinal fluid (CSF) findings of ADEM patients are usually non-specific and include lymphocytic pleocytosis with elevated protein levels and sterile cultures. Our observations in adults demonstrate that neutrophils in CSF predominate in approximately one-fourth of the patients. These findings did not seem to be associated with an adverse outcome.<sup>3</sup> CSF examination can be strictly normal in 19–33% of adult patients.<sup>4,22</sup> Oligoclonal bands in CSF analysed with isoelectric focusing should be systematically sought in patients with a presumed diagnosis of acute demyelination of the CNS. Their presence is reported in about 90% of multiple sclerosis patients but they are rarely detected in other forms of CNS demyelination such as ADEM and neuromyelitis optica.<sup>6,23</sup>

### Diagnosis of ADEM

Distinction between infectious and post-infectious encephalitis can be difficult and all frequent causes of infectious

encephalitis must be excluded before concluding to an acute form of post-infectious inflammatory CNS disorder. Patients' CSF should systematically be screened for herpes CNS infections (*Herpes Simplex* and *Varicella-Zoster Virus*), viruses relevant to specific geographical regions and other frequent causes of infectious encephalitis.<sup>12</sup> Intracerebral malignancies, including CNS lymphomas, should also always be considered. Many systemic diseases (Behçet's disease, systemic lupus erythematosus, sarcoidosis), primary or secondary small-vessel CNS vasculitis and vascular, toxic or infectious leukoencephalopathies can mimic ADEM (Table 2).<sup>14,24</sup> However the time course of ADEM is most often acute or hyperacute and rather different from the one encountered in the majority of the above-mentioned diseases. CNS angiography, typically normal in ADEM patients, can show abnormalities in patients with moderate-vessel to large-vessel vasculitis. In all cases of unexplained encephalopathy with multifocal areas of increased signal of the CNS white matter, brain biopsy should be considered.<sup>23</sup>

A diagnosis algorithm is proposed in Fig. 3. Diagnostic criteria taking into account history, clinical presentation, and MRI patterns have been recently proposed for pediatric forms of ADEM and are reported in Table 3.<sup>25</sup>

### Other forms of severe post-infectious central nervous system disorders

#### Acute hemorrhagic leukoencephalitis

Acute hemorrhagic leukoencephalitis (AHLE) is a rare disorder that may represent a distinct form of post-infectious CNS disorder or may be the more severe form of ADEM. It usually appears 1–20 days following a non-specific illness, mainly non-specific upper respiratory tract infection. The onset is brutal, with fever, coma, seizures and focal neurologic signs. The disease is fulminant and the mortality can be as high as 70%, leaving survivors with significant sequelae.<sup>26</sup> CSF analysis at onset shows pleocytosis and elevated red blood cell count. MRI lesions are consistent with hyperintensities of the white matter which are widespread in both hemispheres, with relative sparing of gray matter. In AHLE the diffuse white matter lesions are more often non-enhancing but accompanied by evidence of cerebral oedema and haemorrhage.<sup>27</sup> Large bihemispheric areas of demyelination with petechial haemorrhages can be seen on T2\*-weighted sequences in the peripheral white matter.<sup>28</sup> The neuropathology of AHLE consists in fibrinoid necrosis of veins and arterioles, accompanied by exudates in the perivascular area with intense polymorphonuclear cell infiltration. White matter analysis shows myelin loss and relative preservation of axons. Some authors reported the benefit of early aggressive therapy in AHLE, with both surgical management of raised intracranial pressure and immunosuppression with cyclophosphamide.<sup>29</sup>

#### Bickerstaff's brainstem encephalitis

In 1957, Bickerstaff reported 8 patients who showed acute brainstem dysfunction (drowsiness, ophthalmoplegia and

**Table 2** Differential diagnosis of white matter lesions in ICU patients admitted for CNS disorders.

---

PRES: hypertensive encephalopathy, eclampsia, tacrolimus, cyclosporin  
 ADEM, pseudo-tumoral forms of multiple sclerosis  
 Brain abscess  
 CNS malignancies: lymphoma, gliomatosis cerebri, brain metastasis  
 Infectious encephalitis, including rhombencephalitis (listeria, arboviruses)  
 HIV patients: IRIS, progressive multifocal leukoencephalopathy  
 Small-vessel vasculitis of the CNS, primary or secondary to infections,<sup>a</sup> collagen diseases,<sup>b</sup> systemic vasculitis or malignancies<sup>c</sup>  
 Toxics: inhaled heroin, carbon monoxide  
 Metabolic disorders: Marchiafava–Bignami disease, Wernicke–Korsakoff encephalopathy, central- and extra-pontine myelinolysis  
 Mitochondrial disorders

---

ICU intensive care unit; CNS central nervous system; PRES posterior reversible encephalopathy syndrome; ADEM acute disseminated encephalomyelitis; and IRIS immune reconstitution inflammatory syndrome.

<sup>a</sup> Bacterial and tuberculous meningitis, VZV encephalitis, HIV, neurosyphilis, Lyme disease, cerebral malaria and infective endocarditis.

<sup>b</sup> Behçet's syndrome, systemic lupus erythematosus, and Gougerot-Sjögren syndrome.

<sup>c</sup> Paraneoplastic vasculitis.

ataxia) in association with abnormal motor or sensory function. This condition has been named Bickerstaff's brainstem encephalitis (BBE). In 2003, Odaka et al. reported a large series of 62 patients with progressive (maximal deficit reached within 4 weeks), symmetrical external ophthalmoplegia and ataxia, associated with disturbance of consciousness or hyperreflexia.<sup>30</sup> Ninety-two percent of the patients had a history of recent illness. Associated flaccid symmetrical tetraparesis was seen in 60% of the patients. Stupor or coma was reported in 74%. Facial diplegia was present in 45%, and pupillary abnormalities and bulbar palsy were found in 34%. Deep tendon reflexes were absent or decreased in 58%. Serum anti-GQ1b IgG antibody was positive in 66% of patients. MRI showed abnormalities in the posterior fossa, white matter or thalami in 30% of the patients, consisting of hyperintense lesions on T2-weighted sequences.<sup>31</sup> Neuropathologic findings showed evidence of perivascular lymphocytic infiltration with

oedema and glial nodules in the brainstem. BBE has a monophasic remitting course and a good outcome with complete remission of symptoms in 66% of patients.<sup>32</sup> The effect of specific immunotherapy in BBE remains uncertain.<sup>33</sup>

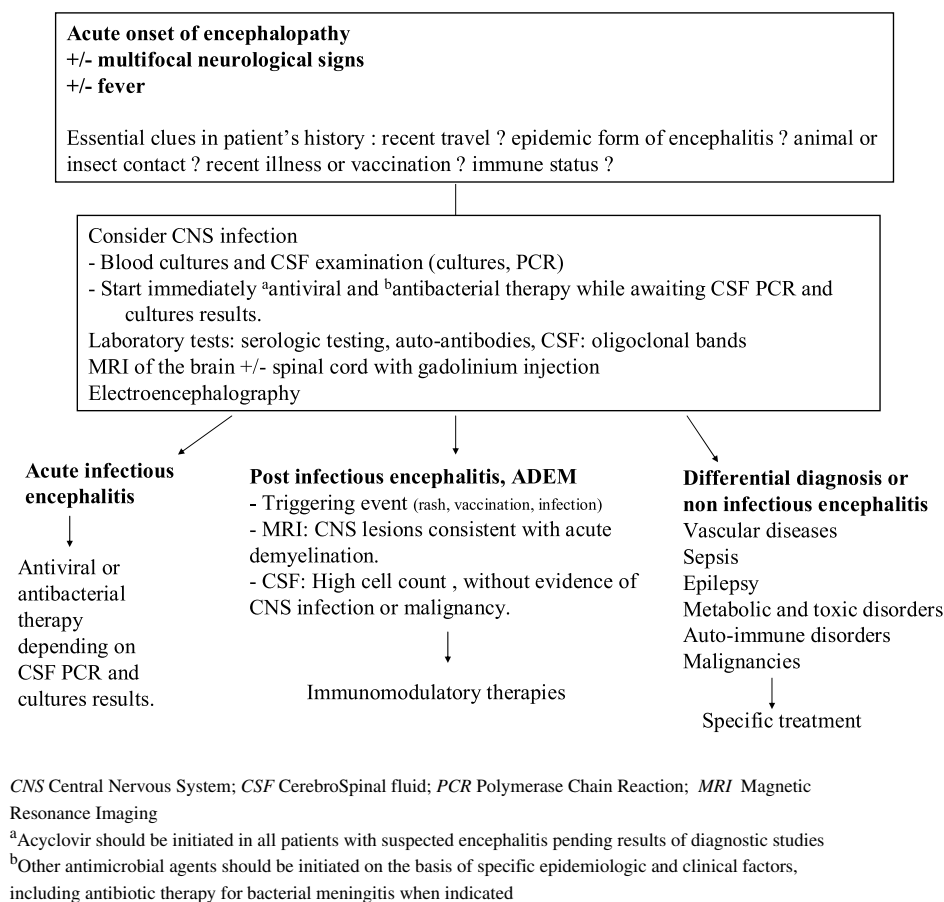
## Initial management of patients

### General supportive measures

Patients with encephalitis are at high risk for developing serious complications and must be immediately transferred to the intensive care unit in case of deterioration of mental status. Careful attention should be paid to the maintenance of respiration, hemodynamics and fluid balance. Prevention of deep venous thrombosis should be adopted. Endotracheal intubation needs to be performed early in case of encephalopathy, recurrent seizures or aspiration.<sup>34</sup>

**Table 3** Consensus definition proposed for acute disseminated encephalomyelitis, adapted from Ref. [25].

- 
- A first clinical event with a presumed inflammatory cause, with acute or subacute onset that affects multifocal areas of the CNS.
  - The clinical presentation must be polysymptomatic and must include encephalopathy (behavioral change, e.g., confusion) and alteration in consciousness (e.g., lethargy, coma).
  - Event should be followed by improvement, either clinically, on MRI, or both, but there may be residual deficits.
  - No history of a clinical episode with features of a prior demyelinating event.
  - No other etiologies can explain the event.
  - New or fluctuating signs, or MRI findings occurring within 3 months of the inciting ADEM event are considered part of the acute event.
  - Neuroimaging shows focal or multifocal lesion(s), predominantly involving white matter, without radiologic evidence of previous destructive white matter changes.
  - FLAIR- or T2-weighted images reveal large (1–2 cm), multifocal, hyperintense lesions, located in the supratentorial or infratentorial white matter regions.
  - Gray matter, especially basal ganglia and thalamus, is frequently involved.
  - In rare cases, brain MR images show a large single lesion (1–2 cm), predominantly affecting white matter.
  - Spinal cord MRI may show confluent intramedullary lesion(s) with variable enhancement, in addition to abnormal brain MRI findings above specified.
-



**Figure 3** Algorithm proposed for the initial management of acute forms of encephalitis admitted to the intensive care unit (adapted from Refs. [34,36]).

Other measures include aggressive efforts to avoid raised intracranial pressure (correction of hyperthermia, head inclination  $>30^\circ$ , fluid balance, optimize ventilation to maintain a normal  $\text{PaCO}_2$ ...) and rapid control of seizures. Surgical decompression may be required to reduce raised intracranial pressure refractory to medical management.<sup>35</sup>

### Immunomodulatory therapy

There is no standard treatment for ADEM and high-dose intravenous steroids are widely accepted as first-line therapy. Other non-specific immunomodulatory therapies include intravenous immunoglobulin or plasma exchange. Most of the data describing treatment for ADEM are derived from case reports and small series. To date, there have been no randomized, controlled trials for the treatment of ADEM in either children or adults.

### Steroids

Although there are no controlled studies about the dose or effectiveness of corticosteroids for ADEM and other forms of acute demyelinating disorders, high-dose steroids are now accepted and have been recently recommended with a class III level of evidence.<sup>36</sup> Intravenous (IV) methylprednisolone pulse has been the most widely reported therapy, up to a maximum dose of 1 g/day, for 3–5 days.<sup>16,37</sup> Higher

doses (IV methylprednisolone 1 g daily until a total dose of 6–10 g) have been reported in severe forms of steroid-resistant post-infectious encephalomyelitis.<sup>3,38</sup> Pulses are usually followed by oral steroid (prednisone 1 mg/kg/day) taper for 4–6 weeks, but it might be therapeutically unnecessary if symptoms start to improve. High-dose steroid treatment is not without risk: hyperglycemia, hypokalemia, high blood pressure and mood disorders should be carefully monitored at the initial phase of treatment.<sup>16</sup>

### Plasma exchange

Although there is class I level of evidence for the benefit of plasma exchange (PE) for acute life-threatening demyelination in adults, its use in ADEM patients has been reported in only a small number of patients, after steroid treatment failure. A series examined the outcome following PE for 59 patients with a variety of severe CNS demyelinating diseases (10 cases of ADEM). Ninety-two percent of the patients had been previously treated with high-dose steroids. Forty-four percent of the patients had moderate to marked improvement following PE.<sup>39</sup> In this cohort, a mean number of 7 exchanges were performed. Male sex, preserved reflexes and early initiation of treatment (within 21 days after onset) were associated with moderate or marked improvement. Successfully treated patients showed rapid and sustained improvement following PE.<sup>40</sup>

## Intravenous immunoglobulins

There have been no studies which have directly compared intravenous immunoglobulins (IVIg) with steroids, PE, or other immunomodulatory treatments. Published case series advocate doses of 1–2 g/kg, administered over 3–5 days.<sup>7</sup> The potential utility of IVIg has recently been reported in severe steroid-resistant post-infectious encephalomyelitis. The authors observed that steroid-resistant patients showed high prevalence of PNS damage (89%) and myelitis (95%). Other features were old age, severe disability at onset, and evidence of blood–brain barrier damage on CSF analysis. IVIg was effective, the clinical improvement beginning within the end of the treatment. Prominent effects of IVIg were detectable on motor dysfunction. Milder onset disability ( $p = 0.013$ ) and lower CSF albumin ( $p = 0.006$ ) were the predictors of IVIg response.<sup>38</sup> Treatment with IVIg might also be of value for patients in whom corticosteroid therapy is contraindicated.<sup>23</sup>

## Outcome

Outcome of ADEM patients is usually favorable, with mortality rates less than 5% in pediatric series. In adults, mortality is higher, especially in patients requiring ICU admission, ranging from 8% to 25%.<sup>3,4</sup>

Recurrent and multiphasic forms have been reported, mainly in children. In adults, approximately 30% of patients will develop a clinically definite form of multiple sclerosis (MS), with recurrences of demyelinating events.<sup>4,6</sup> Some authors proposed criteria to evaluate the risk of evolution to MS after a first episode of severe demyelination, namely: atypical clinical symptoms for MS (one or more of the following: consciousness alteration, aphasia, hemiplegia, paraplegia, tetraplegia, seizure, vomiting, bilateral optic neuritis, or confusion), absence of oligoclonal bands in CSF and gray matter involvement (basal ganglia, cortical gray matter). The presence of 2 of these 3 criteria is suggestive of ADEM disease with a positive predictive value of 97% and a negative predictive value of 75%.<sup>6</sup>

Patients need to be evaluated after ICU discharge and clinical and neuroimaging follow-up should be systematically performed by a neurologist.

## Conclusion

Post-infectious CNS disorders are rare in adults, but should be considered in all cases of unexplained encephalitis, especially in a setting of recent infectious disease or vaccination. Diffuse and focal CNS signs and peripheral nervous system involvement may be present simultaneously at physical examination. Brain and spinal cord MRI should be systematically performed at the initial phase of the disease to look for evidence of multifocal acute inflammation and demyelination. In a subset of adult patients requiring ICU admission, post-infectious encephalitis can be associated with a severe prognosis and intensivists should be aware of the clinical and neuroimaging features in order to initiate appropriate immunomodulating therapy.

## References

1. Dale RC, de Sousa C, Chong WK, Cox TC, Harding B, Neville BG. Acute disseminated encephalomyelitis, multiphasic disseminated encephalomyelitis and multiple sclerosis in children. *Brain* 2000;**123**(Pt 12):2407–22.
2. Dale RC. Acute disseminated encephalomyelitis. *Semin Pediatr Infect Dis* 2003;**14**(2):90–5.
3. Sonnevile R, Demeret S, Klein I, Bouadma L, Mourvillier B, Audibert J, et al. Acute disseminated encephalomyelitis in the intensive care unit: clinical features and outcome of 20 adults. *Intensive Care Med* 2008;**34**(3):528–32.
4. Schwarz S, Mohr A, Knauth M, Wildemann B, Storch-Hagenlocher B. Acute disseminated encephalomyelitis: a follow-up study of 40 adult patients. *Neurology* 2001;**56**(10):1313–8.
5. Marchioni E, Ravaglia S, Piccolo G, Furione M, Zardini E, Franciotta D, et al. Postinfectious inflammatory disorders: subgroups based on prospective follow-up. *Neurology* 2005;**65**(7):1057–65.
6. de Seze J, Debouverie M, Zephir H, Lebrun C, Blanc F, Bourg V, et al. Acute fulminant demyelinating disease: a descriptive study of 60 patients. *Arch Neurol* 2007;**64**(10):1426–32.
7. Tenenbaum S, Chamoles N, Fejerman N. Acute disseminated encephalomyelitis: a long-term follow-up study of 84 pediatric patients. *Neurology* 2002;**59**(8):1224–31.
8. Leake JA, Albani S, Kao AS, Senac MO, Billman GF, Nespeca MP, et al. Acute disseminated encephalomyelitis in childhood: epidemiologic, clinical and laboratory features. *Pediatr Infect Dis J* 2004;**23**(8):756–64.
9. Murthy JM, Yangala R, Meena AK, Jaganmohan Reddy J. Acute disseminated encephalomyelitis: clinical and MRI study from South India. *J Neurol Sci* 1999;**165**(2):133–8.
10. Mikaeloff Y, Caridade G, Husson B, Suissa S, Tardieu M. Acute disseminated encephalomyelitis cohort study: prognostic factors for relapse. *Eur J Paediatr Neurol* 2007;**11**(2):90–5.
11. Hynson JL, Kornberg AJ, Coleman LT, Shield L, Harvey AS, Kean MJ. Clinical and neuroradiologic features of acute disseminated encephalomyelitis in children. *Neurology* 2001;**56**(10):1308–12.
12. Glaser CA, Honarmand S, Anderson LJ, Schnurr DP, Forghani B, Cossen CK, et al. Beyond viruses: clinical profiles and etiologies associated with encephalitis. *Clin Infect Dis* 2006;**43**(12):1565–77.
13. Johnson RT, Griffin DE, Hirsch RL, Wolinsky JS, Roedenbeck S, Lindo de Soriano I, et al. Measles encephalomyelitis – clinical and immunologic studies. *N Engl J Med* 1984;**310**(3):137–41.
14. Menge T, Hemmer B, Nessler S, Wiendl H, Neuhaus O, Hartung HP, et al. Acute disseminated encephalomyelitis: an update. *Arch Neurol* 2005;**62**(11):1673–80.
15. Love S. Demyelinating diseases. *J Clin Pathol* 2006;**59**(11):1151–9.
16. Tenenbaum S, Chitnis T, Ness J, Hahn JS. Acute disseminated encephalomyelitis. *Neurology* 2007;**68**(16 Suppl. 2):S23–36.
17. Rossi A. Imaging of acute disseminated encephalomyelitis. *Neuroimaging Clin N Am* 2008;**18**(1):149–61. ix.
18. Mikaeloff Y, Adamsbaum C, Husson B, Vallee L, Ponsot G, Confavreux C, et al. MRI prognostic factors for relapse after acute CNS inflammatory demyelination in childhood. *Brain* 2004;**127**(Pt 9):1942–7.
19. Pirko I, Lucchinetti CF, Sriram S, Bakshi R. Gray matter involvement in multiple sclerosis. *Neurology* 2007;**68**(9):634–42.
20. Balasubramanya KS, Kovoov JM, Jayakumar PN, Ravishankar S, Kamble RB, Panicker J, et al. Diffusion-weighted imaging and proton MR spectroscopy in the characterization of acute disseminated encephalomyelitis. *Neuroradiology* 2007;**49**(2):177–83.
21. Axer H, Ragoschke-Schumm A, Bottcher J, Fitzek C, Witte OW, Isenmann S. Initial DWI and ADC imaging may predict outcome



- in acute disseminated encephalomyelitis: report of two cases of brain stem encephalitis. *J Neurol Neurosurg Psychiatr* 2005;**76**(7):996–8.
22. Lin CH, Jeng JS, Hsieh ST, Yip PK, Wu RM. Acute disseminated encephalomyelitis: a follow-up study in Taiwan. *J Neurol Neurosurg Psychiatr* 2007;**78**(2):162–7.
  23. Banwell B, Ghezzi A, Bar-Or A, Mikaeloff Y, Tardieu M. Multiple sclerosis in children: clinical diagnosis, therapeutic strategies, and future directions. *Lancet Neurol* 2007;**6**(10):887–902.
  24. Garg RK. Acute disseminated encephalomyelitis. *Postgrad Med J* 2003;**79**(927):11–7.
  25. Krupp LB, Banwell B, Tenembaum S. Consensus definitions proposed for pediatric multiple sclerosis and related disorders. *Neurology* 2007;**68**(16 Suppl. 2):S7–12.
  26. Davies NW, Sharief MK, Howard RS. Infection-associated encephalopathies: their investigation, diagnosis, and treatment. *J Neurol* 2006;**253**(7):833–45.
  27. Kuperan S, Ostrow P, Landi MK, Bakshi R. Acute hemorrhagic leukoencephalitis vs ADEM: FLAIR MRI and neuropathology findings. *Neurology* 2003;**60**(4):721–2.
  28. Canellas AR, Gols AR, Izquierdo JR, Subirana MT, Gairin XM. Idiopathic inflammatory-demyelinating diseases of the central nervous system. *Neuroradiology* 2007;**49**(5):393–409.
  29. Markus R, Brew BJ, Turner J, Pell M. Successful outcome with aggressive treatment of acute haemorrhagic leukoencephalitis. *J Neurol Neurosurg Psychiatr* 1997;**63**(4):551.
  30. Odaka M, Yuki N, Yamada M, Koga M, Takemi T, Hirata K, et al. Bickerstaff's brainstem encephalitis: clinical features of 62 cases and a subgroup associated with Guillain–Barre syndrome. *Brain* 2003;**126**(Pt 10):2279–90.
  31. Mondejar RR, Santos JM, Villalba EF. MRI findings in a remitting-relapsing case of Bickerstaff encephalitis. *Neuroradiology* 2002;**44**(5):411–4.
  32. Overell JR, Willison HJ. Recent developments in Miller Fisher syndrome and related disorders. *Curr Opin Neurol* 2005;**18**(5):562–6.
  33. Overell JR, Hsieh ST, Odaka M, Yuki N, Willison HJ. Treatment for Fisher syndrome, Bickerstaff's brainstem encephalitis and related disorders. *Cochrane Database Syst Rev* 2007;(1):CD004761.
  34. Wijdicks EFM. *Acute viral encephalitis*. New York: Oxford University Press; 2003.
  35. Sekula Jr RF, Marchan EM, Baghai P, Jannetta PJ, Quigley MR. Central brain herniation secondary to fulminant acute disseminated encephalomyelitis: implications for neurosurgical management. Case report. *J Neurosurg* 2006;**105**(3):472–4.
  36. Tunkel AR, Glaser CA, Bloch KC, Sejvar JJ, Marra CM, Roos KL, et al. The management of encephalitis: clinical practice guidelines by the Infectious Diseases Society of America. *Clin Infect Dis* 2008;**47**(3):303–27.
  37. Bennetto L, Scolding N. Inflammatory/post-infectious encephalomyelitis. *J Neurol Neurosurg Psychiatr* 2004;**75**(Suppl. 1):i22–8.
  38. Ravaglia S, Piccolo G, Ceroni M, Franciotta D, Pichiecchio A, Bastianello S, et al. Severe steroid-resistant post-infectious encephalomyelitis: general features and effects of IVIg. *J Neurol* 2007;**254**(11):1518–23.
  39. Weinshenker BG, O'Brien PC, Petterson TM, Noseworthy JH, Lucchinetti CF, Dodick DW, et al. A randomized trial of plasma exchange in acute central nervous system inflammatory demyelinating disease. *Ann Neurol* 1999;**46**(6):878–86.
  40. Keegan M, Pineda AA, McClelland RL, Darby CH, Rodriguez M, Weinshenker BG. Plasma exchange for severe attacks of CNS demyelination: predictors of response. *Neurology* 2002;**58**(1):143–6.