



■ KNEE

Matrix assisted autologous chondrocyte transplantation for cartilage treatment

A SYSTEMATIC REVIEW

**E. Kon,
G. Filardo,
B. Di Matteo,
F. Perdisa,
M. Marcacci**

*From Rizzoli
Orthopaedic Institute,
Bologna, Italy*

Objectives

Matrix-assisted autologous chondrocyte transplantation (MACT) has been developed and applied in the clinical practice in the last decade to overcome most of the disadvantages of the first generation procedures. The purpose of this systematic review is to document and analyse the available literature on the results of MACT in the treatment of chondral and osteochondral lesions of the knee.

Methods

All studies published in English addressing MACT procedures were identified, including those that fulfilled the following criteria: 1) level I-IV evidence, 2) measures of functional or clinical outcome, 3) outcome related to cartilage lesions of the knee cartilage.

Results

The literature analysis showed a progressively increasing number of articles per year. A total of 51 articles were selected: three randomised studies, ten comparative studies, 33 case series and five case reports. Several scaffolds have been developed and studied, with good results reported at short to medium follow-up.

Conclusions

MACT procedures are a therapeutic option for the treatment of chondral lesions that can offer a positive outcome over time for specific patient categories, but high-level studies are lacking. Systematic long-term evaluation of these techniques and randomised controlled trials are necessary to confirm the potential of this treatment approach, especially when comparing against less ambitious traditional treatments.

Keywords: Matrix-assisted autologous chondrocyte transplantation, Cartilage regeneration, Scaffold, Bioengineering, Tissue engineering

■ E. Kon, MD, Orthopaedic Surgeon
■ G. Filardo, MD, Orthopaedic Surgeon
■ B. Di Matteo, MD, Resident in Orthopaedic Surgery
■ F. Perdisa, MD, Resident in Orthopaedic surgery
■ M. Marcacci, MD, Orthopaedic surgeon
Rizzoli Orthopaedic Institute, Biomechanics Laboratory and II Orthopaedic Clinic, Via di Barbiano n. 1/10, Bologna 40136, Italy.

Correspondence should be sent to Dr E. Kon; e-mail: e.kon@biomec.ior.it

10.1302/2046-3758.22.2000092 \$2.00

Bone Joint Res 2013;2:18–25.
Received 26 April 2012; Accepted after revision 21 November 2012

Introduction

The complex biomechanical features of hyaline cartilage are difficult to reproduce. An articular chondral surface has a peculiar ultrastructure, with chondrocytes sparsely distributed and minimal cell-to-cell contact, interacting in a surrounding matrix characterised by a complex framework of collagen, aggrecan and fluid.^{1–3} Treatment options aimed at the recruitment of potential cartilage precursors allowing stem cell migration from the marrow cavity to the fibrin clot of the defect, such as abrasion, drilling and microfracture, produce predominantly type I collagen, fibrocytes and an unorganised matrix.⁴ This fibrous repair tissue lacks the biomechanical and viscoelastic characteristics of the original hyaline cartilage, and does not lead to durable results.⁵

Techniques aiming at transferring autologous osteochondral units from less weight-bearing areas to repair the lesion with a healthy tissue allow a valid articular surface to be reconstructed with good coverage of the defect and graft stability in small lesions.⁶ Donor site availability and technical difficulties are critical aspects that limit this approach for medium to large surfaces. An alternative option is the use of homologous osteochondral grafts, but there are concerns regarding low availability, the difficulty of preserving and managing fresh allografts and the risk of disease transmission.^{7,8} These concerns have reduced the indication of this procedure to large osteochondral lesions in young patients with high functional requirements, who are otherwise doomed to poor clinical outcome.⁹

The pioneers of this ambitious treatment approach developed and introduced the autologous chondrocyte implantation (ACI) technique in Sweden showing firstly in 1994 satisfactory results for the treatment of isolated femoral condyle lesions.¹⁰ Several studies followed and claimed both the production of a hyaline-like articular surface and a good outcome at medium to long-term follow-up: Vasiliadis et al¹¹ used MRI to show good tissue quality despite the evidence of some osteophytes, cysts, and oedema, and Peterson et al¹² reported good results in 224 cases at 13 years with 92% of patients satisfied (n = 206). However, these good results have to be weighed against several problems. From a surgical point of view, the standard ACI procedure presents various limitations related to the complexity and morbidity of the technique, including the difficulty in handling a delicate liquid suspension of chondrocytes, the need to make a hermetic periosteum seal using sutures to avoid cell leakage, the requirement of a second open surgery with a subsequent long rehabilitation period, and a high rate of complications and re-operation due to flap hypertrophy, arthrofibrosis and joint stiffness.¹³ From a biological point of view, critical aspects are the maintenance of the chondrocyte phenotype during the prolonged monolayer culture and the risk of a non-homogeneous distribution of the liquid cell suspension in the lesion area.¹³ Tissue engineering has been developed to address most of these problems, leading to the introduction into clinical practice ten years ago of the so-called matrix-assisted autologous chondrocyte transplantation (MACT) procedures.¹⁴

The aim of this systematic review is to document and analyse the available evidence in the literature on the results obtained in clinical practice by MACT techniques to address chondral and osteochondral knee lesions.

Materials and Methods

All studies on MACT procedures published in English were identified. Two reviewers performed a search of the Medline database from 2000 to March 2012, using the terms “cartilage regeneration”, “autologous chondrocyte transplantation”, “autologous chondrocyte implantation”, “second / third generation ACI”, “matrix-assisted chondrocyte implantation”, “scaffold-based repair” and “osteochondral repair”. Studies were included in our systematic review if they fulfilled the following criteria: 1) level I-IV evidence addressing the areas of interest outlined above; 2) measures of functional or clinical outcome; 3) outcome related to knee cartilage lesions. Citations from relevant studies, as well as any relevant articles captured by the search, were also examined to determine if they were suitable for inclusion. Studies not fulfilling these criteria were excluded.

Results

The search identified 187 articles. The number of articles per year increased progressively from 2000, as

depicted in Figure 1. Including those with short follow-up, a total of 51 articles fulfilled the inclusion criteria: there were three randomised studies, ten comparative studies, 33 case series, and five case reports. All studies are reported and summarised in Table 1¹⁵⁻⁶⁶; those reporting clinical results at a minimum follow-up of two years are described in more detail in the following paragraphs.

Matrix autologous chondrocyte implantation (MACI).

The first autologous chondrocyte transplantation using a porcine collagen type I/III membrane (Chondro-Gide; Geistlich Biomaterials, Wolhusen, Switzerland) was performed in 1998.⁶⁷ As in every MACT procedure, the surgical technique involves two surgical steps: harvesting articular cartilage from a non-weight-bearing area and, after culturing cells for four weeks and then seeding and culturing for the remaining three days on the rough side of the collagen matrix, implantation of the bio-engineered tissue into the lesion (MACI; Verigen Transplantation Service, Copenhagen, Denmark). In 2006 Behrens et al¹⁵ published a five-year prospective study, reporting that eight of 11 patients rated the function of their knee as much better or better than before. In the same year Ronga et al¹⁶ reported the successful treatment of a complex knee ligament, meniscal and chondral lesion in a 40-year-old sportsman at two years' follow-up. Normal biomechanics of the joint were restored by performing a collagen meniscus implant and anterior cruciate ligament reconstruction during the first step, and after six months a 5 cm² chondral lesion was treated with the second-step MACI procedure. Salzmann et al¹⁷ confirmed these good results in a comparative study, in which nine patients treated with MACI obtained a significant clinical improvement with results higher than those obtained in a matching group of patients who underwent osteochondral autograft transplantation. Gigante et al¹⁸ focused on a specific patient population affected by patellar lesion and treated with patellofemoral distal realignment and cartilage reconstruction: all 12 patients (14 knees) presented a significant improvement in all scales. Basad et al¹⁹ performed a randomised trial comparing MACI and microfracture for the treatment of lesions > 4 cm²: at two years, MACI demonstrated significantly higher and more stable results over time. Ebert et al²⁰ evaluated 35 patients at five years, showing a clinical and MRI improvement up to two years and then stable results over time, with 35 patients (86%) satisfied with the results. More recently, Macmull et al²¹ evaluated the treatment of symptomatic chondromalacia patellae in 23 patients evaluated at a follow-up of 40 months: results were satisfactory and better than those obtained in a comparative ACI group. Bauer et al²² combined MACI and neutralising high tibial osteotomy in patients with medial knee osteoarthritis and varus deformity, documenting good clinical and MRI results initially but a

Table I. Details of the 51 articles focusing on clinical results of matrix assisted autologous chondrocyte implantation (MACI) procedures

Author/s	Procedure	Patients (n) [*]	Mean size of lesion (cm ²) (range)	Mean follow-up (yrs)	Study level [†]
2003					
Marcacci et al ⁵⁴	Hyalograft C	20	2.9	1	Prospective study
Cherubino et al ⁵⁵	MACI	13	3.5	6.5 mths (2 to 15)	Case series
Pavesio et al ⁵⁶	Hyalograft C	67	-	17.5 mths	Cohort study
2004					
Ronga et al ⁵⁷	MACI	1	2	1	Case report
Marlovits et al ⁵⁸	MACI	16	4.7 (2.6 to 10.9)	3.1 mths	Case series
2005					
Bartlett et al ⁵⁹	MACI	5	2.2 to 8.0	1	Prospective study
Bartlett et al ⁶⁰	MACI	44 ACI-C/47 MACI	6.1	1	RCT
Marcacci et al ²⁴	Hyalograft C	141	3.5	38 mths	Case series
2006					
Nehrer et al ²⁵	Hyalograft C	36	1.5 to 8	3	Case series
Behrens et al ¹⁵	MACI	11	1.5 to 17.7	5	Case series
Ronga et al ¹⁶	MACI	1	5	2	Case report
Gobbi et al ²⁶	Hyalograft C	32	4.7	2	Case series
2007					
Marcacci et al ²⁸	Hyalograft C	70	2.4	2 to 4	Case series
Manfredini et al ⁶¹	Hyalograft C	17 ACI/10 Hyalograft C	-	1	Comparative study
Adachi et al ⁵¹	Atelocollagen	1	5 and 3	2	Case report
Ossendorf et al ³⁸	Bioseed C	40	4.6	2	Case series
2008					
Ebert et al ⁶²	MACI	62	-	2	RCT
Selmi et al ⁴⁸	Cartipatch	17	3	2	Case series
Ferruzzi et al ³⁰	Hyalograft C	48 ACI I gen/50 Hyalograft C	6.4 / 5.9	5	Comparative study
2009					
Gigante et al ¹⁸	MACI	12	4	3	Case series
Kon et al ⁵	Hyalograft C	40 Hyalograft C/40 MFX	2.2 / 2.5	5	Comparative study
Kreuz et al ³⁹	Bioseed C	19	4	4	Case series
Crawford et al ⁴³	Neocart	8	2.2	2	Case series
Gobbi et al ²⁷	Hyalograft C	34	4.4	5	Case series
Salzmann et al ¹⁷	MACI	9 OCT/9 MACI	2.3 / 6.3	41 mths/42 mths	Comparative study
Wondrasch et al ⁴⁶	Hyalograft C / CaReS	31	4.8	2	Case series
Nehrer et al ²⁹	Hyalograft C	42 arthroscopy/11 arthroscopy	4.4	2 to 7	Case series
Tohyama et al ⁵²	Atelocollagen	27	3.2	2	Case series
Vilchez et al ⁶³	Chondrograft	15	1.5 to 8	1	Prospective study
2010					
Della Villa et al ³³	Hyalograft C	31 athletes/34 non-athletes	2.2 / 2.3	57 mths/52 mths	Comparative study
Welsch et al ⁴⁵	Hyalograft C / CaReS	10 CaReS/10 Hyalograft C	4.6 / 4.9	2	Comparative study
Basad et al ¹⁹	MACI	33 MACI/15 MFX	> 4	2	Randomised study
Kim et al ⁵⁰	Chondron	30	5.8	2	Case series
Kon et al ³¹	Hyalograft C	50	2.5	5	Case series
Zeifang et al ⁴²	Bioseed C	11 Bioseed C/10 ACI I gen	4.3 / 4.1	2	Randomised study
Choi et al ⁴⁹	Chondron	40	5.2	Minimum 2	Case series
Clar et al ³⁴	Hyalograft C	1	14	5.5	Case report
Erggelet et al ⁴¹	Bioseed C	40 Bioseed C/42 ACI I gen	2 to 17.5 / 2 to 15	2	Comparative study
2011					
Ebert et al ²⁰	MACI	35	3.0	5	Case series
Macmull et al ⁶⁴	MACI	24 ACI/7 MACI	0.96 to 15.7	66.3 mths	Comparative study
Bauer et al ²²	MACI	18	6	5	Case series
Kon et al ³²	Hyalograft C	22 Hyalograft C/39 MACI	2.6 / 3.1	5.1/4.8	Comparative study
Kreuz et al ⁴⁰	Bioseed C	52	4.8	4	Case series
Enea et al ⁶⁵	MACI	30	5.0	15 mths	Case series
Schneider et al ⁴⁷	CaReS	116	5.4	12 to 60 mths	Case series
Filardo et al ³⁵	Hyalograft C	32	3	6	Case series
Filardo et al ³⁶	Hyalograft C	58	2.3	6	Case series
Kon et al ⁵³	Hyalograft C	21 Hyalograft C/20 MFX	2	7.5	Comparative study
Filardo et al ³⁷	Hyalograft C	62	2.5	7	Case series
2012					
Ventura et al ²³	MACI	53	4.3	27 mths (n = 53)/59 mths (n = 17)	Case series
Macmull et al ²¹	MACI	25 ACI/23 MACI	4.7	40 mths	Comparative study
Panagopoulos et al ⁴⁴	Novocart	11 ACI/8 MACI	6.5	37.5 mths	Comparative study
Könst et al ⁶⁶	Gel MACI	9	7.1	9 mths	Case series

* (M)ACI-C, (matrix) autologous chondrocyte implantation-collagen membrane; MFX, microfractures; CaReS, Cartilage Repair System (Ars Arthro Technology)

† RCT, randomised controlled trial

significant decline at five years. Finally, Ventura et al²³ documented good results in 53 patients at two years, confirmed by the 17 patients evaluated at five years of

follow-up, with improvements in function and pain and complete integration of the graft within the surrounding native cartilage in 15 patients (88%) at five years.

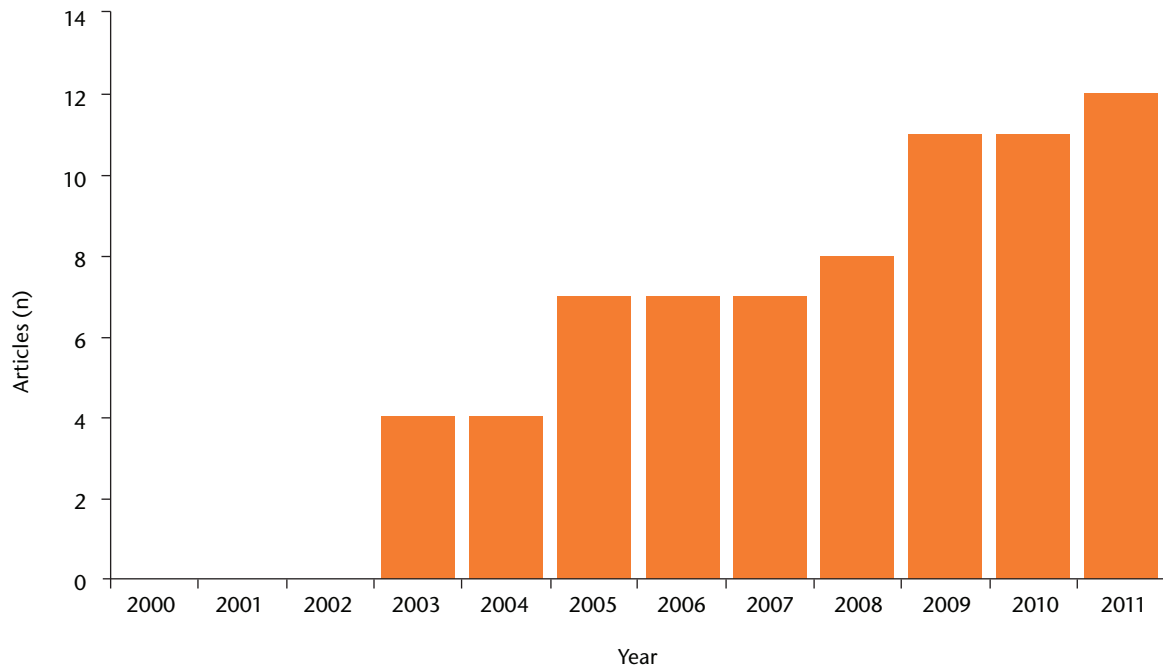


Fig. 1

Bar chart of the number of publications focusing on cartilage regeneration, showing the growing interest in the topic.

Hyalograft C. Hyaluronic acid, another widely represented cartilage matrix element, is the main component of Hyalograft C, introduced into clinical practice in 1999.⁶⁸ This scaffold is entirely based on the benzylic ester of hyaluronic acid (HYAFF 11; Fidia Advanced Biopolymers Laboratories, Padova, Italy) and consists of a network of 20 μm thick fibers with interstices of variable sizes. The features of this device allowed the development of an arthroscopic surgical technique,⁶⁸ and in 2005 Marcacci et al²⁴ reported the clinical results of a multicentre study on 141 patients evaluated at a minimum follow-up of two years. A mean three-year follow-up evaluation showed 129 patients (91.5%) had subjectively improved results, and cartilage repair was graded arthroscopically as normal or nearly normal in 53 of 55 knees (96.4%) that underwent second-look arthroscopy. Moreover, 12 of 22 second-look biopsies were judged as hyaline-like, and a low complication rate was recorded. In the same period, Nehrer et al²⁵ confirmed the good short-term results in a group of 36 patients followed for three years, and Gobbi et al²⁶ reported a positive outcome at two years in 32 patellofemoral full-thickness chondral defects. The same group of patients were described at five years,²⁷ showing a worsening with respect to the previous study, but still good clinical and histological results. A medium-term follow-up evaluation was also performed by Marcacci et al²⁸ and Nehrer et al²⁹ who confirmed the significant clinical improvement with stable results over time. Ferruzzi et al³⁰ treated 50 patients affected by osteochondritis dissecans (OCD)

and traumatic lesions, and showed stable clinical results at minimum five years' follow-up and a well-integrated cartilage tissue in 93% of the patients at the final MRI evaluation. Moreover, they also compared them with a group of patients treated with first-generation ACI and showed a similar healing potential but with fewer complications and a more rapid recovery when the arthroscopic MACT procedure was used.³⁰ Kon et al³¹ followed a group of patients clinically and with MRI for five years and reported durability of the good clinical results obtained and a correlation between imaging and clinical findings. These results were also confirmed in a demanding patient population of high-level soccer players evaluated at 7.5 years: whereas microfracture allowed a faster recovery but presented a clinical deterioration over time, arthroscopic Hyalograft C delayed the return to competition but offered more durable clinical results.³² Della Villa et al³³ focused on the post-operative phase by evaluating highly competitive athletes, and demonstrated that an intensive rehabilitation may safely allow a faster return to competition and also positively influences the clinical outcome at medium-term follow-up. Clar et al³⁴ reported the use of hyaluronic-based MACT as a salvage treatment for a 14 cm^2 defect in a 17.5-year-old girl, due to previous steroid-induced osteonecrosis: after treatment, formation of a solid cartilage layer was observed on MRI and a continuous clinical improvement registered up to 5.5 years. Kon et al⁶⁹ analysed and compared results obtained using arthroscopic Hyalograft C implantation or the mini-open MACI technique¹⁵ for the treatment of cartilage lesions in

61 patients > 40 years of age with no clear signs of osteoarthritis. Results were inferior compared with those previously found for younger populations, with a higher rate of failure, but a significant clinical improvement was still found at five years.⁶⁹ In fact, this group of patients also benefited in most cases from both cartilage regenerative procedures, with the only difference being a faster recovery when the arthroscopic approach was used. Finally, in 2011 Filardo et al³⁵⁻³⁷ confirmed the good results obtained with this scaffold up to seven years of follow-up, documenting overall good and stable results over time but a lower outcome in case of degenerative lesions.

Bioseed. Bioseed C (BioTissue Technologies GmbH, Freiburg, Germany) scaffold is composed of fibrin, polyglycolic/polylactic acid and polydioxanone. It is a tissue-engineered graft that combines autologous chondrocytes, embedded in fibrin, with a 2 mm thick porous gel-like matrix in a bioresorbable polymer scaffold, and has been applied in clinical practice since 2001.³⁸ This biomaterial can be implanted by open or arthroscopic procedure and presents a particular type of fixation: after careful debridement of the defective cartilage to a rectangular shape, the graft is fitted to the size of the defect and a strong fixation is obtained by arming the corners with resorbable threads, anchored transosseously to each corner, thus ensuring secure fixation of the graft even in defects without intact surrounding cartilage. Ossendorf et al³⁸ reported in 2007 clinical results at two years in a group of 40 patients affected by degenerative defects, and showed good integration of the graft, formation of a cartilaginous repair tissue and a significant clinical improvement even in the more challenging osteo-arthritic lesions. Kreuz et al³⁹ then confirmed the good results obtained in 19 patients of the same group analysed at four years, and a further evaluation of 52 patients also showed clinical improvement and moderate-to-complete filling at the MRI in the majority of the patients, even if a persisting strength deficit was found in the treated knee.⁴⁰

Finally, a similar significant improvement to that achieved with the original ACI periosteum-cover technique was found independently by Erggelet et al⁴¹ in a retrospective comparative study and by Zeifang et al⁴² in a randomised clinical trial.

More recently, among the many scaffolds developed, a few other biomaterials have been introduced into clinical practice with a minimum follow-up of two years.

Neocart. NeoCart (Histogenics Corporation, Waltham, Massachusetts) consists of a three-dimensional (3D) type I collagen scaffold seeded with autologous chondrocytes and then undergoing development in a bioreactor.⁴³ The resulting product is a viable proteoglycan- and glycosaminoglycan-rich tissue-like implant, which is surgically fixed to the damaged area with CT3 bioadhesive (Histogenics). Crawford et al⁴³ reported a good clinical outcome at two years of follow-up in eight patients, describing good implant integration, defect

fill, as well as progressive maturation and more organised cartilage formation.

Novocart. Novocart 3D (B. Braun-Tetec, Reutlingen, Germany) comprises autologous chondrocytes embedded in a 3D collagen-chondroitin sulfate scaffold. Results were recently reported by Panagopoulos, van Niekerk and Triantafillopoulos,⁴⁴ who evaluated a cohort of either professional soldiers or athletes with large defects after classic ACI with periosteal flap in 11 cases and Novocart 3D in eight cases. At a minimum of two years, despite the overall improvement, results obtained in this demanding cohort with complex lesions were poor, with only six patients (32%) returning to previous athletic performances. A trend toward better results for Novocart 3D was found in comparison with classic ACI, but without reaching statistical significance.

CaReS. CaReS (Ars Arthro, Esslingen, Germany) consists of autologous chondrocytes seeded on 3D type-I collagen gel. The cells are isolated, mixed with collagen, and after complete gelling and two weeks of culturing, the chondrocyte-loaded gel is available for transplantation. Welsch et al⁴⁵ evaluated two bioregenerative approaches: ten patients underwent CaReS implantation and were compared with ten patients treated with Hyalograft C, matched according to lesion size, site and age of patients. Although the clinical outcome at two years was comparable between the two groups, MRI analysis revealed better surface of the repair tissue in the CaReS group.⁴⁵ Wondrasch et al⁴⁶ applied CaReS or Hyalograft C in 31 patients, documenting an overall significant improvement at two years. The patients were randomised into either an accelerated or delayed weight-bearing protocol, which demonstrated that early weight-bearing was associated with a higher prevalence of bone marrow oedema after six months, but with no effect on clinical outcome.⁴⁶ More recently, Schneider et al⁴⁷ published the results of a multicentre study in which a wide population of 116 patients was evaluated at a follow-up from 12 to 60 months: overall good results were reported, with a continuous improvement towards best results at the last follow-up, regardless of lesion size, site and number of defects, whereas a greater improvement was documented in the OCD group.

Cartipatch. Cartipatch (TBF Tissue Engineering, Mions, France) is an autologous chondrocyte implant on a vegetal hydrogel composed of agarose and alginate. This hydrogel is mixed with isolated autologous cell suspension and can be modulated at 37°C into complex-shaped implants that solidify at approximately 25°C. Alginate provides matrix elasticity, making it easy to handle. Selmi et al⁴⁸ investigated the clinical, radiological, arthroscopic and histological outcome at a minimum follow-up of two years for the treatment of chondral and osteochondral defects. Clinically, all 17 patients improved markedly, especially those with lesions > 3 cm². Good MRI findings, arthroscopic

appearance and predominantly hyaline cartilage were found in eight of 13 biopsies performed (62%).

Chondron. Another gel-type autologous chondrocyte (Chondron; Sewon Cellontech Co. Ltd, Seoul, Korea) implantation has been used by Choi et al.⁴⁹ This procedure involves the injection of cultured chondrocytes mixed with fibrin (1:1) into the defect area previously prepared with debridement and multiple holes. In a multicentre study they evaluated 40 patients with follow-up > two years, showing the safety and effectiveness of this method. Fibrin gel can provide a 3D scaffold with the advantages of technical simplicity and minimal invasiveness. Kim et al⁵⁰ have also shown satisfactory results in 30 patients, with significant clinical improvements, good MRI findings and nearly normal arthroscopic appearance in most patients at two years.

Atelocollagen gel. Autologous chondrocytes cultured on atelocollagen gel have been also documented. Adachi et al⁵¹ first reported a complex case in which corticosteroid-induced osteonecrosis at both condyles of the knee was treated with hydroxyapatite with interconnected pores (IP-CHA) and atelocollagen gel (3% type I collagen; Koken, Tokyo, Japan) used as a scaffold for bone-marrow expanded cells and cultured chondrocytes, and to regenerate both osseous and chondral tissues, respectively. A synovial flap was sutured to cover the lesion and secure the osteochondral implants. Despite the unremarkable arthroscopic findings at a one-year follow-up, MRI and clinical results showed a successful outcome at two years. Tohyama et al⁵² conducted a multicentre study on 27 patients to determine the usefulness of the atelocollagen-associated chondrocyte implantation for the repair of chondral knee defects. The first-generation ACI periosteal flap technique was used to host and protect the chondrocyte-atelocollagen gel. Both clinical and arthroscopic outcomes were positive, with a marked improvement and 23 knees (92%) presented normal or nearly normal arthroscopic appearance.

Discussion

Research in bioengineering offers new technologies and new surgical treatment options for cartilage lesions. The use of 3D structures for cell growth has been shown to allow the maintenance of a chondrocyte differentiated phenotype⁷⁰ and to overcome most of the biological and surgical concerns raised by the first-generation methods.^{13,14,71} Thus, the interest in this scaffold-based cartilage regenerative approach is constantly growing, as shown by the increasing number of publications every year that focus on this topic (Fig. 1).

The rationale of using a scaffold is to have a 3D biodegradable structure for the *in vitro* growth of living cells and their subsequent implantation. An ideal scaffold should mimic the biology, architecture and structural properties of the native tissue, thus facilitating cell infiltration,

attachment, proliferation and differentiation. Other important properties include biocompatibility and biodegradability through safe biochemical pathways at suitable time intervals to support the first phases of tissue formation and then the gradual replacement by the regenerating tissue.

Following these principles, many scaffolds have been developed and, as reported in this systematic review, introduced in the clinical practice with promising results. As polymers can be designed to have a wide range of properties and are easily modified depending on the biological/surgical strategy, many more are being developed. Several other natural and synthetic scaffolds for cartilage regeneration are under investigation and will be available in clinical practice.^{13,14,71} In particular, hydrogels have recently been developed as an attractive evolution of cartilage tissue engineering. Another important source of innovation comes from photopolymerisation: liquid or gel scaffolds can be injected into the site of cartilage injury, thus requiring a less invasive procedure, and then polymerised by exposure to ultraviolet light. It is also possible to encapsulate cells within the gels, thus obtaining a scaffold with uniformly distributed cells, offering both surgical and biological potential advantages.⁴⁸

MACT was introduced into clinical practice in Europe between 1998 and 1999 and a considerable number of clinical studies have been published. However, since introduction into clinical practice is recent, it is difficult to have a long-term follow-up, and most of the papers report case series; up to now only ten non-randomised and three randomised controlled studies have been published, and the few comparative studies available are not conclusive.

Moreover, in the United States the Food and Drug Administration has not yet approved MACT, but different alternative solutions are being developed, avoiding manipulation of cells and regulatory obstacles. In fact, there is an increasing awareness that the role of scaffolds is not only to deliver cells to enhance tissue regeneration, and the use of cell-free scaffolds has been proposed and is gaining popularity. Some scaffolds may have a potential themselves to promote chondral or osteochondral regeneration by exploiting the self-regenerative potential of the body.^{53,72} One-step cell-free approaches have been developed to avoid the problems related to the *ex vivo* chondrocyte culture and expansion in a scaffold, with marked advantages both from the surgical and economic points of view.

In fact, an ideal graft would be an off-the-shelf product. The possibility of a cell-free implant that is 'smart' enough to provide the joint with the appropriate stimuli to induce orderly and durable tissue regeneration is an attractive prospect, and new biomaterials and surgical strategies have been recently proposed to induce *in situ* cartilage regeneration after direct transplantation onto the defect site.

Finally, the increasing awareness on the role of the subchondral bone has led to the development of some new biphasic products: the bilayer structure allows the entire osteochondral unit to be treated, which is important in

particular in cases of large chondral or osteochondral articular defects, reproducing the different biological and functional requirements for guiding the growth of both bone and cartilage tissues.^{53,73}

Promising results have been reported with all of these procedures,^{27,53,74,75} but the properties of the healthy cartilage tissue are still unmatched by any available substitute. Moreover, despite the thousands of patients treated and the published studies suggesting good clinical results, at the present time there is no agreement about the effective superiority of the regenerative approach over the others, and both results and indications remain controversial. One explanation of the contradictory and inconclusive findings in the literature might be that regenerative procedures may lead to a hyaline-like tissue through a remodeling process, thus leading to superior clinical results only detectable at two to three years of follow-up.⁷⁶ Unfortunately, due to the recent development of these techniques, only a few studies report medium to long-term results,^{13,14} and up to now only a few comparative trials have been performed. Thus, medium to long-term comparative studies are mandatory to confirm the positive findings reported and to determine the real potential of the bioengineered approach with respect to the more traditional and less ambitious procedures.

Conclusions. MACT procedures have been reported in the literature in the last decade with promising results, and the growing interest on this scaffold based regenerative approach is confirmed by the growing number of publications documented in this review. Different types of scaffolds have been applied in the clinical practice and shown a good outcome at short and medium-term follow-up, but well-designed studies are lacking. Systematic long-term evaluation of these techniques and randomised controlled studies are necessary to confirm the potential of this tissue-engineered approach, especially compared with the available traditional treatments.

References

1. Buckwalter JA, Mankin HJ. Articular cartilage. Part I: tissue design and chondrocyte-matrix interactions. *J Bone Joint Surg [Am]* 1997;79-A:600–611.
2. Buckwalter JA, Mankin HJ. Articular cartilage. Part II: degeneration and osteoarthritis, repair, regeneration, and transplantation. *J Bone Joint Surg [Am]* 1997;79-A:612–632.
3. Changoor A, Nelea M, Méthot S, et al. Structural characteristics of the collagen network in human normal, degraded and repair articular cartilages observed in polarized light and scanning electron microscopies. *Osteoarthritis Cartilage* 2011;19:1458–1468.
4. Nehrer S, Spector M, Minas T. Histologic analysis of tissue after failed cartilage repair procedures. *Clin Orthop Relat Res* 1999;365:149–162.
5. Kon E, Gobbi A, Filardo G, et al. Arthroscopic second-generation autologous chondrocyte implantation compared with microfracture for chondral lesions of the knee: prospective nonrandomized study at 5 years. *Am J Sports Med* 2009;37:33–41.
6. Marcacci M, Kon E, Delcogliano M, et al. Arthroscopic autologous osteochondral grafting for cartilage defects of the knee: prospective study results at a minimum 7-year follow-up. *Am J Sports Med* 2007;35:2014–2021.
7. Bugbee W, Cavallo M, Giannini S. Osteochondral allograft transplantation in the knee. *J Knee Surg* 2012;25:109–116.
8. Demange M, Gomoll AH. The use of osteochondral allografts in the management of cartilage defects. *Curr Rev Musculoskelet Med* 2012;53:229–235.
9. Gross AE, Shasha N, Aubin P. Long-term followup of the use of fresh osteochondral allografts for posttraumatic knee defects. *Clin Orthop Relat Res* 2005;435:79–87.
10. Brittberg M, Lindahl A, Nilsson A, et al. Treatment of deep cartilage defects in the knee with autologous chondrocyte transplantation. *N Engl J Med* 1994;331:889–895.
11. Vasiliadis HS, Danielson B, Ljungberg M, et al. Autologous chondrocyte implantation in cartilage lesions of the knee: long-term evaluation with magnetic resonance imaging and delayed gadolinium-enhanced magnetic resonance imaging technique. *Am J Sports Med* 2010;38:943–949.
12. Peterson L, Vasiliadis HS, Brittberg M, Lindahl A. Autologous chondrocyte implantation: a long-term follow-up. *Am J Sports Med* 2010;38:1117–1124.
13. Kon E, Verdonk P, Condello V, et al. Matrix-assisted autologous chondrocyte transplantation for the repair of cartilage defects of the knee: systematic clinical data review and study quality analysis. *Am J Sports Med* 2009;37(Suppl):156S–166S.
14. Kon E, Delcogliano M, Filardo G, Montaperto C, Marcacci M. Second generation issues in cartilage repair. *Sports Med Arthrosc* 2008;16:221–229.
15. Behrens P, Bitter T, Kurz B, Russlies M. Matrix-associated autologous chondrocyte transplantation/implantation (MATC/MACI): 5-year follow-up. *Knee* 2006;13:194–202.
16. Ronga M, Grassi FA, Manelli A, Bulgheroni P. Tissue engineering techniques for the treatment of a complex knee injury. *Arthroscopy* 2006;22:576–571.
17. Salzmann GM, Paul J, Bauer JS, et al. T2 assessment and clinical outcome following autologous matrix-assisted chondrocyte and osteochondral autograft transplantation. *Osteoarthritis Cartilage* 2009;17:1576–1582.
18. Gigante A, Enea D, Greco F, et al. Distal realignment and patellar autologous chondrocyte implantation: mid-term results in a selected population. *Knee Surg Sports Traumatol Arthrosc* 2009;17:2–10.
19. Basad E, Ishaque B, Bachmann G, Stürz H, Steinmeyer J. Matrix-induced autologous chondrocyte implantation versus microfracture in the treatment of cartilage defects of the knee: a 2-year randomised study. *Knee Surg Sports Traumatol Arthrosc* 2010;18:519–527.
20. Ebert JR, Robertson WB, Woodhouse J, et al. Clinical and magnetic resonance imaging-based outcomes to 5 years after matrix-induced autologous chondrocyte implantation to address articular cartilage defects in the knee. *Am J Sports Med* 2011;39:753–763.
21. Macmull S, Jaiswal PK, Bentley G, et al. The role of autologous chondrocyte implantation in the treatment of symptomatic chondromalacia patellae. *Int Orthop* 2012;Epub.
22. Bauer S, Khan RJ, Ebert JR, et al. Knee joint preservation with combined neutralising High Tibial Osteotomy (HTO) and Matrix-induced Autologous Chondrocyte Implantation (MACI) in younger patients with medial knee osteoarthritis: a case series with prospective clinical and MRI follow-up over 5 years. *Knee* 2011;Epub.
23. Ventura A, Memeo A, Borgo E, et al. Repair of osteochondral lesions in the knee by chondrocyte implantation using the MACI technique. *Knee Surg Sports Traumatol Arthrosc* 2012;20:121–126.
24. Marcacci M, Berruto M, Brocchetta D, et al. Articular cartilage engineering with Hyalograft C: 3-year clinical results. *Clin Orthop Relat Res* 2005;435:96–105.
25. Nehrer S, Domayer S, Dorotka R, et al. Three-year clinical outcome after chondrocyte transplantation using a hyaluronan matrix for cartilage repair. *Eur J Radiol* 2006;57:3–8.
26. Gobbi A, Kon E, Berruto M, et al. Patellofemoral full-thickness chondral defects treated with Hyalograft-C: a clinical, arthroscopic, and histologic review. *Am J Sports Med* 2006;34:1763–1773.
27. Gobbi A, Kon E, Berruto M, et al. Patellofemoral full-thickness chondral defects treated with second-generation autologous chondrocyte implantation: results at 5 years' follow-up. *Am J Sports Med* 2009;37:1083–1092.
28. Marcacci M, Kon E, Zaffagnini S, et al. Arthroscopic second generation autologous chondrocyte implantation. *Knee Surg Sports Traumatol Arthrosc* 2007;15:610–619.
29. Nehrer S, Dorotka R, Domayer S, Stelzener D, Kotz R. Treatment of full-thickness chondral defects with hyalograft C in the knee: a prospective clinical case series with 2 to 7 years' follow-up. *Am J Sports Med* 2009;37(Suppl 1):81S–87S.
30. Ferruzzi A, Buda R, Faldini C, et al. Autologous chondrocyte implantation in the knee joint: open compared with arthroscopic technique: comparison at a minimum follow-up of five years. *J Bone Joint Surg [Am]* 2008;90-A(Suppl 4):90–101.
31. Kon E, Di Martino A, Filardo G, et al. Second-generation autologous chondrocyte transplantation: MRI findings and clinical correlations at a minimum 5-year follow-up. *Eur J Radiol* 2011;79:382–388.
32. Kon E, Filardo G, Berruto M, et al. Articular cartilage treatment in high-level male soccer players: a prospective comparative study of arthroscopic second-generation autologous chondrocyte implantation versus microfracture. *Am J Sports Med* 2011;39:2549–2557.
33. Della Villa S, Kon E, Filardo G, et al. Does intensive rehabilitation permit early return to sport without compromising the clinical outcome after arthroscopic autologous chondrocyte implantation in highly competitive athletes? *Am J Sports Med* 2010;38:68–77.
34. Clar H, Pascher A, Kastner N, et al. Matrix-assisted autologous chondrocyte implantation into a 14cm(2) cartilage defect, caused by steroid-induced osteonecrosis. *Knee* 2010;17:255–257.

35. **Filardo G, Kon E, Berruto M, et al.** Arthroscopic second generation autologous chondrocytes implantation associated with bone grafting for the treatment of knee osteochondritis dissecans: results at 6 years. *Knee* 2011;Epub.
36. **Filardo G, Kon E, Di Martino A, et al.** Second-generation arthroscopic autologous chondrocyte implantation for the treatment of degenerative cartilage lesions. *Knee Surg Sports Traumatol Arthrosc* 2011;Epub.
37. **Filardo G, Kon E, Di Martino A, Iacono F, Marcacci M.** Arthroscopic second-generation autologous chondrocyte implantation: a prospective 7-year follow-up study. *Am J Sports Med* 2011;39:2153–2160.
38. **Ossendorf C, Kaps C, Kreuz PC, et al.** Treatment of posttraumatic and focal osteoarthritic cartilage defects of the knee with autologous polymer-based three-dimensional chondrocyte grafts: 2-year clinical results. *Arthritis Res Ther* 2007;9:R41.
39. **Kreuz PC, Müller S, Ossendorf C, Kaps C, Erggelet C.** Treatment of focal degenerative cartilage defects with polymer-based autologous chondrocyte grafts: four year clinical results. *Arthritis Res Ther* 2009;11:R33.
40. **Kreuz PC, Müller S, Freymann U, et al.** Repair of focal cartilage defects with scaffold-assisted autologous chondrocyte grafts: clinical and biomechanical results 48 months after transplantation. *Am J Sports Med* 2011;39:1697–1705.
41. **Erggelet C, Kreuz PC, Mrosek EH, et al.** Autologous chondrocyte implantation versus ACL using 3D-bioresorbable graft for the treatment of large full-thickness cartilage lesions of the knee. *Arch Orthop Trauma Surg* 2010;130:957–964.
42. **Zeifang F, Oberle D, Nierhoff C, et al.** Autologous chondrocyte implantation using the original periosteum-cover technique versus matrix-associated autologous chondrocyte implantation: a randomized clinical trial. *Am J Sports Med* 2010;38:924–933.
43. **Crawford DC, Heveran CM, Cannon WD Jr, Foo LF, Potter HG.** An autologous cartilage tissue implant NeoCart for treatment of grade III chondral injury to the distal femur: prospective clinical safety trial at 2 years. *Am J Sports Med* 2009;37:1334–1343.
44. **Panagopoulos A, van Niekerk L, Triantafillopoulos I.** Autologous chondrocyte implantation for knee cartilage injuries: moderate functional outcome and performance in patients with high-impact activities. *Orthopedics* 2012;35:6–14.
45. **Welsch GH, Mamisch TC, Zak L, et al.** Evaluation of cartilage repair tissue after matrix-associated autologous chondrocyte transplantation using a hyaluronic-based or a collagen-based scaffold with morphological MOCART scoring and biochemical T2 mapping: preliminary results. *Am J Sports Med* 2010;38:934–942.
46. **Wondrasch B, Zak L, Welsch GH, Marlovits S.** Effect of accelerated weightbearing after matrix-associated autologous chondrocyte implantation on the femoral condyle on radiographic and clinical outcome after 2 years: a prospective, randomized controlled pilot study. *Am J Sports Med* 2009;37(Suppl 1):88S–96S.
47. **Schneider U, Rackwitz L, Andereya S, et al.** A prospective multicenter study on the outcome of type I collagen hydrogel-based autologous chondrocyte implantation (CaReS) for the repair of articular cartilage defects in the knee. *Am J Sports Med* 2011;39:2558–2565.
48. **Selmi TA, Verdonk P, Chambat P, et al.** Autologous chondrocyte implantation in a novel alginate-agarose hydrogel: outcome at two years. *J Bone Joint Surg [Br]* 2008;90-B:597–604.
49. **Choi NY, Kim BW, Yeo WJ, et al.** Gel-type autologous chondrocyte (Chondron) implantation for treatment of articular cartilage defects of the knee. *BMC Musculoskelet Disord* 2010;11:103.
50. **Kim MK, Choi SW, Kim SR, Oh IS, Won MH.** Autologous chondrocyte implantation in the knee using fibrin. *Knee Surg Sports Traumatol Arthrosc* 2010;18:528–534.
51. **Adachi N, Ochi M, Deie M, Ishikawa M, Ito Y.** Osteonecrosis of the knee treated with a tissue-engineered cartilage and bone implant: a case report. *J Bone Joint Surg [Am]* 2007;89-A:2752–2757.
52. **Tohyama H, Yasuda K, Minami A, et al.** Atelocollagen-associated autologous chondrocyte implantation for the repair of chondral defects of the knee: a prospective multicenter clinical trial in Japan. *J Orthop Sci* 2009;14:579–588.
53. **Kon E, Delcogliano M, Filardo G, et al.** Novel nano-composite multilayered biomaterial for osteochondral regeneration: a pilot clinical trial. *Am J Sports Med* 2011;39:1180–1190.
54. **Marcacci M, Kon E, Zaffagnini S, et al.** New cell-based technologies in bone and cartilage tissue engineering. II. Cartilage regeneration. *Chir Organi Mov* 2003;88:42–47.
55. **Cherubino P, Grassi FA, Bulgheroni P, Ronga M.** Autologous chondrocyte implantation using a bilayer collagen membrane: a preliminary report. *J Orthop Surg (Hong Kong)* 2003;11:10–15.
56. **Pavesio A, Abatangelo G, Borriero A, et al.** Hyaluronan-based scaffolds (Hyalograft C) in the treatment of knee cartilage defects: preliminary clinical findings. *Novartis Found Symp* 2003;249:203–217.
57. **Ronga M, Grassi FA, Bulgheroni P.** Arthroscopic autologous chondrocyte implantation for the treatment of a chondral defect in the tibial plateau of the knee. *Arthroscopy* 2004;20:79–84.
58. **Marlovits S, Striessnig G, Kutscha-Lissberg F, et al.** Early postoperative adherence of matrix-induced autologous chondrocyte implantation for the treatment of full-thickness cartilage defects of the femoral condyle. *Knee Surg Sports Traumatol Arthrosc* 2005;13:451–457.
59. **Bartlett W, Gooding CR, Carrington RW, et al.** Autologous chondrocyte implantation at the knee using a bilayer collagen membrane with bone graft: a preliminary report. *J Bone Joint Surg [Br]* 2005;87-B:330–332.
60. **Bartlett W, Skinner JA, Gooding CR, et al.** Autologous chondrocyte implantation versus matrix-induced autologous chondrocyte implantation for osteochondral defects of the knee: a prospective, randomised study. *J Bone Joint Surg [Br]* 2005;87-B:640–645.
61. **Manfredini M, Zerbinati F, Gildone A, Faccini R.** Autologous chondrocyte implantation: a comparison between an open periosteal-covered and an arthroscopic matrix-guided technique. *Acta Orthop Belg* 2007;73:207–218.
62. **Ebert JR, Robertson WB, Lloyd DG, et al.** Traditional vs accelerated approaches to post-operative rehabilitation following matrix-induced autologous chondrocyte implantation (MACI): comparison of clinical, biomechanical and radiographic outcomes. *Osteoarthritis Cartilage* 2008;16:1131–1140.
63. **Vilchez F, Lara J, Alvarez-Lozano E, et al.** Knee chondral lesions treated with autologous chondrocyte transplantation in a tridimensional matrix: clinical evaluation at 1-year follow-up. *J Orthop Traumatol* 2009;10:173–177.
64. **Macmill S, Parratt MT, Bentley G, et al.** Autologous chondrocyte implantation in the adolescent knee. *Am J Sports Med* 2011;39:1723–1730.
65. **Enea D, Cecconi S, Busilacchi A, et al.** Matrix-induced autologous chondrocyte implantation (MACI) in the knee. *Knee Surg Sports Traumatol Arthrosc* 2012;20:862–869.
66. **Köst YE, Benink RJ, Veldstra R, et al.** Treatment of severe osteochondral defects of the knee by combined autologous bone grafting and autologous chondrocyte implantation using fibrin gel. *Knee Surg Sports Traumatol Arthrosc* 2012;20:2263–2269.
67. **Behrens P, Ehlers EM, Köchermann KU, et al.** New therapy procedure for localized cartilage defects: encouraging results with autologous chondrocyte implantation. *MMW Fortschr Med* 1999;141:49–51 (in German).
68. **Marcacci M, Zaffagnini S, Kon E, et al.** Arthroscopic autologous chondrocyte transplantation: technical note. *Knee Surg Sports Traumatol Arthrosc* 2002;10:154–159.
69. **Kon E, Filardo G, Condello V, et al.** Second-generation autologous chondrocyte implantation: results in patients older than 40 years. *Am J Sports Med* 2011;39:1668–1675.
70. **Grigolo B, Lisignoli G, Piacentini A, et al.** Evidence for redifferentiation of human chondrocytes grown on a hyaluronan-based biomaterial (HYAff 11): molecular, immunohistochemical and ultrastructural analysis. *Biomaterials* 2002;23:1187–1195.
71. **Sharma B, Elisseeff JH.** Engineering structurally organized cartilage and bone tissues. *Ann Biomed Eng* 2004;32:148–159.
72. **Gille J, Schuseil E, Wimmer J, et al.** Mid-term results of Autologous Matrix-Induced Chondrogenesis for treatment of focal cartilage defects in the knee. *Knee Surg Sports Traumatol Arthrosc* 2010;18:1456–1464.
73. **Carmont MR, Carey-Smith R, Saithna A, et al.** Delayed incorporation of a TruFit plug: perseverance is recommended. *Arthroscopy* 2009;25:810–814.
74. **Giannini S, Buda R, Vannini F, Cavallo M, Grigolo B.** One-step bone marrow-derived cell transplantation in talar osteochondral lesions. *Clin Orthop Relat Res* 2009;467:3307–3320.
75. **Kon E, Delcogliano M, Filardo G, et al.** A novel nano-composite multi-layered biomaterial for treatment of osteochondral lesions: technique note and an early stability pilot clinical trial. *Injury* 2010;41:693–701.
76. **Saris DB, Vanlauwe J, Victor J, et al.** Treatment of symptomatic cartilage defects of the knee: characterized chondrocyte implantation results in better clinical outcome at 36 months in a randomized trial compared to microfracture. *Am J Sports Med* 2009;37:10S–19S.

Funding statement:

- This research has been financed by the FIRB project: The efficacy of a new scaffold for osteochondral regeneration.

Author contributions:

- E. Kon: Writing the manuscript
- G. Filardo: Writing the manuscript
- B. Di Matteo: Literature research
- F. Perdisa: Literature research
- M. Marcacci: Senior consultant and editor of text

ICMJE Conflict of Interest:

- E. Kon is a consultant for CartiHeal Ltd, Tel Aviv, Israel.

©2013 British Editorial Society of Bone and Joint Surgery. This is an open-access article distributed under the terms of the Creative Commons Attribution licence, which permits unrestricted use, distribution, and reproduction in any medium, but not for commercial gain, provided the original author and source are credited.