

# Predictors of Spondylolysis on Magnetic Resonance Imaging in Adolescent Athletes With Low Back Pain

Takuji Yokoe,<sup>\*†</sup> MD, Takuya Tajima,<sup>†</sup> MD, PhD, Hiroshi Sugimura,<sup>‡</sup> MD, PhD, Shinichirou Kubo,<sup>§</sup> MD, PhD, Shotarou Nozaki,<sup>§</sup> MD, Nami Yamaguchi,<sup>†</sup> MD, PhD, Yudai Morita,<sup>†</sup> MD, and Etsuo Chosa,<sup>†</sup> MD, PhD

*Investigation performed at Miyazaki University Graduate School of Medicine, Miyazaki, Japan*

**Background:** Spondylolysis and undiagnosed mechanical low back pain (UMLBP) are the main causes of low back pain (LBP) in adolescent athletes. No studies have evaluated the difference in clinical and radiographic factors between these 2 conditions. Furthermore, it remains unclear which adolescent athletes with LBP should undergo advanced imaging examination for spondylolysis.

**Purpose:** To compare the clinical and radiographic factors of adolescent athletes with spondylolysis and UMLBP who did not have neurological symptoms or findings before magnetic resonance imaging (MRI) evaluation and to determine the predictors of spondylolysis findings on MRI.

**Study Design:** Cohort study, Level of evidence, 3.

**Methods:** The study population included 122 adolescent athletes aged 11 to 18 years who had LBP without neurological symptoms or findings and who underwent MRI. Of these participants, 75 were ultimately diagnosed with spondylolysis, and 47 were diagnosed with UMLBP. Clinical factors and the following radiographic parameters were compared between the 2 groups: spina bifida occulta, lumbar lordosis (LL) angle, and the ratio of the interfacet distance of L1 to that of L5 (L1:L5 ratio, %). A logistic regression analysis was performed to evaluate independent predictors of spondylolysis on MRI scans.

**Results:** Significantly more athletes with spondylolysis were male (82.7% vs 48.9%;  $P < .001$ ), had a greater LL angle ( $22.8^\circ \pm 8.1^\circ$  vs  $19.3^\circ \pm 8.5^\circ$ ;  $P = .02$ ), and had a higher L1:L5 ratio ( $67.4\% \pm 6.3\%$  vs  $63.4\% \pm 6.6\%$ ;  $P = .001$ ) versus athletes with UMLBP. A multivariate analysis revealed that male sex (odds ratio [OR], 4.66;  $P < .001$ ) and an L1:L5 ratio of  $>65\%$  (OR, 3.48;  $P = .003$ ) were independent predictors of positive findings of spondylolysis on MRI scans.

**Conclusion:** The study findings indicated that sex and the L1:L5 ratio are important indicators for whether to perform MRI as an advanced imaging examination for adolescent athletes with LBP who have no neurological symptoms and findings.

**Keywords:** adolescent athletes; spondylolysis; mechanical low back pain; magnetic resonance imaging

Low back pain (LBP) is a common symptom in adolescent athletes.<sup>13,18,28</sup> Undiagnosed mechanical low back pain (UMLBP), mechanical low back pain without an organic cause, spondylolysis, and discogenic back pain have been reported as the main causes of LBP in young athletes.<sup>18,27</sup> Micheli and Wood<sup>27</sup> reported that spondylolysis was the most common cause of diagnosable LBP, accounting for 47% of cases of LBP in young athletes. Discogenic back pain was less common in adolescent athletes compared with adults,<sup>27,28</sup> and discogenic back pain is not generally suspected in adolescent athletes without neurological symptoms or findings. Therefore, UMLBP and spondylolysis

would be 2 of the most common causes of LBP in adolescent athletes with LBP who do not have neurological symptoms or findings.

Some studies have proposed diagnostic algorithms for LBP to limit the number of imaging studies without missing the specific diagnoses.<sup>2,6,10</sup> Plain radiography is inexpensive and provides a low dose of radiation exposure to the patient. However, it is less sensitive and specific than are advanced imaging examinations.<sup>6,10</sup> Some authors discourage the routine use of 4 views (anteroposterior [AP], lateral, and right and left oblique) because this provides no superiority to 2 views (AP and lateral) and imposes a greater dose of radiation.<sup>3,13</sup> Therefore, when physical examination and plain radiography of the lumbar spine cannot identify organic causes of LBP, advanced imaging options, including computed tomography (CT), single photon emission

The Orthopaedic Journal of Sports Medicine, 9(4), 2325967121995466

DOI: 10.1177/2325967121995466

© The Author(s) 2021

This open-access article is published and distributed under the Creative Commons Attribution - NonCommercial - No Derivatives License (<https://creativecommons.org/licenses/by-nc-nd/4.0/>), which permits the noncommercial use, distribution, and reproduction of the article in any medium, provided the original author and source are credited. You may not alter, transform, or build upon this article without the permission of the Author(s). For article reuse guidelines, please visit SAGE's website at <http://www.sagepub.com/journals-permissions>.

computed tomography (SPECT), and magnetic resonance imaging (MRI), are considered. It has been demonstrated that MRI has high diagnostic performance for spondylolysis without radiation exposure and is useful for detecting early stage spondylolysis.<sup>9,32</sup> Short tau inversion recovery MRI is especially useful for the accurate diagnosis of spondylolysis in both adult and adolescent athletes.<sup>33,46,47</sup>

In cases of young athletes with LBP who have neurological symptoms and findings, clinicians usually perform MRI as an advanced imaging examination to detect the organic causes of LBP, such as lumbar herniation. However, in young athletes with LBP who do not have neurological symptoms and findings, clinicians may wonder whether to perform advanced imaging examinations because of the lack of a definitive algorithm for such examinations to evaluate LBP in young athletes.<sup>20,41</sup> To the best of our knowledge, no study has analyzed the predictors of findings of spondylolysis on MRI scans in adolescent athletes with LBP. It remains unclear which adolescent athletes with LBP should undergo MRI when clinicians suspect spondylolysis.

The purpose of this study was to evaluate (1) differences in clinical factors and radiographic findings between adolescent athletes with spondylolysis and UMLBP who presented with LBP without neurological findings and symptoms and (2) the predictors of findings of spondylolysis on MRI scans. We hypothesized that some radiographic parameters, such as the ratio of the interfacet distance of the L1 vertebra to that of the L5 vertebra (L1:L5 ratio), would be significant indicators of findings of spondylolysis when performing MRI for adolescent athletes with LBP.

## METHODS

This retrospective study was approved by our institutional review board, and all procedures were in accordance with the ethical standards of the responsible committee on human experimentation (institutional and national) and with the Declaration of Helsinki as revised in 2000. First, we reviewed the medical records of adolescent athletes (age, 11-18 years) who had LBP of undiagnosed origin and underwent MRI as advanced imaging to evaluate LBP in our hospital between January 1, 2017, and January 1, 2019. Thereafter, we identified adolescent athletes who did not have neurological symptoms and findings before they underwent MRI. Among those adolescent athletes who presented with LBP without neurological symptoms and

findings, those who were finally diagnosed with spondylolysis or UMLBP were retrospectively reviewed. Adolescent athletes with a previous history of spondylolysis were excluded from this study.

All included individuals had extension-related LBP on physical examination and undertook plain radiography of the lumbar spine in 4 views (AP, lateral, and right and left oblique). The participants stood upright with their arms folded across their chest while the radiographs were taken, and the radiographic beam was centered on the L3 vertebra.

When physical examination and plain radiography could not identify the organic causes of LBP, MRI was performed as an advanced imaging examination. Patients were diagnosed with spondylolysis when high-signal intensity lesions at the pars interarticularis were detected on short tau inversion recovery MRI scans.<sup>7,11</sup> Patients were diagnosed with UMLBP when the organic cause of LBP could not be identified after MRI scans. MRI scans were evaluated by an experienced radiologist (H.S.) who was a specialist in sports medicine and who was not involved in either the treatment of the included patients or the collection of medical records.

MRI was performed with the patients in the supine position with extended legs and without the use of general anesthesia or contrast enhancement. Participants were examined using a research-dedicated 1.5-T whole-body MRI scanner (Vantage; Canon Medical Systems) with a standard spine coil. T2-weighted fast spin echo scans were taken using spectral adiabatic inversion recovery fat suppression technique with an echo time of 60 milliseconds, a repetition time of 4000 to 6000 milliseconds, a flip angle of 90°, a slice thickness/gap of 4.0/0.8 mm, a field of view of 30 × 30 cm<sup>2</sup>, and a matrix size of 256 × 256.

Clinical factors and patient characteristics including sex, age, height, body mass index, type of sports activity, and interval from onset of LBP to MRI were evaluated by means of a chart review. Regarding radiographic indicators, several studies have reported that the presence of spina bifida occulta (SBO)<sup>21,36</sup> and a greater lumbar lordosis (LL) angle<sup>5,14</sup> are risk factors for the development of spondylolysis. It has also been reported that patients with spondylolysis have a smaller caudal increase in the lumbar transverse interfacet distance compared with healthy individuals.<sup>45,48</sup> Therefore, in the present study, radiographic findings included the presence of SBO, the LL angle, and the L1:L5 ratio.

The presence of SBO was evaluated on the AP view of the lumbar spine. The LL angle was measured using the Cobb

\*Address correspondence to Takuji Yokoe, MD, Division of Orthopaedic Surgery, Department of Medicine of Sensory and Motor Organs, Faculty of Medicine, University of Miyazaki, 5200 Kihara, Kiyotake, Miyazaki 889-1692, Japan (email: yokoetakuji@gmail.com).

†Division of Orthopaedic Surgery, Department of Medicine of Sensory and Motor Organs, Faculty of Medicine, University of Miyazaki, Kiyotake, Miyazaki, Japan.

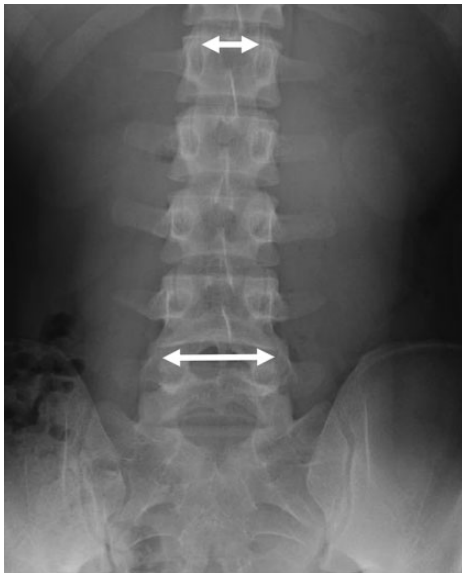
‡Department of Radiology, Nozaki Higashi Hospital, Murasumi, Miyazaki, Japan.

§Department of Orthopaedic Surgery, Nozaki Higashi Hospital, Murasumi, Miyazaki, Japan.

Final revision submitted October 10, 2020; accepted December 14, 2020.

The authors declared that there are no conflicts of interest in the authorship and publication of this contribution. AOSSM checks author disclosures against the Open Payments Database (OPD). AOSSM has not conducted an independent investigation on the OPD and disclaims any liability or responsibility relating thereto.

Ethical approval for this study was obtained from the University of Miyazaki (study No. 0-0624).



**Figure 1.** Measurement on anteroposterior radiograph of the ratio of the interfacet distance of the L1 vertebra (top arrows) to that of the L5 vertebra (bottom arrows) (L1:L5 ratio).

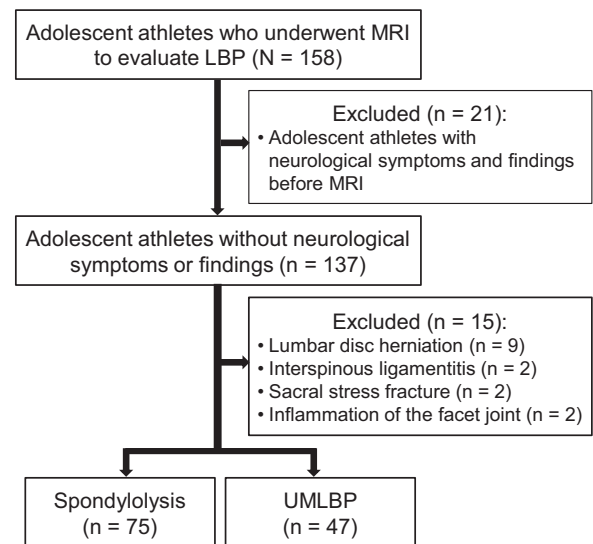
angle; the lordotic angle was measured between the inferior endplate of the L5 and the superior endplate of the L1 in the lateral view following the method of Polly et al.<sup>29</sup> The L1:L5 ratio (%) was evaluated as the interfacet distance of the L1 vertebra and that of the L5 vertebra as measured on AP radiograph<sup>45</sup> (Figure 1).

The LL angle and L1:L5 ratio were measured using a standard digital caliper (X viewer; Yokogawa). Radiographic findings were evaluated by 2 experienced orthopaedic surgeons (N.Y. and Y.M.) who were not involved in the treatment of the included patients or the collection of medical records. The mean value of the 2 examiners was accepted regarding the LL angle and the L1:L5 ratio. In the case of disagreement between the examiners regarding the presence of SBO, a third senior orthopaedic surgeon (T.Y.) resolved the discrepancy.

### Statistical Analysis

All statistical analyses were performed using SPSS software (Version 21.0; IBM Corp). The threshold of significance was set at  $P < .05$ . The Shapiro-Wilk method was used to test whether the data were normally distributed. To compare young athletes with spondylolysis and those with UMLBP, the chi-square test or Fisher exact test was carried out for categorical variables. Student *t* tests were performed for continuous variables when the data showed a normal distribution; otherwise the Mann-Whitney *U* test was performed. For selected variables with significance of  $P < .05$ , odds ratios and 95% CIs were calculated.

Intraclass correlation coefficients (ICCs) were calculated to assess the interrater reliability of the 3 radiographic parameters; the Cohen kappa coefficient ( $\kappa$ ) was calculated for the assessment of the presence of SBO. Intraclass



**Figure 2.** Flowchart of patient enrollment. LBP, low back pain; MRI, magnetic resonance imaging; UMLBP, undiagnosed mechanical low back pain.

correlation coefficients were rated according to Landis classification (slight, 0.0-0.20; fair, 0.21-0.40; moderate, 0.41-0.60; substantial, 0.61-0.80; almost perfect, 0.81-1.00).<sup>19</sup>

A univariate analysis was performed for each variable to determine which to include in the multivariate analysis. Evaluated variables included patient demographic factors and clinical factors: sex, age (<15 years, 15-18 years), type of sports activity, and interval from the onset of LBP to MRI (<2 weeks, 2-4 weeks, >4 weeks), as well as radiographic variables including the presence of SBO, LL angle (<20°, 20-25°, >25°), and L1:L5 ratio (<60%, 60-65%, >65%). A logistic regression analysis was performed to assess the effect of all potential predictors (statistically significant in the univariate analysis) on MRI findings of spondylolysis in the multivariate model. The sensitivity, specificity, positive predictive value (PPV), negative predictive value, positive likelihood ratio (+LR), and negative likelihood ratio (-LR) of the independent predictors were calculated.

### RESULTS

A total of 158 adolescent athletes who underwent MRI to evaluate LBP were identified; 137 of these patients did not have neurological findings and symptoms before MRI. Of the 137 adolescent athletes without neurological findings and symptoms, 15 were excluded because they were diagnosed with lumbar disc herniation (9), interspinous ligamentitis (2), sacral stress fracture (2), and inflammation of the lumbar facet joint (2); 75 were diagnosed with spondylolysis; and 47 were diagnosed with UMLBP on MRI scans and were enrolled in this study (Figure 2).

The characteristics of the study groups are shown in Table 1. The mean age of the patients with spondylolysis and UMLBP was  $15.1 \pm 1.8$  and  $14.9 \pm 1.7$  years, respectively ( $P = .59$ ). There was a statistically significant

TABLE 1  
Descriptive Data of the Enrolled Patients<sup>a</sup>

	Spondylolysis Group (n = 75)	UMLBP Group (n = 47)	P Value
Age, y	15.1 ± 1.8	14.9 ± 1.7	.59
Sex, n (%)			<b>&lt;.001</b>
Male	62 (82.7)	23 (48.9)	
Female	13 (17.3)	24 (51.1)	
Height, cm			
Male	166.4 ± 1.1	166.9 ± 1.3	.87
Female	156.7 ± 1.5	156.9 ± 1.2	.94
Body mass index			
Male	18.5 ± 0.8	18.7 ± 0.7	.79
Female	20.6 ± 1.2	20.4 ± 1.2	.76
Duration of LBP, wk	4.4 ± 4.3	3.6 ± 3.3	.28
Type of sport, n (%)			.18
Soccer	22 (29.3)	10 (21.3)	
Baseball	19 (25.3)	6 (12.8)	
Track and field	11 (14.7)	7 (14.9)	
Volleyball	5 (6.7)	6 (12.8)	
Tennis	0 (0)	4 (8.5)	
Rugby	3 (4)	1 (2.1)	
Basketball	3 (4)	1 (2.1)	
Weightlifting	3 (4)	0 (0)	
Badminton	0 (0)	5 (10.6)	
Gymnastics	1 (1.3)	0 (0)	
Other	8 (10.7)	7 (14.9)	

<sup>a</sup>Data are reported as mean ± SD unless otherwise indicated. Bolded *P* value indicates statistically significant difference between groups (*P* < .05). LBP, low back pain; UMLBP, undiagnosed mechanical low back pain.

difference in sex distribution between the groups, with male athletes accounting for 82.7% (62/75) of patients with spondylolysis and 48.9% (23/47) of patients with UMLBP (*P* < .001). No other significant differences were found between the groups.

### Radiographic Parameters

Table 2 shows the results of the comparison of radiographic parameters between the groups. A statistically significant difference was seen between the spondylolysis and UMLBP patients in mean LL angle overall (22.8° ± 8.1° vs 19.3° ± 8.5°, respectively; *P* = .02) and in male athletes (22.3° ± 8.3° vs 18.0° ± 6.6°; *P* = .02), although this was not the case in female athletes (25.0° ± 7.0° vs 20.4° ± 9.9°; *P* = .08). The mean L1:L5 ratio in athletes with spondylolysis was significantly greater than that in athletes with UMLBP both overall (67.4% ± 6.3% vs 63.4% ± 6.6%, respectively; *P* = .001) and when stratified by sex (male, 67.6% ± 6.0% vs 63.1% ± 6.4%, *P* = .003; female, 66.7% ± 6.5% vs 63.7% ± 6.9%, *P* = .01).

The interrater reliability of the measurements for the 3 radiographic parameters is shown in Table 3. Agreement among the 2 examiners was almost perfect in each case.

When the radiographic findings were stratified by sex, results indicated there were no statistically significant differences in any of the 3 parameters (Table 4).

TABLE 2  
Comparison of Radiographic Parameters Between Groups<sup>a</sup>

Variable	Spondylolysis Group	UMLBP Group	P Value
Spina bifida occulta, n (%)			
All	36/75 (48.0)	16/47 (34.0)	.09
Male	30/62 (48.4)	10/23 (43.5)	.81
Female	6/13 (46.2)	6/24 (25.0)	.27
Lumbar lordosis angle, deg			
All	22.8 ± 8.1	19.3 ± 8.5	<b>.02</b>
Male	22.3 ± 8.3	18.0 ± 6.6	<b>.02</b>
Female	25.0 ± 7.0	20.4 ± 9.9	.08
L1:L5 ratio, %			
All	67.4 ± 6.3	63.4 ± 6.6	<b>.001</b>
Male	67.6 ± 6.0	63.1 ± 6.4	<b>.003</b>
Female	66.7 ± 6.5	63.7 ± 6.9	<b>.01</b>

<sup>a</sup>Data are reported as n (%) or mean ± SD. Bolded *P* values indicate statistically significant difference between groups (*P* < .05). UMLBP, undiagnosed mechanical low back pain.

TABLE 3  
Interrater Reliability for the Radiographic Measurements

Variable	Intraclass Correlation Coefficient	Agreement
Spina bifida occulta	0.848 (κ)	Almost perfect
Lumbar lordosis angle	0.971 (95% CI, 0.959-0.98)	Almost perfect
L1:L5 ratio	0.994 (95% CI, 0.988-0.996)	Almost perfect

TABLE 4  
Comparison of the Radiographic Parameters Between Male and Female Participants<sup>a</sup>

Variable	Male	Female	P Value
Spina bifida occulta, n (%)			
Spondylolysis group	30/62 (48.4)	6/13 (46.2)	.88
UMLBP group	10/23 (43.5)	6/24 (25.0)	.23
All	40/85 (47.1)	12/37 (32.4)	.17
Lumbar lordosis angle, deg			
Spondylolysis group	22.3 ± 8.3	25.0 ± 7.0	.28
UMLBP group	18.0 ± 6.6	20.4 ± 9.9	.34
All	21.2 ± 8.1	22.1 ± 9.2	.60
L1:L5 ratio, %			
Spondylolysis group	67.6 ± 6.0	66.7 ± 6.5	.29
UMLBP group	63.1 ± 6.4	63.7 ± 6.9	.77
All	66.4 ± 6.4	64.4 ± 6.8	.12

<sup>a</sup>Data are reported as mean ± SD unless otherwise indicated. UMLBP, undiagnosed mechanical low back pain.

### Predictors of Findings of Spondylolysis on MRI Scans

The rate of positive findings of spondylolysis on MRI scans for each predicting factor is listed in Table 5. Of the

TABLE 5  
Predictors of Spondylolysis Findings on MRI Scans<sup>a</sup>

Variable	Rate of Positive Findings of Spondylolysis, %	OR (95% CI)	P Value
Sex			
Male	72.9	4.98 (2.19-11.29)	<.001
Female	35.1	0.20 (0.09-0.46)	<.001
Age			
<15 y	52.9	0.54 (0.26-1.13)	.13
15-18 y	67.6	1.86 (0.89-3.88)	.13
Duration of LBP			
<2 wk	51.6	0.58 (0.26-1.31)	.22
2-4 wk	41	0.28 (0.13-0.62)	.003
>4 wk	82.7	5.67 (2.43-13.20)	<.001
Sports activity			
Soccer	68.8	1.54 (0.66-3.57)	.41
Baseball	76	2.32 (0.87-6.13)	.11
Track and field	61.1	0.98 (0.36-2.66)	.97
Volleyball	45.5	0.49 (0.15-1.61)	.33
Spina bifida occulta			
Present	69.2	1.79 (0.85-3.78)	.14
Absent	55.7	0.56 (0.27-1.18)	.14
L1:L5 ratio			
<60%	33.3	0.24 (0.09-0.64)	.006
60%-65%	55.8	0.69 (0.33-1.47)	.44
>65%	75.9	3.35 (1.55-7.22)	.003
Lumbar lordosis angle			
<20°	55.4	0.62 (0.29-1.29)	.26
20°-25°	71.4	1.77 (0.72-4.34)	.27
>25°	63.2	1.11 (0.51-2.43)	.84

<sup>a</sup>Bolded P values indicate statistical significance (P < .05). LBP, low back pain; MRI, magnetic resonance imaging; OR, odds ratio.

TABLE 6  
Multivariate Analysis of the Predictors of Spondylolysis Findings on MRI Scans<sup>a</sup>

Variable	B	SE	OR	95% CI	P Value
Male sex	1.538	0.441	4.657	1.964-11.045	<.001
L1:L5 ratio >65%	1.247	0.421	3.480	1.525-7.939	.003

<sup>a</sup>Bolded P values indicate statistical significance (P < .05). B, regression coefficient; MRI, magnetic resonance imaging; OR, odds ratio.

predictive factors analyzed using the chi-square test, a significantly increased probability was detected for LBP >4 weeks (odds ratio [OR], 5.67), male sex (OR, 4.98), and L1:L5 ratio >65% (OR, 3.35). In contrast, a significantly decreased probability was detected for female sex (OR, 0.20), L1:L5 ratio <60% (OR, 0.24), and LBP 2-4 weeks (OR, 0.28). In the multivariate regression analysis, male sex (OR, 4.66) and L1:L5 ratio >65% (OR, 3.48) were identified as statistically significant independent predictors (Table 6).

Table 7 shows the sensitivity, specificity, PPV, negative predictive value, and LR values of male sex, L1:L5 ratio >65%, and the 2 factors combined for spondylolysis on MRI scans. For male adolescent athletes with LBP who had an L1:L5 ratio of >65%, we noted 52% sensitivity, 84.4% specificity, 84.8% PPV, and 3.34 times the likelihood of a positive finding of spondylolysis on MRI scans.

## DISCUSSION

The results of the present study demonstrated that male sex and an L1:L5 ratio of >65% were independent predictors of positive findings of spondylolysis on MRI scans in adolescent athletes who had extension-related LBP without neurological symptoms and findings. To the best of our knowledge, this was the first study comparing differences in clinical factors and radiographic parameters between adolescent athletes with spondylolysis and UMLBP. The present study was also the first to evaluate predictors of findings of spondylolysis on MRI scans.

LBP is a common symptom in young athletes, and clinicians usually perform physical examinations and plain radiography of the lumbar spine as an initial examination. However, there is no decisive protocol regarding advanced imaging examinations, according to the results of systematic reviews.<sup>20,41</sup> Some studies have recommended using MRI as an advanced imaging modality for children and adolescents with LBP because MRI entails no exposure to radiation.<sup>9,32</sup> However, MRI is expensive, and it would not be appropriate for all young athletes with LBP to undergo MRI. The present study showed that patient sex and the L1:L5 ratio are useful indicators when clinicians are deciding whether to perform MRI, especially in cases of suspected spondylolysis. However, this was a preliminary study, and we could not identify the definitive criteria to indicate whether to perform MRI in the

TABLE 7  
Validity of Male Sex, L1/L5 Ratio >65%, and the 2 Factors Combined<sup>a</sup>

	Sensitivity, %	Specificity, %	PPV, %	NPV, %	+LR	-LR
Male sex	82.7 (76.2-88.3)	51.1 (40.7-60.0)	72.9 (67.2-77.9)	64.9 (51.7-76.2)	1.69 (1.28-2.21)	0.34 (0.20-0.59)
L1:L5 ratio >65%	61.3 (54.5-67.3)	68.9 (57.4-78.8)	76.7 (68.1-84.1)	51.7 (43.1-59.1)	1.97 (1.28-3.17)	0.56 (0.42-0.79)
Male sex and L1:L5 ratio >65%	52 (45.6-56.4)	84.4 (73.8-91.8)	84.8 (74.4-92.0)	51.4 (44.9-55.8)	3.34 (1.75-6.89)	0.57 (0.48-0.74)

<sup>a</sup>Values in parentheses are 95% CIs. -LR, negative likelihood ratio; +LR, positive likelihood ratio; NPV, negative predictive value; PPV, positive predictive value.

assessment of LBP in adolescent athletes. The previous studies describing the L1:L5 ratio have been too limited to determine a clear cutoff value for adolescent athletes or healthy individuals. Further studies are needed to detect clinically valuable predictors of spondylolysis on advanced imaging examinations and to evaluate the effectiveness of these predictors in avoiding excessive use of MRI.

Ward et al<sup>45</sup> and Zehnder et al<sup>48</sup> reported that an insufficient caudal increase in lumbar interfacet spacing was associated with the occurrence of spondylolysis based on the results of the comparison of AP lumbar spine radiographs between individuals with spondylolysis and healthy controls. Other studies have demonstrated that patients with spondylolysis had narrower and more frontally oriented lumbar facets in comparison with healthy controls.<sup>22,23</sup> Masharawi et al<sup>24</sup> found that the lumbar facet shape reached maturity earlier in girls (mean age, 12-13 years) than in boys (mean age, 15-16 years) based on MRI findings in the general population.<sup>24</sup> In the current study, male athletes with spondylolysis had a significantly greater L1:L5 ratio than those with UMLBP ( $P = .003$ ), and this difference was greater than was the difference between female athletes with spondylolysis and those with UMLBP ( $P = .01$ ).

A possible explanation for these findings is that excessive sports activities during puberty may prevent the normal growth of lumbar facet joints, which would result in an insufficient caudal increase in the lumbar interfacet distance, especially in boys. According to Zehnder et al,<sup>48</sup> the mean L1:L5 ratio in healthy controls (age, 6-18 years) was 52.7%. This value is smaller than is that found in the present study, indicating the validity of our hypothesis. Further studies are needed to compare differences in the development of lumbar facet joints between adolescent athletes and nonathletes to evaluate this hypothesis. As far as we know, no studies have compared the interfacet distances of the lumbar spine between young athletes with and without spondylolysis. The current study showed that there was a significant difference in L1:L5 ratio between young athletes with and without spondylolysis. Therefore, calculation of the L1:L5 ratio is recommended before deciding whether to perform MRI for adolescent athletes with LBP.

The presence of SBO and a greater LL angle were recognized as risk factors for the development of spondylolysis.<sup>5,14,21,36</sup> The present study showed that athletes with spondylolysis had a higher prevalence of SBO and greater LL angle compared with athletes who had UMLBP; however, neither the presence of SBO nor a greater LL angle could independently predict findings of spondylolysis on MRI scans. Urrutia et al<sup>43</sup> reported that spondylolysis did not develop more frequently in pediatric patients with SBO than in patients without SBO. It was also reported that the prevalence of SBO decreased from 41.2% in children to 7.7% in adults, which suggested that the closure of the vertebral arch may not be completed in a large percentage of children.<sup>44</sup> Measurement of the LL angle is a static assessment that does not reflect the direct flexibility of the lumbar spine. The LL angle is also influenced by individual factors, including age, weight, activity, and flexibility of the lower extremities.<sup>4,21,36</sup> Further studies should be undertaken to

evaluate whether the presence of SBO and the LL angle are associated with the development of spondylolysis, especially in high-risk populations such as adolescent athletes.

In the current study, male sex was an independent predictor of positive findings of spondylolysis on MRI scans. Furthermore, female sex was a negative predictor of findings of spondylolysis on MRI scans. According to a recent systematic review, male patients developed spondylolysis more frequently than did female patients,<sup>40</sup> which is compatible with our results. Several studies have reported that the incidence of lumbar spondylolysis differed according to ethnicity and sex.<sup>12,26,30</sup> Sakai et al<sup>35</sup> reported that the male-to-female ratio in patients with spondylolysis was 2:1, based on the results of a review of the CT scans of 2000 participants aged 20 to 90 years. Masharawi et al<sup>24</sup> reported that girls had a wider interfacet width relative to the vertebral body in comparison with boys, which implies a better posterior mechanical structure against repetitive sagittal stresses because of the relatively larger area where the spinal load is located. It was also reported that bone mineral density values at the lumbar spine were significantly higher in girls than in boys, based on the results obtained from 363 healthy children aged 10 to 17 years.<sup>1</sup>

These anatomic and biological differences may contribute to the higher incidence of spondylolysis in boys than in girls. In addition to intrinsic factors, extrinsic factors such as differences in sports type and activity level between boys and girls would have a critical influence on the development of spondylolysis. However, most studies have reported on the incidence of spondylolysis in the general population, and few studies have reported the correlation between sex and the incidence of spondylolysis in adolescent athletes. The present study evaluated only Japanese adolescent athletes; therefore, the results of this study cannot be generalized to athletes of other ethnicities. However, Stracciolini et al<sup>39</sup> reported that spondylolysis accounted for 50% of spine injuries in young male athletes compared with 33.9% of young female athletes with spine injuries in the United States. Clinicians should consider not only the characteristics of ethnicity in terms of the development of spondylolysis in their own countries but also the referral patterns specific to their own hospitals because these factors may affect the incidence of spondylolysis in adolescent athletes.<sup>39</sup> Future studies will be required to evaluate the correlation between sex and the incidence of spondylolysis in adolescent athletes all over the world from various viewpoints, including biomechanical, hormonal, anatomic, behavioral, and sex differences.

Soccer, baseball, track and field, and volleyball accounted for the majority of sports activities (70%; 86/122) in this study population. No significant predictive factors were identified in the type of sports activity. It has been described that throwing sports, gymnastics, and rowing were risk factors for spondylolysis in Spanish elite athletes,<sup>38</sup> although only 1 gymnast with spondylolysis was identified in the present study. The prevalence of spondylolysis in gymnasts was reported to be 16.6% by Rossi and Dragoni<sup>31</sup> and 14.0% by Soler and Calderón.<sup>38</sup> However, Komaya et al<sup>16</sup> reported that only 1 of 104 young gymnasts had spondylolysis. It has also been reported that the

prevalence of spondylolysis in gymnasts was 6.5%, with no difference in the general population in Canada.<sup>42</sup> These results may suggest that the real prevalence of spondylolysis in gymnasts was overestimated in previous studies.

Sakai et al<sup>34</sup> reported that Japanese professional soccer and baseball players had >5 times the incidence of spondylolysis in comparison with the general population. Selhorst et al<sup>37</sup> reported that the risk of spondylolysis differed by sex and geographic region and that the activity level of athletes may significantly influence the incidence of spondylolysis. Therefore, the activity level of the athletes and the strength and frequency of their training would be more important than would the type of sports activity when clinicians evaluate adolescent athletes with LBP.

The present study was a retrospective study, and we could not accurately assess the activity level of the athletes or the details of their training programs. The present study evaluated only 4 sports activities (soccer, baseball, track and field, and volleyball) because of the limited sample size and could not assess all types of sports activities as predictors of spondylolysis. Prospective studies will be needed to clarify the types of sports activity or activity levels of athletes that strongly affect the incidence of spondylolysis.

This study had several limitations. First, adolescent athletes who were diagnosed with pathologies other than spondylolysis and UMLBP after the MRI examination (15/137; 10.9%) were excluded from this study in order to compare patients with spondylolysis and UMLBP. Lumbar disk herniation, interspinous ligamentitis, sacral stress fracture, and inflammation of the facet joints are not common causes of LBP in young athletes; however, they should be regarded as differential diagnoses in clinical practice. It has been reported that radicular symptoms and neurological findings, such as a straight-leg raising test, are not present in most children and adolescents with lumbar disk herniation.<sup>8,17</sup> Therefore, the results of the present study should be interpreted with caution because the significant predictors in this study would be valuable when spondylolysis is suspected as a cause of LBP in adolescent athletes. Clinicians should carefully observe young athletes with atypical and persistent LBP and consider performing advanced imaging examinations if needed.

Second, data regarding physical examinations, such as tightness of the hamstrings and hip range of motion, were not evaluated because these data were not accurately collected from the medical records due to the retrospective study design. However, Kobayashi et al<sup>15</sup> reported that no significant physical examination factors that could be useful in the early detection of active spondylolysis were identified.

Third, CT and SPECT were not performed as advanced imaging examinations. Some authors have reported that MRI is not as sensitive for detecting spondylolysis as is a SPECT bone scan<sup>25,49</sup>; however, it has been confirmed that MRI has a high diagnostic performance in detecting pars defects in young athletes.<sup>9,15,32</sup> MRI would be a preferable advanced imaging examination for young athletes because of the lack of exposure to ionizing radiation.

Despite these limitations, the present study provides important information for the clinician when deciding

whether to perform MRI to evaluate the cause of LBP in adolescent athletes.

## CONCLUSION

Male sex, greater LL angle, and increased L1:L5 ratio were the significant variables differentiating adolescent athletes with spondylolysis from those with UMLBP. In addition, male sex and L1:L5 ratio >65% were independent predictors of positive findings of spondylolysis on MRI scans. Study results indicated that sex and L1:L5 ratio are useful indicators when clinicians are deciding whether to perform MRI to evaluate the cause of LBP in adolescent athletes without neurological symptoms and findings.

## ACKNOWLEDGMENT

The authors thank Koki Ouchi, PhD, for his statistical advice.

## REFERENCES

1. Arabi A, Nabulsi M, Maalouf J, et al. Bone mineral density by age, gender, pubertal stages, and socioeconomic status in healthy Lebanese children and adolescents. *Bone*. 2004;35(5):1169-1179.
2. Auerbach JD, Ahn J, Zgonis MH, Reddy SC, Ecker ML, Flynn JM. Streamlining the evaluation of low back pain in children. *Clin Orthop Relat Res*. 2008;466(8):1971-1977.
3. Beck NA, Miller R, Baldwin K, et al. Do oblique views add value in the diagnosis of spondylolysis in adolescents? *J Bone Joint Surg Am*. 2013;95(10):e65.
4. Been E, Kalichman L. Lumbar lordosis. *Spine J*. 2014;14(1):87-97.
5. Been E, Li L, Hunter DJ, Kalichman L. Geometry of the vertebral bodies and the intervertebral discs in lumbar segments adjacent to spondylolysis and spondylolisthesis: pilot study. *Eur Spine J*. 2011;20(7):1159-1165.
6. Bhatia NN, Chow G, Timon SJ, Walts HG. Diagnostic modalities for the evaluation of pediatric back pain: a prospective study. *J Pediatr Orthop*. 2008;28(2):230-233.
7. Cheung KK, Dhawan RT, Wilson LF, Peirce NS, Rajeswaran G. Pars interarticularis injury in elite athletes—the role of imaging in diagnosis and management. *Eur J Radiol*. 2018;108:28-42.
8. Dang L, Chen Z, Liu X, et al. Lumbar disk herniation in children and adolescents: the significance of configurations of the lumbar spine. *Neurosurgery*. 2015;77(6):954-959.
9. Dhouib A, Tabard-Fougere A, Hanquinet S, Dayer R. Diagnostic accuracy of MR imaging for direct visualization of lumbar pars defect in children and young adults: a systematic review and meta-analysis. *Eur Spine J*. 2018;27(5):1058-1066.
10. Feldman DS, Straight JJ, Badra MI, Mohaideen A, Madan SS. Evaluation of an algorithmic approach to pediatric back pain. *J Pediatr Orthop*. 2006;26(3):353-357.
11. Ganiyusufoglu AK, Onat L, Karatoprak O, Enercan M, Hamzaoglu A. Diagnostic accuracy of magnetic resonance imaging versus computed tomography in stress fractures of the lumbar spine. *Clin Radiol*. 2010;65(11):902-907.
12. Gunness-Hey M. The Koniag Eskimo presacral vertebral column: variations, anomalies and pathologies. *OSSA*. 1980;7:99-118.
13. Gurd DP. Back pain in the young athlete. *Sports Med Arthrosc Rev*. 2011;19(1):7-16.
14. Jacobsen S, Sonne-Holm S, Røvsing H, Monrad H, Gebuhr P. Degenerative lumbar spondylolisthesis: an epidemiological perspective. The Copenhagen Osteoarthritis Study. *Spine*. 2007;32(1):120-125.

15. Kobayashi A, Kobayashi T, Kato K, Higuchi H, Takagishi K. Diagnosis of radiographically occult lumbar spondylolysis in young athletes by magnetic resonance imaging. *Am J Sports Med.* 2013;41(1):169-176.
16. Koyama K, Nakazato K, Min S, et al. Radiological abnormalities and low back pain in gymnasts. *Int J Sports Med.* 2013;34(3):218-222.
17. Kraft DE. Low back pain in the adolescent athlete. *Pediatr Clin North Am.* 2002;49(3):643-653.
18. Kujala UM, Taimela S, Erkkintalo M, Salminen JJ, Kaprio J. Low-back pain in adolescent athletes. *Med Sci Sports Exerc.* 1996;28(2):165-170.
19. Landis JR, Koch GG. The measurement of observer agreement for categorical data. *Biometrics.* 1977;33(1):159-174.
20. Ledonio CG, Burton DC, Crawford CH III, et al. Current evidence regarding diagnostic imaging methods for pediatric lumbar spondylolysis: a report from the Scoliosis Research Society evidence-based medicine committee. *Spine Deform.* 2017;5(2):97-101.
21. Lonstein JE. Spondylolisthesis in children: cause, natural history, and management. *Spine.* 1999;24(24):2640-2648.
22. Masharawi YM, Alperovitch-Najenson D, Steinberg N, et al. Lumbar facet orientation in spondylolysis: a skeletal study. *Spine.* 2007;32(6):e176-e180.
23. Masharawi YM, Dar G, Peleg S, et al. Lumbar facet anatomy changes in spondylolysis: a comparative skeletal study. *Eur Spine J.* 2007;16(7):993-999.
24. Masharawi YM, Kjaer P, Bendix T, et al. Lumbar facet and interfacet shape variation during growth in children from the general population: a three-year follow-up MRI study. *Spine.* 2009;34(4):408-412.
25. Masci L, Pike J, Malara F, Phillips B, Bennell K, Brukner P. Use of the one-legged hyperextension test and magnetic resonance imaging in the diagnosis of active spondylolysis. *Br J Sports Med.* 2006;40(11):940-946.
26. Merbs CF. Patterns of activity-induced pathology in a Canadian Inuit population. *Archaeol Surv Canada.* 1983;119:120-128.
27. Micheli LJ, Wood R. Back pain in young athletes: significant differences from adults in causes and patterns. *Arch Pediatr Med.* 1995;149(1):15-18.
28. Müller J, Müller S, Stoll J, Fröhlich K, Otto C, Mayer F. Back pain prevalence in adolescent athletes. *Scand J Med Sci Sports.* 2017;27(4):448-454.
29. Polly DW, Kilkelly FX, McHale KA, Asplund LM. Measurement of lumbar lordosis. *Spine.* 1996;21(13):1530-1535.
30. Roche MB, Rowe GG. The incidence of separate neural arch and coincident bone variations; a survey of 4,200 skeletons. *Anat Rec.* 1951;109(2):233-252.
31. Rossi F, Dragoni S. The prevalence of spondylolysis and spondylolisthesis in symptomatic elite athletes: radiographic findings. *Radiography.* 2001;7(1):37-42.
32. Rush JK, Astur N, Scott S, Kelly DM, Sawyer JR, Warner WC Jr. Use of magnetic resonance imaging in the evaluation of spondylolysis. *J Pediatr Orthop.* 2015;35(3):271-275.
33. Sairyo K, Sakai T, Mase Y, et al. Painful lumbar spondylolysis among pediatric sports players: a pilot MRI study. *Arch Orthop Trauma Surg.* 2011;131(11):1485-1489.
34. Sakai T, Sairyo K, Suzue N, Kosaka H, Yasui N. Incidence and etiology of lumbar spondylolysis: review of the literature. *J Orthop Sci.* 2010;15(3):281-288.
35. Sakai T, Sairyo K, Takao S, Nishitani H, Yasui N. Incidence of lumbar spondylolysis in the general population in Japan based on multidetector computed tomography scans from two thousand subjects. *Spine.* 2009;34(21):2346-2350.
36. Seitsalo S, Osterman K, Hyvärinen H, Tallroth K, Schlenzka D, Poussa M. Progression of spondylolisthesis in children and adolescents: a long-term follow-up of 272 patients. *Spine.* 1991;16(4):417-421.
37. Selhorst M, Fischer A, MacDonald J. Prevalence of spondylolysis in symptomatic adolescent athletes: an assessment of sport risk in non-elite athletes. *Clin J Sport Med.* 2019;29(5):421-425.
38. Soler T, Calderón C. The prevalence of spondylolysis in the Spanish elite athlete. *Am J Sports Med.* 2000;28(1):57-62.
39. Straccioli A, Casciano R, Levey Friedman H, et al. Pediatric sports injuries: a comparison of males versus females. *Am J Sports Med.* 2014;42(4):965-972.
40. Tawfik S, Phan K, Mobbs RJ, Rao PJ. The incidence of pars interarticularis defects in athletes. *Global Spine J.* 2020;10(1):89-101.
41. Tofte JN, CarlLee TL, Holte AJ, Sitton SE, Weinstein SL. Imaging pediatric spondylolysis: a systematic review. *Spine.* 2017;42(10):777-782.
42. Toueg CW, Mac-Thiong JM, Grimard G, et al. Prevalence of spondylolisthesis in a population of gymnasts. *Stud Health Technol Inform.* 2010;158:132-137.
43. Urrutia J, Cuellar J, Zamora T. Spondylolysis and spina bifida occulta in pediatric patients: prevalence study using computed tomography as a screening method. *Eur Spine J.* 2016;25(2):590-595.
44. Urrutia J, Zamora T, Cuellar J. Does the prevalence of spondylolysis and spina bifida occulta observed in pediatric patients remain stable in adults? *Clin Spine Surg.* 2017;30(8):e1117-e1121.
45. Ward CV, Latimer B, Alander DH, et al. Radiographic assessment of lumbar facet distance spacing and spondylolysis. *Spine.* 2007;32(2):e85-e88.
46. Yamashita K, Sakai T, Takata Y, et al. Low back pain in adolescent athletes: comparison of diagnoses made by general orthopaedic surgeons and spine surgeons. *Int J Spine Surg.* 2019;13(2):178-185.
47. Yamashita K, Sugiura K, Manabe H, et al. Accurate diagnosis of low back pain in adult elite athletes. *J Med Invest.* 2019;66(3.4):252-257.
48. Zehnder SW, Ward CV, Crow AJ, Alander D, Latimer B. Radiographic assessment of lumbar facet distance spacing and pediatric spondylolysis. *Spine.* 2009;34(3):285-290.
49. Zetaruk M. Lumbar spine injuries. In: Micheli LJ, Purcell LK, eds. *The Adolescent Athlete.* Springer; 2007:109-140.