

CLINICAL TECHNIQUES AND TECHNOLOGY

# The GOCCLES® medical device is effective in detecting oral cancer and dysplasia in dental clinical setting. Results from a multicentre clinical trial

*Il dispositivo medico GOCCLES® è in grado di individuare displasie e cancro orale se impiegato nel setting odontoiatrico. Risultati da uno studio multicentrico*

A. MORO<sup>1,2</sup>, C. DE WAURE<sup>3</sup>, F. DI NARDO<sup>3</sup>, F. SPADARI<sup>4</sup>, M.D. MIGNOGNA<sup>5</sup>, M. GIULIANI<sup>6</sup>, L. CALIFANO<sup>7</sup>, A.B. GIANNI<sup>8</sup>, L. CARDARELLI<sup>1</sup>, A. CELENTANO<sup>5</sup>, G. BOMBECCARI<sup>4</sup>, S. PELO<sup>2</sup>

<sup>1</sup> Unit of Maxillofacial Surgery, Nuovo Ospedale San Giovanni Battista, Foligno, Italy; <sup>2</sup> Unit of Maxillofacial Surgery, Policlinico Gemelli, C.I. Columbus, Università Cattolica del Sacro Cuore, Rome, Italy; <sup>3</sup> Institute of Public Health, Università Cattolica del Sacro Cuore, Rome, Italy; <sup>4</sup> Department of Reconstructive and Diagnostic Surgical Sciences, Unit of Oral Pathology and Medicine, Fondazione IRCCS Ca' Granda Ospedale Maggiore Policlinico, University of Milan, Italy; <sup>5</sup> Department of Integrated Activities Head-Neck, Unit of Oral Medicine, Università di Napoli Federico II, Naples, Italy; <sup>6</sup> Department of Dentistry, Università Cattolica del Sacro Cuore, Rome, Italy; <sup>7</sup> Department of Integrated Activities Head-Neck, Unit of Maxillofacial Surgery, Università di Napoli Federico II, Naples, Italy; <sup>8</sup> Department of Reconstructive and Diagnostic Surgical Sciences, Complex Unit of Maxillofacial Surgery, Fondazione IRCCS Ca' Granda Ospedale Maggiore Policlinico, University of Milan, Italy

## SUMMARY

The purpose of this study is to demonstrate that the GOCCLES® medical device allows proper autofluorescence examination of the oral mucosa in a dental care setting. This is a non-randomised multicentre clinical trial on consecutive patients at risk for oral cancer. Patients underwent a classical naked eye inspection of the oral cavity followed by autofluorescence examination wearing the GOCCLES® spectacles while the light from a dental curing light irradiated the oral mucosa. Lesions were defined as visible potentially malignant lesions and/or fluorescence loss areas. All persisting lesions underwent excisional or incisional biopsy. Sixty-one patients were enrolled. Data from 64 biopsies were analysed. Of the 62 lesions identified by the device, 31 were true positives. The device identified 31 of 32 true positive lesions. One lesion (an invasive carcinoma) was not visible to the naked eye. The device identified all lesions classified as moderate dysplasia to invasive cancer. In 56.7% of cases, true positive lesions showed greater extension when observed through the device. The GOCCLES® medical device allowed the direct visualisation of fluorescence loss in patients suffering from mild to severe dysplasia and in situ to invasive oral cancer. It allowed autofluorescence examination with each source of light used during the study. These results suggest that the role of the autofluorescence visualisation is that of a complementary inspection following naked eye examination when dealing with patients at risk for oral cancer. The device allows detection of otherwise invisible lesions and otherwise impossible complete resections.

KEY WORDS: Oral cancer • Early Detection of Cancer • Dentistry • Fluorescence • Curing Lights • Dental

## RIASSUNTO

Scopo di questo studio è dimostrare che il dispositivo medico GOCCLES® permette di condurre l'esame dell'autofluorescenza del cavo orale nel setting odontoiatrico. Si tratta di uno studio multicentrico non randomizzato su pazienti consecutivi a rischio di cancro orale. I pazienti sono stati sottoposti ad ispezione del cavo orale ad occhio nudo seguita dall'esame dell'autofluorescenza condotto indossando gli occhiali GOCCLES® mentre una lampada fotopolimerizzante illuminava la mucosa orale. Le lesioni sono state definite come qualunque lesione precancerosa del cavo orale visibile ad occhio nudo o area di perdita di fluorescenza visibile con GOCCLES®. Tutte le lesioni persistenti sono state sottoposte a biopsia escissionale o incisionale. Sono stati reclutati 61 pazienti e analizzati i dati da 64 lesioni. Delle 62 lesioni identificate dal dispositivo, 31 erano veramente positive. Il dispositivo ha identificato 31 delle 32 lesioni veramente positive. Una lesione (un carcinoma invasivo) non era visibile ad occhio nudo. Tutte le lesioni classificate come displasia tra moderata e severa e ogni carcinoma sono stati correttamente identificati dal dispositivo. Nel 56,7% delle lesioni identificate dal dispositivo mostrava margini più ampi rispetto a quelli visibili ad occhio nudo. Il dispositivo medico GOCCLES® permette di osservare il fenomeno della perdita di fluorescenza in pazienti affetti da displasia o cancro del cavo orale. Ha permesso di effettuare l'esame dell'autofluorescenza con ciascuna lampada fotopolimerizzante testata. I risultati suggeriscono di impiegare GOCCLES® come esame complementare rispetto all'ispezione ad occhio nudo del cavo orale su pazienti a rischio per cancro orale. Il dispositivo permette di identificare lesioni altrimenti visibili o i cui margini sono sottostimati dall'ispezione ad occhio nudo.

PAROLE CHIAVE: Cancro orale • Diagnosi precoce del cancro • Odontoiatria • Fluorescenza • Lampade fotopolimerizzanti

## Introduction

No oral cancer screening test on large populations is currently recommended for oral cancer. However, studies on low-cost oral cancer diagnostic techniques are currently ongoing <sup>1</sup>. The autofluorescence examination is among these techniques.

Autofluorescence of the oral mucosa consists of a dim light coming from oxidised flavin adenine dinucleotide (FAD) and other fluorophores when excited by blue-violet and ultra-violet (UV) light <sup>2</sup>. Healthy tissues produce a 515 nm (green) light. Conversely, tissues with disorders of cell metabolism (such as dysplastic mucosa) appear as dark spots on a green background <sup>2</sup>. The disruption of the extracellular matrix, hyperemia and neo-angiogenesis also contribute to reduce fluorescence emission <sup>2</sup>.

Persistent areas of decreased fluorescence can therefore be a sign of dysplasia or cancer and should be treated accordingly. Today, it is commonly accepted that potentially malignant lesions of the oral cavity must be treated if they persist for more than 2 weeks, and many researchers are trying to find a role for autofluorescence not only in the early detection, but also in the complete surgical resection of cancerous or pre-cancerous lesions <sup>3</sup>.

The GOCCLLES<sup>®</sup> (Glasses for Oral Cancer – Curing Light Exposed – Screening) medical device was created in order to provide comfortable, easy and low cost direct visualisation of abnormalities of the oral cavity tissue fluorescence.

This device has already been tested in a clinical trial, with promising results <sup>4</sup>. However, that study suffered from several limitations, and was a pilot study on just 32 patients. Two-thirds of enrolled patients were in follow-up after the surgical resection of an oral cancer, and therefore at high risk of showing dysplastic tissues at histological examination regardless of the results of autofluorescence examination because of disease relapse or incomplete resection. Moreover, during this trial only a prototype of the device was studied, and it was tested with only one dental curing light (an Elipar 2500 3M ESPE). Furthermore, the study was conducted only by the research team responsible for the creation of the device, with obvious conflicts of interest.

In order to demonstrate the capability of the GOCCLLES<sup>®</sup> medical device to allow proper autofluorescence examination of the oral mucosa, which is the aim of this multicentre trial, it is therefore necessary to involve more patients, multiple research groups and curing lights, and to test the final model of the device.

## Materials and methods

The GOCCLLES<sup>®</sup> device (Pierrel S.p.A, Italy) consists of a pair of glasses equipped with filters (Fig. 1) that highlight



**Fig. 1.** The GOCCLLES (Glasses for Oral Cancer – Curing Light Exposed – Screening) medical device.

autofluorescence when the oral mucosa is illuminated by the light emitted by any dental curing light.

The device was studied in a non-randomised multicentre clinical trial in which eligible consecutive patients underwent oral examination with GOCCLLES<sup>®</sup>.

Subjects above the age of 17 years were eligible for the study if showing potentially malignant lesions of the oral mucosa or if they were in follow-up after surgical resection for oral cancer. Patients who underwent radiotherapy for oral or head and neck cancer in the previous three months were excluded from the study.

All eligible subjects were informed in detail on the study protocol and participants joined the study voluntarily after signing an informed consent form. All eligible subjects showing lesions at naked eye oral inspection or on autofluorescence analysis were asked to participate in the study. For ethical reasons, subjects with totally negative naked eye and autofluorescence examinations did not undergo biopsy of the oral mucosa and were excluded.

Enrollment took place at the following six Centers: Unit of Maxillofacial Surgery, C.I. Columbus, Università Cattolica del Sacro Cuore (Rome); Department of Reconstructive and Diagnostic Surgical Sciences, Unit of Oral Pathology and Medicine and Complex Unit of Maxillofacial Surgery, Fondazione IRCCS Ca' Granda Ospedale Maggiore Policlinico, University of Milan (Milan); Department of Integrated Activities Head-Neck, Unit of Maxillofacial Surgery and Unit of Oral Medicine, Università di Napoli Federico II (Naples); Unit of Maxillofacial Surgery, Nuovo Ospedale San Giovanni Battista (Foligno). Enrollment lasted one year and started in September 2013.

Patients underwent a naked eye classical inspection of the oral cavity followed by the autofluorescence examination wearing the GOCCLLES<sup>®</sup> medical device while the light from a dental curing light irradiated the oral mucosa. All examinations were performed by skilled physicians and surgeons with patients lying in a dental chair in a setting similar to that of the dental practice. All operators were asked to hold the light at 20-40 cm

distance from the oral mucosa and to direct the light perpendicularly to the inspected area. The naked eye inspection and the autofluorescence examination had to be performed by the same operator. All fluorescence loss areas were regarded as potentially malignant lesions of the oral mucosa. The following dental curing lights were used during the study: Elipar S10 3M ESPE (used by the Units of Milan); Led.B Carlo de Giorgi (Units of Rome and Foligno); Optilux 501 Kerr Corporation (Units of Naples). After examinations, all lesions persisting for at least two weeks (detected by at least one between the naked eye inspection and the autofluorescence examination) underwent excisional biopsy. If the excisional biopsy was not feasible, patients underwent incisional biopsy. All biopsies were properly oriented and showed the margins detected by both examinations. If an incisional biopsy including both identified margins was not feasible, two incisional biopsies of the same lesion on different margins were allowed. Different incisional biopsies of the same lesion were considered as a single biopsy. All biopsies underwent histological examination. No blinding on pathologist assessment or data analysts was planned.

For each lesion the following data were recorded: if visible to the naked eye and/or on autofluorescence analysis; which examination showed the greater extension if results were non-overlapping; which margins identified by the two techniques were infiltrated; the histological report. True positive lesions were defined as any dysplasia or cancer of the oral cavity. False positive lesions included negative histological findings and any other disorder of the oral mucosa not related to cancer.

Primary outcomes of the study were: proportion of visible lesions; proportion of infiltrated margins; proportion of true positive, false positive and false negative lesions. Given the study design, it was not possible to assess true negative lesions (no proper follow-up was planned).

The study protocol was approved by the respective ethics committees of the Institutions involved in the study.

*Statistical analysis*

Differences in terms of diagnostic performance between the autofluorescence analysis and naked eye inspection of the oral mucosa were assessed using the two-tailed McNemar test. Data analysis was performed with the IBM SPSS 22 Statistics Software for Windows. Statistical significance was set at  $p = 0.05$ .

Sample size calculation was based on the results of the previous study <sup>4</sup>. Assuming that the examination of autofluorescence showed larger margins compared to the naked eye in 25% of the lesions and that the opposite occurs in about 5% of cases, a sample of 100 patients was set in order to observe a significant difference between the two examinations with a probability of 95% (accepting a probability of type I error of 5%).

An interim analysis was planned at one year. After analysis of the first results the study was discontinued given the low probability of achieving more conclusive results with the preset sample of 100 patients.

**Results**

Sixty-one patients were enrolled and all underwent both naked eye inspection and autofluorescence examination of oral cavity mucosa. Data from all 61 patients entered the analysis. Main characteristics of the patients are summarised in Table I.

Autofluorescence of the oral mucosa was analysed using a Led.B curing light on 29 patients (47.6% of the sample), an Elipar S10 on 21 patients (34.4%) and an Optilux 501 on 11 patients (18.0%).

Naked eye inspection of the oral cavity detected 60 suspect lesions, while autofluorescence examination with the GOCCLLES® device detected 62 suspect lesions. A total of 65 lesions were detected: in 59 cases (90.8% of observed suspected lesions) they were visible to both naked eye and autofluorescence, while 2 suspected lesions (3.1%) were only visible during the naked eye inspection and 4 (6.2%) were only visible on the autofluorescence examination. No significant differences in terms of detected suspect lesions were observed between the naked eye inspection

**Table I.** Main demographic and clinical characteristics of the patients enrolled in the GOCCLLES study, by center

		Rome	Milan	Naples	Foligno	TOTAL
Patients [N]		14	21	11	15	61
Age [mean, (SD)]		67 (14)	66 (16)	66 (13)	63 (11)	66 (14)
Gender [N, (%)]	Female	8 (57.1)	15 (71.4)	8 (72.7)	7 (46.7)	39 (63.9)
Group [N, (%)]	A*	11 (78.6)	16 (76.2)	11 (100)	14 (93.3)	52 (85.2)
	B†	3 (21.4)	5 (23.8)	0 (0)	1 (6.7)	9 (14.8)
Biopsies/patient [N, (%)]	1	14 (100)	21 (100)	10 (90.9)	13 (86.6)	58 (95.1)
	2	0 (0)	0 (0)	1 (9.1)	1 (6.7)	2 (3.3)
	3	0 (0)	0 (0)	0 (0)	1 (6.7)	1 (1.6)

\* Patients suffering from suspected dysplastic lesions of the oral mucosa.

† Patients in follow-up after surgical resection of oral cancer.

**Table II.** Autofluorescence examination.

Lesion description	Detected by naked eye inspection only	Detected by both techniques	Detected by AF examination only	TOTAL*
False positive <sup>†</sup> [N (%)]	1 (3.1)	28 (87.5)	3 (9.4)	32 (50.0)
True positive [N (%)]	1 (3.1)	30 (93.8)	1 (3.1)	32 (50.0)
<b>Of which:</b>				
Mild dysplasia [N (%)]	1 (9.1)	10 (90.9)	0 (0)	11 (17.2)
Moderate dysplasia [N (%)]	0 (0)	4 (100)	0 (0)	4 (6.3)
Severe dysplasia [N (%)]	0 (0)	3 (100)	0 (0)	3 (4.7)
Carcinoma in situ [N (%)]	0 (0)	2 (100)	0 (0)	2 (3.1)
Invasive cancer [N (%)]	0 (0)	11 (91.7)	1 (8.3)	12 (18.8)
TOTAL [N (%)]	2 (3.1)	58 (90.6)	4 (6.3)	64 (100)

\*The percentages under the "total" column relate to the whole sample. <sup>†</sup>Includes other non-precancerous and non-cancerous disorders of the oral mucosa. Definitive diagnoses are based on histological findings. No patients were negative for both naked eye and autofluorescence analysis because no subject with totally negative physical examination underwent biopsy of the oral mucosa.

and autofluorescence examination of oral mucosa (McNemar test  $p = 0.687$ ).

Sixty-five biopsies of the oral mucosa were thus taken. Fifty-eight patients underwent one oral mucosa biopsy, while two underwent two biopsies and another patient underwent three biopsies because of multiple lesions. An invalid sample was excluded from statistical analyses and data from 64 of 65 biopsies (98.5% of all biopsies) were analysed. Thirty-two of 64 samples (50.0% of the valid samples) were classified as false positives. Of the 32 truly positive samples, 11 (17.2% of the valid samples) were classified as mild dysplasia, 4 (6.3%) as moderate dysplasia, 3 (4.7%) as severe dysplasia, 2 (3.1%) as carcinoma in situ and 12 (18.8%) as invasive cancer.

Of the 60 suspected lesions detected by naked eye inspection of the oral cavity, 31 were true positive lesions (51.6%), while of the 62 lesions identified on autofluorescence examination, 31 (50.0%) were true positives. In particular, autofluorescence examination identified all the lesions classified as moderate to severe dysplasia and all lesions classified as cancer. Main results of the study are summarised in Table II. Both techniques identified 31 of 32 (96.9%) actual lesions. One lesion (a carcinoma) was not visible to the naked eye, while one lesion (a mild dysplasia) was not visible on the autofluorescence examination. No significant differences in terms of diagnostic

performance were observed between the two techniques (McNemar test  $p = 1.000$ ).

Thirty true positive lesions were visible by both classical inspection and autofluorescence analysis. In 17 cases (56.7% of the 30 true positive lesions), extension of the lesion detected on the autofluorescence examination was greater than that observed at naked eye inspection, while in two cases (6.7%) the margins overlapped and in nine cases (30.0%) autofluorescence examination showed a smaller lesion. In two cases (6.7%), the operator was unsure whether the margins were overlapping or not.

The resection margins identified during the naked eye inspection were infiltrated in 21 cases (67.7% of the 31 lesions identified). Of the 31 true positive lesions identified by autofluorescence examination, 24 (77.4%) showed infiltrated margins. No significant differences were observed between the two techniques in terms of free resection margins (McNemar test  $p = 0.754$ , see Tab. III).

No statistically significant differences were observed in the performance of the autofluorescence test using different curing lights (Tab. IV).

## Discussion

The GOCCLES<sup>®</sup> medical device allowed visualisation of fluorescence loss in patients suffering from mild to severe dysplasia and oral cancer (Fig. 2). The device worked

**Table III.** Proportions of free and infiltrated margins of the lesions identified during naked eye inspection of the oral cavity and on autofluorescence examination.

	Not visible to AF	AF margins not infiltrated	AF margins infiltrated	TOTAL
Not visible to the NE	-	0 (0%)	1 (3.1%)	1 (3.1%)
NE margins not infiltrated	1 (3.1%)	3 (9.4%)	6 (18.8%)	10 (31.3%)
NE margins infiltrated	0 (0%)	4 (12.5%)	17 (53.1%)	21 (65.6%)
TOTAL	1 (3.1%)	7 (21.9%)	24 (75.0%)	32 (100%)

NE: naked eye inspection; AF: auto fluorescence examination.

No patients showed lesions invisible to both techniques because no subject with totally negative physical examination underwent the biopsy of the oral mucosa.



**Table IV.** Comparison of the performance of the GOCCLÉS device with different curing lights.

	Auto fluorescence examination results				Lesion margin detection		
	TP lesion	FP lesion	Not detected	p value*	Free margins	Infiltrated margins	p value*
Led.B [N (%)]	15 (46.9)	16 (50.0)	1 (3.1)	0.488	4 (26.7)	11 (73.3)	0.174
Elipar S10 [N (%)]	8 (38.1)	13 (61.9)	0 (0)		0 (0)	8 (100)	
Optilux 501 [N (%)]	8 (72.7)	3 (27.3)	0 (0)		3 (37.5)	5 (62.5)	

TP: true positive; FP: false positive. \* Chi square test.

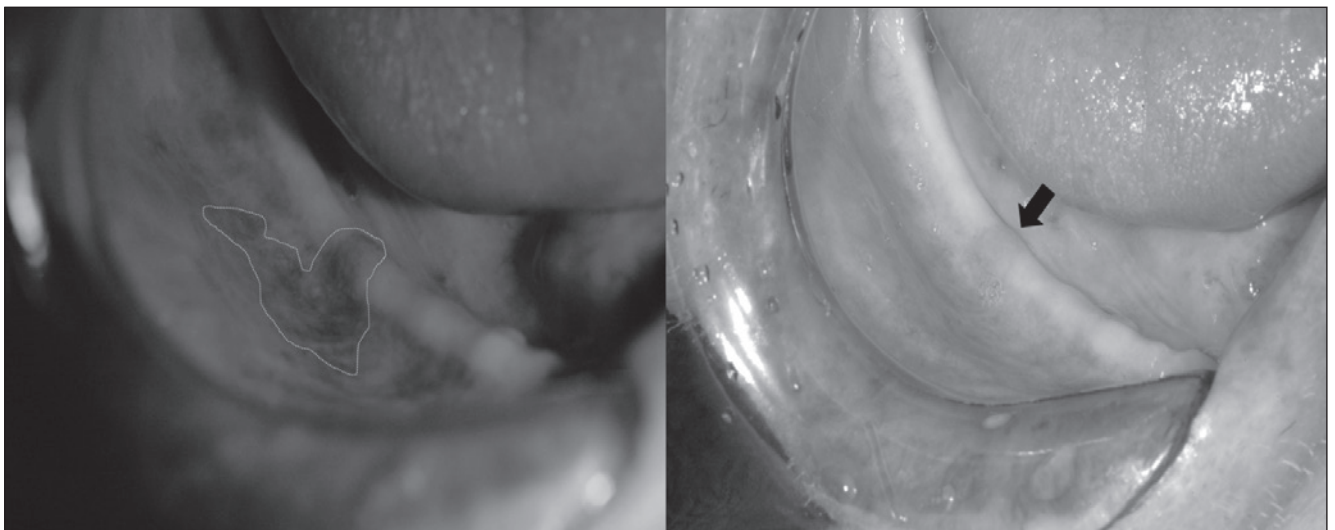
properly with each source of light used in this study, which have different technical characteristics reproducing the variety of available dental curing lights. The Led.B is a LED lamp with a wavelength of 440-490 nm and an intensity of 1,000-1,200 mW/cm<sup>2</sup>; the Elipar S10 LED lamp has a 430-480 nm wavelength and an intensity of 1,000 mW/cm<sup>2</sup>; the Optilux 501 is a halogen lamp with a wavelength of 400-505 nm and an intensity of 850-1,000 mW/cm<sup>2</sup>. The GOCCLÉS® device was also previously successfully tested with another halogen lamp with different characteristics (400-500 nm wavelength and 600 mW/cm<sup>2</sup> intensity).

The study was performed with patients lying in dental chairs in order to reproduce the settings of common dental practice. The intended purpose of the device was to allow any dentist equipped with a curing light to perform low-cost autofluorescence examination. According to the scientific literature, autofluorescence examination shows otherwise invisible characteristics of the oral mucosa that are associated with oral cancer<sup>2,4</sup>. However, the current evidence suggests that the role of the autofluorescence

examination is that of a complementary inspection following the naked eye examination, which should not be replaced by any screening test. Moreover, given the high risk of false positive findings (50% in this study), it is recommended that every dentist equipped with the device is properly trained before using it and that only patients at risk for oral cancer or showing potentially malignant lesions undergo examination with GOCCLÉS®. Remarkably, however, in one case GOCCLÉS® allowed the detection of an otherwise invisible lesion, and in four cases it allowed otherwise impossible complete resections of lesions with infiltrated margins.

We hope that the availability of additional low cost screening techniques encourages more careful and more frequent inspections of the oral cavity among dentists, and further promotes a much needed culture of oral cancer prevention: naked eye inspection of the oral cavity alone could, in fact, save about 37,000 lives worldwide each year<sup>5</sup>.

Furthermore, data on its diagnostic performance are lacking because of the small sample size and study de-



**Fig. 2.** Oral cancer in an edentulous patient in follow-up after surgical resection of a malignant lesion. Autofluorescence examination (on the left) vs. conventional visual examination (on the right). The lesion is barely visible if the oral examination is performed with superficiality. Loss of fluorescence increased contrast making it easier to see the tumour. Also visible in this figure is a clear difference in the extension of the margins of the lesion: fluorescence loss extended beyond the margins, which were visible to the naked eye. The arrow points to the main lesion. The margins of the lesion (as visible on the autofluorescence examination) are also highlighted.

sign (it was impossible to assess the proportion of false negatives in this study as no follow-up of negative patients was planned). Further studies on much larger samples (possibly randomised clinical trials comparing the device with other techniques) are needed to define its diagnostic performance. The previous pilot study (in which patients underwent a follow-up of one year) showed 100% sensitivity, 95% specificity, 93% positive predictive value and 100% negative predictive value. However, the device was studied on patients at very high risk, and most had a history of oral cancer. It is likely that the diagnostic performance is heavily affected by the population tested, being poorer in the general population and improving greatly when dealing (as appropriate) with subjects at risk.

#### *Conflict of interests*

This study was funded by Pierrel S.p.A., owner of the rights on the GOCCLLES medical device. Three research-

ers involved in this study (SP, AM, FDN) have royalty percentages on the sales of the device.

#### **References**

- <sup>1</sup> Petersen PE. *Oral cancer prevention and control--the approach of the World Health Organization*. *Oral Oncol* 2009;45:454-60.
- <sup>2</sup> Monici M. *Cell and tissue autofluorescence research and diagnostic applications*. *Biotechnol Annu Rev* 2005;11:227-56.
- <sup>3</sup> Succo G, Garofalo P, Fantini M, et al. *Direct autofluorescence during CO2 laser surgery of the larynx: can it really help the surgeon?* *Acta Otorhinolaryngol Ital* 2014;34:174-83
- <sup>4</sup> Moro A, Di Nardo F, Boniello R et al. *Autofluorescence and early detection of mucosal lesions in patients at risk for oral cancer*. *J Craniofac Surg* 2010;21:1899-903.
- <sup>5</sup> Sankaranarayanan R, Ramadas K, Thomas G, et al. *Effect of screening on oral cancer mortality in Kerala, India: a cluster-randomised controlled trial*. *Lancet* 2005;365:1927-33.

Received: September 1, 2015 - Accepted: October 1, 2015