

Available online at www.sciencedirect.com

ScienceDirect

journal homepage: www.elsevier.com/locate/radcr

Case report

Is there a role for ^{18}F -FDG PET-CT in Familial Mediterranean fever? A case report and overview of the literature ☆,☆☆,★,★★

A. Abdalla Ibrahim, MD^{a,*}, P. Smeets, MD^b, I. Goethals, MD, PhD^a^a Nuclear Medicine department, University hospital Gent, Belgium.^b Radiology department, University hospital Gent, Belgium.

ARTICLE INFO

Article history:

Received 17 August 2020

Revised 29 March 2021

Accepted 29 March 2021

Keywords:

Familial Mediterranean Fever

 ^{18}F -FDG PET-CT

Positron emission tomography

Computed tomography

ABSTRACT

Familial Mediterranean Fever (FMF) is an autosomal recessive disorder that is characterised by recurrent attacks of fever and painful polyserositis mainly affecting the peritoneum, synovium and pleura that usually begins in childhood. Even though diagnostic criteria have been proposed, conclusive imaging findings or haematological markers for the diagnosis or follow-up of FMF are still lacking. In this case report we present the ^{18}F -FDG PET-CT findings in a 55 year old female during an attack of FMF. We briefly discuss the added value of ^{18}F -FDG PET-CT in the diagnosis and the work-up of FMF, which may open up new applications for ^{18}F -FDG PET-CT in non-infectious inflammatory diseases.

© 2021 The Authors. Published by Elsevier Inc. on behalf of University of Washington.

This is an open access article under the CC BY-NC-ND license

[\(http://creativecommons.org/licenses/by-nc-nd/4.0/\)](http://creativecommons.org/licenses/by-nc-nd/4.0/)

Introduction

Familial Mediterranean Fever (FMF) is a hereditary auto-inflammatory disorder which is most prevalent in populations surrounding the Mediterranean basin. It was first described as a distinct entity in 1945 [1].

As such, FMF is characterized by recurrent episodes of fever accompanied by peritonitis, pleuritis, pericarditis, arthritis or a combination of these, and may also be associated with an erysipelas-like skin rash. These episodes are transient, self-limited with reversible changes. Since the report of Goldfinger in 1972, colchicine is the treatment of choice for FMF. It is also of paramount importance in preventing FMF amyloidosis. [1-5]

☆ Acknowledgement: None declared

☆☆ Conflict-of-interest: The authors have no conflicts of interest to declare.

* All co-authors have seen and agree with the contents of the manuscript and there is no financial interest to report. We certify that the submission is original work and is not under review at any other publication.

** Patient consent: Informed consent was obtained from the patient and can be provided if needed. Please note that the patient consent is not in English language as the patient doesn't speak English.

* Corresponding author:

E-mail address: azzamzeen@gmail.com (A. Abdalla Ibrahim).<https://doi.org/10.1016/j.radcr.2021.03.071>1930-0433/© 2021 The Authors. Published by Elsevier Inc. on behalf of University of Washington. This is an open access article under the CC BY-NC-ND license (<http://creativecommons.org/licenses/by-nc-nd/4.0/>)

Case report

A 55 years old Turkish woman is admitted to our hospital with mild chest pain, fever, chills, malaise and headache while on haemodialysis. She also has a history of end stage renal failure of unknown origin for the past three years, for which haemodialysis was initiated four months prior to this admission. She is also hypertensive and on oral anti-hypertensive medication.

Her history of present illness is extensive. She reports recurrent episodes of fever, abdominal pain, joint pain and headaches during the last five years, for which she made several visits to the emergency department and her general practitioner. These attacks usually lasted for a couple of days with an irregular interval (mostly months), without clear trigger factors. There was some favourable response to paracetamol but not consistently.

The patient also reports a medical history of carpal tunnel syndrome in the right wrist, which was operated on six years ago. In the same year she received two steroid epidural injections due to long-lasting lower back pain.

Four months earlier, the patient was admitted with a similar clinical picture of fever, chills and headache, as well as night sweats and slight weight loss. A pericardial effusion was visible on MRI and echocardiography. Based on these findings and taking into account the negative consecutive blood cultures, a diagnosis of autoimmune pericarditis was made. Corticosteroids were started resulting in a rapid clinical and biochemical recovery. An extensive autoimmune screening was performed. However, anti-nuclear factor (ANF), anti-neutrophil cytoplasmic antibodies (ANCA), rheumatoid factor, anti-cyclic citrullinated peptide were normal. The patient also tested negative for anticardiolipin (aCL) antibody, lupus anticoagulants, urinary porphyrins, cryoglobulins, hepatitis B and C, and HIV. Her family history was negative for FMF.

During the current admission, the patient complains of mild chest pain, stabbing in nature, which is exacerbated by deep breathing. She also complains of left iliac fossa pain without diarrhoea or constipation. Clinical examination in the emergency department is negative except for high grade fever and mild lower abdominal tenderness. Biochemical findings include elevated inflammatory blood parameters, with CRP equal to 285 mg/L, leucocytosis of $18.63 \times 10^9/L$ and haemoglobin of 7.8 gm/dl. A CT scan of the abdomen shows conspicuous wall thickening of the rectum with mild inflammatory changes in the perirectal fat. [Fig. 7] Treatment is started, with a tentative diagnosis of acute proctitis. A left colonoscopy up to 20 cm from the anus with blind biopsies is performed, but shows no signs of proctitis. Even though multiple blood cultures are negative, empiric broad antibiotic coverage therapy is started. The treatment does not lead to any clinical or biochemical improvement, which renders the diagnosis of fever of unknown origin (FUO).

In parallel, considering the patient's medical history of a pericardial effusion and the presence of mild chest pain, a repeat echocardiography is performed, which again shows mild pericardial effusion with no evidence of pericarditis. For further elaboration, a cardiac MRI is also performed, which shows mild thickening of the pericardium with a small amount of

pericardial fluid around the heart without signs of constrictive pericarditis. [Fig. 4].

As part of the workup of FUO, an ^{18}F -FDG PET-CT scan is also performed, which shows an increased ^{18}F -FDG uptake in the pericardium, the pleura and the synovia of some big joints bilaterally, as well as an increased ^{18}F -FDG uptake in the spleen, the bone marrow, the axillar, mediastinal, retroperitoneal and para-iliac lymph nodes bilaterally. [Figs. 1–7].

In view of a hypermetabolic spleen and bone marrow, the increased ^{18}F -FDG uptake several lymph nodes on ^{18}F -FDG PET-CT scan, together with complaints of general malaise, weight loss and previous night sweats, the diagnosis of lymphoma must be considered. On the other hand, given the clinical history of joint pain and fatigue, with abnormal ^{18}F -FDG accumulation in the mediastinal lymph nodes as well as in the pericardium, sarcoidosis is also a possible diagnosis. To explore this possibility further, serum ACE (angiotensin converting enzyme) is measured but yielded normal results.

Subsequently, because of the patient's Turkish origin and the possibility of FMF, a genetic screening is performed which showed that the patient is heterozygous for V726A mutations in the MEFV gene which is known to express a phenotype of FMF in 16.5%–33.8% of the patients.

(Considering this differential diagnosis and the further clinical deterioration), a single dose of 48 mg of methylprednisolone is given during the admission with a rapid clinical recovery and significant decrease of the inflammatory markers in the blood. After a period of two weeks of hospital admission, the patient is discharged on a six-month trial of colchicine.

However, shortly after discharge from the hospital, the patient is readmitted with recurrent chest pain and increased CRP. A lymph node biopsy via mediastinoscopy and a bone marrow puncture is performed. [Fig. 3] Reactive changes are present in the lymph nodes which are characterized by an extensive amount of anthracosilicotic and hemosiderin pigment. No atypical lymphocytic proliferation or atypical epithelioid cells are found. The bone marrow biopsy is normal.

Three days later, the patient is discharged from the hospital in good health, after spontaneous remission of the clinical signs. Eighteen months later, the patient is still in complete remission while on colchicine.

Discussion

In this case report, the added value of ^{18}F -FDG PET-CT in the diagnosis and follow-up of late onset FMF is highlighted.

Symptoms of FMF start in the first decade of life in approximately 50%–60% of cases, sometimes as early as 2 weeks after birth. Only 5% develop the disease after the age of 30. In rare cases, as in our patient, the initial attack occurs in individuals older than 50 years of age. [3].

Even though FMF is usually an autosomal recessive disease and affects individuals with biallelic pathogenic mutations in the MEFV gene, phenotypic expression of FMF has been reported in a subset of patients who carry only one MEFV mutation. However, more than 90% of those carrying a single MEFV gene are asymptomatic. [6–9] The fact there are FMF patients who carry only a single mutation raises the question of

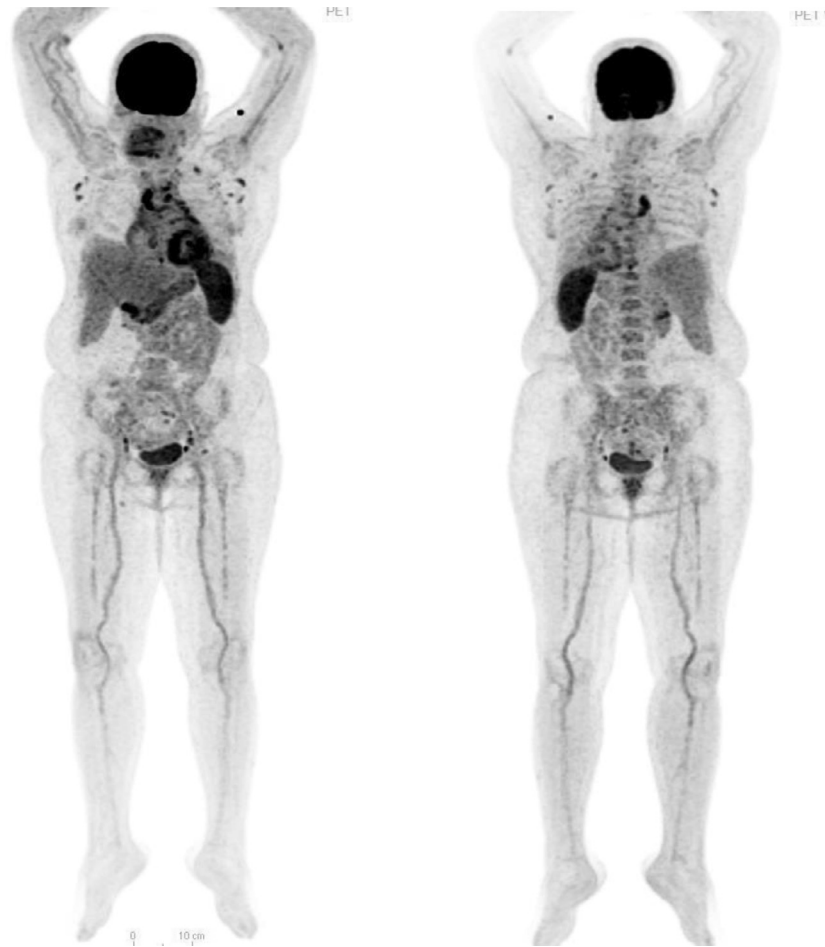

Fig 1 – PET-MIP anterior view (left) and posterior view (right) showing increased FDG uptake in different lymph nodes supra and infradiaphragmatic, pericardium, intense spleen uptake and mild FDG uptake around the big joints (knees, hips and shoulders). Please note the remarkable spleen uptake (SUV max = 7.2) in comparison with the liver (SUVmax for mediastinal blood pool = 2.9 and the liver = 3.7).

whether the disease is also transmitted as an autosomal dominant trait.

The late-onset form, as in our case, is determined more by genetic than by environmental factors. [10] Importantly, mutation analysis of late-onset FMF patients reveals the absence of M694V homozygosity, as in our patient, who was found to be heterozygous for V726A mutations in the MEFV gene. In addition, late-onset FMF patients generally respond well to a low colchicine dose, and they present with less severe symptoms as well as the absence of chronic manifestations of FMF, such as amyloidosis and chronic arthritis. [11] The non-specific and less severe manifestations however make the diagnosis of late-onset FMF very challenging. [2,4,8,9].

The hallmark of FMF pathogenesis is an inflammatory reaction affecting serosal tissues such as the pleura, peritoneum and synovium. Acute attacks of FMF are accompanied by elevated serum markers of systemic inflammation including leucocytosis with a predominance of neutrophils as well as by elevated acute phase reactants such as the erythrocyte sedimentation rate (ESR), C-reactive protein (CRP), serum amyloid protein, and fibrinogen, as a result of the increase of the

chemotactic activity of the polymorphonuclear leucocytes, and a massive influx of granulocytes to the affected tissues. [12].

However, it is worth mentioning that the exact biochemical and molecular basis for FMF is not yet fully known. [13-16]

A typical attack consists of fever and serositis lasting from 1 to 4 days and subsequently resolves spontaneously. The frequency of attacks is highly variable and irregular intervals between episodes ranging from one week to several months or even years may occur in a single patient. The severity of attacks and their frequency usually decreases as patients get older. Usually, FMF patients cannot describe a consistent trigger. Nevertheless, physical and emotional stress, menstruation, and a high-fat diet have been associated with attacks in some patients. [2,3,8].

Acute abdominal pain is the most common complaint and is present in 95% of patients. It may initially be localized and then become a more generalized abdominal pain. The most common cause is (localized) peritonitis. Some patients may report constipation, whereas in children diarrhoea is more common. [2-4,20] Our patient did not only complain of abdom-

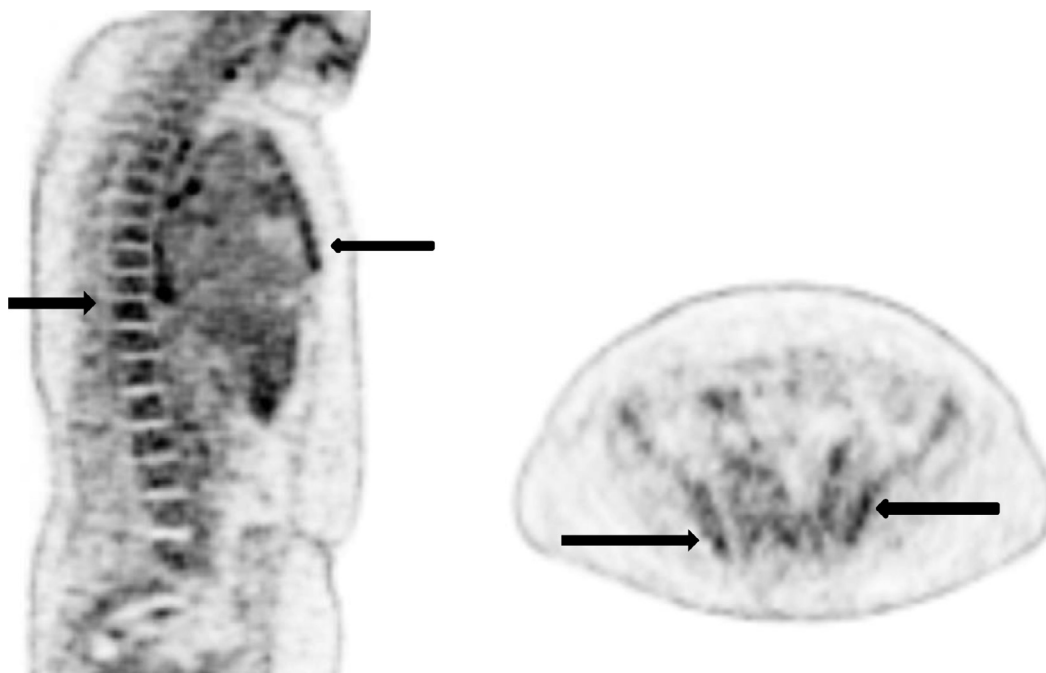


Fig 2 – PET sagittal section [left] and transverse [right] showing mild increased uptake in the bone marrow (SUV max = 4.7) of the spine and the sternum (black arrows) and the ilium.

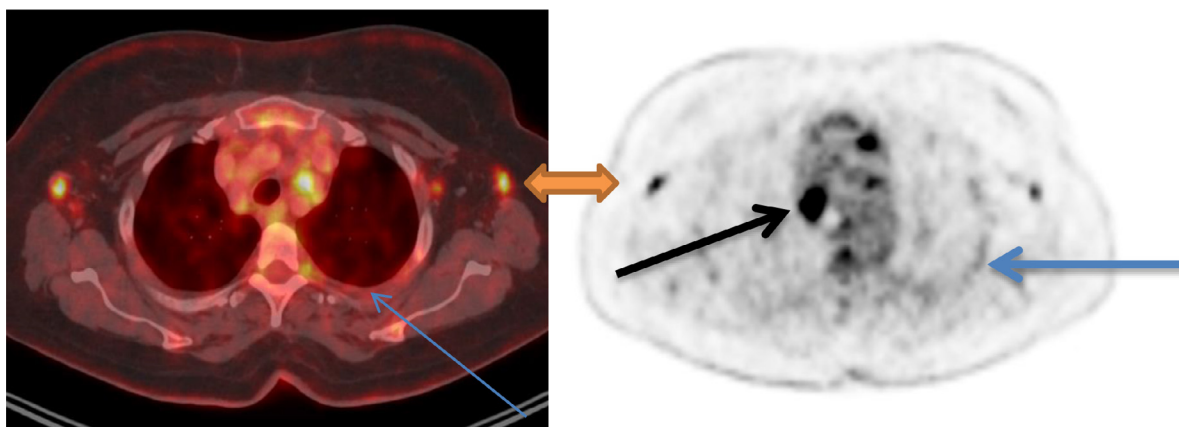


Fig 3 – PET [right] and PET-CT fusion images [left] axial sections showing the increased uptake in the axillary lymph node SUV max = 6.2 (green arrow) and the mediastinum (biopsied lymph node) SUV max = 11.8 (black arrow) plus mild pleural uptake SUV max = 3.2 (blue arrows).(Color version is available online).

inal pain during the current admission, but also during most of the recurrent attacks over the past years. However, the pain was of variable intensity, character and in different abdominal locations.

Arthritis is the second most common manifestation of FMF. There are three forms of arthritis in FMF: (1) asymmetrical, non-destructive arthritis (most common), (2) chronic destructive arthritis, including sacroiliitis, (3) migratory polyarthritis, resembling acute rheumatic fever (rare). [2,3,20] The joint attacks are usually monoarticular, involving one of the large joints but may involve different joints in subsequent attacks. Severe myalgia during the attacks usually appears in the arms and legs, and may be associated with arthritis. Only very rarely

is myalgia the sole presenting manifestation of FMF. Attacks of myalgia may last more than 3 weeks. [1-3,20].

Even though joint pain is not reported by our patient during the current admission, she reported many joint pain attacks over the past years (knee, ankle, hip and MCP joints), for which on several occasions X-rays were performed that were always normal. However, careful rereading of the ^{18}F -FDG-PET scan showed a mild increased ^{18}F -FDG uptake around the shoulders, hips and knees, with a SUV max of 2.8, 3.2 and 3.0 respectively, corresponding with active synovial membrane inflammation in these joints. ^{18}F -FDG uptake in the ankles was normal with a SUV max of 1.1. [Fig. 1,6].

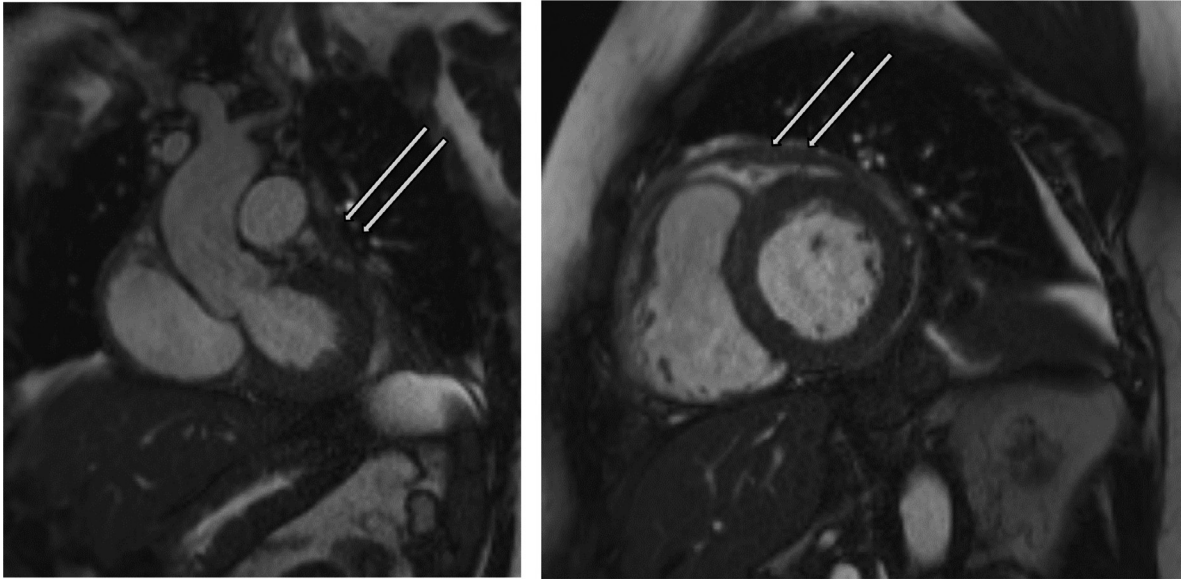


Fig 4 - MRI of the heart showing thickening of the pericardium (arrows).
Left: coronal view, Right: short axis view (both: TRUE FISP (Gradient Echo - 'white blood' sequence) without contrast administration).

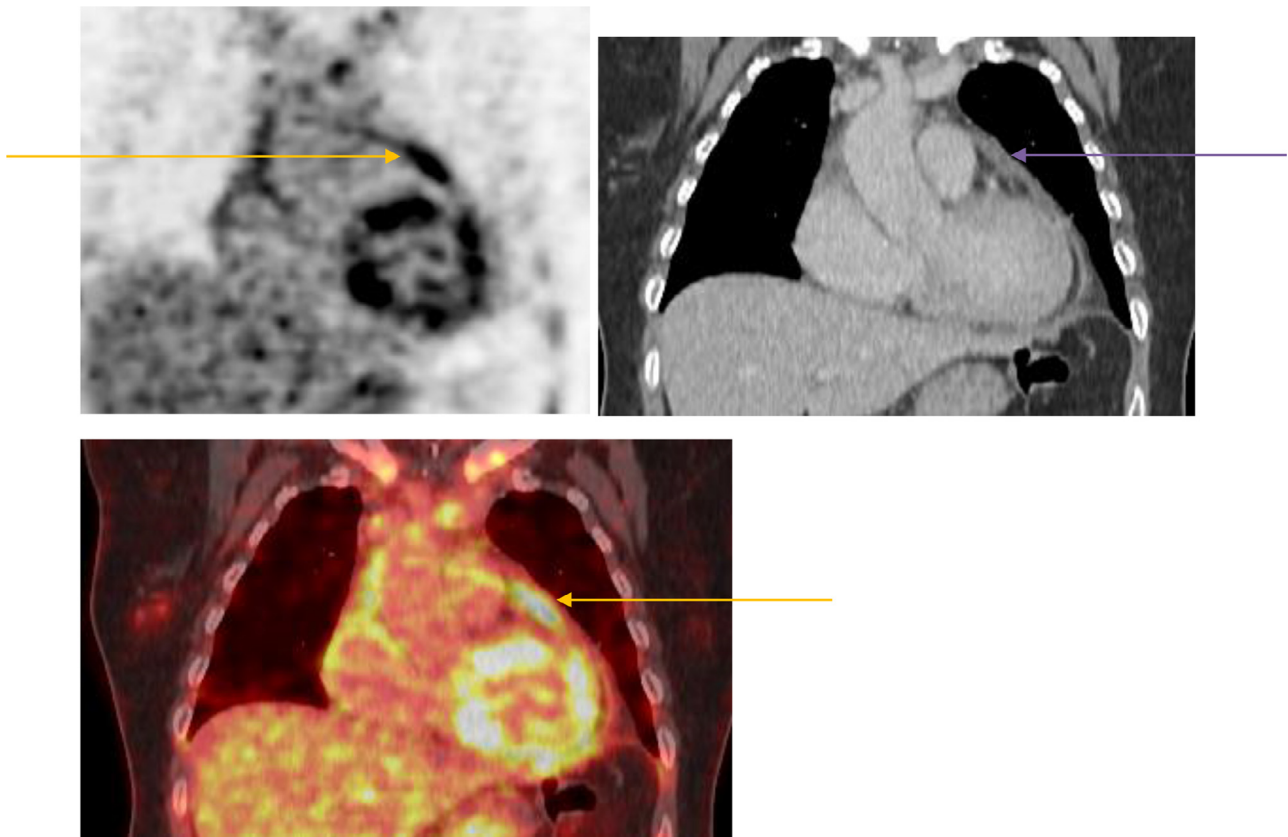


Fig 5 - Coronal sections for PET [upper left], CT [upper right] and fused PET-CT [lower] images showing increased FDG uptake in the thickened pericardium SUV max = 6.9 (arrows). Please compare with MRI coronal view in image 4.

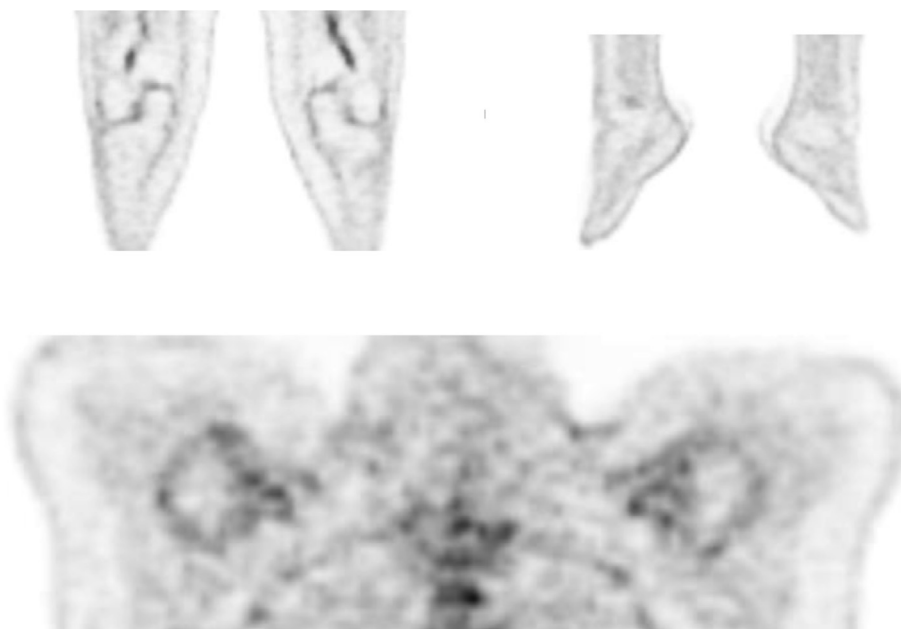


Fig 6 – PET coronal section of the knees, ankles [upper row] and shoulders [lower row] showing the mild increased FDG uptake (SUV max around 3.0) around the knees and shoulders (arrows) and physiological uptake around the ankles.

Chest pain occurs in 25% – 80% of FMF cases, which may last as long as 7 days and is the sole presenting manifestation of FMF in 5% of patients. Chest pain may be due to inflammation of the pleura, the pericardium or may be referred pain from sub-diaphragmatic inflammation [1-3,19-20]. FMF-associated chest pain may be very challenging to diagnose, given its various causes which might lead to diverse characteristics, radiation patterns, associated symptoms, time course, and also exacerbating and relieving factors of the pain. Although pericarditis tends to appear at a late stage of the disease, in our case it was the reason for the first hospital admission.

The diagnosis of FMF is made on the basis of clinical symptoms and supported by ethnic origin and family history. Depending on the protocol, the diagnosis of FMF can be supported by a six-month trial of colchicine therapy which results in a relief of attacks and recurrence after cessation of treatment. Many diagnostic criteria have been proposed, but no consensus has been reached yet. [2-5,8,19].

To date, the role of imaging in FMF is limited, as the majority of patients have non-specific imaging findings. [21] However, the role of ^{18}F -FDG PET-CT in FMF has never been fully explored. To our knowledge, this is the first case report with a focus on ^{18}F -FDG PET-CT findings in (late-onset) FMF in the literature.

In a single previous case report of a known FMF patient in Japan, increased ^{18}F -FDG uptake in the bone marrow was described. However, the focus in this case report was on the fact that the administration of granulocyte-colony stimulating factor (G-CSF) induced a homogeneous hypermetabolic activity in the bone marrow. [17] Other reports in the literature investigating the role of ^{18}F -FDG PET-CT in fever of unknown origin included only accidental FMF cases. [18].

Considering the presence of multifocal serosal inflammation in FMF characterized by a massive influx of polymor-

phonuclear leukocytes (PMNs) during FMF attacks, ^{18}F -FDG-PET can be of value as well in diagnosing as in follow-up of FMF cases.

Since peritonitis is the most common presentation of FMF, special attention must be given to the abdominal imaging findings on ^{18}F -FDG PET-CT scan, which may be hampered by a high physiological ^{18}F -FDG uptake in the intestines. It is notable that in our case, on the CT scan upon admission, a thickened and mild inflammatory rectal wall was seen suggesting proctitis. Eight days later, on the ^{18}F -FDG PET-CT scan only focal thickening of the posterior rectal wall showing mild increased ^{18}F -FDG uptake persisted. [Fig. 7] These findings suggest a localized peritonitis and may explain the negative colonoscopy and biopsies at the time.

Although the spleen is commonly involved in FMF and splenomegaly is reported in 30%-50% of FMF cases, our finding of hypermetabolism in a morphologically normal spleen on ^{18}F -FDG PET-CT is of little help as increased ^{18}F -FDG uptake in the spleen may suggest lymphoma with spleen involvement [Fig. 1].

^{18}F -FDG PET is highly sensitive to detect active synovitis. Even though our patient was asymptomatic upon admission, a mild increased ^{18}F -FDG uptake was seen in the synovial membranes of several big joints out of proportion to degree of degenerative change (SUV max around 3.0), with a complete sparing of the ankles, suggesting an active synovitis. [Fig. 1,6]

It is noteworthy that the mild joint uptake was not reported in the first ^{18}F -FDG PET-CT report, however a careful review of the scan after negative workup and a positive FMF gene test, increased the clinical importance of this mild uptake given the pathophysiology of FMF and the detailed medical history of the patient.

Even with minimal chest pain upon admission, ^{18}F -FDG PET-CT scan showed signs of pericardial and pleural inflam-

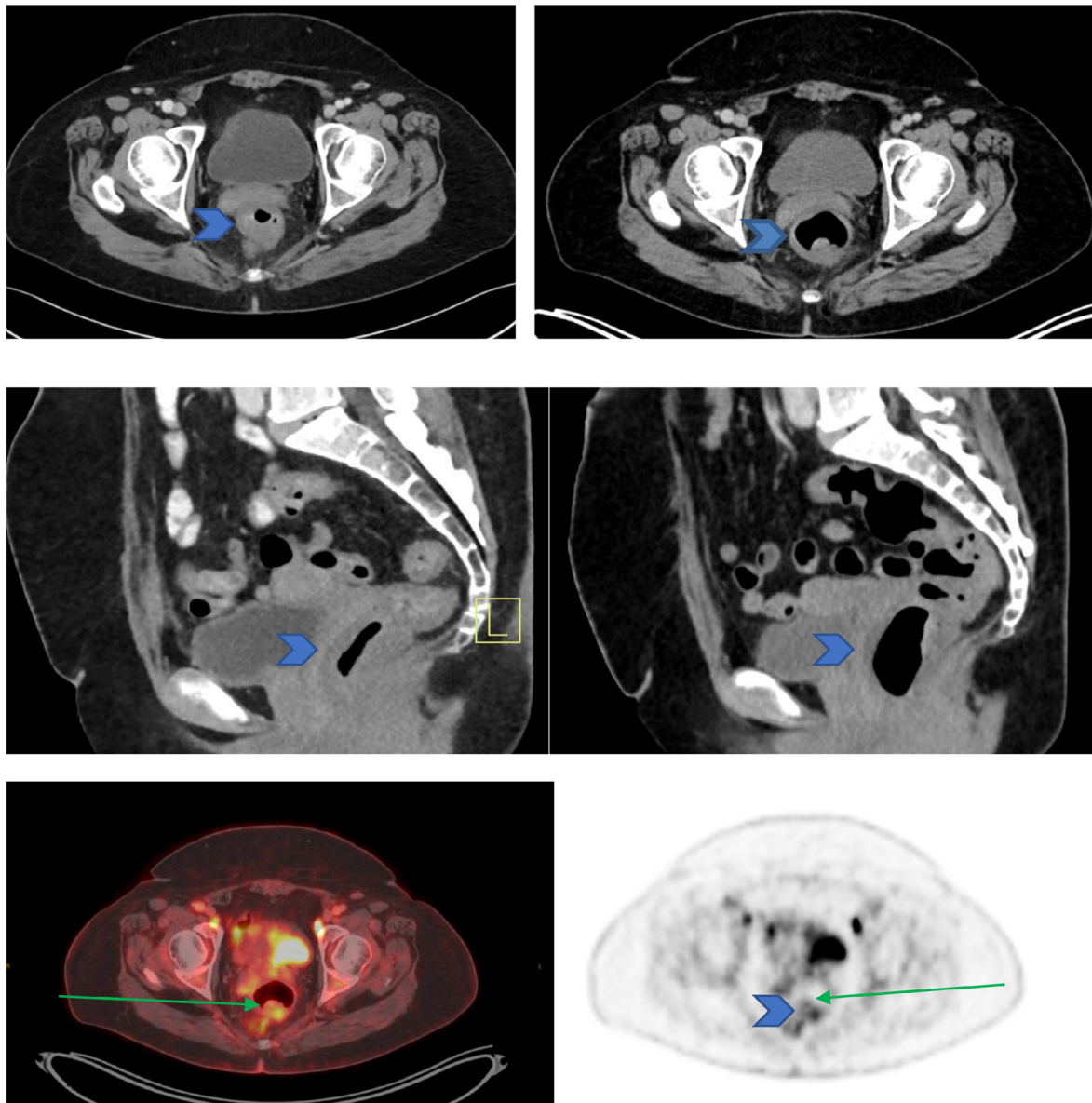


Fig 7 – Transverse section CT [upper row] and coronal section [second row] by admission (left) and eight days later as part of PET-CT (right) showing the regression of the rectum wall thickening. Transverse section of fusion image (left) and PET (right) [third row] showing mild focal FDG uptake (SUV max = 5.6) in the residual thickening of the rectum wall. Please note the physiological faecal activity (green arrows). (Color version is available online).

mation. [2-4,8] The former was also confirmed by a cardiac MRI showing thickening of the pericardium with a small amount of pericardial fluid. [Fig. 4-5].

While lymph nodes are not typically involved in FMF, the finding of hypermetabolic lymph nodes on ^{18}F -FDG-PET-CT scan may guide biopsy and so discriminate between inflammatory and lympho-proliferative disease. [Fig. 3].

Finally, amyloidosis is one of the most significant long-term complications of FMF and a major cause of mortality in patients with FMF, usually affecting the kidneys, and resulting in renal failure and end-stage renal disease. Amyloidosis may also affect the gastrointestinal tract, liver, spleen, and at a later stage the heart and testes. The amyloid is of the AA type,

which is typical of secondary amyloidosis. It is noteworthy that the frequency of amyloidosis differs between various ethnic groups. As mentioned above, colchicine may significantly decrease the incidence of amyloidosis. [5].

Hypothetically, we can think of amyloidosis as a possible cause of the kidney failure, especially in the light of a negative autoimmune screening. Unfortunately, renal biopsy could not be performed due to her high blood pressure.

As an alternative we performed a bone marrow biopsy as part of the workup, which was negative.

Bone marrow biopsy is a good alternative method for diagnosis in this case as it showed amyloidosis in 80% of patients with amyloidosis secondary to FMF. [22].

¹⁸F-FDG PET-CT is not recommended to diagnose systemic amyloidosis. Instead, other radiotracers are more suitable such as ¹²³I- serum amyloid P component (SAP) for Single Photon Emission Computed Tomography (SPECT), ^{99m}Tc-Aprotinin (SPECT) or ¹¹C-Pittsburgh compound B (PIB) for Positron emission tomography (PET). [23].

Conclusion

This case report illustrates that the diagnosis of (late onset) FMF is challenging and ¹⁸F-FDG PET-CT may have a role. More studies in this specific patient population are needed to corroborate our findings.

Disclosure

Informed consent was obtained from the patient.

REFERENCES

- [1] Eliakim M, Levy M, Ehrenfeld M. Recurrent polyserositis (familial Mediterranean fever). Amsterdam: Elsevier/North Holland Biomedical; 1981.
- [2] Samuels J, Aksentijevich I, Torosyan Y, Centola M, Deng Z, Sood R, et al. Familial mediterranean fever at the millennium. clinical spectrum, ancient mutations, and a survey of 100 american referrals to the national institutes of health. *Medicine (Baltimore)* 1998;77(4):268–97.
- [3] Ben-Chetrit E, Levy M. Familial Mediterranean fever. *Lancet* 1998;351(9103):659–64 Feb 28.
- [4] Sohar E, Gafni J, Pras M, Heller H. Familial mediterranean fever. A survey of 470 cases and review of the literature. *Am J Med* 1967;43:227.
- [5] Pras E, Livneh A, Balow JE Jr, Pras E, Kastner DL, Pras M, et al. Clinical differences between North African and Iraqi Jews with familial Mediterranean fever. *Am J Med Genet* 1998;75(2):216–19.
- [6] The International FMF Consortium Ancient missense mutations in a new member of the RoRet gene family are likely to cause familial Mediterranean fever. *Cell* 1997;90:797–807.
- [7] Bernot A, Clepet C, Dasilva C, Devaud C, Petit JL, Caloustian C, ruaud C, et al. The French FMF Consortium: a candidate gene for familial Mediterranean fever. *Nat Genet* 1997;17:25–31.
- [8] Ben-Chetrit E, Touitou I. Familial mediterranean fever in the world. *Arthritis Rheum* 2009;61:1447.
- [9] Booty MG, Chae JJ, Masters SL, et al. Familial mediterranean fever with a single MEFV mutation: where is the second hit? *Arthritis Rheum* 2009;60:1851.
- [10] Tamir N, Langevitz P, Zemer D, et al. Late-onset familial mediterranean fever (FMF): A subset with distinct clinical, demographic, and molecular genetic characteristics. *Am J Med Genet* 1999;87:30–5.
- [11] Kishida D, Nakamura A, Yazaki M, Tsuchiya-Suzuki A, Matsuda M, Ikeda S. Genotype-phenotype correlation in Japanese patients with familial mediterranean fever: differences in genotype and clinical features between Japanese and Mediterranean populations. *Arthritis Res Ther* 2014;16:439–48.
- [12] Bar-Eli M, Ehrenfeld M, Levy M, et al. Leukocyte chemotaxis in recurrent polyserositis (familial Mediterranean fever). *Am J Med Sci* 1981;281:15–18.
- [13] Matzner Y, Ayesch S, Hochner-Celniker D, et al. Proposed mechanism of the inflammatory attacks in familial Mediterranean fever. *Arch Intern Med* 1990;150:1289–91.
- [14] Barakat MH, El-Khawad AO, Gumaa KA. Metaraminol provocative test: a specific diagnostic test for familial Mediterranean fever. *Lancet* 1984;1(8378):656–7. doi:10.1016/s0140-6736(84)92172-x.
- [15] Ben-Chetrit E, Levy M. Autoantibodies in familial mediterranean fever (recurrent polyserositis). *Br J Rheumatol* 1990;29:459–61.
- [16] Swissa M, Schul V, Korish S, et al. Determination of autoantibodies in patients with familial Mediterranean fever and their first degree relatives. *J Rheumatol* 1991;18:606–8.
- [17] Koga T, Umeda M, Migita K, Yamasaki S, Nakamura H, Kawakami A. A Japanese case of familial Mediterranean fever presenting diffuse bone marrow uptake of FDG-PET and high levels of neutrophil membrane CD64 expression. *Rheumatology (Oxford)* 2011;50(6):1171–3 Epub 2011 Feb 4. doi:10.1093/rheumatology/ker012.
- [18] Tokmak H, Ergonul O, Demirkol O, Cetiner M, Ferhanoglu B. Diagnostic contribution of ¹⁸F-FDG-PET/CT in fever of unknown origin. *Int J Infect Dis* 2014;19:53–8 Epub 2013 Dec 1. doi:10.1016/j.ijid.2013.10.009.
- [19] Livneh A, Langevitz P, Zemer D, et al. Criteria for the diagnosis of familial Mediterranean fever. *Arthritis Rheum* 1997;40:1879.
- [20] Zadeh N, Getzug T, Grody WW. Diagnosis and management of familial Mediterranean fever: Integrating medical genetics in a dedicated interdisciplinary clinic. *Genet Med* 2011;13(3):263–9. doi:10.1097/GIM.0b013e31820e27b1.
- [21] Ishak Gisele E, Khoury Nabil J, Birjawi Ghina A, El-Zein Youssef R, Naffaa Lena N, Haddad Maurice C. Imaging findings of familial Mediterranean fever. *G.E. Ishak et al. / Clinical Imaging* 2006;30:153–9.
- [22] Sungur C, Sungur A, Ruacan S, et al. Diagnostic value of bone marrow biopsy in patients with renal disease secondary to FMF. *Kidney Int* 1993;44:834–6.
- [23] Cytawa Wojciech, Teodorczyk F Jacek, Lass Piotr. Nuclear Imaging of Amyloidosis. *Pol J Radiol* 2014;79:222–7.