

Available online at www.sciencedirect.com

ScienceDirect

journal homepage: <http://Elsevier.com/locate/radcr>

Case Report

Prostate brachytherapy seed migration to the heart seen on cardiovascular computed tomographic angiography

Shilpa Sachdeva MD^a, Nneka S. Udechukwu BS^{b,*}, Hossam Elbelasi MD^b,
Kevin P. Landwehr^b, William H. St. Clair MD^a, Michael A. Winkler MD^b

^a Department of Radiation Medicine, University of Kentucky Medical Center, Lexington, KY 40536, USA

^b Department of Radiology, University of Kentucky Medical Center, 805 Rose Street, MN-104G, Lexington, KY 40536-0298, USA

ARTICLE INFO

Article history:

Received 17 August 2016

Received in revised form

10 October 2016

Accepted 14 October 2016

Available online 22 November 2016

Keywords:

Prostate cancer

Embolus

Therapeutic seeds

Brachytherapy

ABSTRACT

Brachytherapy consists of placing radioactive sources into or adjacent to tumors, to deliver conformal radiation treatment. The technique is used for treatment of primary malignancies and for salvage in recurrent disease. Permanent prostate brachytherapy seeds are small metal implants containing radioactive sources of I-125, Pd-103, or Cs-131 encased in a titanium shell. They can embolize through the venous system to the lungs or heart and subsequently be detected by cardiovascular computed tomography. Cardiovascular imagers should be aware of the appearance of migrated seeds, as their presence in the chest is generally benign, so that unnecessary worry and testing are avoided. We report a case of a patient who underwent brachytherapy for prostate cancer and developed a therapeutic seeds embolus to the right ventricle.

© 2016 the Authors. Published by Elsevier Inc. under copyright license from the University of Washington. This is an open access article under the CC BY-NC-ND license (<http://creativecommons.org/licenses/by-nc-nd/4.0/>).

Introduction

Prostate cancer is a slow-growing exocrine gland neoplasm of the reproductive system which most commonly affects men of older age. Methods of prostate cancer management include radical excision, hormone-mediated therapy, and radiation therapy including brachytherapy [1,2]. It is of rare occurrence for an emboli secondary to transmigration of brachytherapy seeds, affixed to the prostate, to be localized in the heart of the patient. On the contrary, embolus of seeds to other organs (e.g., the lungs) is not uncommon [1,3,4]. For this reason, cardiac imagers who do not also practice general thoracic imaging may not be as familiar with the phenomena of seed

embolization. Herein is a report of seed embolization to the right heart diagnosed with gated cardiac computed tomography. Review of the images provided should be sufficient to educate cardiac imagers to identify this rare form of embolus.

Case report

A 60-year-old male with known coronary artery disease presented to the emergency room with acute left-sided atypical chest pain that varied in intensity with deep inspiration. Blood D-dimer and troponin values were determined to be normal. An electrocardiogram was obtained but showed only nonspecific

Competing Interests: The authors have declared that no competing interests exist.

* Corresponding author.

E-mail address: nsud222@uky.edu (N.S. Udechukwu).

<http://dx.doi.org/10.1016/j.radcr.2016.10.009>

1930-0433/© 2016 the Authors. Published by Elsevier Inc. under copyright license from the University of Washington. This is an open access article under the CC BY-NC-ND license (<http://creativecommons.org/licenses/by-nc-nd/4.0/>).

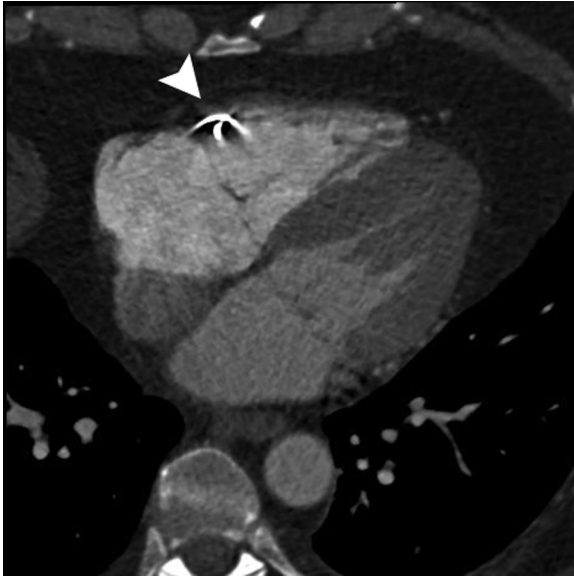


Fig. 1 – CCTA pseudoaxial thin maximal intensity projection image shows very high density focus within the anterior wall of the right ventricle during the isovolemic relaxation phase of systole. The arrow indicates the location of the brachytherapy seeds.

abnormalities. Cardiovascular computed tomography (CVCT) of the thorax was performed at the request of the patient's cardiologist. A "triple rule out" protocol was used to enable opacification of the pulmonary arteries concurrently with the aorta and coronary arteries. The CVCT reconfirmed atherosclerosis of the

coronary arteries but was negative for flow-limiting lesion. Furthermore, it was negative for pulmonary embolus, aortic dissection, pneumonia, or other significant pathology. The patient's pain resolved spontaneous, and the patient returned to work the very next day. Based on the clinical course, the pain was diagnosed as musculoskeletal in origin.

The CVCT revealed an interesting incidental finding, two tiny deposits of metal within the anterior wall of the right ventricle. These deposits caused extreme beam and streak artifacts relative to their tiny size and moved throughout the cardiac cycle as if embedded in the parenchyma (Fig. 1, also Cine 1 for electronic version). A review of prior chest radiographs of the chest revealed, in retrospect, that these metal deposits had been present at least 1 year prior (Fig. 2). The patient did not have any prior history of thoracic intervention or trauma. However, on close questioning, he reported that he had undergone prostate seed implant brachytherapy several years previously (Cine 2 for electronic version).

Discussion

Use of permanent prostate brachytherapy has matured in the last two decades and is now considered routine in the management of low-grade, low-stage prostate cancer. Permanent brachytherapy procedures involve transperineal ultrasound-guided insertion of "seeds" containing radioactive sources Palladium-103 (Pd-103) or Iodine-125 (I-125). Pd-103 has a shorter half-life (17 days, compared to 59 days for I-125), allowing a higher initial dose that may be more effective in faster growing tumors [1]. I-125, the more commonly used isotope, is lower in cost and more easily available.

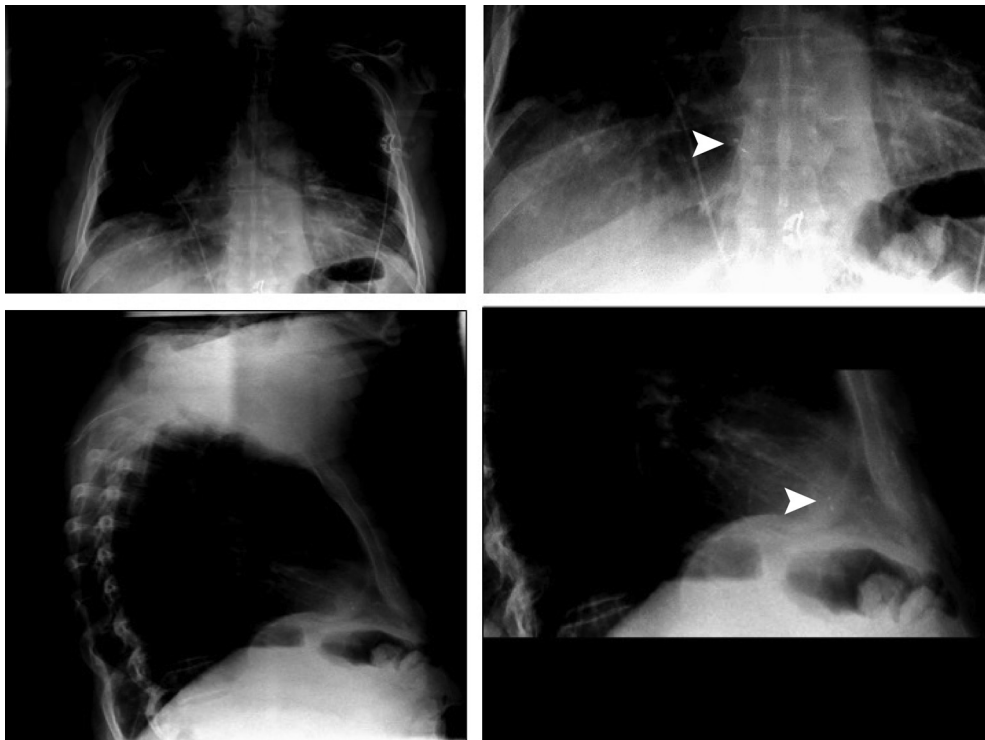


Fig. 2 – PA and lateral radiograph of the chest with magnification view of the heart. The arrows indicate the location of the brachytherapy seeds.

The radioactive “seeds” used in brachytherapy are cylindrical and 4–4.5 mm long with a diameter of 800 micrometers [2]. An inert titanium casing contains both the radioactive material and a small amount of gold foil to ensure easy visualization with both fluoroscopy and computerized tomography. Seeds are often placed near or outside the prostatic capsule, to ensure an adequate dose of radiation is delivered to the periphery of the prostate (Fig. 3, also Cine 2 for electronic version). The prostate is surrounded by a dense venous plexus as such seeds which erode into this vasculature or are originally implanted within it can migrate hematogenously to other sites [3].

The highest reported incidence of seed migration has been to the pulmonary vasculature. In a single case study, Ankem et al. [3] demonstrate that seed migration can occur in 36.2% of patients undergoing prostate brachytherapy. For this reason, guidelines issued by the American Brachytherapy Society recommend counseling patients about the possibility of implants migrating to the lungs [4]. Some investigators have been concerned that this phenomenon can decrease radiation dose to the prostate malignancy and adversely affect lung tissue [1]. However, the loss of 2–4 seeds does not significantly alter the prostate dosimetry, and the calculated dose of radiation to the lung tissue in this scenario, between 20–30 keV per 1 cm³ of lung tissue, was found to have a minimal effect on pulmonary function due to the short half lives of the radioactive isotopes used [1].

There are sparse reports of unusual sequelae of seed migration. Single examples of radiation pneumonitis, acute myocardial infarction, and small-cell lung cancer associated with seed migration to the thorax have been reported [5–7]. Migration of seeds directly into the parenchyma of the right ventricle, as with the case detailed herein, has been reported and proven previously at autopsy, although rare [2]. Most concerns of these reports are related to fear of secondary malignancy or mortality from the radiation effect and embolization, respectively. However, a number of convincing

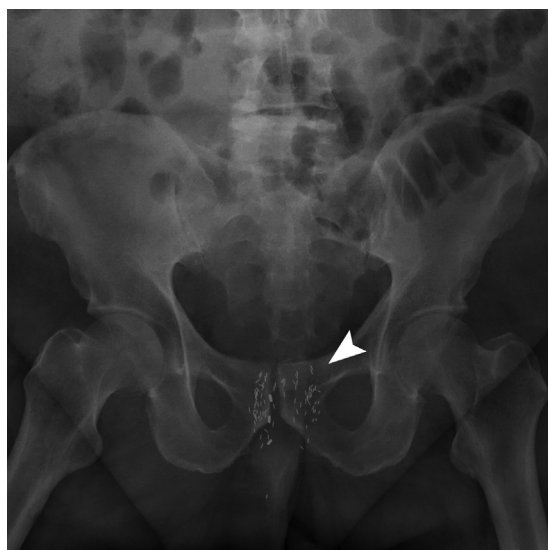

Fig. 3 – Thick maximal intensity projection series derived from a CT Urogram of the prostate shows prostate seeds in situ (different patient). The arrow indicates the location of the brachytherapy seeds.

studies on the phenomenon of seed migration have concluded that the risk of any morbidity is negligible [8–11].

Conclusion

The finding of prostate seed embolization to the heart or lungs is not an indication for subsequent scanning as the reports of possible detrimental risks have been low. Regardless, health care providers should be educated on the appearance of migrated seeds to maintain awareness of its possibility and decrease unnecessary follow-up and testing.

Supplementary data

Supplementary data associated with this article can be found in the online version, at <http://dx.doi.org/10.1016/j.radcr.2016.10.009>.

REFERENCES

- [1] Nag S, Vivekanandam S, Martínez-monge R. Pulmonary embolization of permanently implanted radioactive palladium-103 seeds for carcinoma of the prostate. *Int J Radiat Oncol Biol Phys* 1997;39(3):667–70.
- [2] Davis BJ, Pfeifer EA, Wilson TM, King BF, Eshleman JS, Pisansky TM. Prostate brachytherapy seed migration to the right ventricle found at autopsy following acute cardiac dysrhythmia. *J Urol* 2000;164(5):1661.
- [3] Ankem MK, Decarvalho VS, Harangozo AM, Hartanto VH, Perrotti M, Han Kr, et al. Implications of radioactive seed migration to the lungs after prostate brachytherapy. *Urology* 2002;59(4):555–9.
- [4] Sommerkamp H, Rupprecht M, Wannemacher M. Seed loss in interstitial radiotherapy of prostatic carcinoma with I-125. *Int J Radiat Oncol Biol Phys* 1988;14(2):389–92.
- [5] Miura N, Kusuhara Y, Numata K, Shirato A, Hashine K, Sumiyoshi Y, et al. Radiation pneumonitis caused by a migrated brachytherapy seed lodged in the lung. *Jpn J Clin Oncol* 2008;38(9):623–5.
- [6] Zhu AX, Wallner KE, Frivold GP, Ferry D, Jutzy KR, Foster GP. Prostate brachytherapy seed migration to the right coronary artery associated with an acute myocardial infarction. *Brachytherapy* 2006;5(4):262–5.
- [7] Chen WC, Katcher J, Nunez C, Tirgan AM, Ellis RJ. Radioactive seed migration after transperineal interstitial prostate brachytherapy and associated development of small-cell lung cancer. *Brachytherapy* 2012;11(5):354–8.
- [8] Grimm PD, Blasko J, Ragde H, Sylvester J, Mate T. Migration of iodine-125 and palladium-103 seeds to the lung after transperineal brachytherapy for prostate cancer. *Endocrine Hypertherm Oncol* 1993;9:50.
- [9] Gupta S, Nag S, Gupta J. Pulmonary embolization of permanently implanted radioactive iodine-125 seeds. *Endocrine Hypertherm Oncol* 1993;9:27–31.
- [10] Nag S, Scaperth DD, Badalament R, Hall SA, Burgers J. Transperineal palladium 103 prostate brachytherapy: analysis of morbidity and seed migration. *Urology* 1995;45(1):87–92.
- [11] Steinfeld AD, Donahue BR, Plaine L. Pulmonary embolization of iodine-125 seeds following prostate implantation. *Urology* 1991;37(2):149–50.