

Received: 2015.04.04
Accepted: 2015.06.01
Published: 2015.08.27

Duodenal Obstruction Caused by Acute Appendicitis with Intestinal Malrotation in a Child

Authors' Contribution:
Study Design A
Data Collection B
Statistical Analysis C
Data Interpretation D
Manuscript Preparation E
Literature Search F
Funds Collection G

ABCDEF 1 **Şenol Biçer**
DEF 2 **Ali Çelik**

1 Department of Pediatric Surgery, Erzincan University, Medical School, Erzincan, Turkey
2 Department of General Surgery, Konya State Hospital, Konya, Turkey

Corresponding Author: Şenol Biçer, e-mail: drsenolbicer@gmail.com
Conflict of interest: None declared

Patient: Male, 14
Final Diagnosis: Duodenal obstruction
Symptoms: Bilious vomiting
Medication: None
Clinical Procedure: Laparotomy
Specialty: Surgery

Objective: Rare disease





Background: In patients with intestinal malrotation, the diagnosis of acute appendicitis can be difficult due to atypical presentation. Duodenal obstruction caused by acute appendicitis with the presence of malrotation has rarely been reported in children.

Case Report: We report the case of a 14-year-old male patient with bilious vomiting and abdominal distension. A diagnosis could not be made by computed tomography, ultrasonography, or endoscopy. We observed a dilated stomach and malrotation in laparotomy. The caecum was in the right upper quadrant, and an inflamed appendix was located in the subhepatic region. After the appendectomy, the cecum was mobilized and fixed in the right lower quadrant.

Conclusions: In children with intestinal malrotation, acute appendicitis can present as duodenal obstruction without abdominal pain, and standard imaging methods can miss the correct diagnosis.

MeSH Keywords: Appendicitis • Ileus • Rotation

Full-text PDF: <http://www.amjcaserep.com/abstract/index/idArt/894311>

 1057  —  2  13



Background

Duodenal obstruction in patients with malrotation due to acute appendicitis has been reported in adults [1]. Malrotation is a congenital malformation of the intestine as a result of inadequate rotation during the gestational stage [2]. The fact that the intestines are in a different location instead of the normal anatomical position makes it difficult to diagnose some diseases [3]. In addition, malrotation accounts for intestinal obstructions characterized by bilious vomiting. A newborn was reported to have perforated appendicitis, causing a duodenal obstruction [4]. Although malrotation in acute appendicitis is an expected situation in children, duodenal obstruction due to acute appendicitis is unexpected.

Case Report

A 14-year-old male patient was admitted to our hospital with complaints of bilious vomiting. The patient's complaints had started 2 days prior, after overeating. While the vomiting first contained contents of the stomach, it was later bilious. There was no abdominal pain. A nasogastric tube was placed and 2500 ml of bilious content was drained. Upon abdominal examination, the intestinal sounds were hyperactive and there was no abdominal tenderness. There was clapotage in the epigastric area. We noted that the rectum was empty upon a rectal examination. In a direct abdominal imaging in a standing position, the stomach seemed to be dilated. The appearance of gas in the intestines decreased. Hemoglobin was 9.3 g/dl, serum iron was 21 µg/dl (45–175), serum iron binding capacity was 417 µg/dl (165–375), and serum ferritin was 21 µg/L (22–322). Leukocytosis was not present. In ultrasonography, both the stomach and the 1st and 2nd parts of the duodenum were very distended, but the other parts of the small intestines and colon were not dilated.

In an abdomen CT scan, the 1st and 2nd parts of the duodenum and stomach were slightly dilated, and we observed wall thickening in the pylorus segment and passage to distal. In upper gastrointestinal (UGI) radiography, a dilated stomach extending to the pelvic region was observed (Figure 1). In the first 20 min, there was no passage to the small intestine. Within 2 h, half of the contrast substance had passed to distal. Based on endoscopy, the passage was open for 100 cm. After pre-operative resuscitation, the patient was operated on. We accessed the abdomen via an upper median incision. In the exploration, it was seen that the stomach was dilated and that there was malrotation. The cecum was mobile and located in the right upper quadrant. The appendix was located at the subhepatic region (Figure 2); it was inflamed but not perforated. An appendectomy was performed and the cecum was mobilized and fixed in the right lower quadrant. Liquid was added from a nasogastric catheter and the passage of the contents

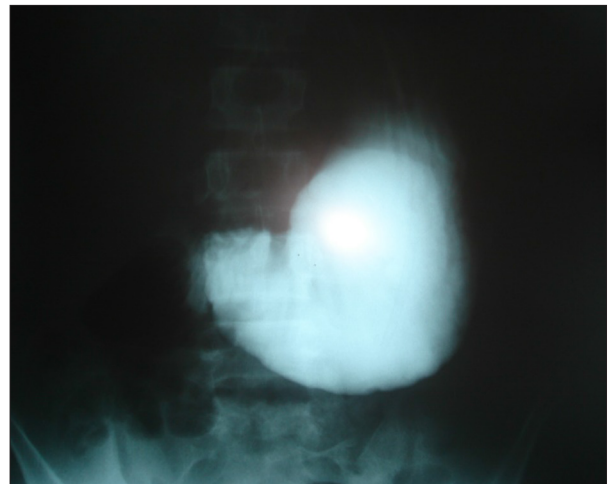


Figure 1. The appearance of the dilated stomach extending to the pelvic region in UGI radiography.

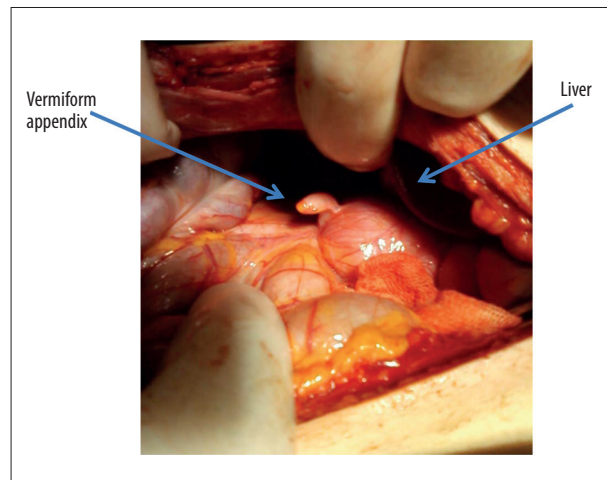


Figure 2. Operative photograph showing the inflamed appendix in the upper abdominal region.

to the small intestine was observed. We determined that the passage was open and the surgery was concluded. After the surgery, the patient, who was stopped enteral feeding, was given total parenteral nutrition for 15 days. The nasogastric drainage amount decreased gradually. UGI radiography of the patient, who could tolerate oral nutrition on the post-operative 15th day, was obtained. Although the stomach was dilated, it was seen that the passage was normal. The pathology report noted acute appendicitis, and the patient was discharged on the 20th day after the operation. Gastric dilatation improved in a follow-up X-ray examination 2 months later.

Discussion

It is frequently difficult to assess abdominal pain in children. In the case of appendicitis, which is the most frequent cause

of abdominal pain requiring surgery, morbidity can be decreased with correct and rapid diagnosis. After clinical assessment, there is a need for advanced diagnosis methods [5]. In our case, there were no symptoms such as pain, fever, or leukocytosis findings other than bilious vomiting that would make us suspect appendicitis. When the appendix was visualized with imaging methods in an unexpected region, malrotation should be suspected [2,6]. In our case, the location of the appendix could not be confirmed with imaging methods.

Most symptomatic intestinal rotation anomalies are detected in the neonatal period. Half of the cases are diagnosed within the first postnatal week and 80% of cases are diagnosed within the first month of life [7,8]. However, malrotation is asymptomatic in adults. It can be incidentally diagnosed in routine examinations or in laparotomies for other diseases. In children, the presentation of symptomatic intestinal rotation anomalies varies with age. Infants always exhibit vomiting. However, adults mostly present with abdominal pain. The incidence of volvulus decreases with age. The incidence rate was reported to be 12% in children younger than 1 year, 12% in children aged 1–18, and 22% in adults older than 18 [5]. In our patient, a 14-year-old male, there was ileus that resulted from appendix inflammation and there was a gastric outlet obstruction. The only clinical finding was bilious vomiting.

Malrotation consists of a spectrum of congenital malformations that result from inadequate rotation of the superior mesenteric veins in the fetal intestine in 10th–12th weeks of gestation [2]. In malrotation syndromes, it was reported that many malabsorption symptoms such as chronic diarrhea and growth retardation are seen after the neonatal period [9]. In our case, there was chronic iron-deficiency anemia.

References:

1. Ueo H, Nagamatsu M, Nakamura A et al: Duodenal obstruction caused by acute appendicitis with intestinal malrotation in an adult. A case report. *Jpn J Surgery*, 1990; 20: 346–50
2. Keyzer C, Tack D, deMaerteiser V et al: Acute appendicitis: comparison of low dose- and standard-dose enhanced multi-detector row CT. *Radiology*, 2004; 232: 164–72
3. Nehra D, Goldstein AM: Intestinal malrotation: varied clinical presentation from infancy through adulthood. *Surgery*, 2011; 149(3): 386–93
4. Sweed Y, Quinn F, Puri P, Guiney EJ: Neonatal perforated appendicitis associated with duodenal obstruction. *Pediatr Surgery Int*, 1992; 7: 306–7
5. Bundy DG, Byerley JS, Liles EA et al: Does this child have appendicitis? *JAMA*, 2007; 298(4): 438–51
6. Sonomura T, Koyama T, Ishii S et al: Acute appendicitis with intestinal malrotation: the usefulness of coronal computed tomography. *Intern Med*, 2014; 53(14): 1511–13
7. Stewart DR, Colondy AL, Daggett WC: Malrotation of the bowel in infants and children: A 15 year review. *Surgery*, 1976; 79: 716–20
8. Kiesewetter WB, Smith JW: Malrotation of midgut in infancy and childhood. *Arch Surgery*, 1985; 77: 483–91
9. Imamoglu M, Cay A, Saruhan H, Sen Y: Rare clinical presentation mode of intestinal malrotation after neonatal period: Malabsorption-like symptoms due to chronic midgut volvulus. *Pediatr Int*, 2004; 46(2): 167–70
10. Fernandez EM, Favre Rizzo J, Arteaga González I, Hernández Hernández JR: Left-sided appendicitis: diagnosis and minimally invasive treatment. *Acta Gastroenterology Latinoam*, 2014; 44(1): 62–66
11. Odabasi M, Arslan C, Abuoglu H et al: An unusual presentation of perforated appendicitis in epigastric region. *Int J Surgery Case Rep*, 2014; 5(2): 76–78
12. Tawk CM, Zgheib RR, Mehanna S: Unusual case of acute appendicitis with left upper quadrant abdominal pain. *Int J Surgery Case Rep*, 2012; 3(8): 399–401

Ueo reported a case of an adult Japanese patient with acute appendicitis who had complete duodenal obstruction, high fever, and middle abdominal pain in intestinal malrotation. There was an inflammatory appendix and fibrous adhesion in the duodenojejunal junction [1]. Intestinal malrotation and situs inversus can cause a diagnostic dilemma if acute abdominal symptoms develop. Intraabdominal structures may have inverted position and thus may easily mislead the surgeon during physical examinations. When patients with asymptomatic undiagnosed gastrointestinal malrotation clinically present with abdominal symptoms, accurate diagnosis and definitive therapy may be delayed; thus, the risk of morbidity and mortality increases [10–12].

In the presence of a mobile cecum, the appendix can be in a variety of locations. In our patient, this situation caused duodenal obstruction without abdominal pain. This report reminds us that presentation of appendicitis can be extremely varied.

Conclusions

Appendicitis accompanied with malrotation is rare and can lead to gastric outlet obstruction; this condition is not characterized by any symptom except for ileus. One must kept in mind that this type of case, which was previously reported only in adult patients, can also be observed in children.

Conflict of interest

The authors declare that they have no conflicts of interest.