


CLINICAL ARTICLE

Adverse Tissue Reactions and Metal Ion Behavior After Small-Head Metasul Hip Arthroplasty: A Long-Term Follow-Up Study

Tsunehito Ishida, MD, PhD¹ , Toshiyuki Tateiwa, MD, PhD¹, Yasuhito Takahashi, PhD^{1,2}, Yohei Nishikawa, MD¹, Takaaki Shishido, MD, PhD¹, Toshinori Masaoka, MD, PhD¹, Kengo Yamamoto, MD, PhD¹

Department of ¹Orthopedic Surgery and ²Bone and Joint Biomaterial Research, Tokyo Medical University, Tokyo, Japan

Objective: To investigate the long-term survivorship, incidence of adverse reactions to metal debris (ARMD), and metal ion behavior in patients who underwent small-head Metasul metal-on-metal (MoM) total hip arthroplasty (THA).

Methods: Between February 1998 and September 2003, a retrospective study was performed on 43 consecutive patients (43 hips) who underwent unilateral cementless Metasul MoM THAs at our institution. Of them, 35 patients (nine males and 26 females) who were available for follow-up more than 15 years after THA were enrolled in this study and underwent metal artifact reduction sequence magnetic resonance imaging (MARS-MRI) to identify ARMD. The mean age at surgery of the patients was 59.7 years old (range, 31–83). Clinical and radiographic outcomes were evaluated retrospectively. Clinical examinations were conducted using the Harris Hip Score (HHS). Serum cobalt (Co) and chromium (Cr) ion levels and Co/Cr ratio were assessed at different postoperative periods of <5, 5–10, 11–14, and ≥15 years.

Results: The mean follow-up period for the 35 patients included was 18.1 years (range, 15–22). The mean HHS significantly improved from 44.6 ± 11.3 points preoperatively to 89.4 ± 7.9 points at the final follow-up ($P < 0.0001$). ARMD was found in 20% of the patients using MARS-MRI. No signs of stem loosening were found clinically or radiographically, whereas cup loosening and ARMD were observed in three patients (9%), for whom revision THAs were performed. The Kaplan–Meier survival rates with revision for any reason as the endpoint were 90.9% at 5 years, 84.8% at 10 years, 84.8% at 15 years (95% CI, 67.1–93.6), and 70.3% at 20 years (95% CI, 43.6–87.0). The survival rates with revision for ARMD as the endpoint were 100% at 5 years, 96.6% at 10 years, 96.6% at 15 years (95% CI, 77.2–99.7), and 80.1% at 20 years (95% CI, 45.3–95.2). Serum Co ion level peaked at 5–10 years after THA, which was significantly higher than that <5 years; however, it decreased to the initial level after 15 years. In contrast, serum Cr ion level significantly increased at 5–10 years and then remained almost constant. Significant differences in Cr ion levels (1.0 vs 2.0 $\mu\text{g/L}$, $P = 0.024$) and Co/Cr ratio (1.3 vs 0.9, $P = 0.037$) were found between non-ARMD and ARMD patients at >11 years postoperatively.

Conclusion: Our results suggest that increased Cr ion levels and decreased Co/Cr ratio may be signs of ARMD in patients who underwent small-head Metasul MoM THA.

Key words: Adverse reactions to metal debris; Metal ion levels; Metal-on-metal; Metasul; Small head

Introduction

Metal-on-metal (MoM) bearing was clinically introduced in the 1960s to prevent periprosthetic osteolysis and

aseptic loosening associated with implant articulation wear in total hip arthroplasty (THA). However, the first-generation MoM THA exhibited unsatisfactory outcomes due to a high

Address for correspondence Tsunehito Ishida MD, PhD, Department of Orthopedic Surgery, Tokyo Medical University, 6-7-1 Nishishinjuku, Shinjuku-ku, Tokyo 160-0023, Japan Tel: +81-3-3342-6111; Fax: +81-3-3342-5295; Email: tsune725@aol.com

Disclosure: The authors declare no competing interests.

Received 11 February 2021; accepted 3 June 2021

rate of failure associated with frictional torque complications resulting in locking and seizing with subsequent corrosion of the bearing surfaces¹. The second-generation MoM bearings such as Metasul (Sulzer Medica, currently Zimmer-Biomet, Warsaw, IN, USA) were developed in the late 1980s using updated technologies including improved bearing tolerances and surface finish, contact-area location, and elimination of bearing recesses². Metasul bearing couple comprised a 28-mm wrought-forged high-carbon (0.2%–0.25%) cobalt-chromium (CoCr) head, and the acetabular liner housed in a non-crosslinked polyethylene insert, which was held in a titanium alloy metal shell. Metasul MoM bearings have shown promising outcomes both *in vivo* and *in vitro*. According to the past retrieval study, high-carbon Metasul bearings showed approximately 60 times less wear than metal-on-conventional polyethylene bearings in THA³. Several clinical studies have reported implant survival rates of over 90% with a minimum of 10 years of follow-up^{4–8}.

Despite the excellent wear resistance of metal bearings, some of the latest generation MoM THA have exhibited unexpected high failure rates due to soft tissue inflammatory and immunological reactions to metal debris and ions (adverse reactions to metal debris [ARMD])^{9–11}. The complication includes necrosis, lymphocytosis, vasculitis, and the development of pseudotumors. ARMD is commonly associated with mechanically assisted metal corrosion at the head–neck taper interface as well as articulation wear^{12–14}. Several studies have identified the use of large heads (≥ 36 mm) as a significant risk factor for ARMD in MoM THA because of large frictional torque at the modular head–neck interfaces^{15–17}. ARMD is often asymptomatic, and its careful screening is hardly performed before clear symptoms appear. Metal artifact reduced sequence magnetic resonance imaging (MARS-MRI) is the gold standard in diagnosing ARMD, which has some disadvantages including the increased scan time, the obscuration of periprosthetic tissues by metal artifacts, and the cost¹⁸. The levels of blood metal ions have also been monitored for evaluating the risk of ARMD. Cobalt (Co) and chromium (Cr) ion levels and their ratios are considered important biomarkers for diagnosing ARMD^{19–21}. It has been generally understood in large diameter MoM THA that the higher the serum Co ion level and Co/Cr ratio, the higher the risk of ARMD²². Bosker *et al.*²³ reported that patients with elevated serum Co and Cr ion levels had a four-times greater risk of developing a pseudotumor following large-head MoM THA. Haddad *et al.* reported that 75%–90% of patients with metal ion levels of either Co or Cr above 4 ug/L have ARMD-related complications²⁴. A metal ion level greater than 4.5–7.0 ppb (Cr or Co) is currently considered as a potential threshold for the occurrence of abnormal wear, and also as a trigger for a MARS MRI scan or revision surgery^{25,26}. On the other hand, one clinical study performed by Griffin *et al.*²⁷ showed no significant correlation between levels of metal ions and severity of ARMD at the time of the revision, whereas a positive correlation was found between implantation time and the severity of ARMD. The findings suggest that ARMD may be more dependent on an *in vivo* time of metal exposure rather than on its amount. In this context, they questioned the effectiveness and reliability of the ion

level threshold (7 ppb) as a predictor for soft tissue damage based on their results of low sensitivity (Co 61%, Cr 31%) and specificity (Co 58%, Cr 76%) in detecting ARMD. One potential limitation of metal ion measurement is that individual patients have an undefined variable biologic response to metal ions and particles^{26, 27}. Another limitation can be considered as a time-dependent change in the balance between ion release from the device and ion excretion or storage (or potential consumption for tissue reactions)^{28, 29}. Therefore, it is of great importance to continuously monitor the long-term metal ion behavior following MoM THA.

Furthermore, in contrast to many reports on large head MoM, the long-term behaviors of *in vivo* metal ions after small-head MoM (≤ 28 mm) have been much less studied. Considering less frictional torques generated at head–neck junction and articulation, patients receiving small-head MoM THA may entail a smaller risk of ARMD than those receiving large-head MoM^{15–17}. Some studies have shown excellent survivorship in small-head MoM bearings^{4–8}. An Australian Orthopaedic Association National Joint Replacement Registry (AOANJRR) database-based study showed a significantly lower revision rate after small-head MoM THA than after large-head MoM THA. In addition, the cumulative percentages of revision surgeries for ARMD at 15 years were 0.8% (95% CI, 0.8–1.4) for small heads and 12.4% (95% CI, 11.4–13.7) for large heads¹⁷. However, other recent studies have highlighted the late onset of ARMD in small-head MoM THAs, resulting in reduced long-term survivorship^{30–32}.

In consideration of the above background, we performed the long-term follow-up study on small-head Metasul MoM THA, which was specifically designed in order to clarify the following: (i) the implant survivorship; (ii) incidence of ARMD; and (iii) serum metal ion levels over time. Based on the results, we also attempted to consider the diagnostic potential of metal ion measurement in identifying ARMD.

Materials and Methods

Inclusion and Exclusion Criteria

The inclusion criteria were defined as follows: (i) patients treated with unilateral primary cementless THA; (ii) patients with small-head (28 mm) MoM Metasul bearings; and (iii) patients with complete clinical, radiographic evaluation and MARS-MRI screening for ARMD.

The exclusion criteria were as follows: (i) patients with a history of metal hypersensitivity; and (ii) patients with renal dysfunction potentially affecting serum metal ion levels.

Patients

The institutional review board of our hospital approved this study. We retrospectively collected the medical records included 43 patients who underwent unilateral cementless MoM THAs using small-head (28 mm) Metasul bearings at our institution between February 1998 and September 2003. Among these patients, four died due to reasons unrelated to THA, and four had missing follow-up data for more than

10 years postoperatively. The remaining 35 patients were included in this study and were followed up at a minimum period of 15 years.

Surgery

All surgeries were performed on by three senior surgeons (KY, TS, TM) under general anesthesia in the lateral position with a posterior approach. Primary cementless THA was performed with a Metasul MoM bearing in all patients. A cementless straight-tapered stem with a Natural Hip femoral stem (Zimmer-Biomet) was used as the femoral component combined with a 28 mm modular CoCr head in all patients. The femoral component is a proximally porous-coated titanium alloy implant, and its neck was designed with a 12/14 taper. The target acetabular position during surgery was 40° of inclination and 20° of anteversion angle.

Outcome Measures

Clinical and Radiographic Evaluation

Clinical and radiographic outcomes at a mean follow-up period of 18.1 years (range: 15–22) were evaluated retrospectively. Clinical examinations were conducted using the Harris Hip Score (HHS) (range, 0–100), which was evaluated as poor (<70), fair (70 to 79), good (80 to 89), and excellent

(90 to 100). Standard anteroposterior pelvic and lateral radiographs of the hip were obtained at the follow-up visits to evaluate periprosthetic osteolysis and loosening of the component in the seven femoral zones of stem defined by Gruen *et al.*³³ and three acetabular zones defined by DeLee and Charnley³⁴. Cup inclination and anteversion angles were measured using the Martell Hip Analysis Suite software, version 8.0.4.5 (University of Chicago, IL, USA).

Metal Ion Measurement

The patients' serum Co and Cr ion levels were measured using inductively coupled plasma mass spectrometry at Mayo Medical Laboratories (Rochester, MN, USA) and atomic absorption spectrometry at LSI Medience Corporation (Tokyo, Japan). The serum Co and Cr ion levels were examined at different postoperative periods of <5 (median: 1.9, n = 21), 5–10 (median: 7.5, n = 26), 11–14 (median: 12.3, n = 28), and ≥15 (median: 16.5, n = 19) years. Note that we considered <5, 5–10, and >11 years as the early-, mid-, and long-term follow-up periods, respectively. The metal ion levels after revision surgery were excluded from this analysis. The detection limit of both Co and Cr ions was 0.1 µg/L. Additionally, the Co/Cr ratio was analyzed for each patient.

MARS-MRI Evaluation

Cross-sectional imaging using metal artifact reduction sequence magnetic resonance imaging (MARS-MRI) using a 1.5-T scanner (MAGNETOM Avanto fit; Siemens Healthineers, Erlangen, Germany) was performed at a mean postoperative period of 12 years (±standard deviation: 1.5) to diagnose ARMD for all patients (including asymptomatic screening). According to the MRI classification described by Hauptfleisch *et al.*³⁵, ARMD was defined as any cystic or solid mass (pseudotumor) with the definite presence of a cyst wall in continuity with the hip joint, excluding isolated distension or thickening of a non-communicating trochanteric bursa. This classification system was based on the compositions and wall thicknesses of the reactive masses on MARS-MRI, dividing them into the following three groups: type I, thin-walled (<3 mm) cystic masses; type II, thick-walled (>3 mm) cystic masses; and type III, predominantly solid masses.

TABLE 1 Patients' demographics

Demographic	Value
Number of patients	35
Gender (male: female)	9: 26
Diagnosis (OA: RA: ION)	26: 5: 4
Age at surgery* (year)	59.7 (±9.0)
Follow-up time* (year)	18.1 (±2.4)
Body mass index* (kg/m ²)	23.8 (±3.3)
Cup inclination* (°)	42.9 (±9.0)
Cup anteversion* (°)	15.8 (±12.1)

*Values are presented as the mean (± SD).; ION, idiopathic osteonecrosis of the femoral head; OA, osteoarthritis; RA, rheumatoid arthritis.

TABLE 2 Detailed information on revised hips

Case	Age/ Gender	Diagnosis	Reason for revision	Time to revision (years)	Revision procedure
1	55/Male	ION	Infection	5	Two-stage revision of cup and stem
2	58/Male	ION	Infection	5	Two-stage revision of cup and stem
3	69/Female	OA	Recurrent dislocation	5	Revision with cup and head exchange
4	64/Female	OA	Infection	6	Two-stage revision of cup and stem
5	62/Female	OA	Symptomatic ARMD with cup loosening	7	Revision with cup exchange
6	61/Female	OA	Symptomatic ARMD with cup loosening	16	Revision with cup and bone graft
7	50/Female	RA	Symptomatic ARMD with cup loosening	19	Revision with cup and bone graft

ARMD, adverse reactions to metal debris; ION, idiopathic osteonecrosis of the femoral head; OA, osteoarthritis; RA, Rheumatoid arthritis.

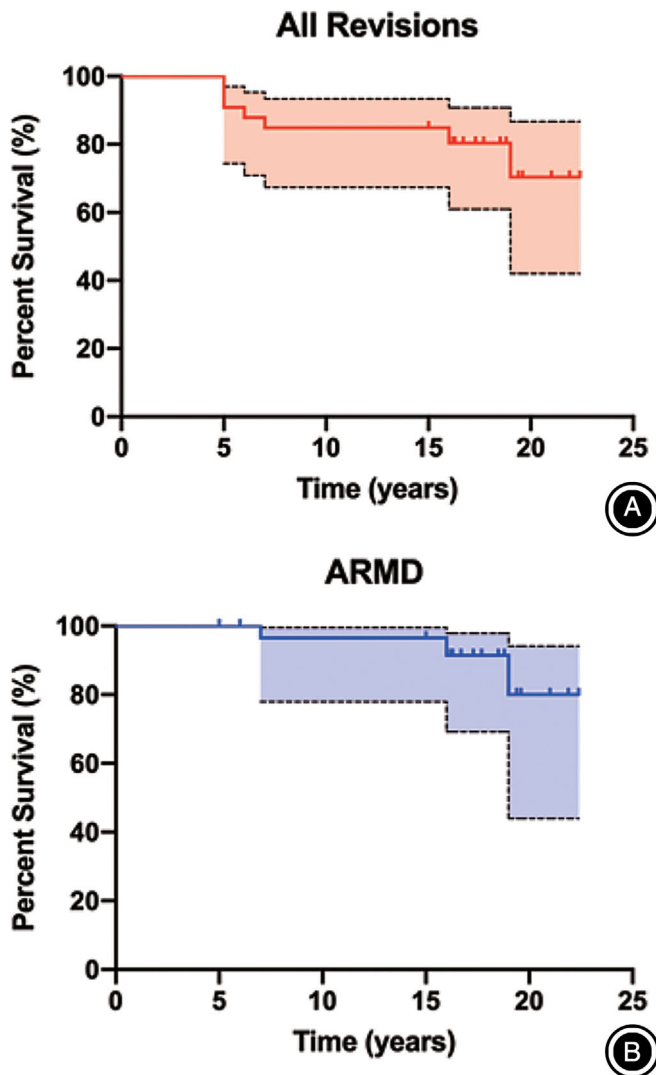


Fig. 1 Kaplan–Meier survival curves for any revision (A) and for adverse reaction to metal debris (ARMD) (B) as the end points. Dotted lines represent 95% confidence interval (CI). The (A) indicates the survival rates of 90.9% at 5 years, 84.8% at 10 years, 84.8% at 15 years (95% CI, 67.1–93.6), and 70.3% at 20 years (95% CI, 43.6–87.0). The (B) indicates the survival rates of 100% at 5 years, 96.6% at 10 years, 96.6% at 15 years (95% CI, 77.2–99.7), and 80.1% at 20 years (95% CI, 45.3–95.2).

Statistical Analysis

All statistical analyses were performed using the GraphPad Prism software, version 8.4.1 (GraphPad Software Inc., San Diego, CA, USA). The Kaplan–Meier survivorship analysis with 95% confidence intervals (95% CI) was conducted on revision surgeries for any reason and ARMD as the end-points. The Wilcoxon signed-rank and Fisher’s exact tests were conducted to assess the statistical differences in gender percentage between non-ARMD and ARMD patients. The Mann–Whitney U test was conducted to compare the

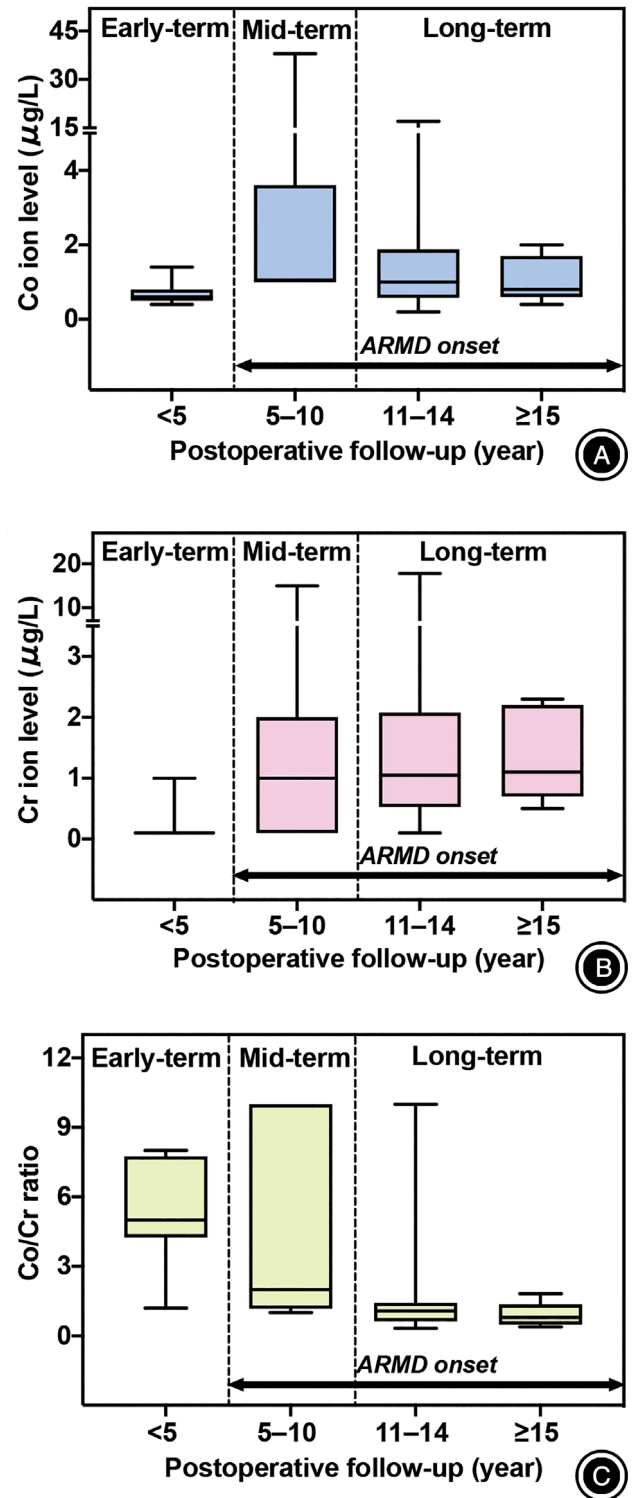


Fig. 2 Box plots showing changes in serum cobalt (Co) ion (A), chromium (Cr) ion (B), and Co/Cr ratio (C) over the postoperative period. Co ion level peaked at 5–10 years after surgery and then decreased continuously until the final follow-up. Cr ion levels increased at 5–10 years and remained almost constant until the final follow-up. Co/Cr ratio was the highest at <5 years and then decreased continuously.

TABLE 3 The median values and interquartile ranges of serum cobalt (Co), chromium (Cr) ion levels and Co/Cr ratios at <5, 5–10, 11–14, and ≥15 years postoperatively

Variable	Follow-up (years)	Median (IQR)	Kruskal-Wallis test P-value	Dunn's <i>post hoc</i> test P-value
Co ion level (µg/L)	<5	0.6 (0.5–0.8)	0.0002*	<5y vs 5–10y (< 0.0001*) vs 11–14y (0.0381*) vs ≥15 y (> 0.9999)
	5–10	1.1 (1.0–3.6)		
	11–14	1.0 (0.7–1.8)		
	≥15	0.8 (0.8–1.4)		
Cr ion level (µg/L)	<5	0.2 (0.1–0.2)	<0.0001*	<5y vs 5–10y (0.0028*) vs 11–14y (< 0.0001*) vs ≥15 y (0.0157*)
	5–10	1.0 (0.1–2.0)		
	11–14	1.1 (0.6–2.0)		
	≥15	1.1 (0.9–2.1)		
Co/Cr ratio	<5	5.0 (4.8–7.3)	<0.0001*	<5y vs 5–10y (>0.9999) vs 11–14y (< 0.0001*) vs ≥15 y (0.0019*)
	5–10	2.0 (1.3–10.0)		
	11–14	1.1 (0.8–1.4)		
	≥15	0.8 (0.6–0.9)		

Their P-values were also provided among the different follow-up periods according to the Kruskal–Wallis test with Dunn's *post hoc* test.; IQR, interquartile range.; * $P < 0.05$.

demographic data between non-ARMD and ARMD patients. The Kruskal–Wallis test was conducted to compare serum Co and Cr ion levels and Co/Cr ratios among the different postoperative periods, and Dunn's multiple comparisons test was used for their pairwise *post hoc* comparisons. Probability (P) values of <0.05 denote statistical significance.

Results

General Results

The mean follow-up period for the 35 included patients (nine males and 26 females) was 18.1 ± 2.4 years (range, 15–22). The mean age at surgery of the patients was 59.7 years old (range, 31–83). The mean HHS significantly improved from 44.6 ± 11.3 points preoperatively to 89.4 ± 7.9 points at the final follow-up ($P < 0.0001$). The patients' demographics and clinical characteristics are summarized in Table 1.

Radiographic Outcomes

The osteolytic lesions of the stem and cup were observed in five patients (14%) and four patients (11%), respectively. All femoral osteolysis were located at the Gruen zone 1 or 7, whereas the acetabular osteolysis were at DeLee and Charnley zone 2 (two patients) and zone 3 (two patients). No signs of stem loosening were found clinically or radiographically, whereas cup loosening was observed in three patients (9%), for whom revision THAs were performed (Table 2). The mean cup inclination and anteversion angles were $42.9^\circ \pm 9.0^\circ$ and $15.8^\circ \pm 12.1^\circ$, respectively (Table 1).

Complications

In total, seven patients underwent revision surgery for recurrent dislocation (one patient), infection (three patients), and ARMD (three patients) at the postoperative years of 5, 5–6,

and 7–19, respectively. The detailed information of all complications in the revised cases are summarized in Table 2.

Implant Survivorship Evaluation

The Kaplan–Meier survival rates with revision for any reason as the endpoint were 90.9% at 5 years, 84.8% at 10 years, 84.8% at 15 years (95% CI, 67.1–93.6), and 70.3% at 20 years (95% CI, 43.6–87.0) (Fig. 1A). The survival rates with revision for ARMD as the endpoint were 100% at 5 years, 96.6% at 10 years, 96.6% at 15 years (95% CI, 77.2–99.7), and 80.1% at 20 years (95% CI, 45.3–95.2) (Fig. 1B).

Metal Ion Levels

Figure 2 shows the serum Co and Cr ion levels and their ratio in all patients examined at different follow-up periods after THA. The median Co and Cr ion levels were lowest at the initial follow-up period of <5 years and increased at 5–10 years (Fig. 2A,B). The median and interquartile range (IQR) of serum Co ion levels (µg/L) were 0.6 (IQR, 0.5–0.8), 1.1 (IQR, 1.0–3.6), 1.0 (IQR, 0.7–1.8), and 0.8 (IQR, 0.8–1.4) at <5, 5–10, 11–14, and ≥15 years, respectively (Table 3). Alternatively, the median serum Cr ion levels (µg/L) were 0.2 (IQR, 0.1–0.2), 1.0 (IQR, 0.1–2.0), 1.1 (IQR, 0.6–2.0), 1.1 (IQR, 0.9–2.1) at <5, 5–10, 11–14, and ≥15 years, respectively. The Kruskal–Wallis test revealed significant differences in serum Co and Cr ion levels among the different follow-up periods ($P = 0.0002$ and $P < 0.0001$, respectively). *Post hoc* analysis using Dunn's multiple comparison tests showed that serum Co ion levels detected at 5–10 years ($P < 0.0001$) and 11–14 years ($P = 0.0381$) were 83% and 67% higher significantly than the Co ion levels at <5 years, whereas serum Cr ion levels detected at 5–10 years ($P = 0.0028$), 11–14 years ($P < 0.0001$), and ≥15 years ($P = 0.0157$) were 400%, 450%, and 450% higher significantly than those detected at <5 years. However, the median

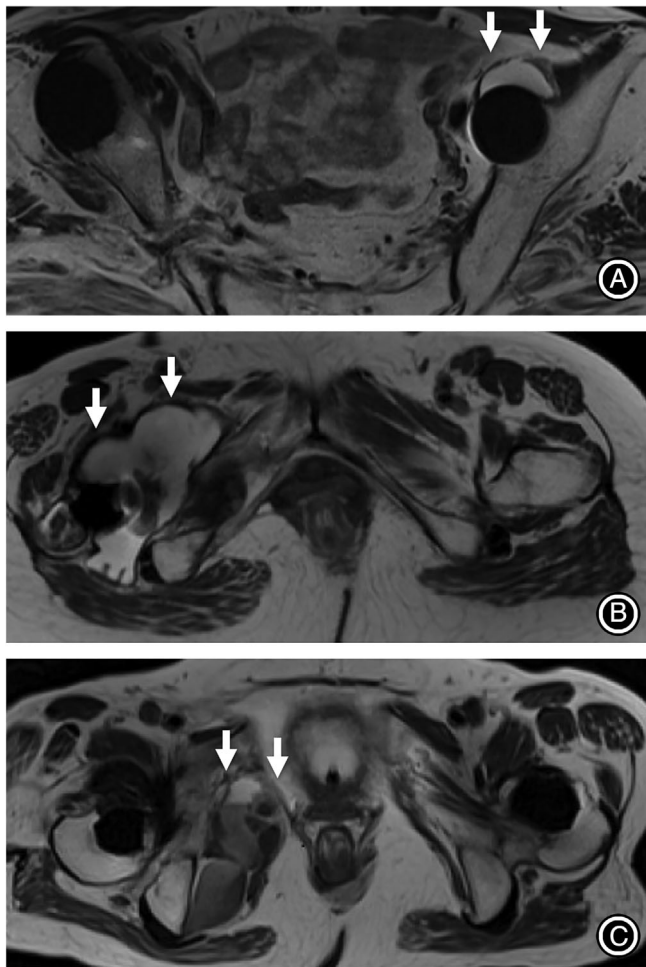


Fig. 3 Representative postoperative metal artifact reduction sequence magnetic resonance imaging (MARS-MRI) findings of pseudotumor (arrows) classified as Hauptfleisch's types I (A), II (B), and III (C), respectively. The (A) indicates the coronal MARS-MRI of a 63-year-old female with type I pseudotumor located in front of the left acetabular cup. She was asymptomatic and had an excellent Harris Hip Score (HHS) of 90 points at the final follow-up of 18 years. The (B) indicates the coronal MARS-MRI of a 61-year-old female with a type II pseudotumor located around the femoral neck of the right stem. She underwent revision surgery due to a symptomatic adverse reaction to metal debris (ARMD) with cup loosening at 16 years postoperatively (Case 6 in Table 2). The (C) indicates the coronal MARS-MRI of a 50-year-old female with type III pseudotumor located in the right pelvic cavity. She underwent revision surgery due to symptomatic ARMD with cup loosening at 19 years postoperatively (Case 7 in Table 2).

Co/Cr ratio was the highest at <5 years and then decreased continuously (Fig. 2C, Table 3). Significant differences in the serum ion levels over time were more sensitively detected using the Co/Cr ratio instead of each ion level, and *post hoc* analysis showed the significant differences in the Co/Cr ratio between <5 and 11–14 years (78% decrease, $P < 0.0001$), between <5

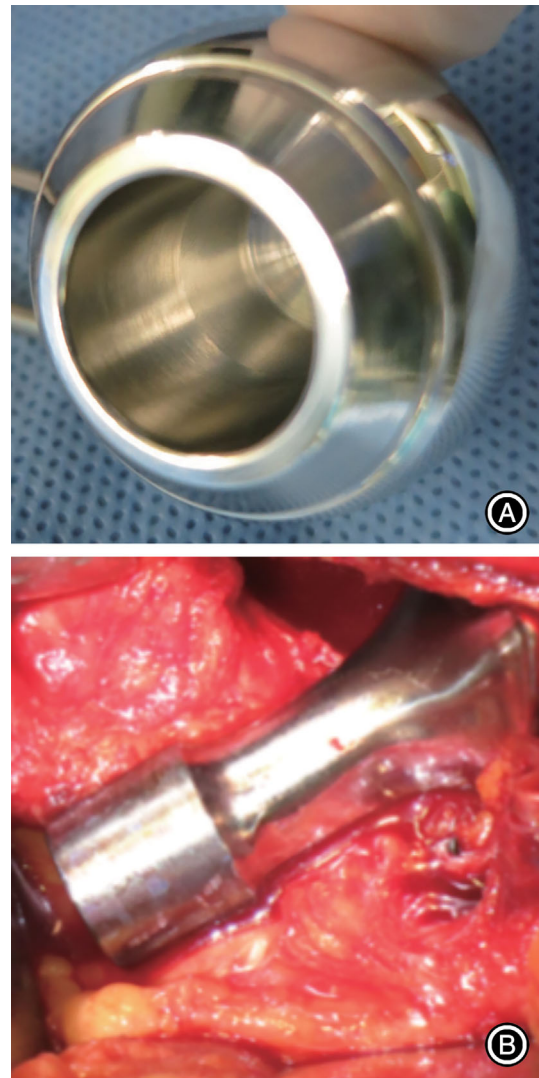


Fig. 4 The representative photographs showing no obvious fretting corrosion at taper bore interface of the retrieved metal head (A) and stem trunnion (B) in a patient with adverse reaction to metal debris (ARMD) (Case 6 in Table 2).

and ≥ 15 years (84% decrease, $P = 0.0019$), between 5–10 and 11–14 years (45% decrease, $P = 0.0116$), and between 5–10 and ≥ 15 years (60% decrease, $P = 0.0313$).

Comparisons Between Non-ARMD and ARMD Patients

MARS-MRI identified pseudotumor formation in seven patients (20%), suggesting the incidence of ARMD. The pseudotumor was classified as type I (four patients, 57%), type II (one patient, 14%), and type III (two patients, 29%) (Fig. 3A–C). Three of the seven patients underwent revision surgery for symptomatic ARMD and component loosening (Table 2). No obvious signs of fretting corrosion were intra-operatively found at their head–neck junctions in the three

TABLE 4 Characteristics of patients with and without adverse reaction to metal debris (ARMD)

Variable	Non-ARMD (n = 28)	ARMD (n = 7)	P-value
Age at surgery*	58.9 (± 9.0)	60.3 (± 6.7)	0.692
Female gender (%)	65	100	0.069
BMI* (kg/m ²)	23.4 (± 3.3)	23.6 (± 2.8)	0.853
eGFR* (mL/min/1.73 m ²)	76.9 (± 25.2)	76.3 (± 26.9)	0.942
HHS* (points)	90 (± 6.6)	87 (± 8.8)	0.482
Cup inclination* (°)	42 (± 5.8)	47 (± 8.5)	0.296
Cup anteversion* (°)	15 (± 11.8)	18 (± 12.2)	0.587
Co ion level† at the mid-term (µg/L)	1.0 (0.7–1.2)	1.0 (1.0–11.3)	0.179
Co ion level† at the long-term (µg/L)	1.0 (0.1–1.0)	1.8 (1–2.3)	0.158
Cr ion level† at the mid-term (µg/L)	0.9 (0.8–1.6)	1.0 (0.3–6.5)	0.233
Cr ion level† at the long-term (µg/L)	1.0 (0.3–1.8)	2.0 (1.1–2.6)	0.024‡
Co/Cr ratio† at the mid-term	1.6 (1.0–5.0)	2.1 (1.1–4.4)	0.654
Co/Cr ratio† at the long-term	1.3 (1.0–2.9)	0.9 (0.7–1.2)	0.037‡

Co, cobalt; Cr, chromium; BMI, Body mass index; HHS, Harris hip score; eGFR, Estimated glomerular filtration rate; * Values are presented as the mean (±SD).; † Values are presented as the median (IQR).; ‡ P < 0.05.

ARMD patients (Fig. 4). The remaining four patients had asymptomatic ARMD and had no hip pain, for whom, therefore, revision THA was not performed. The clinical characteristics of non-ARMD and ARMD patients are shown in Table 4. Since all cases of ARMD were found beyond the mid-term follow-ups, the serum ion levels were compared between the groups by the relevant periods (Table 4, Fig. 5). The median serum Co and Cr ion levels and their ratio at the mid-term follow-up (5–10 years) did not differ significantly between non-ARMD and ARMD groups ($P = 0.179$, $P = 0.233$, and $P = 0.654$, respectively). Serum Co ion levels at the long-term follow-up did not significantly differ between the two groups ($P = 0.158$). However, significant differences were found in the serum Cr ion levels and Co/Cr ratio at the long-term follow-up ($P = 0.024$ and $P = 0.037$, respectively). Consequently, the serum Cr ion level was 100% higher (1.0 µg/L [IQR, 0.3–1.8] vs 2.0 µg/L [IQR, 1.1–2.6]), and the Co/Cr ratio was 31% lower (1.3 [IQR, 1.0–2.9] vs 0.9 [IQR, 0.7–1.2]) in the ARMD group than those in the non-ARMD group.

Discussion

The Long-Term Survivorship and Incidence of ARMD

The excellent mid- and long-term outcomes of MoM THA using 28 mm Metasul bearings have been reported. The survival rates were 90%–96% with revision surgery as the endpoint^{4–8}. Besides, the revision rates associated with ARMD have been reported as 0%–3% only within 15 years following small-head MoM THA^{5,6,8,17,36}. A recent study of AOANJRR data showed a significantly lower revision rate after small-head MoM THA than after large-head (>32 mm) MoM THA¹⁷. The revision rates were 27.4% and 8.5% at a 14-year follow-up period of large-head MoM THA and a 15-year follow-up period of small-head MoM THA with a hazard ratio

of 5.18 (95% CI, 4.1–6.5; $P < 0.001$); additionally, the cumulative percentages of revision surgeries for ARMD at 15 years were 0.8% (95% CI, 0.8–1.4) for small heads and 12.4% (95% CI, 11.4–13.7) for large heads. Nevertheless, even using small-head MoM bearings, other recent studies have cautioned elevated metal ion levels and the late onset of ARMD after a long-term *in vivo* service^{30–32}. Lombardi *et al.*³¹ reported the outcomes of small-head MoM THA using the M2a Taper system (Zimmer-Biomet), whose survival rates at 10, 15, and 19 years were 96%, 92%, and 73%, respectively. Revision THAs were performed in 14/20 hips (70%) due to ARMD. Reiner *et al.*³² reported that ARMD was found in 41% of the patients implanted with Metasul followed up at a mean period of 15.5 years. In this study, ARMD was found in 20% of the patients implanted with Metasul. Accordingly, the revision rate increased rapidly from 4% to 20% between 15 and 20 years after THA, and the survival rate decreased from 84.8% to 70.3% (Fig. 1). Our results suggest that ARMD is a major postoperative complication beyond 15 years even after small-head MoM THA.

The Long-Term Behavior of Metal Ions and Diagnostic Potential of ARMD

Most investigations on the association between serum metal ion levels and ARMD have involved large-head MoM THA^{10,11,23}. Bosker *et al.*²³ reported that patients with elevated serum metal ion levels had a four-times greater risk of developing a pseudotumor following large-head MoM THA. Conversely, the long-term behavior of serum metal ion levels after small-head MoM THA is not fully understood. Waldstein *et al.*³⁷ showed that the median serum Co ion level remained low (1.04 µg/L [IQR, 0.64–1.70]) 21 years after implantation of 28 mm Metasul bearing, which was not significantly different from that at 5 years (0.70 µg/L [IQR, 0.2–1.8])³⁸. In this study, serum Co ion levels at ≥15 years were

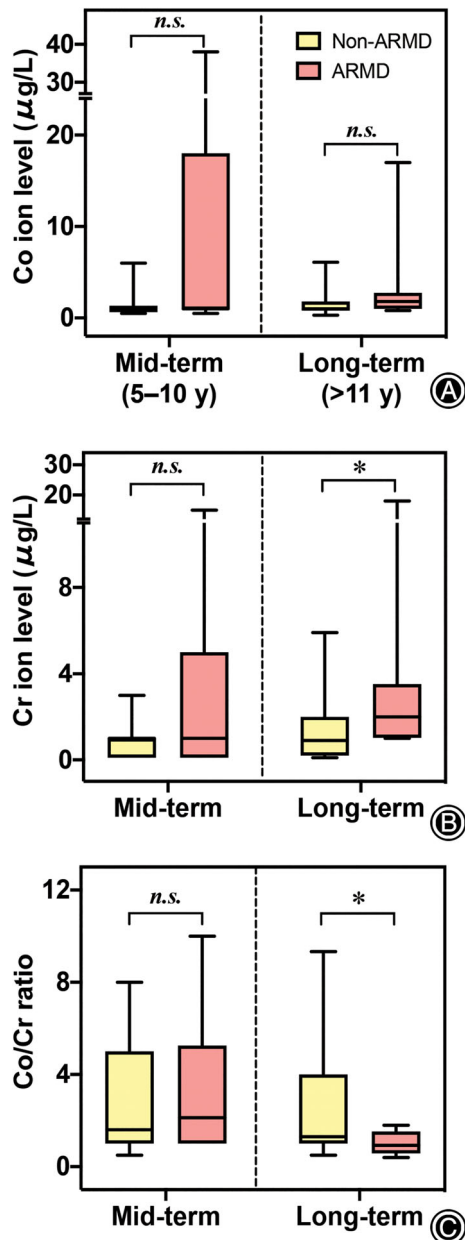


Fig. 5 Box plots showing comparisons of serum cobalt (Co) ion (A), chromium (Cr) ion (B), and Co/Cr ratio (C) between patients with and without adverse reaction to metal debris (ARMD) at the mid- and long-term follow-ups. The asterisks and *n.s.* represent $P < 0.05$ and not significant, respectively. Significant differences in Cr ion levels (1.0 vs 2.0 $\mu\text{g/L}$, $P = 0.024$) and Co/Cr ratio (1.3 vs 0.9, $P = 0.037$) were noted between non-ARMD and ARMD patients at >11 years postoperatively.

also as low as those at <5 years although serum Cr ion levels were significantly higher (Table 3). Note that the Co ion level peaked at 5–10 years, which was significantly higher than that at <5 years, but it decreased to the initial level after

15 years. Alternatively, Cr ion levels increased significantly at 5–10 years and remained almost constant. This trend should reflect a time-dependent change in the balance between ion release from the device and ion excretion or storage (or potential consumption for tissue reactions)^{28,29}. Renal excretion is the primary clearance mode of Co and Cr ions, but the kidney reportedly eliminates Co ions at a higher rate compared with Cr ions^{28,29}. Furthermore, Cr ions bind more readily to proteins than Co ions, allowing Cr accumulation in local soft tissues and precipitation as chromium orthophosphate³⁹. In these contexts, Cr ions might last longer *in vivo* than Co ions, suggesting the potential of Cr ion level as a more stable indicator. According to the current guideline⁴⁰, serum Co and Cr ion levels of <2.0 $\mu\text{g/L}$ are of no clinical concern. Possible biological effects of high Cr ion levels are DNA and chromosomal damage, reduction in CD8⁺ lymphocyte levels, and ARMD, although these effects remain controversial⁴¹.

Besides the serum ion levels, the Co/Cr ratio is an informative parameter to understand the long-term behavior of the released metal ions in the serum. The Co/Cr ratio of the base material within the ASTM guidelines ranges from 1.9 to 2.6 depending on the exact composition of the alloy used by the manufacturer⁴². Numerous studies^{19–21,43–45} have reported that, in large-head MoM THA, ARMD onset is associated with mechanically assisted (fretting) corrosion at the head–neck interfaces and its related metal ion release. The fretting corrosion is an irreversible interfacial reaction of material, often resulting in an active metal ion release. Under such circumstances, ion release might continuously occur at a faster rate than excretion and tissue reaction, increasing serum Co levels and the Co/Cr ratio in large-head MoM components being susceptible to large frictional torque at the modular head–neck interfaces^{19–21}. Nevertheless, the fact that our results obtained from the small-head MoM THA did not follow the previously reported trend is interesting. The median Co/Cr ratio (5.0 [IQR, 4.8–7.3]) was highest within the first 5 years after THA, a value higher than that of the base material, and then decreased thereafter (Table 3, Fig. 2C). In fact, no obvious fretting corrosion was intraoperatively confirmed in the three ARMD patients during the revision surgeries, which might be due to less frictional torque at the head–neck junction associated with the use of the small-head bearings¹⁷. Thus, in our cases, articulating surfaces were probably a primary source of metal ion release rather than the head–neck interfaces. Because the wear rates of Metasul MoM articulation decreased with implantation time⁴⁶, the Co/Cr ratio peaked within the first 5 years possibly due to the initial wear and then decreased possibly due to the reduced wear rate and increased ion excretion (primarily Co ion) and/or tissue reaction.

The overall trend of the Co/Cr ratio can be associated with the difference in ion release–excretion behavior between Co and Cr (i.e. a faster excretion of Co than Cr ion). Renner *et al.*⁴⁷ have reported that Co/Cr ratios above 1.71 were predictive of osteolysis; however, ARMD was not studied as an

outcome. In our study on small-head Metasul bearings, most ARMD patients had Co/Cr ratios below 1.71 and a lower median Co/Cr ratio than non-ARMD patients. In fact, Fehring *et al.*⁴² have highlighted that the interplay between ion release and excretion makes the use of this ratio difficult as a diagnostic tool. Nevertheless, in our cases, the Co/Cr ratio succeeded in obtaining the statistical significances between non-ARMD and ARMD patients after long-term follow-up (Table 4, Fig. 5). Thus, compared with the initial Co/Cr ratio at <5 years, its significant decrease might be associated with an increased risk of ARMD after small-head MoM THA. Additionally, the Co/Cr ratio may be a more sensitive predictor than serum Co levels alone, showing no significance at ≥ 15 years. These results suggest that, in small-head MoM THA, monitoring both Co and Cr ion levels is important for a more stable prediction of the ARMD risk.

Limitations of the Study

This study had the following limitations. First, the number of patients followed up over 15 years was relatively small (35 patients). Second, the infection rate was relatively high (Table 2), contributing to the reduced overall survival rate of the patients implanted with Metasul bearings. MoM bearings have been noted to be associated with a higher risk of periprosthetic infection than metal-on-polyethylene and ceramic-on-ceramic bearings⁴⁸. However, in the patients with infections in this study, the serum Co and Cr levels at

the time of infection onset (within 5–6 years) remained below the level of clinical concern ($< 2.0 \mu\text{g/L}$)⁴⁰. All three revision cases due to infection were at high risk of infection; two cases of idiopathic osteonecrosis of the femoral head (Cases 1 and 2 in Table 2) were on high-dose steroids, and the other case of osteoarthritis (Case 4 in Table 2) was complicated with severe diabetes mellitus. Thus, metal ions released from Metasul bearings are unlikely to be associated with infection.

Conclusion

The risk of ARMD-related revision surgery significantly increased following MoM THA using 28 mm Metasul bearings beyond the postoperative period of 15 years. The long-term *in vivo* behavior differs between Co and Cr, and increased Cr ion levels and decreased Co/Cr ratio may be signs of ARMD. Our results suggest that careful screening is needed not only for large-head MoM patients but also for small-head MoM patients according to metal ion levels and clinical imaging findings.

Acknowledgements

Not applicable.

Ethics Approval and Consent to Participate

The institutional review board of our hospital approved this study.

References

- McKee GK, Chen SC. The statistics of the McKee-Farrar method of total hip replacement. *Clin Orthop Relat Res*, 1973, 95: 26–33.
- Weber BG. Experience with the Metasul total hip bearing system. *Clin Orthop Relat Res*, 1996, 329: 69–77.
- Sieber HP, Rieker CB, Kötting P. Analysis of 118 second-generation metal-on-metal retrieved hip implants. *J Bone Joint Surg Br*, 1999, 81: 46–50.
- Hwang KT, Kim YH, Kim YS, Choi IY. Is second generation metal-on-metal primary total hip arthroplasty with a 28 mm head a worthy option?: a 12-to 18-year follow-up study. *J Arthroplasty*, 2013, 28: 1828–1833.
- Randelli F, Banci L, D'Anna A, Visentin O, Randelli G. Cementless Metasul metal-on-metal total hip arthroplasties at 13 years. *J Arthroplasty*, 2012, 27: 186–192.
- Delaunay CP, Putman S, Puliéro B, Bégin M, Migaud H, Bonnet F. Cementless total hip arthroplasty with Metasul bearings provides good results in active young patients: a concise followup. *Clin Orthop Relat Res*, 2016, 474: 2126–2133.
- Moon JK, Kim Y, Hwang KT, Yang JH, Oh YH, Kim YH. Long-term outcomes after metal-on-metal total hip arthroplasty with a 28-mm head: a 17-to 23-year follow-up study of a previous report. *J Arthroplasty*, 2018, 33: 2165–2172.
- Eswaramoorthy V, Moonot P, Kalairajah Y, Biant LC, Field RE. The Metasul metal-on-metal articulation in primary total hip replacement: clinical and radiological results at ten years. *J Bone Joint Surg Br*, 2008, 90: 1278–1283.
- de Steiger RN, Miller LN, Prosser GH, Graves SE, Davidson DC, Stanford TE. Poor outcome of revised resurfacing hip arthroplasty: 397 cases from the Australian Joint Replacement Registry. *Acta Orthop*, 2010, 81: 72–76.
- Matharu GS, Eskelinen A, Judge A, Pandit HG, Murray DW. Revision surgery of metal-on-metal hip arthroplasties for adverse reactions to metal debris: a clinical update. *Acta Orthop*, 2018, 89: 278–288.
- Liddle AD, Satchithananda K, Henckel J, *et al.* Revision of metal-on-metal hip arthroplasty in a tertiary center: a prospective study of 39 hips with between 1 and 4 years of follow-up. *Acta Orthop*, 2013, 84: 237–245.
- Pandit H, Glyn-Jones S, McLardy-Smith P, *et al.* Pseudotumours associated with metal-on-metal hip resurfacings. *J Bone Joint Surg Br*, 2008, 90: 847–851.
- Gruber FW, Böck A, Trattng S, Lintner F, Ritschl P. Cystic lesion of the groin due to metallosis: a rare long-term complication of metal-on-metal total hip arthroplasty. *J Arthroplasty*, 2007, 22: 923–927.
- De Smet K, De Haan R, Calistri A, *et al.* Metal ion measurement as a diagnostic tool to identify problems with metal-on-metal hip resurfacing. *J Bone Joint Surg Am*, 2008, 90: 202–208.
- Sugano N, Iida H, Akiyama H, *et al.* Nationwide investigation into adverse tissue reactions to metal debris after metal-on-metal total hip arthroplasty in Japan. *J Orthop Sci*, 2014, 19: 85–89.
- Smith AJ, Dieppe P, Vernon K, Porter M, Blom AW. Failure rates of stemmed metal-on-metal hip replacements: analysis of data from the National Joint Registry of England and Wales. *Lancet*, 2012, 379: 1199–1204.
- de Steiger R, Peng A, Lewis P, Graves S. What is the long-term survival for primary THA with small-head metal-on-metal bearings? *Clin Orthop Relat Res*, 2018, 476: 1231–1237.
- Kwon YM, Dimitriou D, Liow MHL, Tsai TY, Li G. Is ultrasound as useful as metal artifact reduction sequence magnetic resonance imaging in longitudinal surveillance of metal-on-metal hip arthroplasty patients? *J Arthroplasty*, 2016, 31: 1821–1827.
- Kwon YM, Tsai TY, Leone WA, Liow MHL. Sensitivity and specificity of metal ion levels in predicting “pseudotumors” due to taper corrosion in patients with dual taper modular total hip arthroplasty. *J Arthroplasty*, 2017, 32: 996–1000.
- Bayley N, Khan H, Grosso P, *et al.* What are the predictors and prevalence of pseudotumor and elevated metal ions after large-diameter metal-on-metal THA? *Clin Orthop Relat Res*, 2015, 473: 477–484.
- Hothi HS, Berber R, Whittaker RK, Blunn GW, Skinner JA, Hart AJ. The relationship between cobalt/chromium ratios and the high prevalence of head-stem junction corrosion in metal-on-metal total hip arthroplasty. *J Arthroplasty*, 2016, 31: 1123–1127.
- Laaksonen I, Galea VP, Donahue GS, Matuszak SJ, Muratoglu O, Malchau H. The cobalt/chromium ratio provides a similar diagnostic value to a low cobalt threshold in predicting adverse local tissue reactions in patients with metal-on-metal hip arthroplasty. *J Arthroplasty*, 2018, 33: 3020–3024.
- Bosker BH, Ettema HB, Boomsma MF, Kollen BJ, Maas M, Verheyen CCPM. High incidence of pseudotumor formation after large-diameter metal-on-metal total hip replacement: a prospective cohort study. *J Bone Joint Surg Br*, 2012, 94: 755–761.
- Haddad FS, Thakrar RR, Hart AJ, *et al.* Metal-on-metal bearings: the evidence so far. *J Bone Joint Surg Br*, 2011, 93: 572–579.

- 25.** Matharu GS, Judge A, Eskelinen A, Murray DW, Pandit HG. What is appropriate surveillance for metal-on-metal hip arthroplasty patients? *Acta Orthop*, 2018, 89: 29–39.
- 26.** Griffin WL. Metal ion levels: how can they help us? *J Arthroplasty*, 2014, 29: 659–660.
- 27.** Griffin WL, Fehring TK, Kudrna JC, *et al.* Are metal ion levels a useful trigger for surgical intervention? *J Arthroplasty*, 2012, 27: 32–36.
- 28.** Daniel J, Ziaee H, Pradhan C, Pynsent PB, McMinn DJ. Renal clearance of cobalt in relation to the use of metal-on-metal bearings in hip arthroplasty. *J Bone Joint Surg Am*, 2010, 92: 840–845.
- 29.** Galea VP, Laaksonen I, Matuszak SJ, Connelly JW, Muratoglu O, Malchau H. Mid-term changes in blood metal ion levels after articular surface replacement arthroplasty of the hip. *Bone Joint J*, 2017, 99: 33–40.
- 30.** Hwang KT, Kim YH, Kim YS, Ryu JA. Prevalence of a soft-tissue lesion after small head metal-on-metal total hip replacement: 13-to 19-year follow-up study. *Bone Joint J*, 2014, 96: 1594–1599.
- 31.** Lombardi AV, Berend KR, Adams JB, Satterwhite KL. Adverse reactions to metal on metal are not exclusive to large heads in total hip arthroplasty. *Clin Orthop Relat Res*, 2016, 474: 432–440.
- 32.** Reiner T, Do TD, Klotz MC, *et al.* MRI findings in patients after small-head metal-on-metal total hip arthroplasty with a minimum follow-up of 10 years. *J Bone Joint Surg Am*, 2017, 99: 1540–1546.
- 33.** Gruen TA, McNeice GM, Amstutz HC. “Modes of failure” of cemented stem-type femoral components: a radiographic analysis of loosening. *Clin Orthop Relat Res*, 1979, 141: 17–27.
- 34.** DeLee JG, Charnley J. Radiological demarcation of cemented sockets in total hip replacement. *Clin Orthop Relat Res*, 1976, 121: 20–32.
- 35.** Hauptfleisch J, Pandit H, Grammatopoulos G, Gill HS, Murray DW, Ostlere S. A MRI classification of periprosthetic soft tissue masses (pseudotumours) associated with metal-on-metal resurfacing hip arthroplasty. *Skeletal Radiol*, 2012, 41: 149–155.
- 36.** Carr AM, de Steiger R. Osteolysis in patients with a metal-on-metal hip arthroplasty. *ANZ J Surg*, 2008, 78: 144–147.
- 37.** Waldstein W, Koller U, Springer B, *et al.* Serum cobalt concentrations remain at low levels at a minimum of 20 years following metal-on-metal total hip arthroplasty. *Bone Joint Res*, 2020, 9: 145–150.
- 38.** Brodner W, Bitzan P, Meisinger V, Kaider A, Gottsauner-Wolf F, Kotz R. Serum cobalt levels after metal-on-metal total hip arthroplasty. *J Bone Joint Surg Am*, 2003, 85: 2168–2173.
- 39.** Newton AW, Ranganath L, Armstrong C, Peter V, Roberts NB. Differential distribution of cobalt, chromium, and nickel between whole blood, plasma and urine in patients after metal-on-metal (MoM) hip arthroplasty. *J Orthop Res*, 2012, 30: 1640–1646.
- 40.** Hannemann F, Hartmann A, Schmitt J, *et al.* European multidisciplinary consensus statement on the use and monitoring of metal-on-metal bearings for total hip replacement and hip resurfacing. *Orthop Traumatol Surg Res*, 2013, 99: 263–271.
- 41.** Afolaranmi GA, Tettey J, Meek RM, Grant MH. Release of chromium from orthopaedic arthroplasties. *Open Orthop J*, 2008, 2: 10–18.
- 42.** Fehring TK, Carter JL, Fehring KA, Odum SM, Griffin WL. Cobalt to chromium ratio is not a key marker for adverse local tissue reaction (ALTR) in metal on metal hips. *J Arthroplasty*, 2015, 30: 107–109.
- 43.** Berstock JR, Whitehouse MR, Duncan CP. Trunnion corrosion: what surgeons need to know in 2018. *Bone Joint J*, 2018, 100-B: 44–49.
- 44.** Atrey A, Hart A, Hussain N, Waite J, Shepherd AJ, Young S. 601 metal-on-metal total hip replacements with 36 mm heads a 5 minimum year follow up: levels of ARMD remain low despite a comprehensive screening program. *J Orthop*, 2016, 14: 108–114.
- 45.** Witt F, Bosker BH, Bishop NE, Ettema HB, Verheyen CCPM, Morlock MM. The relation between titanium taper corrosion and cobalt-chromium bearing wear in large-head metal-on-metal total hip prostheses: a retrieval study. *J Bone Joint Surg Am*, 2014, 96: e157.
- 46.** Rieker C, Köttig P. In vivo tribological performance of 231 metal-on-metal hip articulations. *Hip Int*, 2002, 12: 73–76.
- 47.** Renner L, Schmidt-Braekling T, Faschingbauer M, Boettner F. Do cobalt and chromium levels predict osteolysis in metal-on-metal total hip arthroplasty? *Arch Orthop Trauma Surg*, 2016, 136: 1657–1662.
- 48.** Bordini B, Stea S, Castagnini F, Busanelli L, Giardina F, Toni A. The influence of bearing surfaces on periprosthetic hip infections: analysis of thirty nine thousand, two hundred and six cementless total hip arthroplasties. *Int Orthop*, 2019, 43: 103–109.