

## Reviews

# Slow Orthostatic Tremor: Review of the Current Evidence

Anhar Hassan, MBBCh, FRACP<sup>1\*</sup> & John Caviness, MD<sup>2</sup>

<sup>1</sup>Department of Neurology, Mayo Clinic, Rochester, MN, USA, <sup>2</sup>Department of Neurology, Mayo Clinic, Scottsdale, AZ, USA

## Abstract

**Background:** Orthostatic tremor (OT) is defined as tremor in the legs and trunk evoked during standing. While the classical description is tremor of  $\geq 13$  Hz, slower frequencies are recognized. There is disagreement as to whether the latter represents a slow variant of classical OT, or different tremor disorder(s) given frequent coexistent neurological disease.

**Methods:** A systematic literature search of PubMed was performed in February 2019 for “slow orthostatic tremor” and related terms which generated 573 abstracts, of which 61 were included.

**Results:** Between 1970 and 2019, there were 70 cases of electrophysiologically confirmed slow OT. Two-thirds were female, of mean age 60 years (range 26–86), and mean disease duration 6 years (range 0–32). One-third of cases were isolated, and two-thirds had a coexistent disorder(s), including parkinsonism (30%), ataxia (12%), and dystonia (10%). Postural arm tremor was present in 34%. Median tremor frequency was 6–7 Hz (range 3–12). Tremor bursts ranged from 50 to 150 ms duration, and were alternating or synchronous in antagonistic and/or analogous muscles. Low and high coherences were reported. Five cases (7%) had coexistent classical OT. Clonazepam was the most effective medication across all frequencies, and levodopa was effective for 4–7 Hz OT with coexistent parkinsonism. Two cases resolved with the treatment of Graves’ disease. Electrophysiology and imaging predominantly support a central tremor generator.

**Discussion:** While multiple lines of evidence separate slow OT from classical OT, clinical and electrophysiological overlap may occur. Primary and secondary causes are identified, similar to classical OT. Further exploration to clarify these slow OT subtypes, clinically and neurophysiologically, is proposed.

**Keywords:** Shaky legs, pseudo-orthostatic, tremor, slow variant, electrophysiology

**Citation:** Hassan A, Caviness J. Slow orthostatic tremor: review of the current evidence. Tremor Other Hyperkinet Mov. 2019; 9. doi: 10.7916/tohm.v0.721

\*To whom correspondence should be addressed. E-mail: hassan.anhar@mayo.edu

**Editor:** Elan D. Louis, Yale University, USA

**Received:** August 23, 2019; **Accepted:** October 7, 2019; **Published:** November 26, 2019

**Copyright:** © 2019 Hassan A, Caviness J. This is an open-access article distributed under the terms of the Creative Commons Attribution–Noncommercial–No Derivatives License, which permits the user to copy, distribute, and transmit the work provided that the original authors and source are credited; that no commercial use is made of the work; and that the work is not altered or transformed.

**Funding:** None.

**Financial Disclosures:** None.

**Conflicts of Interest:** The authors report no conflicts of interest.

**Ethics Statement:** Not applicable for this category of article.

## Introduction

Orthostatic tremor (OT) is defined by the key symptom of tremor during standing. The classical description is of a high-frequency tremor syndrome, typically 13–18 Hz, requiring electrophysiological confirmation.<sup>1</sup> It is subdivided into primary OT when it occurs in isolation, or primary OT-plus when it is associated with other neurological disorders.<sup>1,2</sup> In 2018, the Consensus Statement on the Classification of Tremors from the Task Force of Tremor of the International Parkinson and Movement Disorder Society proposed the term “pseudo-orthostatic tremor” to describe all orthostatic tremors  $< 13$  Hz. This replaced previous various terminology of “slow orthostatic tremor” or “tremor in orthostatism.”<sup>1</sup>

There is much debate as to whether this represents a slow variant of classical OT, or a different tremor disorder(s).

## Historical perspective

The first clinical and electrophysiological description of OT was by Pazzaglia et al. in 1970. They reported three patients with leg tremor and unsteadiness emerging upon standing and relieved by leaning, ranging from 10 to 16 Hz on surface electromyography (EMG).<sup>3</sup> Fourteen years later, Heilman coined the term “orthostatic tremor” to clinically describe three similar cases.<sup>4,5</sup> The term “slow OT” was first used by Thompson et al. in 1986, with electrophysiological capture of both slow (8 Hz) and

high (16 Hz) frequency tremors in a patient.<sup>6</sup> In the same year, slow OT was described in a family with essential tremor (ET).<sup>7</sup> Other observations emerged of cases with either classical or slow OT with coexistent ET, of which some responded to ET medications.<sup>8</sup> It was proposed that OT was an ET variant, regardless of frequency.<sup>8-10</sup> although others argued against this.<sup>11,12</sup> Meanwhile, other reports emerged of lateralized slow OT occurring prior to or coincident with a diagnosis of parkinsonism, of similar slow frequency to coexistent upper limb rest tremor, and with exquisite responsiveness to levodopa, suggesting it was a parkinsonian variant.<sup>13-17</sup> In 2007, Thomas et al. proposed “pseudo-orthostatic tremor” to describe slow OT affecting both legs, with dramatic levodopa response, to differentiate it from parkinsonism-related OT and classical OT.<sup>18</sup>

In the last 5 years, further divisions of slow OT were proposed. In 2014, Erro et al. expanded the clinical and electrophysiological description of OT, and recommended the term “pseudo-orthostatic tremor” for all OT <13 Hz to reflect differences from primary OT.<sup>19</sup> In 2015, Rigby et al. described the first series of slow OT patients divided into low (<10 Hz) and intermediate (10–13 Hz) frequencies, and contrasted with primary OT (>13 Hz). The clinical features of patients with low and intermediate frequencies differed from primary OT, whereas the electrophysiological features of intermediate frequencies were more closely aligned to high frequencies.<sup>20</sup> In 2016, Ure subdivided slow OT into three subtypes: “primary” (i.e., idiopathic), “secondary” (i.e., symptomatic), and “pseudo-orthostatic” tremor (asymmetry, parkinsonism, and levodopa-responsive).<sup>21</sup> This brings us to the current timeframe, where the Consensus Statement took a new direction, again reducing all orthostatic tremors <13 Hz to the term “pseudo-orthostatic tremor.”<sup>21</sup>

There is obvious widespread disagreement (nomenclature, classification, proposed pathophysiology) with unresolved questions and contradictory ideas. Should all tremors under 13 Hz be considered a single entity? If so, what is the optimal terminology? Why not simply “slow OT” to reflect the lower frequency if they are to be lumped together? The term pseudo-orthostatic tremor might be misinterpreted as functional tremor, or that patients were not truly orthostatic or weightbearing at the time of tremor; should this term be best reserved for re-emergent parkinsonian leg tremor while standing? Electrophysiology is currently the gold standard diagnosis, but is not accessible to many neurologists. Therefore, are there clinical clues that could favor slow OT over other mimickers of shaky legs? Should it be subdivided into parkinsonian variant, ET variant, slow variant of classical OT, ataxia variant, or other variant based on clinical and electrophysiological features?

We thus aim to methodically review the literature on slow OT to assess whether some of these questions can be answered, and to propose strategies to address unresolved issues. For the purposes of this article, we will use the term “slow OT” to reflect any orthostatic tremor less than 13 Hz.

## Methods

A systematic literature search of PubMed was performed in February 2019 using the search terms “slow orthostatic tremor” (22 articles), “orthostatic tremor” (402 articles), “shaky legs” (21 articles), “shaky leg syndrome” (91 articles), and “pseudo-orthostatic tremor” (4 articles).

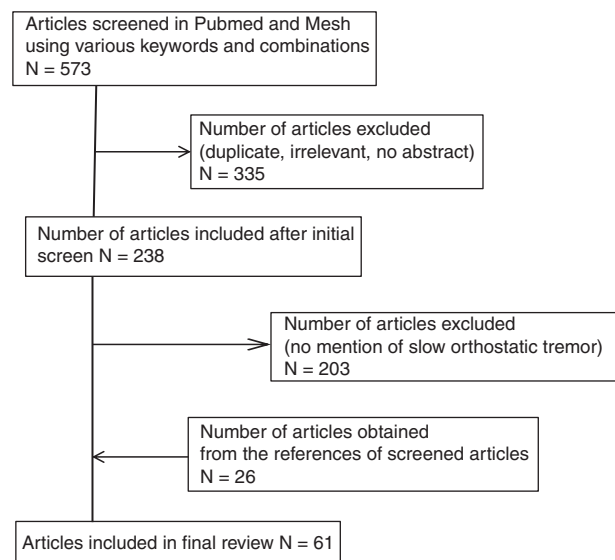
The MeSH entry term of “primary orthostatic tremor” is a unique identifier for both orthostatic tremor and shaky legs since 2010 and yielded 34 articles. A manual review of all 573 abstracts was then performed to exclude duplicated articles and irrelevant articles (e.g. orthostatic hypotension, animal studies). We included non-English papers. In total, 239 reviews, case reports, case series, and clinical studies (from 1970 to 2019) were evaluated. We reviewed any additional papers obtained from references that did not appear in our initial search criteria. We then selected the articles relating to “slow orthostatic tremor” and included these in our final analysis, of which there were 61 articles. We tabulated all cases with sufficient details to extract demographic, clinical, and electrophysiology data (Figure 1).

## Results

A total of 70 patients with well-characterized slow OT with electrophysiological confirmation were identified in the literature between 1970 and 2019. Table 1 shows their demographic, clinical, treatment, and imaging features, and Table 2 shows their electrophysiological features. There were a number of other slow OT cases identified within mixed case series of classical and slow OT, but lacked sufficient individual details to tabulate.<sup>9,22-25</sup>

## Clinical

Of the 70 slow OT cases, two-thirds were female (44F; 26M; 63%), of mean age 60 years (range 26–86), and mean disease duration of 6 years (range 0–32). These demographics are similar to classical OT.<sup>26</sup> Almost all patients reported tremor or unsteadiness provoked by standing, that disappeared with walking, and was absent with sitting and lying. Slow OT persisted walking backwards in one patient,<sup>27</sup> although this aspect was not studied by others. It could worsen when walking slowed down.<sup>6</sup>



**Figure 1. Flow diagram of literature search.** Summary of steps involved in the literature search leading to final number of articles included.

**Table 1. Demographic, Clinical, Treatment, and Imaging Characteristics of Slow OT (Listed in Order of EMG Frequency) (N = 70 cases)**

Case Author	EMG Frequency, Hz	Age, years	Sex	Duration, years	Family History	Other Tremor	Other Neurologic Disorder	Treatment Helpful	Treatment Failure	Imaging
1 Kang <sup>24</sup>	3-4	NA	F				Parkinsonism	Levodopa		
2 Hegde <sup>33</sup>	3-4	69	M	NA	None	None	Cerebellar ataxia; novel CSF and serum Abs	IVIg	Valproate, Clonazepam, Gabapentin, Thiamine, B12, Methylprednisolone	MRI brain normal
3 Bonnet <sup>49</sup>	3.2-3.5	45	M	10	NA	Rest arms and legs, and postural arms and legs, L>R, 3.2-3.5 Hz	Cerebellar ataxia, SCA3	Levodopa		
4 Oda <sup>14</sup>	4	79	F	NA	NA	NA	Parkinsonism, dementia, L Babiniski sign	Levodopa	Haloperidol	MRI brain vascular pathology
5 Yoo <sup>30</sup>	4	48	M	3	None	Rest hand and foot, crossed, 4-6 Hz	PD	None reported	Dopamine agonist, Propranolol, Anticholinergic, Clonazepam	PET DAT asymmetric decreased uptake posterior putamen caudate, L>R
6 Baker <sup>36</sup>	4	38	F	NA	NA	None	MS, spasticity, ataxia	Clonazepam, Leviracetam, Levodopa, Gabapentin		MRI brain L brachium pontis enhancing lesion, periventricular lesions
7 Stitt <sup>46</sup>	4-4.5	79	F	3	None	None	Alexander disease; asymmetric spastic quadriparesis	None tried	None tried	MRI brain medulla atrophy, hyperintensity pons, medulla, upper cervical cord; MRA head and neck normal

Table 1 continued

**Table 1. (Continued) Demographic, Clinical, Treatment, and Imaging Characteristics of Slow OT (Listed in Order of EMG Frequency) (N = 70 cases)**

Case Author	EMG Frequency, Hz	Age, years	Sex	Duration, years	Family History	Other Tremor	Other Neurologic Disorder	Treatment Helpful	Treatment Failure	Imaging
8 Yokota <sup>32</sup>	4.4–4.8	67	F	5	Head tremor	Voice 4.8–8.8 Hz, head, postural hand			Perphenazine, Propranolol, Trihexiphenidyl, Levodopa, Clonazepam, Apomorphine	MRI brain generalized atrophy
9 Kim <sup>55</sup>	4–5	68	F						Alprazolam, Propranolol, Clonazepam	
10 Kim <sup>16</sup>	4–5	45	F	2	None	Rest hand and legs 4–5 Hz	Parkinsonism	Trihexiphenidyl	Propranolol	MRI brain normal
11 Setta <sup>48</sup>	4–5 (coexistent 14 Hz)	63	F	7	None	Postural arm 4 Hz	Cerebellar ataxia		Propranolol, Primidone, Clonazepam	CT brain – cerebellar atrophy
12 Kang <sup>34</sup>	4–5	^	F				Parkinsonism	Clonazepam	Benzotropine	
13 Kobylecki <sup>31</sup>	4–5	53	F	4	#	Postural arms, head	Dystonia	Alcohol, SSRI, Metoprolol, Trihexiphenidyl		
14 Leu-Semenescu <sup>17</sup>	4.3–5.0	54	F	6	NA	Rest arm L	PD	Clonazepam, Levodopa	NA	NA
15 Setta <sup>48</sup>	4–6 (coexistent 15 Hz)	61	F	5	None	Postural arm 4–5 Hz	Cerebellar ataxia		Propranolol, Primidone, Isoniazid, Valproic acid, Clonazepam	MRI brain cerebellar atrophy
16 Lee <sup>56</sup>	4–6	81	F	0	NA	None	PD	Levodopa		MRI brain atrophy, periventricular ischemia
17 Bonnet <sup>49</sup>	4.2–6.5	45	F	12	NA	Postural tremor legs bilateral 8 Hz, Rest tremor arms and legs bilateral 4.3–5 Hz, neck tremor	Parkinsonism, dystonia (SCA3), without ataxia	Levodopa, piribedil, pramipexole		MRI brain mild vermian atrophy

Table 1 continued

**Table 1.** (Continued) Demographic, Clinical, Treatment, and Imaging Characteristics of Slow OT (Listed in Order of EMG Frequency) (N = 70 cases)

Case Author	EMG Frequency, Hz	Age, years	Sex	Duration, years	Family History	Other Tremor	Other Neurologic Disorder	Treatment Helpful	Treatment Failure	Imaging
18 Leu-Semencescu <sup>17</sup>	5	85	F	0	NA	Rest arm L, 6 Hz	PD	Clonazepam, Levodopa	NA	NA
19 Infante <sup>57</sup>	5	62	M	32	Parkin PD	Rest leg bilateral, L>R	Parkinsonism (Parkin homozygous mutation)	Levodopa	Trihexyphenidyl, Alprazolam	SPECT bilateral symmetric decreased striatal binding
20 Kobylecki <sup>31</sup>	5.3	43	M	8	#	Postural arm, head	Dystonia	Primidone, Alcohol	Clonazepam, Propranolol, Levodopa, Topiramate, Trihexyphenidyl	
21 Kobylecki <sup>31</sup>	5.8	70	F	6	#	Rest arm 4.6 Hz, rest leg 5.2 Hz, jaw tremor	None	Gabapentin, Clonazepam	Levodopa	SPECT normal
22 Alonso-Navarro <sup>35</sup>	5-6	80	F	1			Metoclopramide-induced			MRI brain normal
23 Leu-Semencescu <sup>17</sup>	5-6	57	F	0	NA	Rest arm L	PD	Clonazepam, Levodopa	NA	NA
24 Kobylecki <sup>31</sup>	5-6	50	F	6	#	Rest + postural arms, head	Dystonia	Propranolol, Levodopa		
25 Kang <sup>54</sup>	6	^	F				Parkinsonism	Propranolol	Clonazepam	
26 Thomas <sup>18</sup> / Invernizzi <sup>58</sup>	6.2	53	M	3	None	Rest hand	Parkinsonism, PEO, myopathy (POLG1 compound heterozygous mutations)	Propranolol, Pramipexole, Levodopa	Gabapentin	MRI brain normal; SPECT bilateral reduced dopamine uptake striatum, R>L
27 Kobylecki <sup>31</sup>	6.25	62	M	12	#	Rest + postural arms, 6.5 Hz	None	Levodopa	Trihexyphenidyl, Topiramate	SPECT normal

Table 1 continued

**Table 1.** (Continued) Demographic, Clinical, Treatment, and Imaging Characteristics of Slow OT (Listed in Order of EMG Frequency) (N = 70 cases)

Case Author	EMG Frequency, Hz	Age, years	Sex	Duration, years	Family History	Other Tremor	Other Neurologic Disorder	Treatment Helpful	Treatment Failure	Imaging
28 Thomas <sup>18</sup>	6.3	52	M	5	PD	NA	Parkin homozygous, PD	Pergolide, Levodopa	Gabapentin	SPECT reduced uptake posterior left striatum
29 Cleaves <sup>45</sup>	6.4	53	F	15	Hand tremor	Postural hand 7 Hz	ET	Primidone, Clonazepam	Diazepam, Propranolol	
30 Thomas <sup>18</sup>	6.7	47	F	13	None	Postural leg	PINK1 PD	Clonazepam, levodopa, ropinirole	Gabapentin	SPECT bilateral reduced striatal uptake, L>R
31 Thomas <sup>18</sup>	6.9	26	F	8	NA	Rest foot R	Parkinsonism	Camnabis, Levodopa	Alcohol, Gabapentin, Propranolol, Lorazepam, Carbamazepine, Topiramate, Acetazolamide	SPECT bilateral reduced striatal reuptake, maximal left putamen
32 Wee <sup>7</sup>	6-7	53	F	9	ET	Lips	None	Clonazepam	Metoprolol, Lorazepam, Amitriptyline, Anticholinergics, Alcohol, caffeine	CT head, isotope brain scan normal
33 Wee <sup>7</sup>	6-7	70	F	15	ET			Clonazepam	Propranolol, diazepam, perphenazine, lorazepam, clorazapate, amitriptyline	
34 Gabellini <sup>10</sup>	6-7	75	F	3	NA	Postural arm, tongue				
35 Gabellini <sup>10</sup>	6-7	64	M	3	NA					
36 Gabellini <sup>10</sup>	6-7	66	M	4	NA					
37 Gabellini <sup>10</sup>	6-7	59	M	3	NA	Postural arm	Hydrocephalus aqueduct stenosis, parkinsonism	Phenobarbitone, VP shunt		CT head hydrocephalus due to non-tumral aqueduct stenosis

Table 1 continued

**Table 1.** (Continued) Demographic, Clinical, Treatment, and Imaging Characteristics of Slow OT (Listed in Order of EMG Frequency) (N = 70 cases)

Case Author	EMG Frequency, Hz	Age, years	Sex	Duration, years	Family History	Other Tremor	Other Neurologic Disorder	Treatment Helpful	Treatment Failure	Imaging
38 Gabellini <sup>10</sup>	6–7	47	F	7	NA	Postural arm	Chronic relapsing polyradiculoneuropathy	Prednisone		CT head normal
39 Alonso-Navarro <sup>35</sup>	6–7	60	M	0.5			Sulpiride and thethylperazine induced	Stop DA blocker		
40 Kang <sup>54</sup>	6–7	^	F				Parkinsonism		Propranolol, Levodopa, Clonazepam, Benzotropine	
41 Kobylecki <sup>31</sup>	7–7.5	46	F	2	#	Postural arm, head	Dystonia	Trihexyphenidyl		
42 Kobylecki <sup>31</sup>	7.5	33	M	16	#	Rest + postural arms, head	Dystonia	Propranolol	Topiramate	
43 Benito Leon <sup>34</sup>	7–8	49	F	NA	NA	None	Right pontine cavernoma, resection with right CN 6, 7 palsies, ataxic gait	Clonazepam		MRI brain postsurgical changes of resected right pontine cavernoma
44 Leu-Semenescu <sup>17</sup>	7.5–9	76	F	8	NA	Rest arm bilateral 6.8 Hz	PD	Clonazepam	NA	NA
45 Thompson <sup>6</sup>	8 (coexistent 16 Hz)	55	M	NA	None	Postural arm 10 Hz	None	-	Alcohol	CT head normal
46 Deuschl <sup>40</sup>	8 (coexistent 16 Hz)	48	F	6	ET	Hand	-	Primidone	Benzodiazepine, Trazodone, Amitriptyline	-
47 Cano <sup>15</sup>	8 (coexistent 16 Hz)	54	M					Gabapentin		
48 Kobylecki <sup>31</sup>	8	77	F	15	#	Postural arm	Dystonia			
49 Mazzucchi <sup>39</sup>	8	70	F	1	NA	None	Graves' disease	Methimazole		MRI brain and spinal cord normal
50 Lin <sup>47</sup>	8–9	26	M	0.3	NA	None	Graves' disease	Methimazole	Clonazepam	MRI brain, T, LS spine normal

Table 1 continued

**Table 1. (Continued) Demographic, Clinical, Treatment, and Imaging Characteristics of Slow OT (Listed in Order of EMG Frequency) (N = 70 cases)**

Case Author	EMG Frequency, Hz	Age, years	Sex	Duration, years	Family History	Other Tremor	Other Neurologic Disorder	Treatment Helpful	Treatment Failure	Imaging
51 Uncini <sup>28</sup>	8–10	73	M	0.5	None	Postural hand		Primidone	Propranolol	CT head normal
52 Williams <sup>27</sup>	9	70	F	1.5	NA	Postural arm	Ataxia, mild cognitive impairment	NA	NA	SPECT normal; MRI Brain cerebellar atrophy
53–60 Rigby <sup>20</sup>	<10	75*	7F; 1M	2*	Tremor 3/8	Postural arm 6/8	None	Clonazepam, Gabapentin, Primidone	NA	
61 Coffeng <sup>29</sup>	10–11	86	M	0.5	NA	Postural arm	None	NA	NA	MRI brain age-related atrophy
62 Pazzaglia <sup>3</sup>	10–12	56	M				Parkinsonism, tabes dorsalis			
63 Pazzaglia <sup>3</sup>	10–12	66	M				Flaccid paralysis, parkinsonism			
64–69 Rigby <sup>20</sup>	10–13	69.5*	2F; 4M	8.0*	0	Postural arm 2/6	Spinal dural AVF, Cerebellar degeneration, autoimmune PQ antibodies, PN, myelopathy	Clonazepam, Gabapentin		
70 Fitzgerald <sup>8</sup>	12	70	M	5	ET	Postural hand 8–9 Hz	ET	Clonazepam, Phenobarbital	Primidone, Valproate	NA

\*Mean; ^Duration was calculated as age at diagnosis minus age at onset for some cases; +Invernizzi et al. reported case 3 in Thomas 2007 paper in more details; #Kobylecki et al. reported 2/8 with ET family history and 3/8 had co-contraction or irregular relationship between ipsilateral agonists/antagonists; ^Kang et al. reported mean age 59 years in case series. Abbreviations: AVF, Arteriovenous Fistula; ET, Essential Tremor; L, Left; LS, Lumbosacral; MS, Multiple Sclerosis; PD, Parkinson Disease; PEO, Progressive External Ophthalmoplegia; R, Right; T, Thoracic.



**Table 2. Electrophysiology Characteristics of Slow OT (Listed in Order of EMG Frequency) (*N* = 70 cases)**

Case	Author	EMG Frequency, Hz	Age, year	Sex	Electrophysiology Burst Duration, Other Comments	Coherence	Burst Pattern	Peripheral Reset?
1	Kang <sup>54</sup>	3–4	NA	F			R distal synchronous, L proximal alternating bursts	
2	Hegde <sup>33</sup>	3–4	69	M			Alternating bursts in corresponding TAs	
3	Bonnet <sup>49</sup>	3.2–3.5	45	M	OT and postural leg tremor had same frequency 3.2–3.5 Hz			
4	Oda <sup>14</sup>	4	79	F	Not evoked by muscle contraction against resistance		Alternating bursts in antagonist muscles. Synchronous in corresponding leg muscles.	Reset bilaterally by unilateral voluntary or passive leg movement
5	Yoo <sup>30</sup>	4	48	M			Asynchronous antagonistic muscle activation	
6	Baker <sup>36</sup>	4	38	F	100 ms bursts. Dominant peak 4 Hz and subharmonic 8 Hz, and 8–15 Hz subpeaks in left MG/TA	Significant unilateral and bilateral coherence at 4 Hz, 8–12 Hz, and 13–18 Hz range.		Patella tendon stimulation could not reset tremor
7	Stitt <sup>46</sup>	4–4.5	79	F	Longer duration EMG bursts. Did not transmit by leaning.		Synchronous bursts bilat TAs.	
8	Yokota <sup>32</sup>	4.4–4.8	67	F			Synchronous in corresponding leg muscles, alternating bursts in antagonist muscles	
9	Kim <sup>55</sup>	4–5	68	F				
10	Kim <sup>16</sup>	4–5	45	F			Alternating bursts in antagonistic muscle groups	
11	Setta <sup>48</sup>	4–5 (coexistent 14 Hz)	63	F	14 Hz tremor leg + paraspinals which intermittently slowed to 4–5 Hz		Synchronous bursts in bilateral quadriceps at 4–5 Hz	
12	Kang <sup>54</sup>	4–5	^	F			R>L, R synchronous and L alternating bursts	
13	Kobylecki <sup>31</sup>	4–5	53	F	150 msec bursts			
14	Leu-Semencescu <sup>17</sup>	4.3–5.0	54	F	90–120 ms bursts	Coherence 0.6 at 4.8 Hz	Symmetric, R/L alternating	
15	Setta <sup>48</sup>	4–6 (coexistent 15 Hz)	61	F	15 Hz tremor leg/paraspinals, occasionally slowed to 4–6 Hz			

Table 2 continued

**Table 2.** (Continued) **Electrophysiology Characteristics of Slow OT (Listed in Order of EMG Frequency)** (*N* = 70 cases)

Case	Author	EMG Frequency, Hz	Age, year	Sex	Electrophysiology	Coherence	Burst Pattern	Peripheral Reset?
					Burst Duration, Other Comments			
16	Lee <sup>56</sup>	4–6	81	F	50–120 ms bursts		Alternating bursts in analogous muscles (bilateral TAs), and right TA/MG, but synchronous is left TA/MG	
17	Bonnet <sup>49</sup>	4.2–6.5	45	F	OT slowed from 6.5 to 4.2 Hz over 8 yr follow-up. Rest tremor and OT had similar declining frequencies, 5.4 and 4.2 Hz			
18	Leu-Semenescu <sup>17</sup>	5	85	F	110–120 ms bursts, symmetric; Rest arm L, 6 Hz, 80 ms bursts		Bilateral burst synchrony	
19	Infante <sup>57</sup>	5	62	M			Agonist-antagonist leg muscles	
20	Kobylecki <sup>31</sup>	5.3	43	M	80 msec bursts			
21	Kobylecki <sup>31</sup>	5.8	70	F	80–100 msec bursts			
22	Alonso-Navarro <sup>35</sup>	5–6	80	F			Synchronous agonists and antagonists	
23	Leu-Semenescu <sup>17</sup>	5–6	57	F	80–100 ms bursts R leg only			
24	Kobylecki <sup>31</sup>	5–6	50	F	100–120 msec bursts, Dominant frequency 6 Hz, and subpeaks 12–13 Hz, 18–19 Hz	Significant bilateral coherence at 12–14 Hz and 17–18 Hz	Variation in burst duration and asymmetry with more distinct bursts on the R.	
25	Kang <sup>54</sup>	6	^	F			R>L, alternating bursts	
26	Thomas <sup>18</sup> / Invernizzi <sup>58</sup>	6.2	53	M	Subharmonic 8.1 Hz	Coherence 0.6–0.9 for 6.2 Hz vs. 0.32 for arm tremor		
27	Kobylecki <sup>31</sup>	6.25	62	M	60–80 msec bursts			
28	Thomas <sup>18</sup>	6.3	52	M	Subharmonic 10.4 Hz	Coherence 0.6–0.9		
29	Cleeves <sup>45</sup>	6.4	53	F			Synchronous antagonist muscles	Peripheral stimulation could not reset
30	Thomas <sup>18</sup>	6.7	47	F	Subharmonic 14.3 Hz	Coherence 0.6–0.9 at 6.7 Hz vs. 0.13 for arm tremor		
31	Thomas <sup>18</sup>	6.9	26	F	Subharmonic 18.2 Hz	Coherence 0.6–0.9		

*Table 2 continued*

**Table 2.** (Continued) **Electrophysiology Characteristics of Slow OT (Listed in Order of EMG Frequency)** (N = 70 cases)

Case	Author	EMG Frequency, Hz	Age, year	Sex	Electrophysiology	Coherence	Burst Pattern	Peripheral Reset?
					Burst Duration, Other Comments			
32	Wee <sup>7</sup>	6–7	53	F	6–7 Hz tremor also with legs contracted while seated		Synchronous EMG activity in antagonistic leg muscle pairs	Normal H reflex
33	Wee <sup>7</sup>	6–7	70	F	6–7 Hz tremor also with legs contracted while seated		Synchronous EMG activity in antagonistic leg muscle pairs	Normal H reflex
34	Gabellini <sup>10</sup>	6–7	75	F			Alternating and synchronous bursts antagonistic muscles	
35	Gabellini <sup>10</sup>	6–7	64	M	Tremor dissipates with walking		Alternating and synchronous bursts antagonistic muscles. Marked reduction of tremor during walking	
36	Gabellini <sup>10</sup>	6–7	66	M			Alternating and synchronous bursts antagonistic muscles	
37	Gabellini <sup>10</sup>	6–7	59	M			Alternating and synchronous bursts antagonistic muscles	
38	Gabellini <sup>10</sup>	6–7	47	F			Alternating and synchronous bursts antagonistic muscles. Tremor appeared more irregular	
39	Alonso-Navarro <sup>35</sup>	6–7	60	M			Synchronous agonists and antagonists	
40	Kang <sup>54</sup>	6–7	^	F			L>R, alternating bursts	
41	Kobylecki <sup>31</sup>	7–7.5	46	F	Dominant 7 Hz frequency.	Significant bilateral coherence at 15–17 Hz + and 20 Hz		
42	Kobylecki <sup>31</sup>	7.5	33	M				
43	Benito Leon <sup>34</sup>	7–8	49	F			Synchronous agonists and antagonists	
44	Leu-Semenescu <sup>17</sup>	7.5–9	76	F	80–100 ms bursts, symmetric			
45	Thompson <sup>6</sup>	8 (coexistent 16 Hz)	55	M	Predominantly 16 Hz tremor with intermittent halving of tremor to 8 Hz in quads coinciding with increased unsteadiness.		Alternating between antagonist muscles and synchronous in corresponding muscles for 16 Hz, but 8 Hz isolated to quads	Peripheral stimulation could not reset. Normal H reflex and sensory EPs

Table 2 continued

Table 2. (Continued) Electrophysiology Characteristics of Slow OT (Listed in Order of EMG Frequency) (N = 70 cases)

Case	Author	EMG Frequency, Hz	Age, year	Sex	Electrophysiology	Coherence	Burst Pattern	Peripheral Reset?
					Burst Duration, Other Comments			
46	Deuschl <sup>40</sup>	8 (coexistent 16 Hz)	48	F			Highly synchronous in leg muscles and arm muscles	
47	Cano <sup>15</sup>	8 (coexistent 16 Hz)	54	M	8 Hz + 16 Hz tremor			
48	Kobylecki <sup>31</sup>	8	77	F	50–60 msec bursts			
49	Mazzucchi <sup>59</sup>	8	70	F	80 msec bursts uniform		Alternating in agonist and antagonist muscles	Motor EP normal
50	Lin <sup>47</sup>	8–9	26	M				
51	Uncini <sup>28</sup>	8–10	73	M	Tremor with isometric contraction also.		Synchronous EMG bursts in antagonistic muscles; out of phase between antagonist muscle pairs and synchronous in corresponding muscles	Peripheral stimulation could not reset. Normal sensory NCS, H reflex latency, and peroneal EPs.
52	Williams <sup>27</sup>	9	70	F	50–100 ms. 15,22,35 Hz harmonics. Unilateral and bilateral coherence peaks at 9,15,22,35 Hz. Persisted walking backward.		Synchronous EMG bursts in bilateral gastrocnemius	
53–60	Rigby <sup>20</sup>	<10	75*	7F; 1M	Longer duration bursts	Coherence 0.53*		
61	Coffeng <sup>29</sup>	10–11	86	M			Synchronous bursts in R TA and quads, and L MG	
62	Pazzaglia <sup>3</sup>	10–12	56	M	Less regular contractions			
63	Pazzaglia <sup>3</sup>	10–12	66	M	Less regular contractions			
64–69	Rigby <sup>20</sup>	10–13	69.5*	2F; 4M	Shorter duration EMG bursts	Coherence 0.74*		
70	Fitzgerald <sup>8</sup>	12	70	M			Asynchronous bursts in both legs	

\*Mean; ^Kang et al. reported mean age 59 years in case series. Abbreviations: EP, Evoked Potentials; L, Left; MG, Medial Gastrocnemius; NCS, Nerve Conduction Studies; TA, Tibialis Anterior; R, Right.

**Table 3. Neurological and Medical Disorders Associated with Slow OT**

Parkinsonism <sup>18</sup>
Idiopathic Parkinson disease <sup>16,17,30</sup>
Genetic Parkinson disease [parkin, <sup>18,57</sup> PINK1, <sup>18</sup> ], POLG1 mutation <sup>58</sup>
Cerebellar disease <sup>27,48</sup>
Multiple sclerosis <sup>36</sup>
Dystonia
*Anti-Hu antibody <sup>60</sup>
PQ calcium channel antibodies <sup>20</sup>
Graves' disease <sup>47,59</sup>
Vocal tremor <sup>32</sup>
Essential tremor <sup>7,8</sup>
Alexander disease <sup>46</sup>
Myelopathy <sup>20</sup>
Dural arteriovenous fistula <sup>20</sup>
Dopamine blocking medication <sup>35</sup>
Chronic relapsing polyneuropathy <sup>10</sup>
Peripheral neuropathy
Hydrocephalus <sup>10</sup>

\*Clinical diagnosis only.

Rigby et al. noted that gait unsteadiness, falls, and abnormal gait were much more common in low (<10 Hz) compared with intermediate (10–13 Hz) OT, but these features were uncommon or absent in high-frequency OT (>13 Hz).<sup>20</sup> One-third of slow OT cases (23/70; 33%) occurred in isolation, challenging previous views that suggested it was rarely isolated.<sup>28,29</sup> Two-thirds of cases ( $n = 47$  patients; 67%) had a coexistent disorder to which slow OT was attributed (see Table 3). These were almost all neurologic ( $n = 43$ ); parkinsonism ( $n = 21$ ; 30%), cerebellar ataxia ( $n = 8$ ; 11%), dystonia ( $n = 7$ ; 10%), and spasticity/myelopathy ( $n = 6$ ; 9%) were most commonly identified, and occasionally more than one were concurrent. Autoimmune ( $n = 4$ ; 6%), drug-induced, polyneuropathy (all  $n = 2$ ; 3%) and aqueduct stenosis with hydrocephalus ( $n = 1$ ; 1%) were uncommon. Within the autoimmune category, two patients had Graves' disease. ET was formally diagnosed in only two patients (3%). However, a coexistent tremor was observed or recorded in 42 patients (60%): postural arm tremor in 24 (34%); rest tremor in 10 (14%); mixed postural and rest tremor in 5 (7%); postural leg; lips; or voice (all 1 each). Side-locked resting tremor and lateralized orthostatic tremor were noted in three patients with parkinsonism, highly suggestive that slow OT represented re-emergent leg tremor upon standing in these cases.<sup>30</sup> Other PD patients had resting tremor in the upper limb only, with a crossed orthostatic tremor in the opposite limb. Some PD patients had bilateral orthostatic leg tremor; without a resting leg component identified.

### Imaging

There were focal structural and/or functional imaging abnormalities in about one-fifth of cases (15; 21%). This may be an underestimate, given that several cases reported were prior to widespread availability of magnetic resonance imaging (MRI). MRI brain or spinal cord images were abnormal in all patients with a coexistent structural neurological disorder, most commonly reflecting lesions in the cerebellum, pons, medulla, and upper spinal cord. In a patient with a lateralized pontine

lesion, slow OT was more pronounced ipsilateral to the lesion. Single-photon emission computerized tomography (SPECT) imaging was abnormal in several cases with coexistent parkinsonism. In the remainder, brain imaging was normal or showed only diffuse age-related changes.

### Neurophysiology

The median tremor frequency of slow OT was 6–7 Hz and ranged from 3 to 12 Hz. The tremor bursts ranged from 50 to 150 ms duration, and were often variable.<sup>17,27,31</sup> The bursts could be either synchronous<sup>7,14,27,28</sup> or alternating<sup>6,32,33</sup> in analogous muscles (e.g., bilateral tibialis anteriors); and either synchronous<sup>34,35</sup> or alternating in agonist/antagonist muscle pairs<sup>8,18</sup> (e.g., ipsilateral tibialis anterior and gastrocnemius). Low coherence (0.2–0.8) was reported,<sup>20</sup> and several cases with high coherence ( $\geq 0.8$ ) were also identified.<sup>18,27,36</sup> These neurophysiological findings can be contrasted with classical OT, which is foremost immediately distinguished by its higher tremor frequency. Furthermore, classical OT typically has synchronous EMG tremor bursts in analogous leg muscles (e.g., bilateral tibialis anteriors) of uniform short duration (25–40 ms).<sup>13,16</sup> This synchronous bursting pattern has been reported in leg, paraspinal, and upper limb muscles where patients bear weight, or where tremor is activated by isometric contraction. Classical OT was previously regarded as the only organic tremor with high coherence (0.8–1.0), suggesting a single or closely linked bilateral oscillators, which distinguishes it from other centrally generated tremor disorders.<sup>37</sup> For example, essential and parkinsonian tremors have poor side-to-side coherence, suggesting discrete bilateral generators for these centrally generated movements.<sup>38</sup>

Slow OT can be distinguished electrophysiologically from its mimic of orthostatic myoclonus. While orthostatic myoclonus can fall within the frequency range of slow OT, it can also occasionally be >13 Hz. However, it is distinguished from slow orthostatic tremor by an irregular nonrhythmic bursting pattern, and the burst duration is typically much shorter than slow OT, at under 100 ms and often <50 ms.<sup>39</sup>

Rigby et al. compared electrophysiology in slow OT patients, divided into <10 Hz ( $n = 8$ ) and 10–13 Hz ( $n = 6$ ), versus classical OT >13 Hz ( $n = 14$ ). Lower frequency discharges tended to have a broader spectral peak, greater variability in discharge duration, and lower intermuscular coherence.<sup>20</sup> In another study, patients were subdivided into “slow” (4–6 Hz) and “intermediate” (7–9 Hz) OT, and intermediate OT has shared EMG characteristics with “slow” and “fast” OT.<sup>17,27</sup>

Slow OT has been observed to be evoked by different conditions of strong tonic-muscle contraction, such as independent standing, isometric muscle contraction, or pressing a limb against resistance.<sup>7,28</sup> This has also been observed with classical OT.<sup>40,41</sup> However, as it is sometimes not purely orthostatic or weight bearing, some have suggested reserving these terms for those characteristics.<sup>7,39</sup>

Focusing on the electrophysiology findings of PD patients with resting leg tremor and orthostatic tremor, in three cases there was asymmetric or sidelocked tremor bursts on standing, suggestive of re-emergent leg tremor. However, in several other PD cases with rest leg tremor, the electrophysiology reports were lacking in details, and did not specify whether there was laterality of standing tremor.

**Table 4. Differential Diagnosis of Mimics of Slow Orthostatic Tremor**

Classical orthostatic tremor (>13 Hz)
Orthostatic myoclonus
Re-emergent leg tremor in parkinsonism
Negative myoclonus (asterixis)
Isolated generalized polymyoclonus <sup>61</sup>
Titubation
Clonus
Postural orthostatic intolerance (hypotension, dehydration, hyperadrenergic state, deconditioning)
Epileptic cortical myoclonic tremor
Limb-shaking transient ischemic attack
Functional tremor
Enhanced physiological tremor

### Differential diagnosis

This is listed in Table 4. Slow OT can clinically mimic other shaky leg disorders, for example, classical OT, orthostatic myoclonus, or functional shaky legs, because the frequency and regularity of the shaking are difficult to accurately estimate by clinical examination. The “helicopter sign” of auscultating the legs with a stethoscope for a rhythm is not specific to orthostatic tremor.<sup>42</sup> Electrophysiology remains the gold standard detection, confirming the presence of tremor bursts and the slow frequency.<sup>39</sup> Given limited access to electrophysiology studies in some clinical settings, emerging use of new technologies, such as app-based tremor devices which have been found to be highly sensitive in OT, can increase bedside detection.<sup>43</sup>

### Treatment

There are three main medication classes to which patients with slow OT appear to respond in a dichotomous fashion: parkinsonian medications (levodopa, anticholinergics), ET medications (beta-blockers, primidone), or classical OT medication (clonazepam). In addition, the two cases with Graves’ disease had a dramatic improvement after methimazole therapy to treat the underlying condition. These observations support earlier theories that slow OT has different variants with different pathophysiological underpinnings. Clonazepam and levodopa were the most effective medications (both  $n = 15$ ; 21%), followed by gabapentin ( $n = 6$ ; 9%) and primidone ( $n = 5$ ; 7%). However, important observations can be made. Clonazepam and gabapentin were effective across all tremor frequencies. Levodopa was effective in 15/19 patients with 4–7 Hz OT, and 11 of these 15 responders had coexistent parkinsonism. Primidone was effective for 5–10 Hz tremor. Moreover, these findings suggest patterned variants of slow OT, characterized by frequency, coexistent disorder, and medication response. These medications may be helpful in classical OT, excepting levodopa which is often ineffective.<sup>26</sup> A variety of other medications were tried with mostly unfavorable responses.

### Pathophysiology

There are several lines of support for slow OT having a central generator like classical OT, rather than of peripheral origin.<sup>44</sup> First, it can share the same frequency as concurrent tremor in other body parts,

suggesting a single generator.<sup>32</sup> The tremor cannot be reset by peripheral stimuli.<sup>6,28,45</sup> Stretch reflexes in the calf and pretibial muscles are typically normal.<sup>6</sup> Peripheral neuropathic processes are rarely reported. Where studied, sensory nerve conduction studies and sensory and motor evoked potentials have been normal.<sup>6,28</sup>

A combination of fast and slow orthostatic tremors were reported in five cases. Interestingly, three of these had a combination of 8 and 16 Hz OT, and subjective unsteadiness and visibly increased tremor amplitude was reported only during the presence of the 8 Hz tremor.<sup>6,15,40</sup> In one patient, selective slowing to 8 Hz was observed in one leg muscle, while remaining at 16 Hz in the other leg muscles.<sup>6</sup> With treatment, the 8 Hz tremor disappeared and symptoms improved in two patients, while the 16 Hz tremor persisted.<sup>6,15</sup> These observations are intriguing and provide further data for speculation on the pathophysiology. In some patients, dual slow and fast frequencies have been attributed to either fast harmonics in slow OT<sup>4</sup> or to slow harmonics in fast OT, depending on the predominant tremor frequency on accelerometry. However, the tremors in those three cases did not behave like a harmonic, as only one tremor resolved with treatment. Furthermore, the selective slowing of frequency in one leg muscle might suggest two distinct generators for fast and slow tremors, which may become coupled or uncoupled by an enigmatic mechanism. An alternative hypothesis is that they may have the same central generator, with frequency output modified by a secondary process, which is amenable to medication effect. Patients with dominant low frequency orthostatic tremor accompanied by subpeak harmonic or nonharmonic higher frequencies have been observed, and it has been theorized that other common frequencies might drive the lower limb tremor.<sup>27,31,36</sup>

A shared underpinning for slow OT is suggested in patients with coexistent neurologic disorders manifesting with tremor of similar frequency as slow OT. A similar rationale can be made for structural lesions<sup>13,25,26</sup> or autoimmune disorders<sup>13,29,33</sup> that appear to be timelocked to the onset or offset of slow OT. This is aptly illustrated by the two patients with Graves’ disease, both with 8 Hz tremor, with complete remission after treatment with methimazole, suggesting the slow OT mechanism was due to enhanced physiological tremor. Interestingly, others have suggested that slow OT may be an exaggeration of physiological tremor, due to synchronization of central structures involved in organizing postural signal, for example, spinal cord neurons, inferior olive, or thalamus, which are all capable of spontaneous oscillatory activity.<sup>20,28,33,36,46,47</sup> Central pathways involved in relaying postural signals could also be activated by standing, and trigger a central oscillator for OT.<sup>14,28,40</sup> The cerebellum, pons, medulla, and upper spinal cord have been hypothesized as potential sites based on symptomatic cases of slow OT.<sup>34,46,48,49</sup> However, as OT is a rare complication of structural brain and cord abnormalities, possibly a second hit in an intersecting pathway may be required for this phenomenon to occur.

### Discussion

The 70 tremor cases reviewed here qualify as orthostatic by definition because they are “relating to or are evoked by an upright posture.” Almost all occurred uniquely, but a handful had coexistent >13 Hz

classic OT. Importantly, numerous <13 Hz cases have sufficient clinical and electrophysiological differences from >13 Hz cases to consider that at least a portion of slow OT cases are distinct entities from classic OT. Notably, about two-thirds of slow OT were associated with other etiologies, compared with one-third of primary OT<sup>50</sup>; therefore, it is unclear if slow OT appears “different” to primary OT due to underlying disease, or intrinsic factors of slow OT itself. In many cases, it is difficult to argue that a patient with slow OT and significant parkinsonism or ataxia is simply a “variant” of classic high-frequency OT. However, cases with frequencies in the 9–12 Hz range, or those with a harmonic of >13 Hz in idiopathic OT cases, seem very closely related to classic OT and may well deserve the “variant” label. Frequency should continue to be an importance characteristic of OT cases because important clinical, diagnostic, and treatment differences seem to exist for at least some slow OT cases versus classic OT. This makes additional study of slow orthostatic tremor important, so more specificity can replace the “pseudo” term to improve clinical management.

It is tempting to connect OT with a pathological alteration of stance physiology. Normal stance physiology uses multisensory inputs to provide ongoing small corrections of an upright body schema to the desired well-balanced body posture.<sup>51</sup> This happens unconsciously through both tonic and phasic activation of axial and lower limb muscles.<sup>52</sup> Muscle agonist–antagonist co-contraction is thought to be important for this postural control of stance. Classic high-frequency OT, as well as select slow OT cases, exhibits synchronous antagonistic muscle bursts on standing associated with high intermuscular coherence. These properties, along with less common symptomatic lesions and its association with elicitation by anti-gravity activation, have prompted authors to suggest a disordered brainstem-cerebellum circuit abnormality of stance for classic OT.<sup>44,53</sup> However, a more precise concept for classic OT pathophysiology has been elusive.

When compared with classic OT, slow OT pathophysiology is at least as perplexing. However, some observations deserve comment on a relational basis. Our literature review indicated that 29/70 (41%) of slow OT cases were associated with ataxia and parkinsonism from different etiologies. The family history of ET or tremor (11/70; 16%) was lower than anticipated, although 34% had coexistent postural arm tremor detected electrophysiologically. Indeed, the frequency for symptomatic limb tremor in all these syndromes is classically within the slow OT range. Moreover, there appears to be no reason why symptomatic muscle activation tremors in the upper limbs of these disorders could not be associated with lower limb tremors by the same pathophysiology. For example, it is probable that parkinsonism pathophysiology is responsible for slow OT in the presence of coexistent parkinsonism, dopaminergic responsiveness, abnormal SPECT imaging, and alternating tremor bursts in the range of 4–7 Hz. However, given the absence of detailed electrophysiology recordings in many cases, a conclusion cannot be reached as to what proportion of cases were slow OT versus re-emergent leg tremor while standing. ET pathophysiology could be suggested by the presence of family history of ET, beta-blocker response, alcohol response, and synchronous tremor bursts in antagonist muscles at 5–8 Hz. Finally, such distinct pathophysiology

mechanisms in slow OT bolster the argument for considering slow OT to comprise of heterogeneous entities, and for many cases to be distinct from >13 Hz OT.

Slow OT neurophysiology also seems to be more disparate when compared with classic high-frequency OT. The neurophysiology characteristics of slow OT, such as lower intermuscular coherence, variable discharge duration, and less rhythmicity, when compared with classic high-frequency OT, would be consistent with poor coordination of muscle control in slow OT. From these combined findings, one could speculate that slow OT represents disordered voluntary system contributions to stance, whereas classic high-frequency OT represents disordered involuntary system contributions to stance. This speculation may warrant investigation. Whatever the mechanism, the neurophysiology described for slow OT in the literature supports distinction from classic >13 Hz and, in addition, provides a useful tool in the clinic to objectively confirm clinical suspicion of slow OT.

Compiling the findings from this review, the current label of “pseudo-orthostatic tremor” for all OT <13 Hz may restrict physicians from putting the slow OT symptom in diagnostic and treatment context in many instances. This was one of the reasons that we instead selected the term “slow OT” for the purposes of our study, and still utilized frequency as the single cutoff between classical and slow OT as per the current definition. Aligned with this idea, we tentatively propose that patients with OT symptoms and EMG confirmation of <13 Hz tremor should be termed “slow OT.” Similar to classical OT subdivisions, “primary slow OT” could indicate isolated slow OT. “Primary slow OT-plus” could label slow OT with a coexistent neurological disorder, although “secondary slow OT” may be more appropriate to include all symptomatic causes of slow OT, including non-neurological (e.g., Graves’). These proposals share some commonalities with those proposed by Ure et al.<sup>21</sup>

Limitations to our interpretation include the possibility of overlooking other published cases of slow OT. As this was a retrospective review of mostly single case reports, with sometimes absent demographic and clinical data, and high variability in electrophysiological reports, the lack of uniformity may plausibly have skewed the overall findings. However, as the largest review of slow OT cases to date, it is likely to provide more robust characterization of this disorder than suggested by single case reports.

## Conclusions

While multiple lines of evidence separate slow OT from classical OT, not least the tremor frequency, clinical and electrophysiological overlap may occur. Demographics are similar, and both may occur in isolation, or in combination with neurological or medical disorders. Although the terms “variant” and “pseudo” may eventually be suitable for some slow OT cases, these labels probably distract clinicians from putting the slow OT symptom in diagnostic and treatment context in many instances. We suggest a data-driven approach with enhanced detailed characterization of the clinical and electrophysiological properties of slow OT. These features could be potentially utilized to prospectively assess the validity of diagnostic criteria for subtypes of slow OT.

## References

1. Bhatia KP, Bain P, Bajaj N, Elble RJ, Hallett M, Louis ED, et al. Consensus statement on the classification of tremors. From the task force on tremor of the International Parkinson and Movement Disorder Society. *Mov Disord* 2018; 33(1):75–87. doi: 10.1002/mds.27121
2. Gerschlagler W, Munchau A, Katzenschlager R, Brown P, Rothwell JC, Quinn N, et al. Natural history and syndromic associations of orthostatic tremor: a review of 41 patients. *Mov Disord* 2004;19(7):788–795. doi: 10.1002/mds.20132
3. Pazzaglia P, Sabattini L, Lugaresi E. [On an unusual disorder of erect standing position (observation of 3 cases)]. *Riv Sper Freniatr Med Alien Ment* 1970;94(2):450–457.
4. Heilman KM. Orthostatic tremor. *Arch Neurol* 1984;41(8):880–881. doi: 10.1001/archneur.1984.04050190086020
5. Heilman KM. Orthostatic tremor and parkinsonism. *Parkinsonism Relat Disord* 2015;21(5):541. doi: 10.1016/j.parkreldis.2014.12.035
6. Thompson PD, Rothwell JC, Day BL, Berardelli A, Dick JP, Kachi T, et al. The physiology of orthostatic tremor. *Arch Neurol* 1986;43(6):584–587. doi: 10.1001/archneur.1986.00520060048016
7. Wee AS, Subramony SH, Currier RD. “Orthostatic tremor” in familial-essential tremor. *Neurology* 1986;36(9):1241–1245. doi: 10.1212/WNL.36.9.1241
8. FitzGerald PM, Jankovic J. Orthostatic tremor: an association with essential tremor. *Mov Disord* 1991;6(1):60–64. doi: 10.1002/mds.870060111
9. Papa SM, Gershanik OS. Orthostatic tremor: an essential tremor variant? *Mov Disord* 1988;3(2):97–108. doi: 10.1002/mds.870030201
10. Gabellini AS, Martinelli P, Gulli MR, Ambrosetto G, Ciucci G, Lugaresi E. Orthostatic tremor: essential and symptomatic cases. *Acta Neurol Scand*. 1990;81(2):113–117. doi: 10.1111/j.1600-0404.1990.tb00944.x
11. Poersch M, Koster B. Tremor frequency shift in orthostatic tremor from low to high frequencies due to forceful muscle contractions. *Muscle Nerve* 1996; 19(6):795–796.
12. Walker FO, McCormick G. Orthostatic tremor. *Mov Disord* 1991;6(3): 266–267. doi: 10.1002/mds.870060315
13. Cristea RL, Goren H. Orthostatic tremor. *Arch Neurol* 1991;48(11):1119. doi: 10.1001/archneur.1991.00530230027014
14. Oda K, Fukushima N, Kakigi R, Shibasaki H. [A case of orthostatic tremor in parkinsonism]. *Rinsho Shinkeigaku* 1989;29(7):924–926.
15. Cano J, Catalan B, Ibanez R, Gudín M, Hernandez A, Vaamonde J. [Primary orthostatic tremor: slow harmonic component as responsible of instability]. *Neurologia*. 2001;16(7):325–328.
16. Kim JS, Lee MC. Leg tremor mimicking orthostatic tremor as an initial manifestation of Parkinson’s disease. *Mov Disord* 1993;8(3):397–398. doi: 10.1002/mds.870080331
17. Leu-Semenescu S, Roze E, Vidailhet M, Legrand AP, Trocello JM, Cochen V, et al. Myoclonus or tremor in orthostatism: an under-recognized cause of unsteadiness in Parkinson’s disease. *Mov Disord* 2007;22(14):2063–9. doi: 10.1002/mds.21651
18. Thomas A, Bonanni L, Antonini A, Barone P, Onofrij M. Dopa-responsive pseudo-orthostatic tremor in parkinsonism. *Mov Disord* 2007;22(11):1652–1656. doi: 10.1002/mds.21621
19. Erro R, Bhatia KP, Cordivari C. Shaking on standing: a critical review. *Mov Disord Clin Pract* 2014;1(3):173–179. doi: 10.1002/mdc3.12053
20. Rigby HB, Rigby MH, Caviness JN. Orthostatic tremor: a spectrum of fast and slow frequencies or distinct entities? *Tremor Other Hyperkinet Mov* 2015;5:324.
21. Ure RJ, Dhanju S, Lang AE, Fasano A. Unusual tremor syndromes: Know in order to recognise. *J Neurol Neurosurg Psychiatry* 2016;87(11):1191–1203. doi: 10.1136/jnnp-2015-311693
22. Veilleux M, Sharbrough FW, Kelly JJ, Westmoreland BF, Daube JR. Shaky-legs syndrome. *J Clin Neurophys* 1987;4:304–305.
23. McManis PG, Sharbrough FW. Orthostatic tremor: clinical and electrophysiologic characteristics. *Muscle Nerve* 1993;16(11):1254–1260. doi: 10.1002/mus.880161117
24. Karlberg M, Fransson PA, Magnusson M. Posturography can be used to screen for primary orthostatic tremor, a rare cause of dizziness. *Otol Neurotol* 2005;26(6):1200–1203. doi: 10.1097/01.mao.0000194891.26097.e0
25. Manrique-Huarte R, Arcocha J, Perez-Fernandez N. [Orthostatic tremor inducing instability]. *Acta Otorrinolaringol Esp* 2012;63(2):120–124. doi: 10.1016/j.otorri.2011.09.010
26. Hassan A, Ahlskog JE, Matsumoto JY, Milber JM, Bower JH, Wilkinson JR. Orthostatic tremor: clinical, electrophysiologic, and treatment findings in 184 patients. *Neurology* 2016;86(5):458–64. doi: 10.1212/WNL.0000000000002328
27. Williams ER, Jones RE, Baker SN, Baker MR. Slow orthostatic tremor can persist when walking backward. *Mov Disord* 2010;25(6):795–797. doi: 10.1002/mds.23024
28. Uncini A, Onofrij M, Basciani M, Cutarella R, Gambi D. Orthostatic tremor: report of two cases and an electrophysiological study. *Acta Neurol Scand* 1989;79(2):119–122. doi: 10.1111/j.1600-0404.1989.tb03722.x
29. Coffeng SM, Hoff JI, Tromp SC. A slow orthostatic tremor of primary origin. *Tremor Other Hyperkinet Mov* 2013;3:tre-03-147-3163-2.
30. Yoo SW, Choi KE, So J, Lee KS, Kim JS. Pseudo-orthostatic tremor in idiopathic Parkinson’s disease: could it be re-emergent tremor? *Neurol Sci* 2019;40(3):621–623. doi: 10.1007/s10072-018-3605-x
31. Kobylecki C, Silverdale MA, Dick JP, Kellett MW, Marshall AG. Dystonia associated with idiopathic slow orthostatic tremor. *Tremor Other Hyperkinet Mov* 2015;5:351.
32. Yokota J, Imai H, Seki K, Ninomiya C, Mizuno Y. Orthostatic tremor associated with voice tremor. *Eur Neurol* 1992;32(6):354–358. doi: 10.1159/000116860
33. Hegde M, Glass GA, Dalmau J, Christine CW. A case of slow orthostatic tremor, responsive to intravenous immunoglobulin. *Mov Disord* 2011;26(8): 1563–1565. doi: 10.1002/mds.23610
34. Benito-Leon J, Rodriguez J, Orti-Pareja M, Ayuso-Peralta L, Jimenez-Jimenez FJ, Molina JA. Symptomatic orthostatic tremor in pontine lesions. *Neurology* 1997;49(5):1439–1441. doi: 10.1212/WNL.49.5.1439
35. Alonso-Navarro H, Orti-Pareja M, Jimenez-Jimenez FJ, Zurdo-Hernandez JM, de Toledo M, Puertas-Munoz I. [Orthostatic tremor induced by pharmaceuticals]. *Rev Neurol* 2004;39(9):834–836. doi: 10.33588/rn.3909.2004403
36. Baker M, Fisher K, Lai M, Duddy M, Baker S. Slow orthostatic tremor in multiple sclerosis. *Mov Disord*. 2009;24(10):1550–1553. doi: 10.1002/mds.22630
37. Koster B, Lauk M, Timmer J, Poersch M, Guschlbauer B, Deuschl G, et al. Involvement of cranial muscles and high intermuscular coherence in orthostatic tremor. *Ann Neurol*. 1999;45(3):384–388. doi: 10.1002/1531-8249(199903)45:3<3C384::AID-ANA15%3E3.0.CO;2-J



38. O'Sullivan JD, Rothwell J, Lees AJ, Brown P. Bilaterally coherent tremor resembling enhanced physiological tremor: report of three cases. *Mov Disord* 2002;17(2):387–391. doi: 10.1002/mds.10097
39. Hassan A, van Gerpen JA. Orthostatic tremor and orthostatic myoclonus: Weight-bearing hyperkinetic disorders: A systematic review, new insights, and unresolved questions. *Tremor Other Hyperkinet Mov* 2016;6:417.
40. Deuschl G, Lucking CH, Quintern J. [Orthostatic tremor: clinical aspects, pathophysiology and therapy]. *EEG EMG Z Elektroenzephalogr Elektromyogr Verwandte Geb* 1987;18(1):13–19. doi: 10.1055/s-2008-1060891
41. Boroojerdi B, Ferbert A, Foltys H, Kosinski CM, Noth J, Schwarz M. Evidence for a non-orthostatic origin of orthostatic tremor. *J Neurol Neurosurg Psychiatry* 1999;66(3):284–288. doi: 10.1136/jnnp.66.3.284
42. McKay JH, van Gerpen JA. Different orthostatic hyperkinesias go “Thump.” *Clin Neurophysiol Pract* 2017;2:144–146. doi: 10.1016/j.cnp.2017.06.005
43. Bhatti D, Thompson R, Hellman A, Penke C, Bertoni JM, Torres-Russotto D. Smartphone apps provide a simple, accurate bedside screening tool for orthostatic tremor. *Mov Disord Clin Pract* 2017;4(6):852–857. doi: 10.1002/mdc3.12547
44. Lenka A, Pal PK, Bhatti DE, Louis ED. Pathogenesis of primary orthostatic tremor: current concepts and controversies. *Tremor Other Hyperkinet Mov* 2017;7:513.
45. Cleaves L, Cowan J, Findley LJ. Orthostatic tremor: diagnostic entity or variant of essential tremor? *J Neurol Neurosurg Psychiatry* 1989;52(1):130–131. doi: 10.1136/jnnp.52.1.130-a.
46. Stitt DW, Gavrilova R, Watson R, Hassan A. An unusual presentation of late-onset Alexander's disease with slow orthostatic tremor and a novel GFAP variant. *Neurocase* 2018;24(5–6):266–268. doi: 10.1080/13554794.2019.1580749
47. Lin FC, Wu MN, Chen CH, Huang P. Slow orthostatic tremor as the first manifestation of Grave's disease. *Mov Disord* 2013;28(8):1158–1159. doi: 10.1002/mds.25313
48. Setta F, Jacquy J, Hildebrand J, Manto MU. Orthostatic tremor associated with cerebellar ataxia. *J Neurol* 1998;245(5):299–302. doi: 10.1007/s004150050222
49. Bonnet C, Apartis E, Anheim M, Legrand AP, Baizabal-Carvallo JF, Bonnet AM, et al. Tremor-spectrum in spinocerebellar ataxia type 3. *J Neurol* 2012;259(11):2460–2470. doi: 10.1007/s00415-012-6531-5
50. Mestre TA, Lang AE, Ferreira JJ, Almeida V, de Carvalho M, Miyasaki J, et al. Associated movement disorders in orthostatic tremor. *J Neurol Neurosurg Psychiatry* 2012;83(7):725–729. doi: 10.1136/jnnp-2012-302436
51. Forbes PA, Chen A, Blouin JS. Sensorimotor control of standing balance. *Handb Clin Neurol* 2018;159:61–83. doi: 10.1016/B978-0-444-63916-5.00004-5
52. Chiba R, Takakusaki K, Ota J, Yozu A, Haga N. Human upright posture control models based on multisensory inputs; in fast and slow dynamics. *Neurosci Res* 2016;104:96–104. doi: 10.1016/j.neures.2015.12.002
53. Benito-Leon J, Domingo-Santos A. Orthostatic tremor: an update on a rare entity. *Tremor Other Hyperkinet Mov* 2016;6:411.
54. Kang SY, Song SK, Kim JS, Sohn YH. Unilateral standing leg tremor as the initial manifestation of Parkinson disease. *J Mov Disord* 2009;2(1):29–32. doi: 10.14802/jmd.09007
55. Kim JS, Lee JH. Orthostatic tremor: a case report. *J Korean Neurol Assoc* 1990;8(1):151–153.
56. Lee SY, Chung EJ, Kim YJ, Kim SJ. Dopa responsive slow orthostatic tremor in Parkinson's disease. *J Mov Disord* 2011;4(2):82–4. doi: 10.14802/jmd.11019
57. Infante J, Berciano J, Sanchez-Juan P, Garcia A, Di Fonzo A, Breedveld G, et al. Pseudo-orthostatic and resting leg tremor in a large Spanish family with homozygous truncating parkin mutation. *Mov Disord* 2009;24(1):144–147. doi: 10.1002/mds.22349
58. Invernizzi F, Varanese S, Thomas A, Carrara F, Onofrij M, Zeviani M. Two novel POLG1 mutations in a patient with progressive external ophthalmoplegia, levodopa-responsive pseudo-orthostatic tremor and parkinsonism. *Neuromuscul Disord* 2008;18(6):460–464. doi: 10.1016/j.nmd.2008.04.005
59. Mazzucchi S, Frosini D, Calabrese R, Bonuccelli U, Ceravolo R. Symptomatic orthostatic tremor associated with Graves' disease. *Neurol Sci* 2014;35(6):929–931. doi: 10.1007/s10072-014-1672-1
60. Gillhuis HJ, van Ommen HJ, Pannekoek BJ, Sillevs Smitt PA. Paraneoplastic orthostatic tremor associated with small cell lung cancer. *Eur Neurol* 2005;54(4):225–226. doi: 10.1159/000090715
61. McKeon A, Pittock SJ, Glass GA, Josephs KA, Bower JH, Lennon VA, et al. Whole-body tremulousness: isolated generalized polymyoclonus. *Arch Neurol* 2007;64(9):1318–1322. doi: 10.1001/archneur.64.9.1318