

Letter to the Editor



Rapidly Progressive Behavioral Syndrome Without Spastic Paraplegia in a Patient With *SPAST* p.Pro26Thr Variant

Faheem Arshad ,¹ Suvarna Alladi ,¹ Karthik Kulanthaivelu ²

¹Department of Neurology, National Institute of Mental Health and Neurosciences (NIMHANS), Bangalore, India

²Department of Neuroimaging and Interventional Radiology, National Institute of Mental Health and Neurosciences (NIMHANS), Bengaluru, India

OPEN ACCESS

Received: Dec 19, 2021

Revised: Apr 25, 2022

Accepted: Apr 25, 2022

Published online: Apr 30, 2022

Correspondence to

Faheem Arshad

Department of Neurology, National Institute of Mental Health and Neurosciences (NIMHANS), Bengaluru, Karnataka 560029, India.

Email: faheem2285@gmail.com

© 2022 Korean Dementia Association

This is an Open Access article distributed under the terms of the Creative Commons Attribution Non-Commercial License (<https://creativecommons.org/licenses/by-nc/4.0/>) which permits unrestricted non-commercial use, distribution, and reproduction in any medium, provided the original work is properly cited.

ORCID iDs

Faheem Arshad

<https://orcid.org/0000-0002-2102-7937>

Suvarna Alladi

<https://orcid.org/0000-0002-0372-9572>

Karthik Kulanthaivelu

<https://orcid.org/0000-0002-1585-8769>

Conflict of Interest

The authors have no financial conflicts of interest.

Dear Editor,

Recently, there have been several advancements in the genetic techniques used for the diagnosis of neurological disorders. However, a continuous increase in the amount of genetic data has led to many challenges in the interpretation of data for clinicians. In addition, these disorders present with a wide spectrum of clinical features that include neuropsychiatric and cognitive changes and have extensive white-matter hyperintensities on brain imaging, that are often misdiagnosed as acquired small vessel disease. The diagnoses of the genetic disorders like adult-onset leukoencephalopathy with axonal spheroids and pigmented glia (ALSP), cerebral autosomal dominant arteriopathy with subcortical infarcts, and leukoencephalopathy (CADASIL) have been considered in neuro-patients in the absence of vascular risk factors. The common variants associated with ALSP are *CSF1R* and *AARS-2* genes and the imaging features that are classically described are deep white-matter diffusion abnormalities.^{1,2} However, there have been cases with the same imaging abnormalities that are not associated with either of the 2 variants, thereby implying the involvement of other genetic causes in adult-onset leukoencephalopathies. We herein report a rare case with *SPAST*-related leukoencephalopathy with clinical presentation suggestive of frontotemporal dementia (FTD) and brain imaging indicative of ALSP.

A 62-year-old woman presented with a one-year history of behavioral disturbances characterized by anger outbursts, mental inflexibility, overfamiliarity, poor interpersonal conduct, and changes in dietary habits in the form of excessive eating with a preference for sweet foods. For the past 8-months, the patient had a history of aimless wandering and lack of personal hygiene. In addition, worsening in her behavior was reported along with the development of occasional crying episodes, a lack of empathy, and apathy. Subsequently, she had lost insight into her illness and became dependent on others for all her daily activities. She had sphincter disturbances in the form of urgency and incontinence without any concern. There was no relevant family history or any other medical history or fever before the illness (**Fig. 1A**). Her vitals were stable (blood pressure=130/80, pulse=74/min). Neurological examination revealed echolalia, utilization behavior, prominent frontal release signs (bilateral palmo-mental reflex, glabellar tap, and snout reflex), inattention, executive

Author Contributions

Conceptualization: Arshad F; Visualization: Kulanthaivelu K; Writing - original draft: Arshad F; Writing - review & editing: Arshad F, Alladi S, Kulanthaivelu K.

dysfunction, impaired naming, reduced fluency, and abstract knowledge. Motor examination showed normal tone, power, and deep tendon reflexes. Bilateral plantar response was flexor. Except for mildly reduced vibration sense (11 seconds at ankles), pain, touch, and joint position sense were normal. There was no neck stiffness. Her gait was normal. Laboratory investigations as part of secondary work-up for dementia were unremarkable. These tests included hemogram, liver, renal, and thyroid function tests, serum electrolytes, autoimmune encephalitis panel, antinuclear antibody profile, vitamin B12, homocysteine, VDRL, screening for abnormal metabolites for storage disorders, and ultrasound abdomen. The cerebrospinal fluid and electroencephalogram studies could not be done because she was not cooperative during the examination. Brain imaging (**Fig. 1B-G**) showed punctate calcification in the right basal ganglia, symmetric confluent hyperintensity involving bilateral frontal and peri-atrial white matter with severe frontal atrophy, hyperintense signal changes in the corpus callosum, foci of diffusion restriction in the frontal white-matter and sparing of subcortical U-fibres and features suggestive of ALSP. Whole exome sequencing of the proband revealed a heterozygous missense variation in exon-1 of the *SPAST* gene (chr2:g.32288976C>A;Depth:57x) that resulted in the amino acid substitution of Threonine for Proline at codon 26(p.Pro26Thr) and was validated by Sanger technique (**Fig. 1H**). To the best of our knowledge, the missense variant NM_014946.4(*SPAST*):c.76C>A (p.Pro26Thr) has not been reported previously as a pathogenic variant nor as a benign variant. The p.Pro26Thr variant is novel in 1kG All and gnomAD. Concerning In-silico prediction, the p.Pro26Thr is not predicted to introduce a novel splice site by any splice site algorithm. The p.Pro26Thr missense variant is predicted to be tolerated by both SIFT and PolyPhen2. The nucleotide c.76 in *SPAST* is not conserved according to a GERP++ and PhyloP analysis of 100 vertebrates. For these reasons, this variant has been classified as a variant of uncertain significance according to American College of Medical Genetics guidelines.

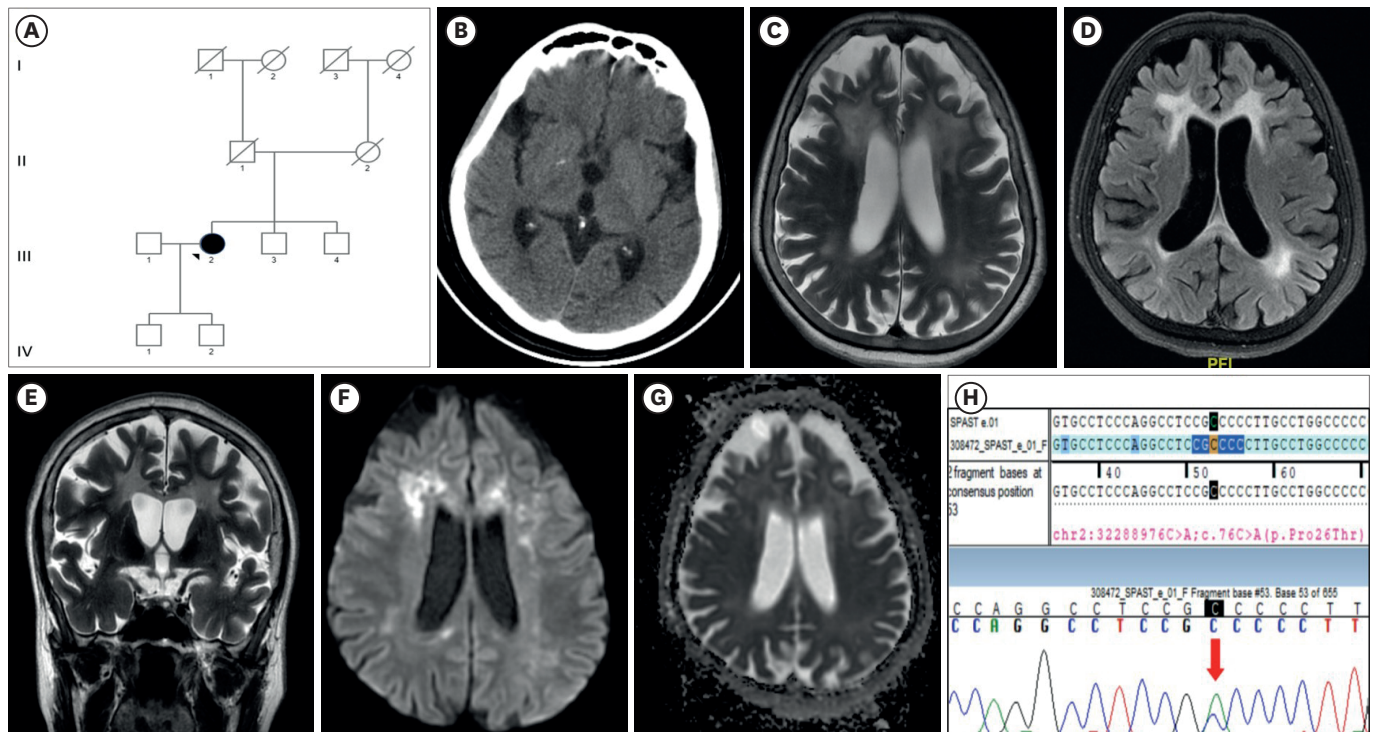


Fig. 1. Clinical, neuroimaging, and genetic findings in the patient. (A) Pedigree chart of the family showing the proband. (B) Computed tomography brain demonstrates punctate calcification in right basal ganglia. (C-E) Magnetic resonance imaging brain, axial and coronal T2-weighted, and axial F. (F) Axial T2-weighted MRI. (G) Axial T2-weighted MRI. (H) Sanger sequencing chromatogram showing the variant.

The patient was managed with symptomatic treatment (serotonergic medications for behavioral disturbances) and cognitive behavior therapy. Her symptoms have gradually worsened over time, primarily in the form of behavioral changes, according to a telephonic follow-up.

Cognitive impairment in association with the *SPAST* variant has been less frequently recognized probably due to subclinical cognitive problems which often go unnoticed and, thus scarcely reported. *SPAST* encodes a microtubule-severing protein spastin located on chromosome 2p. While *SPAST* variant has been commonly associated with hereditary spastic paraplegia (HSP), there is evidence to suggest deficits in executive function and social cognition similar to those seen in FTD.³ In clinicopathological studies, missense variation in *SPAST* associated with cognitive decline has been reported in families, with intrafamilial variability in clinical manifestations. Pathology reported in such studies has been variable and not typical of tauopathies.⁴ Only anecdotal cases suggest the presentation of *SPAST* variant similar to FTD as seen in our patient. Brain imaging results are generally normal in the majority of patients with the *SPAST* variant. However, a few reports on cerebellar and spinal cord atrophy, white-matter hyperintensities, or thinning of the corpus callosum have been described. Although the radiological appearance of genetic leukoencephalopathies can be nonspecific, there are important features to be distinguished. Deep white matter diffusion abnormalities have been well described in *CSF1R* and *AARS2*, in addition to the prominent involvement of the corpus callosum. A patchy leukoencephalopathy with lacunes, microhemorrhages, and involvement of the anterior temporal lobe suggests genetic vasculopathy such as CADASIL (*NOTCH-3* variant), or cathepsin A-related arteriopathy with strokes and leukoencephalopathy (CARASIL). Arylsulfatase A gene variant causes metachromatic leukodystrophy and is characterized by bilateral confluent areas of periventricular deep white matter signal changes, particularly around the atria and frontal horn with sparing of subcortical U-fibres leading to a butterfly pattern.

Genetic analysis showed a heterozygous missense *SPAST* variant instead of commonly reported variants associated with ALSP.^{1,2} Spastic paraplegia type 4 (SPG4) is the most prevalent form of autosomal dominantly inherited pure HSP worldwide, caused by mutations in *SPAST* gene. While most of the patients have a positive family history, only 5.7% can occur sporadically. In general, the identification of sporadic—*de novo* patients with SPG4 that result in a complex phenotype as seen in our patient, is attributed to common mechanisms like incomplete penetrance, somatic mosaicism, non-paternity, and inadequate clinical assessment of the parents.⁵ Altogether, true *de novo* occurrence of *SPAST* variants, i.e., where both the parents of the patient are proven not to have the variations in lymphocytes, appears rare and has never been studied separately. In the present case, segregation analysis was not possible. Such novel findings can be relatively explained based on the concept of epigenetics and reverse phenotyping.⁶ While genotypes remain stable over the life of an individual and can be pleiotropic, phenotypes are often inherently dynamic and unstable. Furthermore, phenotype definition must be addressed in genetic studies. The success of gene mapping in such genetically complex disorders relies on the ability to delineate the target phenotype accurately. This could be possible only by reviewing the phenotype at the end of a study, a concept referred to as reverse phenotyping, where phenotypes are refined based on genetics.⁶ Based on these concepts, a diagnosis of leukoencephalopathy secondary to the *SPAST* variant was considered in the present case, thereby extending its clinical and radiological spectrum. This may be a promising approach to extending the spectrum of a genetic disorder which may require further studies, although statistical challenges remain.

In addition, functional studies along with computational and predictive data using in-silico prediction programs are required to prove the genotype-phenotype correlation. The present case highlights the challenge of diagnosing the disease at an early stage due to its rare presentation and emphasizes the importance of not only genetic testing in patients with dementia and leukoencephalopathy but also the need for clinical genetic-pathological studies. It is hypothesized that the identification of such variations will advance the field with newer insights that can facilitate our understanding of disease mechanisms underlying adult-onset leukoencephalopathies.

REFERENCES

1. Konno T, Yoshida K, Mizuno T, Kawarai T, Tada M, Nozaki H, et al. Clinical and genetic characterization of adult-onset leukoencephalopathy with axonal spheroids and pigmented glia associated with *CSFIR* mutation. *Eur J Neurol* 2017;24:37-45.
[PUBMED](#) | [CROSSREF](#)
2. Lynch DS, Zhang WJ, Lakshmanan R, Kinsella JA, Uzun GA, Karbay M, et al. Analysis of mutations in *AARS2* in a series of *CSFIR*-negative patients with adult-onset leukoencephalopathy with axonal spheroids and pigmented glia. *JAMA Neurol* 2016;73:1433-1439.
[PUBMED](#) | [CROSSREF](#)
3. Chamard L, Ferreira S, Pijoff A, Silvestre M, Berger E, Magnin E. Cognitive impairment involving social cognition in SPG4 hereditary spastic paraplegia. *Behav Neurol* 2016;2016:6423461.
[PUBMED](#) | [CROSSREF](#)
4. Murphy S, Gorman G, Beetz C, Byrne P, Dytko M, McMonagle P, et al. Dementia in SPG4 hereditary spastic paraplegia: clinical, genetic, and neuropathologic evidence. *Neurology* 2009;73:378-384.
[PUBMED](#) | [CROSSREF](#)
5. Schieving JH, de Bot ST, van de Pol LA, Wolf NI, Brilstra EH, Frints SG, et al. *De novo SPAST* mutations may cause a complex SPG4 phenotype. *Brain* 2019;142:e31.
[PUBMED](#) | [CROSSREF](#)
6. Schulze TG, McMahon FJ. Defining the phenotype in human genetic studies: forward genetics and reverse phenotyping. *Hum Hered* 2004;58:131-138.
[PUBMED](#) | [CROSSREF](#)