

# Aesthetic Outcomes of the Adipofascial Turnover Flap for Nasal Defects

Christina N. Canzoneri, MD  
Anthony E. Capito, MD, FACS

**Background:** The single-stage adipofascial turnover (AFT) flap with full-thickness skin grafting is a novel technique that has been demonstrated as a safe, reliable, and cost-effective alternative to forehead flaps for nasal tip reconstruction. The purpose of this study was to compare aesthetic outcomes of these reconstructive techniques.

**Methods:** A retrospective review was conducted of patients who underwent either a forehead flap or an AFT flap for nasal reconstruction between January 2016 and January 2021. Aesthetic outcomes were compared via patient surveys and photographic analysis by plastic surgeons. All photographs were standardized and masked to conceal which reconstructive technique was utilized. Wilcoxon rank-sum tests and *t*-tests were performed to determine significance.

**Results:** Ten forehead flaps and 22 AFT flaps were performed between January 2016 and January 2021. Seven forehead flap patients and 18 AFT flap patients participated in the aesthetic outcome survey. Seven forehead flap postoperative photographs and 20 AFT flap postoperative photographs were available for analysis. Patients who underwent forehead flap reconstruction reported higher satisfaction for color match of the reconstruction to the surrounding nasal skin ( $P = 0.005$ ). Otherwise, there was no statistical significance between the two patient groups. There was no statistical difference in the photographic analysis of the two groups.

**Conclusion:** The single-stage AFT flap with full thickness skin grafting provides similar aesthetic outcomes compared with the two-stage forehead flap when reconstructing large defects of the nasal tip, which is supported by both patient-reported outcome measures and standardized photographic analysis by a panel of plastic surgeons. (*Plast Reconstr Surg Glob Open* 2023; 11:e4962; doi: 10.1097/GOX.0000000000004962; Published online 26 April 2023.)

## INTRODUCTION

Large defects of the nasal tip with denuded cartilage, such as those encountered following Mohs excision of nasal skin cancer, present an interesting challenge for reconstruction. Numerous techniques for nasal reconstruction are reported in the literature; however, for defects more than 2 cm, the regional two-stage

paramedian forehead flap remains the gold standard, in part due to a lack of local flap options available.<sup>1,2</sup> Utilization of the forehead flap in nasal reconstruction dates to 500 B.C.E., with description of the median forehead flap to reconstruct an amputated nose in the *Sushruta Samhita*.<sup>3</sup> Indeed, forehead flaps are still considered an excellent option for nasal reconstruction due to the large available donor site and close resemblance to the color and texture of nasal skin. Although the forehead flap can provide an excellent match for the color and quality of nasal skin, it is associated with multiple drawbacks. Forehead flaps by design are staged procedures, requiring a minimum of two operations, often with the need for revision procedures to debulk the flap and improve symmetry. In addition to the increased costs associated with staged procedures and visible donor site

From the Virginia Tech Carilion Section of Plastic and Reconstructive Surgery, Roanoke, Va.

Received for publication January 23, 2023; accepted March 6, 2023.

Presented at the Virginia Society of Plastic Surgeons Annual Meeting September 10, 2022 Charlottesville, Va., and at Plastic Surgery the Meeting 2022 Resident on-demand program, October 27–30, 2022 Boston, Mass.

Copyright © 2023 The Authors. Published by Wolters Kluwer Health, Inc. on behalf of The American Society of Plastic Surgeons. This is an open-access article distributed under the terms of the [Creative Commons Attribution-Non Commercial-No Derivatives License 4.0 \(CCBY-NC-ND\)](https://creativecommons.org/licenses/by-nc-nd/4.0/), where it is permissible to download and share the work provided it is properly cited. The work cannot be changed in any way or used commercially without permission from the journal.

DOI: 10.1097/GOX.0000000000004962

Disclosure statements are at the end of this article, following the correspondence information.

Related Digital Media are available in the full-text version of the article on [www.PRSGlobalOpen.com](http://www.PRSGlobalOpen.com).

scar, patients also must accept a period of discomfort, disfigurement, and wound care that accompanies the interval between the original procedure and the final division and inset.<sup>4</sup> The single-stage adipofascial turnover flap with full-thickness skin grafting is a novel technique that has previously been demonstrated as a safe, reliable, and cost-effective alternative for nasal tip reconstruction.<sup>5</sup> The purpose of this study was to compare aesthetic outcomes of these two reconstructive techniques. We hypothesized that the cosmetic results would be equivalent between the two groups.

## METHODS

A retrospective review was conducted of all patients in the senior author's practice who underwent either a forehead flap or an adipofascial turnover flap for nasal reconstruction between January 2016 and January 2021. The technical details of the adipofascial turnover flap design and execution have been previously reported<sup>5</sup> (Fig. 1). Aesthetic outcomes were compared via patient-reported aesthetic outcome surveys as well as via photographic analysis by board-certified or board-eligible plastic surgeons.

### PATIENT SATISFACTION SURVEY

A patient satisfaction survey was conducted for this study. All patients who underwent either reconstructive option were interviewed privately by telephone, during which they were asked to grade their nasal reconstruction on several categories, including color match to the surrounding skin, contour of the reconstruction, appearance of the nasal tip, symmetry of the nasal tip, appearance of the nasal tip in profile, cosmetic appearance of the nose, and overall satisfaction with the reconstruction. Patients were asked to score each category on a scale from 1 to 5, with 5 being the best score. (See survey, **Supplementary Digital Content 1**, which displays the patient satisfaction survey utilized in this study. <http://links.lww.com/PRSGO/C525>.)

### Takeaways

**Question:** Is the adipofascial turnover flap an aesthetically acceptable alternative to the forehead flap for nasal defects?

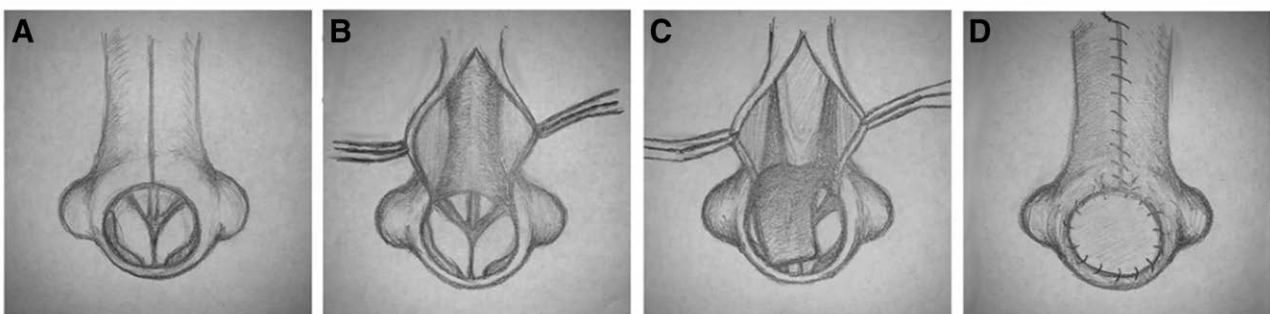
**Findings:** A retrospective study was performed, comparing the aesthetic results of patients who underwent forehead flaps and patients who underwent adipofascial turnover flaps. Patients reported comparable satisfaction in all categories except color match, which was higher in the forehead flap group. Photographs of both groups were scored by a panel of plastic surgeons. There was no significant difference between the scores.

**Meaning:** The adipofascial turnover flap is an aesthetically comparable alternative to the forehead flap for nasal defects.

The average scores for each category were compared between the adipofascial turnover flap group and the forehead flap group. Wilcoxon rank-sum tests were performed to determine significance.

### SURGEON PHOTOGRAPHIC ANALYSIS

A panel of three board-certified plastic surgeons and one board-eligible plastic surgeon was assembled from the faculty at Virginia Tech Carilion Section of Plastic Surgery. These surgeons were not involved in any parts of the patients' care. The surgeon panel was invited to objectively and independently review photographs of the patients and grade the appearance of their nasal reconstructions on categories of color match to the surrounding skin, appearance of the tip in anterior-posterior view, appearance of the tip in profile view, tip symmetry, and overall appearance of the reconstruction. Each category was graded on a scale from 1 to 5, with 5 being the best score. (See survey, **Supplementary Digital Content 2**, which displays the postoperative photograph grading sheet utilized by the surgeon panel in this study. <http://links.lww.com/PRSGO/C526>.)



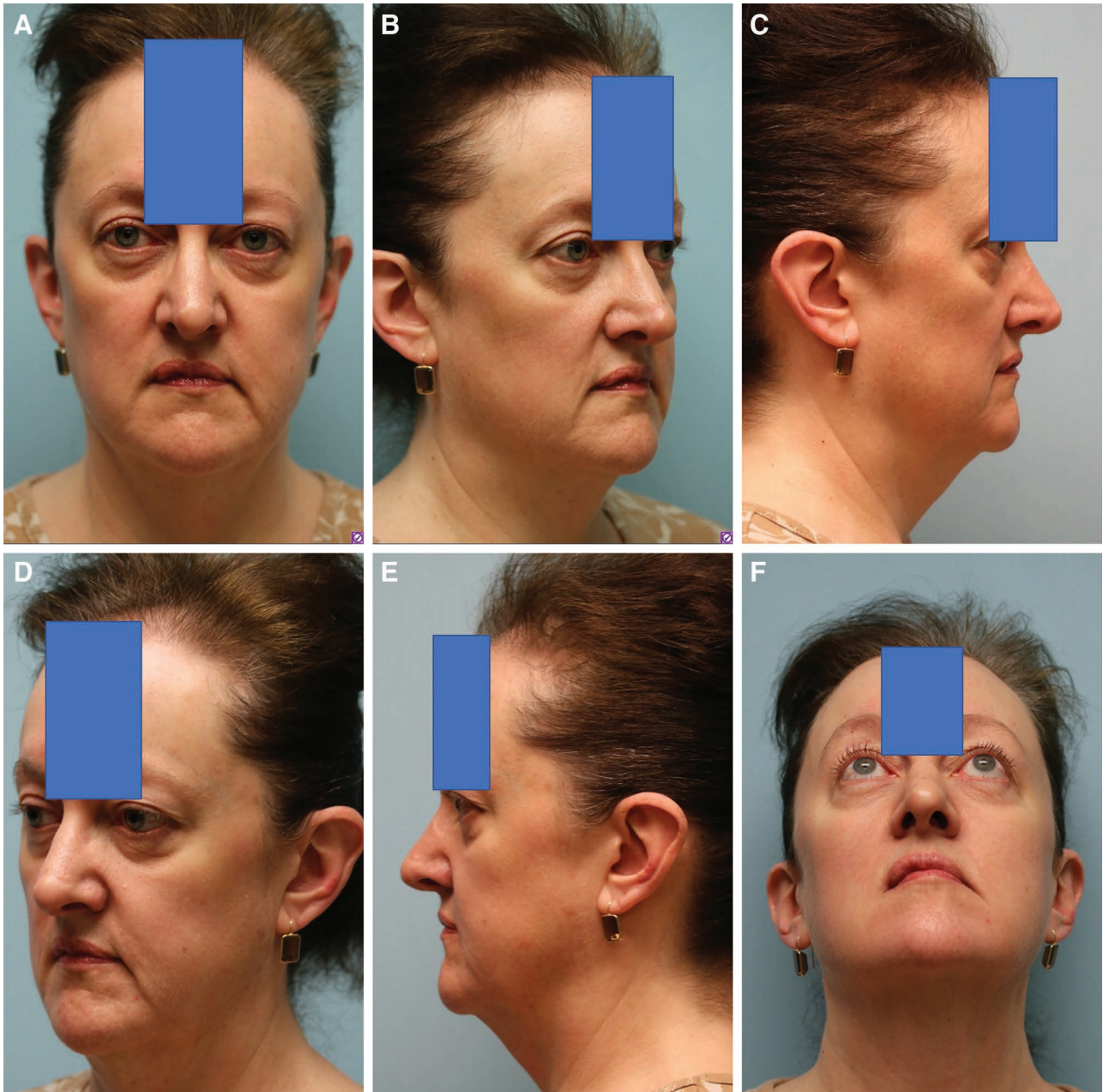**Fig. 1.** Stepwise approach to the adipofascial turnover flap. A, First, a midline or paramedian incision is made along the nasal dorsum in line with the nasal tip defect. B, Skin flaps are raised to expose the underlying adipofascial tissue. The inferiorly-based adipofascial flap is harvested. The width of the flap approximately equals the width of the defect. The length of the flap should be equal to the vertical height of the nasal defect plus an additional 6–8 mm to account for the length required for the turnover point. C, The flap is turned over and inset into the defect. D, Finally, a full thickness skin graft is inset over the adipofascial flap.

These photographs were taken as part of the patients' standard postoperative care. All photographs were standardized for lighting and resolution. Photographs were taken in anterior-posterior view, three-quarters view, and profile view. The photographs from the patients' last postoperative visit were selected. All photographs reviewed by the surgeon panel were subsequently masked to conceal which reconstructive technique was utilized. The grades assigned to each reconstructive category were compared between the adipofascial turnover flap group and the forehead flap group. *T* tests were performed to determine

significance for the plastic surgeon photographic analysis (Fig. 2).

### RESULTS

A total of 10 forehead flaps and 22 adipofascial turnover flaps were performed by the senior author for nasal tip reconstruction between January 2016 and January 2021 (Table 1). Of those patients, seven forehead flap patients and 18 adipofascial turnover flap patients participated in the aesthetic outcome survey. The other patients



**Fig. 2.** These photographs, taken 24 months after a two-stage forehead flap reconstruction of a nasal tip defect, demonstrate the method of masking that was utilized on postoperative photographs graded by the surgeon panel. A, Anterior-posterior view. B, Right oblique view. C, Right profile view. D, Left oblique view. E, Left profile view. F, Worms' eye view.



**Table 1. General and Demographic Information for Patients in the Adipofascial Turnover Group Compared with Patients in the Forehead Flap Group**

	Adipofascial Turnover Flap Group	Forehead Flap Group
Age		
Avg	69.7	71.0
Range	51–88	50–84
Race		
White	100% (n = 22)	100% (n = 10)
Other	0% (n = 0)	0% (n = 0)
Gender		
Women	77% (n = 17)	50% (n = 5)
Men	23% (n = 5)	50% (n = 5)
BMI		
Avg	26.5	27.6
Range	20.5–41.3	21.4–40.3
Active smoking status at time of procedure	9% (n = 2)	10% (n = 1)
Diabetes	32% (n = 7)	10% (n = 1)
Defect size (cm <sup>2</sup> )		
Avg	2.9	10.4
Range	1.0–5.3	4.0–20.3
Patient survey participation	81% (n = 18)	80% (n = 8)
Postop photos available for review	91% (n = 20)	70% (n = 7)

were deceased, lost to follow-up, or declined to participate. The average defect size that was treated with the adipofascial turnover flap was 2.9 cm<sup>2</sup>, with a range of 1.0 cm<sup>2</sup> to 5.3 cm<sup>2</sup>. The average defect size that was treated with the forehead flap was 10.4 cm<sup>2</sup>, with a range of 4.0 cm<sup>2</sup> to 20.3 cm<sup>2</sup>.

Patients who underwent forehead flap reconstruction reported higher satisfaction for color match of the reconstruction to the surrounding nasal skin ( $P = 0.005$ ). Otherwise, there was no statistical significance between the two patient groups when surveyed about nasal contour, symmetry, profile, tip, overall nasal appearance, and overall satisfaction with the reconstruction (Table 2).

Seven forehead flap patient postoperative photographs and 20 adipofascial turnover flap postoperative photographs were available for analysis by the panel of board-certified and board-eligible plastic surgeons. The other patients did not have photographs available for review if they were deceased or lost to follow-up. Of the adipofascial turnover flap group, the postoperative photographs that were evaluated by the panel of plastic surgeons were taken an average of 219 days postoperatively (range of 32–424 days; median 194 days). Of the forehead flap group, the photographs that were evaluated by the plastic surgeon panel were taken an average of 193 days postoperatively (range of 49–444 days; median 181 days). There was no statistical difference in the surgeon photographic analysis of the two groups when comparing color, tip profile view, tip anterior-posterior view, symmetry, and overall nasal appearance. There was no statistical difference in surgeon analysis of postoperative photographs taken before the 6 months postoperative timeframe and photographs taken after the 6 months postoperative timeframe (Table 3; Figs. 3 and 4).

## DISCUSSION

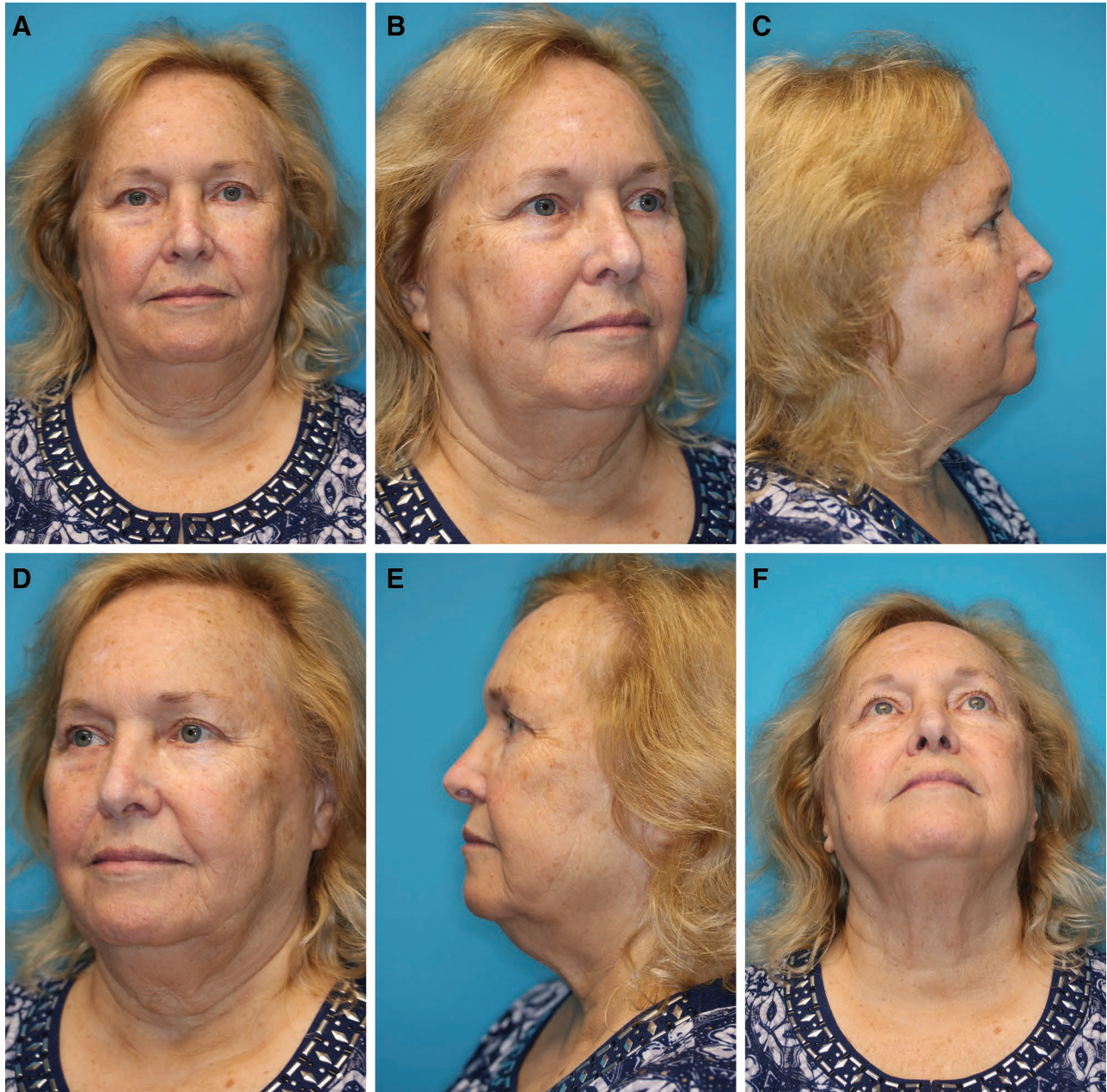Nasal reconstruction techniques remain an interesting challenge for plastic surgeons. Due to the similarity

**Table 2. Results of the Patient Satisfaction Survey**

	Color	Contour	Profile	Symmetry	Tip	Nose	Overall
AFT (n = 18)							
Average	4.11	4.67	4.78	4.78	4.61	4.67	4.94
Range	2.0–5.0	4.0–5.0	3.0–5.0	3.0–5.0	4.0–5.0	4.0–5.0	4.0–5.0
SD	0.83	0.49	0.55	0.55	0.50	0.49	0.24
FF (n = 7)							
Average	5.00	4.57	04.71	4.57	4.86	4.71	5.00
Range	5.0–5.0	4.0–5.0	3.0–5.0	4.0–5.0	4.0–5.0	4.0–5.0	5.0–5.0
SD	0.0	0.54	0.49	0.79	0.38	0.49	0.0
<i>P</i>	0.005	0.689	0.601	0.515	0.261	0.852	0.593

**Table 3. Results of the Postoperative Photograph Grades by the Surgeon Panel**

	Photo POD#	Color	Tip Profile	Tip AP	Tip Symmetry	Overall
AFT (n = 20)						
Average	219	3.95	4.23	3.9	3.97	3.98
Range	32–424	2.0–5.0	3.0–5.0	2.5–5.0	2.5–5.0	2.75–5.0
SD	135	0.84	0.69	0.77	0.73	0.70
FF (n = 7)						
Average	193	4.11	3.79	3.43	3.43	3.68
Range	49–444	3.75–4.75	3.0–4.25	3.0–4.25	2.75–4.5	3.0–4.25
SD	115	0.35	0.60	0.55	0.80	0.49
<i>P</i>		0.499	0.149	0.151	0.115	0.239

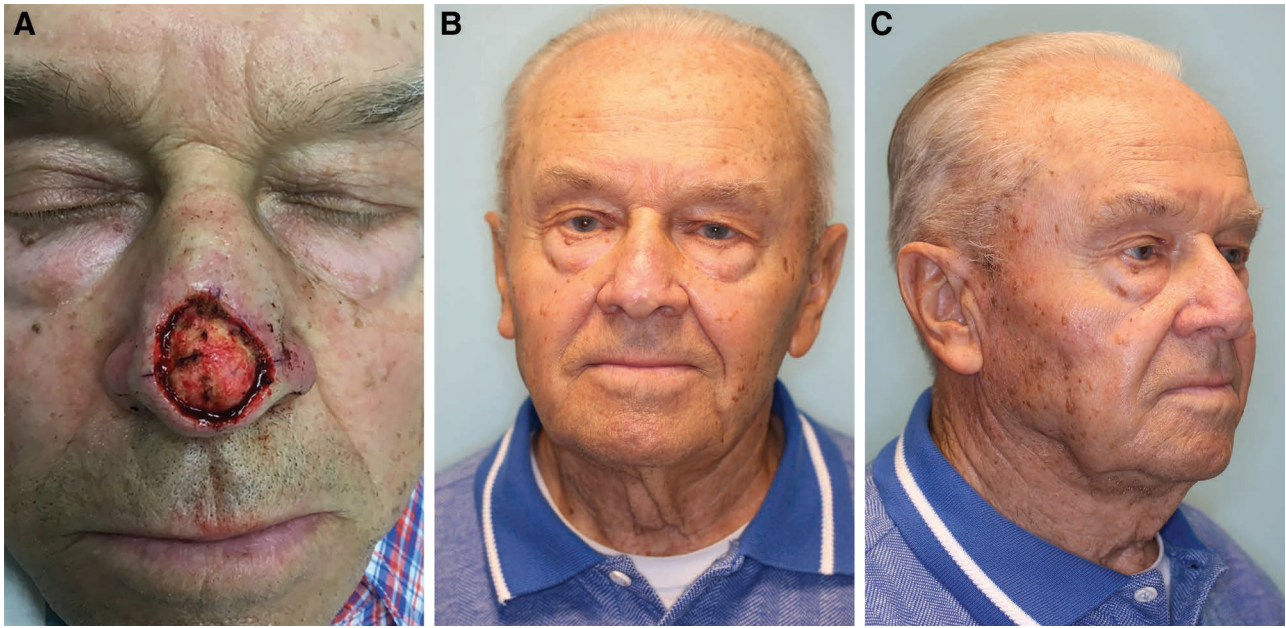

**Fig. 3.** This patient underwent reconstruction of a  $1.6 \times 1.4$  cm nasal tip defect with adipofascial turnover flap and full thickness skin graft. These photographs were taken 11 months postoperatively. A, Anterior-posterior view. B, Right oblique view. C, Right profile view. D, Left oblique view. E, Left profile view. F, Worms' eye view.

in color and texture to nasal skin, forehead skin has long been considered the best donor site to resurface defects of the nose when local options are not feasible.<sup>6,7</sup> For many centuries, the forehead flap has remained the gold standard for large defects of the nasal tip with denuded cartilage. Although the forehead flap is a great option given its large available donor site and likeness to the quality of nasal skin, it is also associated with inherent drawbacks. It is, by nature, a staged procedure with a minimum of two operations and occasionally three, often necessitating revision procedures to debulk the flap and improve

symmetry.<sup>8</sup> The forehead flap is associated with a morbid period between the two stages, in which the flap is inset distally, but the pedicle remains attached at the forehead. Diligent wound care is required to control drainage from the raw surface of the flap, and patients are subjected to the psychosocial effects of this temporary aesthetic deformity.<sup>4</sup> The forehead flap is additionally associated with visible scarring of the forehead, potential brow elevation, and recipient site hair growth.<sup>1,9</sup> In contrast, the adipofascial flap avoids these potential drawbacks of the forehead flap. It is, by design, a single-stage flap that avoids





**Fig. 4.** This patient underwent reconstruction of a 2.3 cm × 2.5 cm nasal tip defect with adipofascial turnover flap and full thickness skin graft. These photographs were taken 11 months postoperatively. A, Preoperative photograph demonstrating the nasal tip defect. B, Anterior-posterior view. C, Right oblique view.

considerable donor site scarring by utilizing local adipofascial tissue and a skin graft that can be harvested from a more discrete location. As a single-stage procedure, it is associated with less operative time and less overall cost. In the original technique article describing the adipofascial turnover flap for nasal reconstruction, total operative time was noted to average 142 minutes (about 2.5 hours) less in the adipofascial turnover flap group compared with the forehead flap group and cost on average \$22,000 less in the adipofascial turnover group compared with the forehead flap. The complication rates were noted to be similar between the two groups.<sup>5</sup> After establishing the safety and feasibility of the procedure, the next logical course of action is to investigate the aesthetic outcome. Despite the longstanding history of the superiority of forehead skin for nasal defects, this study demonstrates similar aesthetic results between the two groups based on both patient- and surgeon-reported metrics. Notably, color match was the only aspect of the reconstruction considered to be inferior by patients in the adipofascial flap group compared with the forehead flap group. Evaluation of color match was not statistically lower in the adipofascial group than the forehead flap group by surgeon panel analysis. For this technique, the senior author typically utilizes a preauricular lateral cheek donor site for skin grafting. Although forehead skin is often considered the best match for nasal skin, it is not always the best option for a skin graft donor site for the nose given its thick and sebaceous quality. Instead, as proposed by Burget, use of a preauricular skin graft is a good alternative.<sup>10</sup> This is the favored skin graft donor site for the adipofascial turnover flap. The scar can be well concealed in an existing facial rhytid, as typical for cosmetic facelift procedures. Additionally, preauricular

skin thickness is appropriate when resurfacing the defect in conjunction with a local adipofascial flap.<sup>11</sup> A forehead skin graft donor site is often too thick when used in combination with the adipofascial flap, yielding an abnormal contour. The pigmentation may be a better match from the forehead donor site, but the contour irregularities are prohibitive to its use in the senior author's experience. To optimize skin graft take, the use of quilting sutures is recommended to secure the full thickness skin graft to the underlying adipofascial flap. An additional technical pearl to consider is designing the turnover point at the supratip break if possible. This creates a natural transition between adjacent subunits of the nose and allows for a favorable contour in profile view. We have not experienced any contour irregularities at the turnover point of the flap with this technique.

The quality of nasal reconstruction cannot be successfully assessed without considering patient-reported outcome measures. Indeed, several patient-reported instruments have been developed for the purposes of analyzing both cosmetic rhinoplasty and nasal reconstruction outcomes. Previously validated patient-reported outcome surveys were reviewed, including the FACE-Q Satisfaction with Nose scale, the Utrecht scale, the RHINO scale, and the NAFEQ-score.<sup>12-15</sup> Many of these questionnaires included items on both nasal appearance and nasal function. None of these surveys was directly applicable to our primary interest, which was to evaluate patient satisfaction with isolated nasal tip reconstruction. These validated metrics were, however, useful to review when developing the patient survey that was utilized in this study. All of these scales consist of short questionnaires in which patients were asked to rank their satisfaction with several aspects of

their outcome on a five-point Likert scale. The survey utilized in this study incorporated many aspects from these previously validated scales but tailored the questions to more directly apply to nasal tip appearance. Patients were asked to grade their satisfaction for seven discrete aspects of nasal tip reconstruction as follows: color match to surrounding skin, nasal tip contour, nasal tip shape, nasal tip symmetry, nasal profile shape, overall nasal appearance, and overall satisfaction with nasal reconstruction.

Although the adipofascial flap has been demonstrated to have similar aesthetic outcomes to the forehead flap for large nasal tip defects, there are situations in which the forehead flap remains a more appropriate reconstructive option. When deciding which reconstructive technique to use, one should first evaluate the extent of the nasal defect. Although the adipofascial flap has been successfully used in our institution for defects up to 5 cm<sup>2</sup>, the algorithm for choosing between the reconstructive options is not strictly dependent upon size of the nasal defect. Rather, it is dependent upon the size of the nasal defect in relation to the size of the patient's nose. To successfully perform this technique, there must be adequate preserved length of the adipofascial tissue along the nasal dorsum. This length should be equal to the vertical length of the nasal defect plus an additional 6–8 mm to account for the length required for the turnover point. Therefore, this flap may not be a feasible reconstructive option if the defect involves a substantial portion of the nasal dorsum. The adipofascial turnover flap can be considered for defects involving more than one nasal subunit if it involves the nasal tip and columella; however, if the defect involves the tip and ala, it is not sufficient to resurface the

entire area, and an additional or alternative reconstructive modality should be considered. If the defect involves a through-and-through defect, an additional locoregional flap should be incorporated for internal nasal lining or external coverage, as the adipofascial turnover flap alone would not be sufficient, especially if a cartilage graft is required.<sup>11</sup> (Fig. 5).

This study is not without limitations. Notably, this was a single surgeon retrospective investigation. This study had a relatively small sample size of 32 total patients. All patients were White. Patients who declined to participate in the patient satisfaction survey or whose photographs were unavailable for review by the panel of plastic surgeons represent an additional source of bias. There was likely an element of selection bias, as the groups were unevenly distributed due to the nature of retrospective chart review. The forehead flap patients did trend toward having larger defects than the adipofascial group, as defect size was not controlled for in this retrospective study. Indeed, the average defect size treated with the adipofascial turnover flap (2.9 cm<sup>2</sup>) was substantially smaller than the average defect size that was treated with the forehead flap (10.4 cm<sup>2</sup>). As the adipofascial turnover flap was incorporated into the senior author's practice, it quickly replaced the forehead flap for nasal tip defects more than 1.5 cm<sup>2</sup>, while the forehead flap was reserved for very large defects typically involving multiple nasal subunits. This represents a limitation for the comparison of the two techniques. Likewise, given the retrospective nature of the study, the timing of postoperative photographs was not standardized. This was analyzed, however, and timing of the postoperative photographs (less than 6

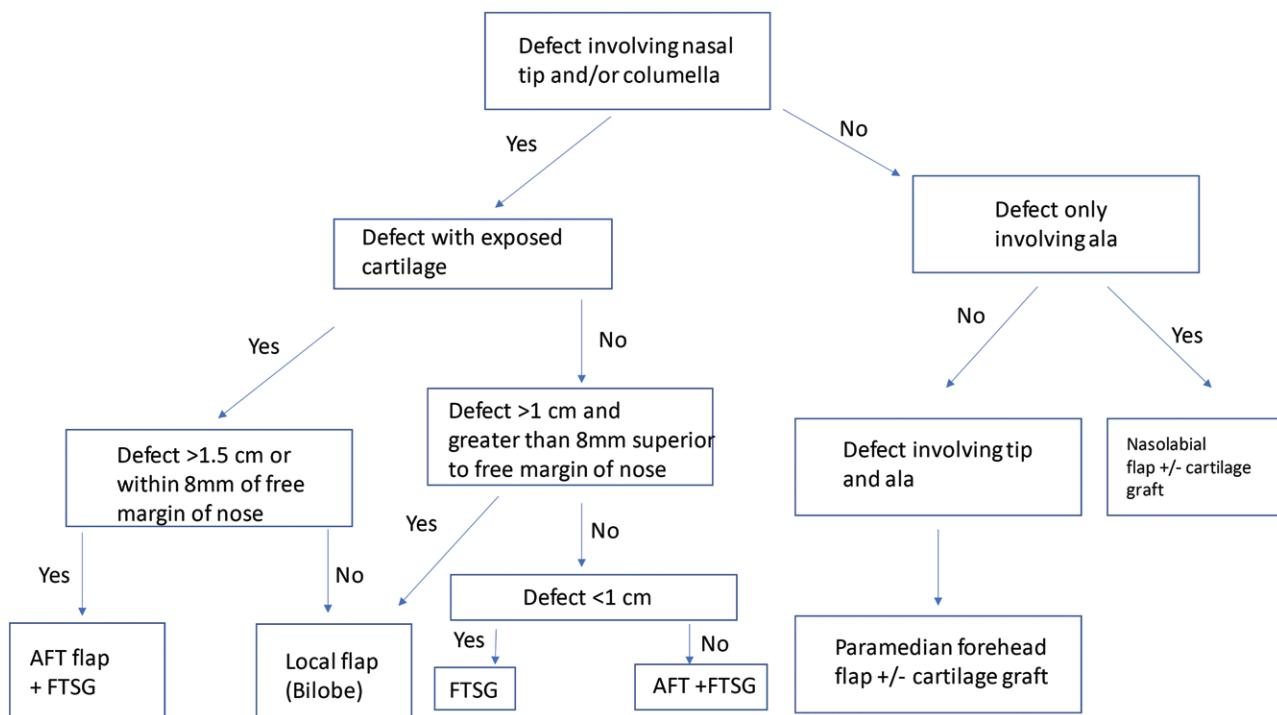


Fig. 5. Algorithm for determining reconstruction technique based on defect size and location.

months versus more than 6 months) was not a significant factor in the rankings of postoperative photographs by the surgeon panel. A final source of potential error was the method with which photographs were masked. We intended to conceal which method of reconstruction was used by obscuring the forehead, which would show a scar if a forehead flap had been utilized; however, the nasal dorsum and lateral cheek were not masked, which could potentially inform the viewer whether an adipofascial flap with full thickness skin grafting from a preauricular donor site was utilized. Ultimately it was decided that masking the nasal dorsum would limit the panel's ability to judge the overall reconstruction. Likewise, it was decided that masking the lateral cheek would not be necessary as scars in this area could be attributed to other procedures such as a previous reconstruction or facelift. Additionally, other skin graft donor sites were occasionally used.

### CONCLUSIONS

Overall, the single-stage adipofascial turnover flap with full-thickness skin grafting provides similar aesthetic outcomes compared with the two-stage forehead flap when reconstructing large defects of the nasal tip. The only category in which the adipofascial turnover flap was not considered equal to the forehead flap by patient-reported metrics was in color match of the reconstruction to the surrounding nasal skin. Otherwise, the two groups were rated similarly by both patient-reported metrics and by photographic analysis reviewed by a panel of plastic surgeons. The satisfactory and reliable aesthetic appearance of the adipofascial turnover flap with skin grafting for nasal reconstruction is supported by both patient-reported outcome measures and standardized photographic analysis by a panel of board-certified and board-eligible plastic surgeons.

**Anthony E. Capito, MD, FACS**  
 3 Riverside Circle, Suite 400  
 Roanoke, VA 24016  
 E-mail: [Aecapito@carilionclinic.org](mailto:Aecapito@carilionclinic.org)  
 Instagram: @vtcplasticsurgery

### DISCLOSURE

*The authors have no financial interest to declare in relation to the content of this article.*

### PATIENT CONSENT

*The patients provided written consent for the use of their images.*

### REFERENCES

- Correa BJ, Weathers WM, Wolfswinkel EM, et al. the forehead flap: the gold standard of nasal soft tissue reconstruction. *Semin Plast Surg.* 2013;27:96–103.
- Menick FJ. Nasal Reconstruction. *Plast Reconstr Surg.* 2010;125:138e–150e.
- Sankaran PS. *Sushruta's Contribution to Surgery.* Varanasi, India: Indological Book House; 1976.
- Başağaoğlu B, Ali K, Hollier P, et al. Approach to reconstruction of nasal defects. *Semin Plast Surg.* 2018;32:75–83.
- Gallagher TM, Capito AE. Single-stage adipofascial turnover flap as an alternate option for large nasal defects usually requiring two-stage forehead flap. *Plast Reconstr Surg.* 2020;146:1371–1375.
- Ribuffo D, Serratore F, Cigna E, et al. Nasal reconstruction with the two stages vs three stages forehead flap. A three centres experience over ten years. *Eur Rev Med Pharmacol Sci.* 2012;16:1866–1872.
- Menick FJ. Aesthetic refinements in use of forehead for nasal reconstruction: the paramedian forehead flap. *Clin Plast Surg.* 1990;17:607–622.
- Menick FJ. 10-year experience in nasal reconstruction with the three-stage forehead flap. *Plast Reconstr Surg.* 2002;109:1839–1855. ; discussion 1856-1861.
- Durgun M, Özakpınar HR, Selçuk CT, et al. Repair of full-thickness nasal alar defects using nasolabial perforator flaps. *Ann Plast Surg.* 2015;75:414–417.
- Burget GC. Aesthetic restoration of the nose. *Clin Plast Surg.* 1985;12:463–480.
- Capito AE. Reply: single-staged adipofascial turnover flap as an alternative option for large nasal defects usually requiring two-staged forehead flap. *Plast Reconstr Surg.* 2021;148:508e–509e.
- Klassen AF, Cano SJ, Scott A, et al. Measuring patient-reported outcomes in facial aesthetic patients: development of the FACE-Q. *Facial Plast Surg.* 2010;26:303–309.
- Lee MK, Most SP. A comprehensive quality-of-life instrument for aesthetic and functional rhinoplasty: the RHINO scale. *Plast Reconstr Surg Glob Open.* 2016;4:e611.
- Lohuis PJFM, Hakim S, Duivesteijn W, et al. Benefits of a short, practical questionnaire to measure subjective perception of nasal appearance after aesthetic rhinoplasty. *Plast Reconstr Surg.* 2013;132:913e–923e.
- Moolenburgh SE, Mureau MA, Duivenvoorden HJ, et al. Validation of a questionnaire assessing patient's aesthetic and functional outcome after nasal reconstruction: the patient NAFEQ-score. *J Plast Reconstr Aesthet Surg.* 2009;62:656–662.