



Contents lists available at ScienceDirect

International Journal of Surgery Case Reports

journal homepage: www.casereports.com

Simultaneous peritoneal and retroperitoneal splenosis mimics metastatic right adrenal mass

Abdelwahab Hashem*, M.A. Elbaset, Mohamed H. Zahran, Yasser Osman

Urology and Nephrology Center, Mansoura University, Egypt

ARTICLE INFO

Article history:

Received 19 January 2018

Received in revised form 11 May 2018

Accepted 19 May 2018

Available online 5 June 2018

Keywords:

Case report

Adrenal

Adrenal incidentalomas

Splenosis

Retroperitoneum

Peritoneum

ABSTRACT

INTRODUCTION: Right retroperitoneal splenosis is rare with few reported cases. We report, here, the case of simultaneous peritoneal and retroperitoneal splenosis mimics metastatic right adrenal mass.

PRESENTATION OF CASE: A 28-year-old man who had previously undergone post traumatic splenectomy at childhood and subsequently presented with an large incidental non-functioning right adrenal mass with presence of extra-hepatic peritoneal focal lesion diagnosed as metastasis by magnetic resonance imaging (MRI). Adrenalectomy with metatstectomy was performed, and both masses were identified to be splenosis.

DISCUSSION: Adrenal incidentalomas (AIs) is defined as asymptomatic masses >1 cm. on cross-sectional imaging studies. AIs have significant malignant potential for masses > 6cm. Splenosis are found most frequently in the left retroperitoneum in cases involving retroperitoneal splenosis. However, right retroperitoneal splenosis have been reported. Traditional imaging techniques cannot differentiate splenosis from malignancy.

CONCLUSION: Large right adrenal incidentalomas present with other abdominal, peritoneal masses could be splenosis in patient following post-traumatic splenectomy.

© 2018 The Author(s). Published by Elsevier Ltd on behalf of IJS Publishing Group Ltd. This is an open access article under the CC BY-NC-ND license (<http://creativecommons.org/licenses/by-nc-nd/4.0/>).

1. Introduction

Incidental discovered adrenal mass (adrenal incidentalomas "AIs") has a widespread diversity of differential diagnosis [1,2]. Beside these, some rare causes still involved. One of rare causes of AIs is splenosis, defined as heterotopic autotransplantation and implantation of viable splenic tissue after either splenic trauma or surgery most commonly located within the peritoneal cavity [3].

In spite of the fact that splenosis is a benign mass can be diagnosed through Tc-99m labeled heat-damaged autologous red blood cell single-photon emission computed tomography (SPECT-CT) imaging, avoiding surgical intervention [4]. A review of >1300 patients with Adrenal incidentalomas revealed that incidence of malignant potential significantly increased for masses >6 cm in diameter and should be considered malignant until proven otherwise, almost always requiring definitive resection [5]. In all previous reported cases of adrenal splenosis the mass size ranged from 3.4 to 6 cm [2,3,6–8] which can have lower possibility of being malignant.

2. Presentation of case

A 28-year-old male was referred to our outpatient clinic complaining of non-specific abdominal pain. He underwent splenectomy for ruptured spleen since 2000. All laboratory parameters were normal including the hormonal work up for the adrenal hyperfunction.

MRI of the abdomen revealed a 7.8 × 9.4 cm right supra-renal (non-adenomatous) mass with intermediate SI at T₂ WI and no drop in SI at out phase chemical shift in close relation to liver and upper pole of the kidney. In addition, there was extra hepatic peritoneal focal lesion related to lateral aspect of segment VI of the liver measured 2.5 × 2 × 1 cm (mostly metastatic) (Fig. 1). Chest CT scan was free and bone scan confirmed no evidence of bony metastatic deposits.

During adrenalectomy, extra hepatic peritoneal focal lesion identified at the surface of right lobe of the liver and was resected (Fig. 2). Histopathological examination showed normal splenic red and white pulp components including lymphoid follicles with germinal center formation with normal supra renal tissue and no malignancy and accessory peritoneal mass showed same findings consistent with splenosis (Fig. 3). The patient had smooth postoperative course.

* Corresponding author.

E-mail address: abdelwahab.hashem@yahoo.com (A. Hashem).

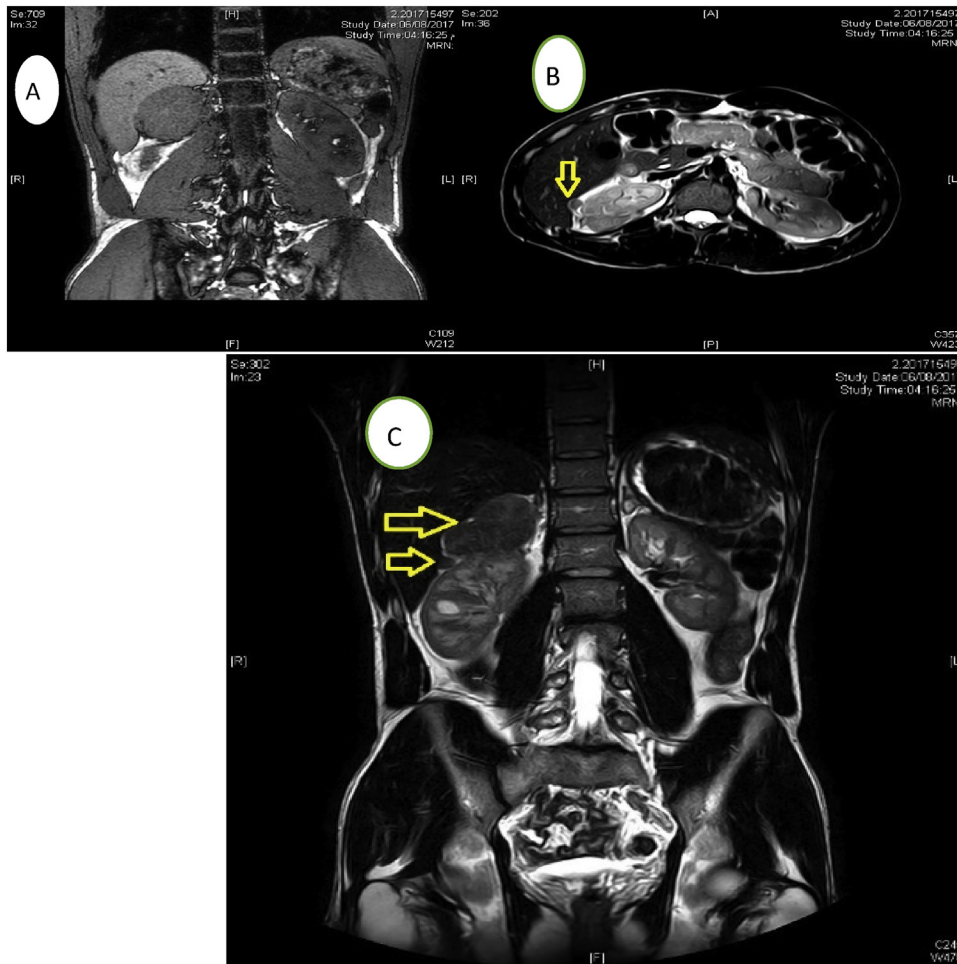


Fig. 1. (A) MRI reformatting image showing right supra renal mass measuring about 9.4×7.8 cm. (B) Extra hepatic peritoneal focal lesion related to lateral aspect of segment VI of the liver measured $2.5 \times 2 \times 1$ cm. (C) Reformatting image of MRI showing both lesions.

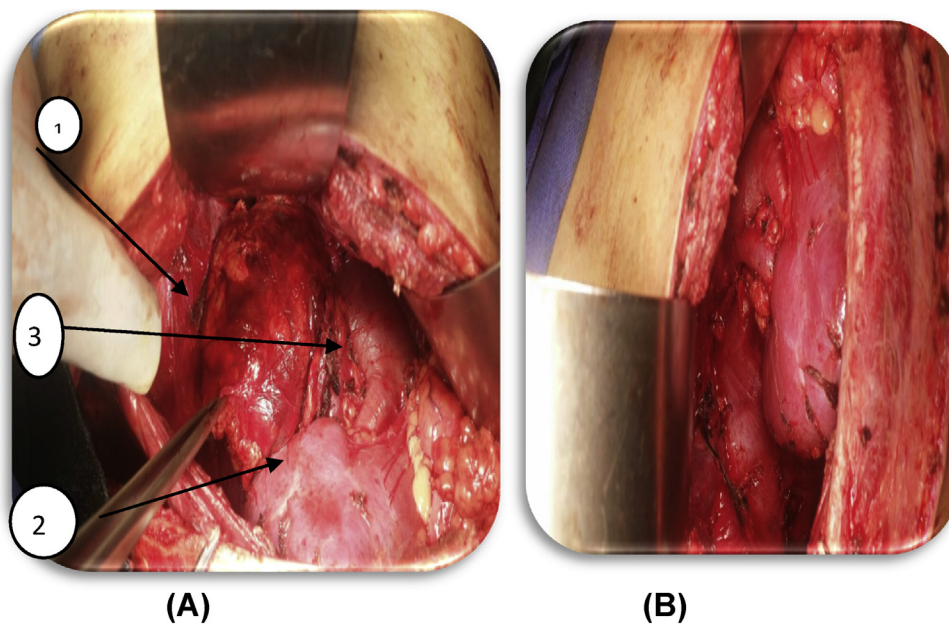


Fig. 2. (A) Intraoperative findings: (1) Right supra renal mass (2) Right renal unit (3) Inferior Vena Cava (IVC). (B) Right supra renal bed after removal of the mass.

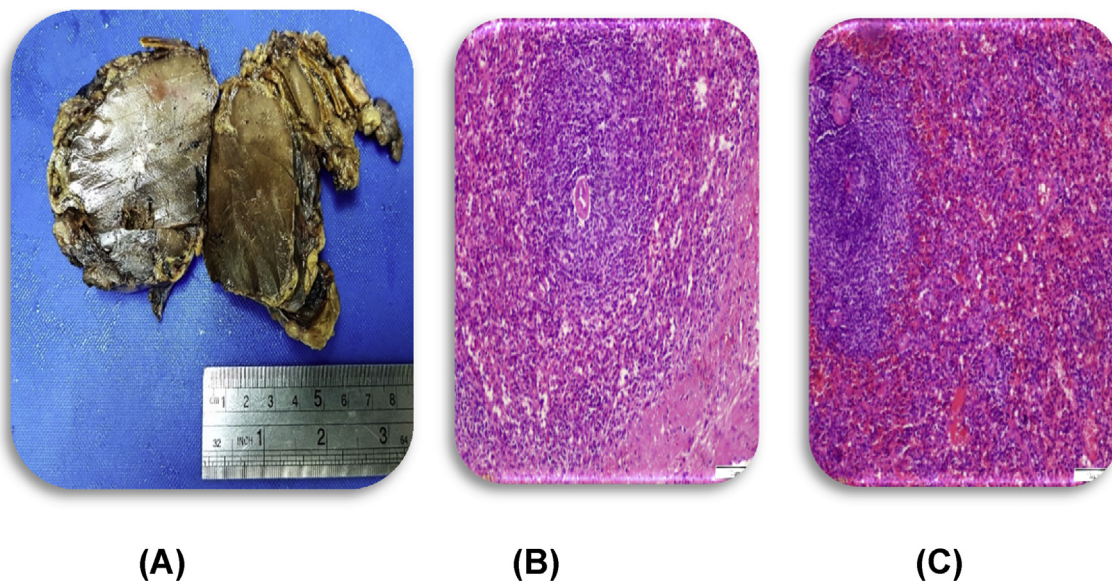


Fig. 3. (A) Gross picture of the mass “opened” (B&C). Pathological findings normal splenic red and white pulp components including lymphoid follicles with germinal center formation with normal supra renal tissue and no malignancy and accessory peritoneal mass showed same findings consistent with splenosis “Magnification × 1000”.

3. Discussion

Adrenal incidentalomas (AIs) is defined as asymptomatic masses >1 cm. in on cross-sectional imaging studies performed for reasons unrelated to adrenal disease. AIs have significant malignant potential for masses > 6 cm in diameter, so should be considered malignant until proven otherwise and always requiring definitive resection [8,9]. The majority of AIs are nonfunctional, benign lesions that account for 82.5% of cases including adenomas (61%), myelolipomas (10%), adrenal cysts (6%), and ganglioneuromas (5.5%), cortisol-secreting adenomas (5.3%), pheochromocytomas (5.1%), adrenocortical carcinomas (4.7%), metastatic lesions (2.5%), and aldosteronomas (1%) [12].

Auto-transplantation of splenic parenchyma at the time of trauma or after splenectomy for traumatic splenic rupture known as splenosis may mimics AIs especially if retroperitoneal implanted which is atypical. In all previously reported cases of adrenal splenosis mimicking AIs, masses size ranged from 3 to 6 cm [3,4,6,7,10]. Splenosis are found most frequently in the left retroperitoneum in cases involving retroperitoneal splenosis. However, right retroperitoneal splenosis have been reported [3,4,6,7]. Our case have the larger size 7.8 × 9.4 cm. Beside the large size, synchronous splenosis at anterior peritoneum. The differential diagnosis of abdominal splenosis may include metastatic disease, pheochromocytoma, lymphoma, carcinomatosis, hepatic or renal malignancy, endometriosis, or simple adenopathy. Traditional imaging techniques cannot differentiate splenosis from malignancy [4].

Though Tc-99m labeled heat-damaged autologous red blood cell SPECT-CT scan had a 32% greater diagnostic yield when directly compared to sulfur colloid scan in detection of splenosis, we proceed for exploration due to abnormal finding by 3-T MRI not in favor of benign lesion and didn't perform SPECT-CT scan as prominent activity is normally seen in liver and kidneys in splenectomized patients [11]. Also, adrenal masses > 6 cm in diameter and malignancy should be considered malignant. [5].

To the best of our knowledge, this is the first report for simultaneous peritoneal and retroperitoneal splenosis mimicking metastatic right adrenal mass.

4. Conclusion

Large right adrenal incidentalomas present with other abdominal, peritoneal masses could be splenosis in patient following post-traumatic splenectomy.

Conflict of interest

The authors declare that they have no conflict of interests.

Funding

None.

Ethical approval

Approval of the Institutional Review Board according to publish this case report was obtained. This case report manuscript follows the surgical case report (SCARE) Guidelines (12).

Consent

Written informed consent was obtained from the patient for publication of this case report and accompanying images.

Author's contribution

Abdelwahb Hashem: Manuscript writing.
 Abdelbaset MA: Data collection and manuscript editing.
 Mohamed H Zahran: Manuscript revision.
 Yasser Osman: Manuscript revision and editing.

Registration of research studies

None.

Guarantor

Yasser Osman.
 Abdelwahab Hashem.

References

- [1] S. Chodiseti, Y. Boddepalli, M. Kota, Giant adrenal cyst displacing the right kidney, *Indian J. Urol: IJU: J. Urol. Soc. India* 32 (1) (2016) 81–82.
- [2] C. Davenport, A. Liew, B. Doherty, H.H.N. Win, H. Misran, S. Hanna, et al., The prevalence of adrenal incidentaloma in routine clinical practice, *Endocrine* 40 (1) (2011) 80–83.
- [3] K.T. Perry Jr., A. Zisman, J. Singer, P. Schulam, Splenosis presenting as a right suprarenal retroperitoneal mass, *J. Urol.* 168 (2) (2002) 644–645.
- [4] M. Felice, M. Tourojman, C. Rogers, Right retroperitoneal splenosis presenting as an adrenal mass, *Urol. Case Rep.* 16 (2018) 44–45.
- [5] L. Barzon, N. Sonino, F. Fallo, G. Palu, M. Boscaro, Prevalence and natural history of adrenal incidentalomas, *Eur. J. Endocrinol.* 149 (4) (2003) 273–285.
- [6] M. Louie-Johnsun, D. Gilbourd, Unusual retroperitoneal splenosis confirmed by laparoscopic retroperitoneal excisional biopsy, *ANZ J. Surg.* 82 (10) (2012) 758.
- [7] M. Valli, P. Arese, G. Gallo, D. Flecchia, Right retroperitoneal splenosis presenting as an adrenal mass, *Eur. J. Surg.* 165 (12) (1999) 1197–1198.
- [8] W.F. Young, Management approaches to adrenal incidentalomas: a view from Rochester, Minnesota, *Endocrin. Metab. Clin. North. Am.* 29 (1) (2000) 159–185.
- [9] Health Nlo, NIH state-of-the-science conference statement on manifestations and management of chronic insomnia in adults, *NIH Consens. Sci. Statements* 22 (2005) 1–30.
- [10] C.P. Melon, J.E. Morcillo, C. Salgado, M.C. Bande, E.A. Rodriguez, A.O. González, Incidentaloma due to abdominal splenosis, *Nephron* 80 (3) (1998) 359–360.
- [11] I. Gunes, T. Yilmazlar, I. Sarikaya, T. Akbunar, C. Irgil, Scintigraphic detection of splenosis: superiority of tomographic selective spleen scintigraphy, *Clin. Radiol.* 49 (2) (1994) 115–117.
- [12] R.A. Agha, A.J. Fowler, A. Saeta, I. Barai, S. Rajmohan, D.P. Orgill, et al., The SCARE statement: consensus-based surgical case report guidelines, *Int. J. Surg.* 34 (2016) 180–186.

Open Access

This article is published Open Access at [sciencedirect.com](https://www.sciencedirect.com). It is distributed under the [IJSCR Supplemental terms and conditions](#), which permits unrestricted non commercial use, distribution, and reproduction in any medium, provided the original authors and source are credited.