

Zinner's syndrome: Case report of a rare maldevelopment in the male genitourinary tract

Ahmed M. Almuhanha^{a,*}, Shaheed Alsuhaibani^b, Razan Almesned^c, Ashraf Almatar^d, Hamed Alali^d

^a Urology Department, King Fahad Hospital, Al-Ahsa, Saudi Arabia

^b Urology Department, King Fahad Hospital, Imam Abdulrahman Bin Faisal University, Saudi Arabia

^c Urology Department, King Faisal Specials Hospital, Riyadh, Saudi Arabia

^d Urology Department, King Fahad Specials Hospital, Dammam, Saudi Arabia

ARTICLE INFO

Keywords:

Infertility
Zinner syndrome
Pregnancy
Case report

ABSTRACT

Zinner syndrome is a rare congenital malformation of the urogenital tract. It is due anomaly in the developmental of Wolffian duct. Zinner syndrome comprises triad of seminal vesicle cyst, unilateral renal agenesis and ipsilateral ejaculatory duct obstruction. It is frequently associated with infertility. Herein we are highlighting a case of a 35 years-old male, a father of 4 biological children who presented to our clinic due to right hemiscrotal pain, associated with post ejaculation pain.

1. Introduction

Zinner syndrome is a rare congenital condition consists a typical triad of seminal vesicle cyst, ipsilateral renal agenesis and ejaculatory duct obstruction.¹ Symptoms tend to manifest with the beginning of sexual activity due to accumulation of seminal fluid in the seminal vesicles.² Due to the underlying ejaculatory duct obstruction, males with Zinner syndrome usually have abnormal semen parameters and present with infertility that requires surgical intervention.^{2,3} When Zinner syndrome is suspected, MRI is the diagnostic test of choice.⁴ In this report we highlight a case of a 35 years-old male, a father of 4 biological children who presented to our clinic due to chronic intermittent right hemiscrotal and associated with post ejaculation pain.

2. Case report

A 35 year-old male father of 4 biological children all as a product of spontaneous pregnancy. Presented to clinic complaining of recurrent, mild intermittent right hemiscrotal pain radiating to right flank which was treated as case of chronic epididymitis with long course of antibiotics. The pain is associated with suprapubic pain, dysuria and post ejaculation pain. The symptoms started since he became sexually active. Physical examination revealed no palpable pelvic mass, with normally developed external genitalia, vas deferents was bilaterally palpable with

tenderness of right epididymis tenderness. Digital rectal examination (DRE) was painless, intact anal tone with a normal prostate volume and consistency. Semen analysis showed no abnormalities (Table 1).

CT scan was done in another hospital, which showed right renal agenesis. For explanation of recurrent presentation MRI was done and the findings were consistent with Zinner syndrome. MRI showed right sided cystic dilatation of the seminal vesicles with a maximum diameter of 1.8 cm which extends to the pelvis. As well as ejaculatory duct obstruction, contralateral ejaculatory duct compression and seminal vesicle dilatation (Figs. 1 and 2).

3. Discussion

Zinner's syndrome remains a rare congenital malformation with only 200 cases reported of seminal vesicles cysts associated with ipsilateral renal agenesis.² Therefore, it is difficult to determined its incidence.

Initially, males with Zinner syndrome are asymptomatic and symptoms tend to start with intensive sexual activity due to insufficient drainage and accumulation of seminal fluid in the seminal vesicles.²

Zinner syndrome can present with wide range of symptoms that are not specific. It can present with voiding symptoms, impaired defecation, hematuria, urogenital tract infections, perineal or scrotal pain and ejaculatory disorders. The ejaculatory disordered previously described in the literature are in the form of pain following ejaculation, infertility

* Corresponding author.

E-mail address: a.almuhanna4@hotmail.com (A.M. Almuhanha).

<https://doi.org/10.1016/j.eucr.2021.101839>

Received 29 August 2021; Received in revised form 4 September 2021; Accepted 8 September 2021

Available online 14 September 2021

2214-4420/© 2021 Published by Elsevier Inc. This is an open access article under the CC BY-NC-ND license (<http://creativecommons.org/licenses/by-nc-nd/4.0/>).

Table 1
Semen analysis at the time of presentation.

Parameter	Patient	Normal value
Volume (ml)	1.5	≥ 1.5
pH	8	≥7.2
Sperm count (sperms/ml)	62 million	≥15 million
Total sperm (sperms/ejaculate)	93 million	≥39 million
Motility (%)	65	≥40
Progressive (%)	50	≥32
Normal forms (%)	60	≥4

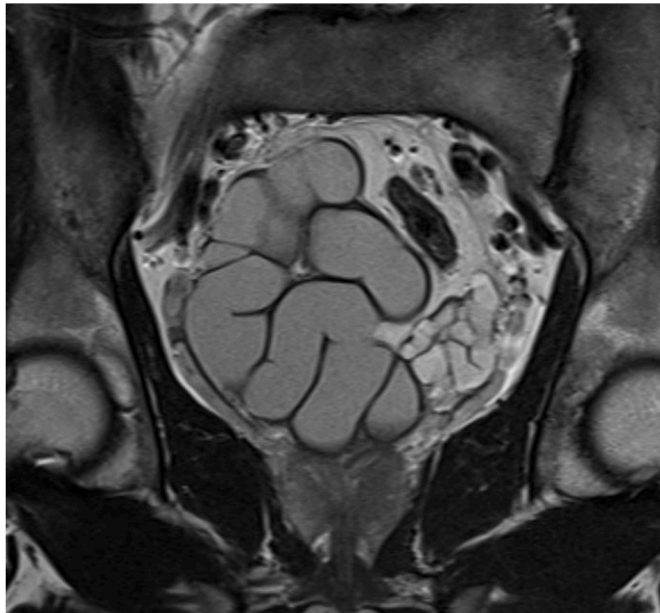


Fig. 1. MRI, coronal section showing dilated right seminal vesical with mild dilated left seminal vesicle due to contralateral compression.

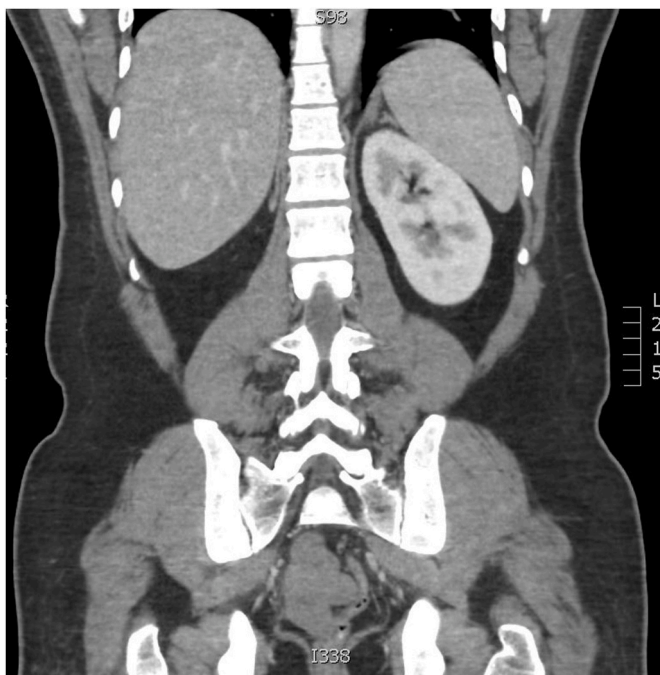


Fig. 2. CT coronal section of the Kidney, abdomen and pelvis showing right renal agenesis.

and hematospermia²

The pathogenesis of infertility is not well understood since those patients have intact contra lateral ejaculatory duct. However, it have been suggested that the unilateral obstruction can lead to the development of autoantibodies against the sperms.² Therefore, further studies should be conducted to identify the pathomechanism of infertility associated with Zinner syndrome.

Given the rarity of this syndrome, it is difficult to determine the fertility status. In 1998 a pooled analysis of 52 men with the syndrome, only 20 cases reported fertility status showed a 45% infertility rate.³ Updated studies that include all reported cases and look into the fertility status in patients with Zinner syndrome should be conducted in order to have a better understanding of the fertility outcome in those patients and offer the follow up and management accordingly.

Semen parameters for men with Zinner syndrome tend to be abnormal, in the form of azoospermia and azoospermia.⁵ There is one reported case of a 21-year-old male with normal semen parameters.¹ Such unusual findings should be followed-up to report future fertility outcome and changes in semen parameters. The Presented case have 4 kids with completely normal semen analysis without any surgical intervention. Management of seminal vesicle cysts depends on the size and presenting symptoms as well as its complications.² Treatment modalities including conservative management by percutaneous drainage and transurethral or transrectal aspiration, but both are associated with greater risk of recurrence. Surgical procedure is the mainstay in management of symptomatic, complicated and recurrent cyst by either open approach or laparoscopic transperitoneal approach.^{2,3}

In our case, since mild pain was the only complaint the patient desired to go with conservative management with regular follow up.

4. Conclusion

Zinner syndrome is a rare urogenital anomaly. Although these patients tend to present with infertility, achieving spontaneous pregnancy is possible because of normal contralateral side. Thus, Zinner syndrome should be kept in mind even in the absence of infertility.

References

1. Florim S, Oliveira V, Rocha D. Zinner syndrome presenting with intermittent scrotal pain in a young man. *Radiology Case Reports*. 2018;13(6):1224–1227.
2. Pereira BJ, Sousa L, Azinhais P, et al. "Zinner's syndrome: an up-to-date review of the literature based on a clinical case. *Andrologia*. 2009;41(5):322–330.
3. van den Ouden D, Blom JHM, Bangma C, de Spiegeleer AHVC. Diagnosis and management of seminal vesicle cysts associated with ipsilateral renal agenesis: a pooled analysis of 52 cases. *Eur Urol*. 1998;33(5):433–440.
4. Sundar R, Sundar G. *Zinner Syndrome: An Uncommon Cause of Painful Ejaculation*. vol. 2015. *Case Reports*; 2015. bcr2014207618 pages.
5. Hofmann A, Vauth F, Roesch WH. Zinner syndrome and infertility—a literature review based on a clinical case. *Int J Impot Res*. 2021 Mar;33(2):191–195. <https://doi.org/10.1038/s41443-020-00360-0>. Epub 2020 Nov 5. PMID: 33149231.