



Case Report

Infantile Hemiconvulsion-Hemiplegia and Epilepsy (IHHE) in a boy with tuberous sclerosis complex



Chariton Moschopoulos, Jurriaan M. Peters, Masanori Takeoka, Coral M. Stredny*

Department of Neurology, Division of Epilepsy and Clinical Neurophysiology, Boston Children's Hospital, Harvard Medical School, 300 Longwood Avenue, Boston, MA 02115, USA

ARTICLE INFO

Article history:

Received 15 April 2021

Revised 25 July 2021

Accepted 2 August 2021

Available online 6 August 2021

Keywords:

Tuberous sclerosis complex

Infantile Hemiconvulsion-Hemiplegia and Epilepsy

New-Onset Refractory Status Epilepticus

ABSTRACT

Tuberous sclerosis complex (TSC) is a rare autosomal dominant disease due to pathogenic variants in TSC1 or TSC2 genes. In the brain, TSC is associated with multiple cortical and subcortical malformations including tubers and abnormalities of radial neuronal migration. Approximately 80% of patients develop epilepsy in the first two years of life, most often focal seizures and infantile spasms. As with all seizure disorders, systemic illness and fever can trigger a seizure, and result in status epilepticus or even refractory status epilepticus. Infantile Hemiconvulsion-Hemiplegia and Epilepsy (IHHE) is considered a subcategory of new-onset refractory status epilepticus (NORSE) and presents with hemiclonic seizures in the setting of fever, unihemispheric brain imaging abnormality and hemiparesis. Here, we present an 18-month-old boy with TSC who developed IHHE. His extensive brain malformations and neuronal hyperexcitability in peri-tuberal tissue could have predisposed him to IHHE. In addition to these factors, we postulate that another prerequisite for IHHE is likely a genetic predisposition for an excessive inflammatory response that is yet to be elucidated.

© 2021 The Author(s). Published by Elsevier Inc. This is an open access article under the CC BY-NC-ND license (<http://creativecommons.org/licenses/by-nc-nd/4.0/>).

1. Introduction

Tuberous sclerosis complex (TSC) is a rare autosomal dominant disorder with an incidence of 1 in 6000 live births [1]. Pathogenic variants in TSC1 or TSC2 genes on chromosome 9q34 and 16q13, respectively [2,3], lead to hyperactivation of the mammalian target of rapamycin complex 1 (mTORC1) signalling network [4]. While the clinical phenotype is variable, the main neurologic manifestations include autism, intellectual disability and epilepsy [5]. Individuals with TSC present with clinical (focal motor seizures and infantile spasms) and subclinical seizures with a lifetime prevalence of 85% [5,6]. Interictal epileptiform activity and subclinical seizures are often seen on EEG prior to the onset of clinical seizures [6,7]. Infantile spasms are treated with vigabatrin as a first line antiseizure medication (ASM) and focal seizures are treated similarly to patients without TSC [8].

Despite being a potential life-threatening complication seen in over half of patients with TSC, there is a paucity of literature on status epilepticus in this population [9]. Infantile Hemiconvulsion-Hemiplegia and Epilepsy (IHHE) is a rare syndrome characterized by status epilepticus with hemiclonic seizures in the setting of

fever. Unihemispheric brain imaging abnormalities and development of hemiparesis are hallmarks of IHHE [10]. Association with cortical malformations has been reported but IHHE remains very rare, even in patients with a high tuber burden, perhaps due to the need for a genetic propensity for excessive inflammatory responses. We present a case of an 18-month-old boy with TSC who presented with refractory status epilepticus that evolved into IHHE.

2. Case report

An 18-month-old boy had onset of epilepsy at 3 months of age. Initial focal motor seizures were characterized by behavioral arrest, eye blinking, left gaze deviation and oral automatisms. EEG showed ictal onset in the right posterior quadrant and seizures were controlled with oxcarbazepine. Medical and family history were otherwise unremarkable. Exam revealed scattered hypopigmented macules. MRI showed subependymal nodules and subcortical tubers (Fig. 1A). No supendymal giant cell tumors (SGCTs), cardiac rhabdomyomas or angiomyolipomas were identified. Based on the combination of focal motor seizures, hypopigmented macules and MRI brain findings, TSC was suspected. Genetic evaluation showed a pathogenic TSC2 frameshift variant.

Next, he developed infantile spasms, with an immediate response to vigabatrin. EEG at 4 months of age showed bilateral

* Corresponding author at: Department of Neurology, Division of Epilepsy and Clinical Neurophysiology, Boston Children's Hospital, 300 Longwood Ave, Fegan 11, Boston, MA 02115, USA.

E-mail address: coral.stredny@childrens.harvard.edu (C.M. Stredny).

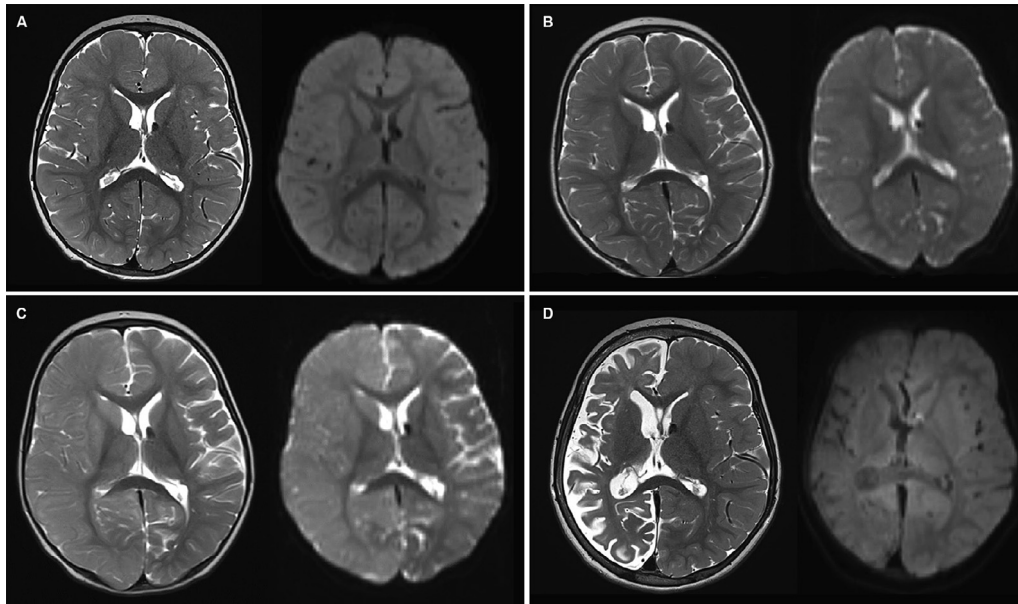


Fig. 1. The composite figure illustrates MRI T2 (left) and DWI (right) sequences (A) 2 months prior to the presentation of IHHE, multifocal tubers with foci of T2 prolongation in the bilateral cerebral hemispheres, some of which showed linear morphology toward the ventricles; lining the lateral ventricles there are ependymal/subependymal nodules; (B) hospital day 2, mild right hemispheric edema; (C) hospital day 10, diffuse swelling and restricted diffusion of the entire right hemisphere; (D) 1 year after the presentation of IHHE, diffuse right hemispheric encephalomalacia.

temporal spikes and slowing in the same regions, but no hypsarrhythmia. He remained seizure-free on oxcarbazepine and vigabatrin for 15 months.

At 18 months of age, he had a left hemiclonic seizure in the context of a febrile illness. Seizure onset occurred out of sleep and was not witnessed, and he was last seen well by his parents 2 h prior. Seizures persisted despite intravenous (IV) diazepam, midazolam, and fosphenytoin. EEG showed right hemispheric seizures with onset in the right fronto-temporal region and spread to the entire right hemisphere (Fig. 2). He was intubated and started on a propofol infusion with resolution of seizures after an estimated duration of 8 h.

Once status epilepticus resolved, EEG showed diffuse right hemispheric polymorphic delta slowing and voltage attenuation. Exam was notable for diminished withdrawal to noxious stimulation on the left. Brain MRI showed mild right hemispheric edema (Fig. 1B). CSF examination for ongoing fever on hospital day 2 showed 0 white blood cells/mm³, 0 red blood cells/mm², protein 18 mg/dL, glucose 80 mg/dL and cultures were negative. Infectious studies, including urine culture, stool studies, viral respiratory panel, Lyme, *Mycoplasma pneumoniae*, arbovirus, and Epstein Barr virus (EBV) titers were negative.

His flaccid left hemiparesis persisted and seizures recurred on hospital day 6 in the setting of vomiting and diarrhea, warranting IV boluses of lorazepam, levetiracetam, and valproic acid. In this setting, brain MRI was repeated on hospital day 10 and showed diffuse swelling and restricted diffusion of the entire right hemisphere (Fig. 1C). Additional diagnostic studies were obtained, including serum antinuclear antibodies (ANA), anti-thyroid peroxidase (TPO)/anti-thyroglobulin, and anti-myelin oligodendrocyte glycoprotein (MOG) that were negative/normal. Serum autoimmune encephalitis panel was positive for low-titer anti-GAD65 (0.10 nmol/L, normal <0.02 nmol/L, Mayo Medical Laboratories). A differential diagnosis for causes of unihemispheric edema and focal status epilepticus, including Rasmussen encephalitis, lupus cerebritis, autoimmune encephalitis, infectious encephalitis, and other structural changes (such as Sturge-Weber syndrome or congenital hemiatrophy (Dyke-Davidoff-Masson syndrome)) were considered and felt to be less likely. Therefore, he was diagnosed

with IHHE and received intravenous immunoglobulin (IVIg) 2 g/kg over 2 days without recurrence of his seizures.

With intact mental status but a dense left hemiparesis, he was discharged to inpatient rehabilitation 2 weeks later. On outpatient follow-up exam 2 years later, he had left spastic hemiplegia, but was able to walk independently. He had minimal fine motor movements of the left hand. His vocabulary was improving but not yet age appropriate. He was seizure free on oxcarbazepine monotherapy. Brain MRI one year after presentation showed diffuse encephalomalacia of the right hemisphere with associated ex vacuo dilatation of the lateral ventricle (Fig. 1D).

3. Discussion

Although seen in the majority of patients, there is a relative paucity of literature on status epilepticus in TSC. In a single cohort of 36 children with TSC, 58% had at least one episode of status epilepticus although the phenotype of IHHE was not noted. Early age of seizure onset, history of infantile spasms, higher tuber burden, presence of SGCTs, intellectual disability and behavioral comorbidities, and active interictal epileptiform discharges in the EEG were associated with increased risk of status epilepticus [9].

Considered a subcategory of new-onset refractory status epilepticus (NORSE), IHHE is an uncommon presentation marked by a prolonged hemiclonic seizure occurring in the setting of fever in a child typically ≤ 2 years of age. These patients have acute unihemispheric imaging abnormalities, followed by hemiparesis and often subsequent epilepsy [10,11]. The resultant hemiplegia is of varying duration (for at least 1 day to 1 week [11,12]), and it is often permanent. It is typically followed by a seizure-free period ranging from 1 to 9 years, and then remote symptomatic and intractable focal epilepsy. Acutely, the brain MRI shows extensive hemispheric edema and restricted diffusion that progresses to hemiatrophy. EEG has been reported to show delta slowing with admixed low amplitude fast activity and rhythmic spikes over the affected hemisphere. There is no clear evidence for acute immunotherapy. Patients may eventually undergo epilepsy surgery for the treatment of chronic drug-resistant epilepsy [10].

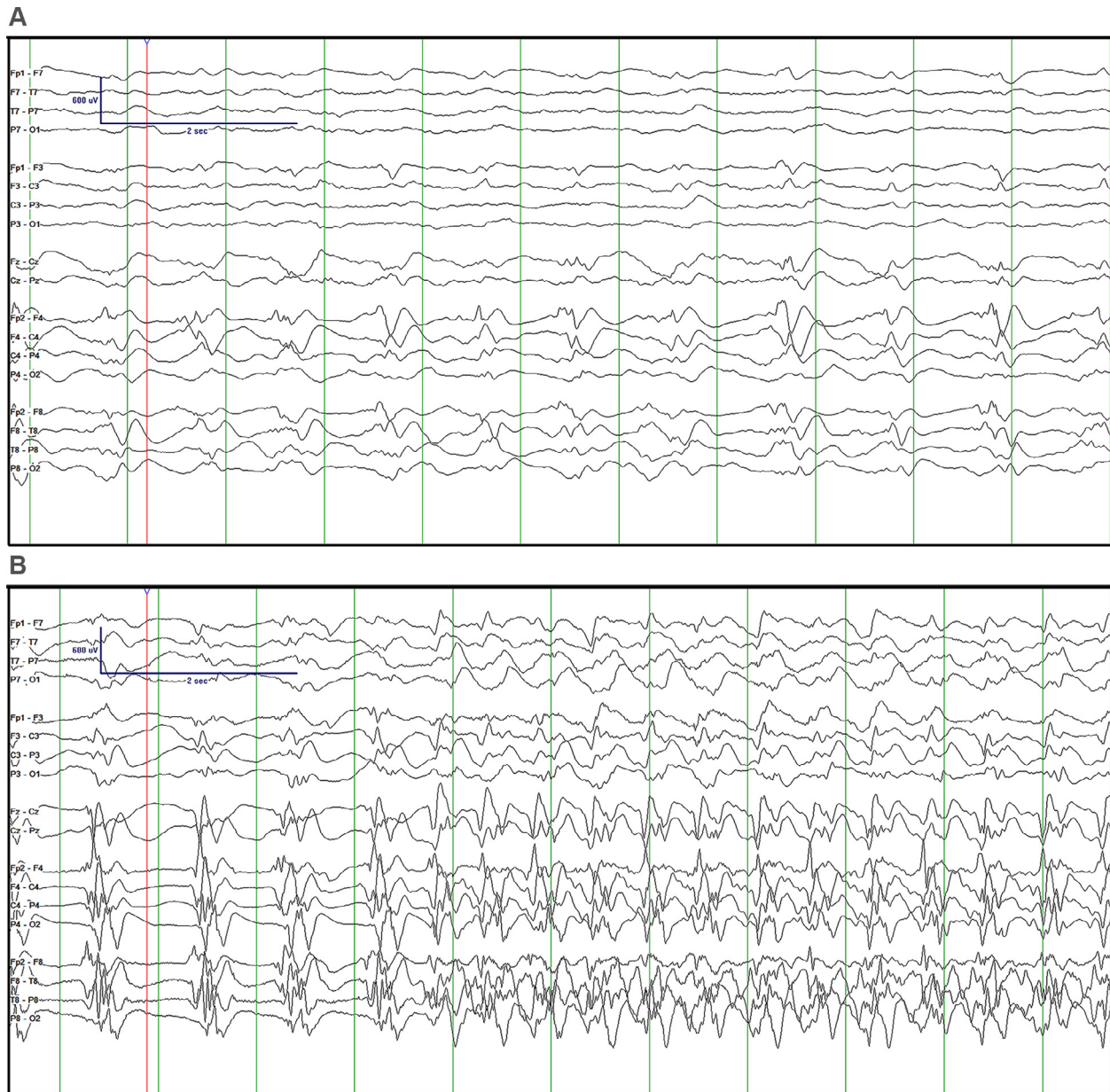


Fig. 2. EEG (anterior–posterior bipolar montage) reveals evolution from right lateralized periodic discharges maximal in the fronto-temporal region (A) to an electrographic seizure involving the right hemisphere (B).

The pathophysiology of IHHE is unknown. Proposed mechanisms include genetic predisposition, cortical malformations or other lesions, and/or infection or inflammation of the affected region of the brain [10]. Many variants, including those in *CACNA1A*, *ATP1A3*, *HNRNPU*, and *SCN1A*, have been noted in patients with IHHE but a common, pathogenic variant is yet to be identified [10,13–15]. Pathological review of post-mortem and resected IHHE brain tissue has commonly shown cortical dysplasia; however, there is a lack of inflammatory cells to support an infectious or inflammatory trigger [16–19]. While specific infections are not usually identified and the CSF is typically bland, there are reports of the co-occurrence of IHHE with Influenza Associated Encephalopathy (IAE) [20,21] and HHV-6 [21]. Of note, elevated interleukin-6 (IL-6) in the CSF was noted in a single patient with IHHE [22], which has similarly been identified in patients with NORSE and febrile-infection related epilepsy syndrome (FIRES). This may offer the opportunity for targeted treatment with tocili-

zumab, an IL-6 receptor antagonist that has been used in adults with NORSE and children with FIRES, after further investigation in IHHE [23,24].

TSC is associated with numerous focal subcortical and cortical malformations, and with increased excitability on a neuronal and glial cell level [25]. The rarity of IHHE in TSC may indicate the requirement of a “third hit”, or genetic predisposition to fuel an exaggerated inflammatory response. We speculate that in this patient, the systemic illness and fever triggered a focal seizure at a known epileptogenic tuber, and a simultaneous regional exaggerated immune response resulted in diffuse unihemispheric inflammation. Particularly in TSC, the mTORC1 signaling network may also be involved in this pathogenesis. Further studies, such as those exploring genetic variants in innate immune system pathways that may lead to immune dysregulation, are needed to explore this triple hit hypothesis and identify additional risk factors that predispose patients with TSC or other cortical malformations to

develop IHHE. Abnormal activation of the innate immune system and pro-inflammatory cytokines may play a role, which could offer the potential for novel immunomodulatory therapies in the acute phase pending further study.

In our case, despite his persistent and significant hemiplegia, he is making remarkable developmental progress. He remains seizure-free at follow-up, although only 2 years from his initial presentation. Notably however, some patients with IHHE may recover without associated weakness or seizures, and further studies are needed to understand the effect of pre-existing neurologic disease on outcomes in these patients.

4. Conclusion

IHHE is characterized by hemiclonic status epilepticus in the setting of a febrile illness in early childhood and has an unclear etiology. The association of IHHE in patients with pre-existing TSC has been identified, however, our case adds a detailed report of this phenotype which is currently lacking in the literature. We postulate a triple hit mechanism: cortical malformation, cell hyperexcitability, and genetic predisposition to produce an exaggerated inflammatory response. Further investigations to understand the pathogenesis of this rare disease are needed to guide therapy.

Ethical statement

None.

CRedit authorship contribution statement

Chariton Moschopoulos: Writing - original draft, Visualization. **Jurriaan M. Peters:** Conceptualization, Validation, Writing - review & editing, Supervision. **Masanori Takeoka:** Writing - review & editing, Validation. **Coral M. Stredny:** Conceptualization, Validation, Writing - review & editing, Supervision.

Declaration of Competing Interest

The authors declare that they have no known competing financial interests or personal relationships that could have appeared to influence the work reported in this paper.

References

- [1] Osborne JP, Fryer A, Webb D. Epidemiology of tuberous sclerosis. *Ann N Y Acad Sci* 1991;615:125–7. <https://doi.org/10.1111/j.1749-6632.1991.tb37754.x>.
- [2] The European Chromosome 16 Tuberous Sclerosis Consortium. Identification and characterization of the tuberous sclerosis gene on chromosome 16. *Cell* 1993;75:1305–15. [10.1016/0092-8674\(93\)90618-Z](https://doi.org/10.1016/0092-8674(93)90618-Z).
- [3] Van Slegtenhorst M, De Hoogt R, Hermans C, Nellist M, Janssen B, Verhoef S, et al. Identification of the tuberous sclerosis gene TSC1 on chromosome 9q34. *Science* (80-) 1997;277:805–8. <https://doi.org/10.1126/science.277.5327.805>.
- [4] Lam HC, Nijmeh J, Henske EP. New developments in the genetics and pathogenesis of tumours in tuberous sclerosis complex. *J Pathol* 2017;241:219–25. <https://doi.org/10.1002/path.4827>.
- [5] Chu-Shore CJ, Major P, Camposano S, Muzykewicz D, Thiele EA. The natural history of epilepsy in tuberous sclerosis complex. *Epilepsia* 2010;51:1236–41. [10.1111/j.1528-1167.2009.02474.x](https://doi.org/10.1111/j.1528-1167.2009.02474.x).
- [6] de Groen AE, Bolton J, Bergin AM, Sahin M, Peters JM. The evolution of subclinical seizures in children with tuberous sclerosis complex. *J Child Neurol* 2019;34:770–7. <https://doi.org/10.1177/0883073819860640>.
- [7] Wu JY, Goyal M, Peters JM, Krueger D, Sahin M, Northrup H, et al. Scalp EEG spikes predict impending epilepsy in TSC infants: A longitudinal observational study. *Epilepsia* 2019;60:2428–36. <https://doi.org/10.1111/epi.16379>.
- [8] van der Poest Clement E, Jansen FE, Braun KPJ, Peters JM. Update on drug management of refractory epilepsy in tuberous sclerosis complex. *Pediatr Drugs* 2020;22:73–84. <https://doi.org/10.1007/s40272-019-00376-0>.
- [9] Shehata HS, Abdelghaffar HM, Nasreldin M, Elmazny A, Abdelalim A, Sabbah A, et al. Clinical patterns and outcomes of status epilepticus in patients with tuberous sclerosis complex. *Ther Clin Risk Manag* 2017;13:779–85. <https://doi.org/10.2147/TCRM.S138576>.
- [10] Auvin S, Bellavoine V, Merdarius D, Delanoë C, Elmaleh-Bergés M, Gressens P, et al. Hemicnvulsion-hemiplegia-epilepsy syndrome: current understandings. *Eur J Paediatr Neurol* 2012;16:413–21. <https://doi.org/10.1016/j.ejpn.2012.01.007>.
- [11] Hirsch LJ, Gaspard N, van Baalen A, Nabhout R, Demeret S, Loddenkemper T, et al. Proposed consensus definitions for new-onset refractory status epilepticus (NORSE), febrile infection-related epilepsy syndrome (FIRES), and related conditions. *Epilepsia* 2018;59:739–44. <https://doi.org/10.1111/epi.14016>.
- [12] Chauvel P, Dravet C. The HHE syndrome. *Epileptic syndromes in infancy, childhood, and adolescence*. 4th ed. Montrouge John Libbey Eurotext; 2005:277–293.
- [13] Boonsimma P, Michael Gasser M, Netbaramee W, Wechapinan T, Srichomthong C, Ittiwut C, et al. Mutational and phenotypic expansion of ATP1A3-related disorders: Report of nine cases. *Gene* 2020;749:144709. <https://doi.org/10.1016/j.gene.2020.144709>.
- [14] Shimada S, Oguni H, Otani Y, Nishikawa A, Ito S, Eto K, et al. An episode of acute encephalopathy with biphasic seizures and late reduced diffusion followed by hemiplegia and intractable epilepsy observed in a patient with a novel frameshift mutation in HNRNPU. *Brain Dev* 2018;40:813–8. <https://doi.org/10.1016/j.braindev.2018.05.010>.
- [15] Kim DW, Lim BC, Kim KJ, Chae JH, Lee R, Lee SK. Low incidence of SCN1A genetic mutation in patients with hemicnvulsion-hemiplegia-epilepsy syndrome. *Epilepsy Res* 2013;106:440–5. <https://doi.org/10.1016/j.epilepsyres.2013.06.012>.
- [16] Mori Y. Anatomopathology and pathogeny of the hemicnvulsion-hemiplegia-epilepsy syndrome. Part II. *J Neurosurg Sci* 1979;22:17–28.
- [17] Mori Y. Anatomopathology and pathogeny of the hemicnvulsion-hemiplegia-epilepsy syndrome. Part I. *J Neuro Sci* 1978;23:1–22.
- [18] Berhouma M, Chekili R, Brini I, Kchir N, Jemel H, Bousnina S, et al. Decompressive hemicraniectomy in a space-occupying presentation of hemicnvulsion-hemiplegia-epilepsy syndrome. *Clin Neurol Neurosurg* 2007;109:914–7. <https://doi.org/10.1016/j.clineuro.2007.07.027>.
- [19] Kim DW, Kim K-K, Chu K, Chung C-K, Lee SK. Surgical treatment of delayed epilepsy in hemicnvulsion-hemiplegia-epilepsy syndrome. *Neurology* 2008;70:2116–22. <https://doi.org/10.1212/01.wnl.0000289192.50924.93>.
- [20] Britton PN, Dale RC, Blyth CC, Macartney K, Crawford NW, Marshall H, et al. Influenza-associated Encephalitis/Encephalopathy Identified by the Australian Childhood Encephalitis study 2013–2015. *Pediatr Infect Dis J* 2017;36:1021–6. [10.1097/INF.0000000000001650](https://doi.org/10.1097/INF.0000000000001650).
- [21] Mizuguchi M, Yamanouchi H, Ichijama T, Shiomi M. Acute encephalopathy associated with influenza and other viral infections. *Acta Neurol Scand* 2007;115:45–56. <https://doi.org/10.1111/j.1600-0404.2007.00809.x>.
- [22] Kimura M, Tasaka M, Sejima H, Takusa Y, Ichijama T, Yamaguchi S. Hemicnvulsion-hemiplegia syndrome and elevated interleukin-6: case report. *J Child Neurol* 2002;17:705–7. <https://doi.org/10.1177/088307380201700912>.
- [23] Cantarín-Extremera V, Jiménez-Legido M, Duat-Rodríguez A, García-Fernández M, Ortiz-Cabrera NV, Ruiz-Falcó-Rojas ML, et al. Tocilizumab in pediatric refractory status epilepticus and acute epilepsy: Experience in two patients. *J Neuroimmunol* 2020;340. <https://doi.org/10.1016/j.jneuroim.2019.577142>.
- [24] Stredny CM, Case S, Sansevere AJ, Son M, Henderson L, Gorman MP. Interleukin-6 blockade with tocilizumab in anakinra-refractory febrile infection-related epilepsy syndrome (FIRES). *Child Neurol Open* 2020;7:2329048X2097925. [10.1177/2329048X20979253](https://doi.org/10.1177/2329048X20979253).
- [25] Zhao JP, Yoshii A. Hyperexcitability of the local cortical circuit in mouse models of tuberous sclerosis complex. *Mol Brain* 2019;12:6. <https://doi.org/10.1186/s13041-019-0427-6>.