

Fluoro-deoxy glucose positron emission tomography-computed tomography in a case of natural killer/T-cell lymphoma with bilateral adrenal involvement

Chidambaram Natrajan Balasubramanian Harisankar

Department of Nuclear Medicine, PET and Therapy, Amala Institute of Medical Sciences, Thrissur, Kerala, India

ABSTRACT Natural killer/T-cell (NK/T-cell) lymphoma is a rare condition, which presents as necrotic, granulomatous lesions involving the nose and the upper respiratory tract. The condition usually has an aggressive clinical course. The predominant subtype of NK/T-cell lymphoma noted in Asian population is the nasal type. We describe a case of biopsy-proven NK/T-cell lymphoma with bilateral adrenal involvement. Adrenal involvement by lymphoma is usually of B-cell type and occurs in disseminated disease and often unilateral. Bilateral adrenal involvement by T-cell lymphoma is extremely rare.

Keywords: Adrenal lymphoma, fluoro-deoxy glucose positron emission tomography-computed tomography, midline granuloma, natural killer/T-cell lymphoma, SMILE

INTRODUCTION

Natural killer/T-cell (NK/T-cell) lymphoma is a rare fast-growing lymphoma arising from the lining of the nose or upper airway. They usually present with epistaxis and swelling. We report an interesting case who also had bilateral adrenal involvement.

CASE REPORT

A 26-year-old young female presented with nasal obstruction, bloody discharge and swelling of the nasal skin and right lower eyelid. Biopsy from the soft tissue seen in the nasal cavity revealed NK/T-cell lymphoma (nasal type). Patient was referred to a whole body 18 fluoride (18F)-fluoro-deoxy glucose (FDG) positron emission tomography-computed tomography (PET-CT). 18F-FDG PET-CT performed showed intense FDG uptake in heterogeneously enhancing soft tissue in the right nasal cavity with

extension into the skin of the cheek and right lower eyelid [Figure 1: a - maximum-intensity projection, b - axial CT, c - fused PET-CT]. Intense FDG uptake was also noted in enhancing soft tissue bilateral adrenal masses [d - axial CT; e - fused PET-CT] indicating disease involvement. A diagnosis of bilateral adrenal involvement by NK/T-cell lymphoma was made. Patient was referred back to medical Oncology Department for chemotherapy.

DISCUSSION

Natural killer cells mediate lysis of tumor cells, bacteria or virus infected cells. They also aid in the production of immunomodulatory cytokines. Morphologically, mature NK cells are large granular lymphoid cells, they are negative for surface CD3 but characteristically express cytoplasmic CD3 epsilon (ϵ), CD56, and cytotoxic molecules. There are two main categories of NK cell-derived neoplasms, namely, aggressive NK cell leukemia and extranodal NK/T-cell lymphoma, nasal type. Epstein-Barr virus infection in the lymphoma cells is a consistent finding.^[1] NK/T-cell lymphoma of the nasal type accounts for 7–10% of all non-Hodgkin lymphomas in Asia and Latin America, but only 1% of that amongst Caucasians.^[2] The leukemic counterpart of NK/T-cell lymphoma, aggressive NK-cell leukemia is an uncommon disease. Clinically, it is useful to classify NK/T-cell malignancies into two categories, namely,

Access this article online

Quick Response Code:



Website:

www.ijnm.in

DOI:

10.4103/0972-3919.158537

Address for correspondence:

Dr. Chidambaram Natrajan Balasubramanian Harisankar, Department of Nuclear Medicine, PET and Therapy, Amala Institute of Medical Sciences, Amala Nagar, Thrissur - 680 555, Kerala, India. E-mail: hari.cnb@gmail.com

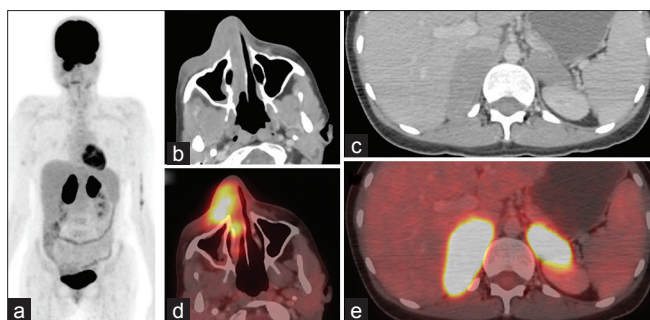


Figure 1: 18 Fluoride-fluoro-deoxy glucose positron emission tomography-computed tomography (18F-FDG PET-CT) performed showed intense FDG uptake in heterogeneously enhancing soft tissue in the right nasal cavity with extension into the skin of the cheek and right lower eye lid (a - maximum-intensity projection, b - axial CT, c - fused PET-CT). Intense FDG uptake was also noted in enhancing soft tissue bilateral adrenal masses (d - axial CT; e - fused PET-CT) indicating disease involvement

nasal NK-cell lymphomas, and nonnasal or extranasal NK/T-cell lymphomas, depending on the site of the lesions. Nasal NK/T-cell lymphomas occur in the nose and the upper aerodigestive tract. Nasal obstruction, facial swelling, and epistaxis are the common presentations. Bone marrow involvement occurs in <10% of patients, and distant metastasis is unusual.^[3]

Extranasal or nonnasal NK/T-cell lymphomas occur outside the typical nasal region, and the common primary sites involved include the skin, gastrointestinal tract, salivary glands, spleen, and testis. Unusual sites of involvement such as the muscle, the adrenal gland, and the female genital tract (ovaries and uterus) have been reported.^[4] Occult nasal involvement should be ruled out with panendoscopy and multiple random biopsies in patients presenting with extranasal NK/T-cell lymphoma. Disseminated nodal NHL can involve the adrenals in up to 25% of the cases.^[5,6] However, primary adrenal lymphoma is extremely rare with majority of the cases being B cell type.

Natural killer-cell lymphomas are FDG-avid and PET-CT offers more accurate definition of the extent of involvement by distinguishing lymphoma involvement from inflammatory masses. 18-FDG PET-CT is increasingly used both at diagnosis and for monitoring of response to therapy.^[7-9] PET changes the staging in up to 21% of the patients and alters the planned management strategy in 44% of the patients.^[7] PET parameters such as total lesion glycolysis, in addition to the international prognostic index, is useful in predicting prognosis of these patients.^[9]

For the stage, I/II nasal NK/T-cell lymphomas, radiotherapy is an important modality of treatment. Recent evidence

indicates radiation therapy alone is insufficient, and chemotherapy is also needed in these patients. Nonnasal NK cell lymphomas tend to have advanced or disseminated disease at presentation, and the role of radiotherapy is often limited. For the stage III/IV nasal NK/T-cell lymphomas, extranasal NK/T-cell lymphomas and aggressive NK-cell lymphoma/leukemia, chemotherapy is the primary treatment. L-asparaginase-containing regimens have shown promise as the tumor cells lack L-asparagine synthetase and are susceptible to L-asparaginase, which depletes L-asparagines in NK lymphoma cells.^[10]

REFERENCES

1. Ho FC, Srivastava G, Loke SI, Fu KH, Leung BP, Liang R, *et al*. Presence of Epstein-Barr virus DNA in nasal lymphomas of B and T cell type. *Hematol Oncol* 1990;8:271-81.
2. Au WY, Ma SY, Chim CS, Choy C, Loong F, Lie AK, *et al*. Clinicopathologic features and treatment outcome of mature T-cell and natural killer-cell lymphomas diagnosed according to the World Health Organization classification scheme: A single center experience of 10 years. *Ann Oncol* 2005;16:206-14.
3. Gill H, Liang RH, Tse E. Extranodal natural-killer/t-cell lymphoma, nasal type. *Adv Hematol* 2010;2010:627401.
4. Hasserjian RP, Harris NL. NK-cell lymphomas and leukemias: A spectrum of tumors with variable manifestations and immunophenotype. *Am J Clin Pathol* 2007;127:860-8.
5. Santhosh S, Mittal BR, Shankar P, Kashyap R, Bhattacharya A, Singh B, *et al*. (18) F-FDG PET/CT in bilateral primary adrenal T-cell lymphoma. *Hell J Nucl Med* 2011;14:166-7.
6. Kumar R, Xiu Y, Mavi A, El-Haddad G, Zhuang H, Alavi A. FDG-PET imaging in primary bilateral adrenal lymphoma: A case report and review of the literature. *Clin Nucl Med* 2005;30:222-30.
7. Moon SH, Cho SK, Kim WS, Kim SJ, Chan Ahn Y, Choe YS, *et al*. The role of 18F-FDG PET/CT for initial staging of nasal type natural killer/T-cell lymphoma: A comparison with conventional staging methods. *J Nucl Med* 2013;54:1039-44.
8. Khong PL, Huang B, Phin Lee EY, Sum Chan WK, Kwong YL. Midtreatment 18F-FDG PET/CT Scan for early response assessment of SMILE therapy in natural Killer/T-Cell lymphoma: A prospective study from a single center. *J Nucl Med* 2014;55:911-916.
9. Kim CY, Hong CM, Kim DH, Son SH, Jeong SY, Lee SW, *et al*. Prognostic value of whole-body metabolic tumour volume and total lesion glycolysis measured on 18F-FDG PET/CT in patients with extranasal NK/T-cell lymphoma. *Eur J Nucl Med Mol Imaging* 2013;40:1321-9.
10. Yang L, Liu H, Xu XH, Wang XF, Huang HM, Shi WY, *et al*. Retrospective study of modified SMILE chemotherapy for advanced-stage, relapsed, or refractory extranasal natural killer (NK)/T cell lymphoma, nasal type. *Med Oncol* 2013;30:720.

How to cite this article: Harisankar CB. Fluoro-deoxy glucose positron emission tomography-computed tomography in a case of natural killer/T-cell lymphoma with bilateral adrenal involvement. *Indian J Nucl Med* 2015;30:254-5.

Source of Support: Nil. **Conflict of Interest:** None declared.