

Treatment of early onset spinal deformities with magnetically controlled growing rods: a single centre experience of 30 cases

D. Studer¹
C. Heidt¹
P. Büchler²
C. C. Hasler¹

Abstract

Purpose The treatment of early onset scoliosis continues to be a major challenge, even when using motorized growth-sparing implants. We report on 30 cases operated on with magnetically controlled growing rods (MCGRs) at our institution, analyzing radiological parameters and complications, comparing our results with the literature and presenting a special implant fixation technique. A separate focus highlights the challenges of conversion from previous non-motorized implants.

Methods Consecutive case series. The nature and effects of complications were recorded for all patients. Radiographic evaluations were performed for patients with a minimum follow-up of two years. Separate analyses were carried out for patients who were previously treated with non-motorized growth-sparing implants.

Results There were 12 documented complications in 11/30 (37%) patients leading to 13 unplanned returns to the operating room. In all, 18/30 patients had a minimum follow-up of two years. Major curve and main kyphosis, as well as T1 to T12 and T1 to S1 distances significantly improved with MCGR implantation, however, less in patients converted from previous growth-sparing surgical treatment. While the achieved correction of the major curve was maintained, there was a loss of kyphosis correction with subsequent implant lengthening. Gain in implant length decreased with increasing number of extensions.

Conclusion Despite improved patient's comfort, MCGR show a considerable complication rate. Coronal plane deformities can be well controlled, but diminished implant lengthening is

already apparent within two years after MCGR implantation. Central databases should help to clarify unresolved aspects and optimize the treatment of these young patients.

Level of Evidence IV

Cite this article: Studer D, Heidt C, Büchler P, Hasler CC. Treatment of early onset spinal deformities with magnetically controlled growing rods: a single centre experience of 30 cases. *J Child Orthop* 2019;13:196-205. DOI: 10.1302/1863-2548.13.180203

Keywords: early onset scoliosis; growth-sparing surgery; complications

Introduction

According to a consensus statement of the Scoliosis Research Society,¹ any spinal deformity occurring before the age of ten years is referred to as early onset scoliosis (EOS), regardless of the aetiology. Despite ongoing technical development and increasing knowledge about deformity evolution, the treatment of EOS remains challenging. Based on the understanding of the dependence of spinal and thoracic growth and lung development with devastating consequences in case of early operative spinal fusion, various growth-friendly techniques have been developed.² The expanding variety of operative techniques led to a neglect of conservative treatment options, but the surgical enthusiasm subsided with numerous reports of considerable surgery-related complications leading to a renaissance of nonoperative treatment methods. Serial Mehta or Risser casting represent conservative techniques to sometimes treat patients with EOS or at least delay surgery.³⁻⁵

In cases of progressive EOS with coronal plane deformities exceeding 50° to 60°, operative strategies may nevertheless become necessary.^{6,7} Distraction-based systems have been favoured to control the deformity and stimulate growth of the spine and thorax, aiming for as normal pulmonary function as possible. In the case of absence of rib anomalies and thoracic insufficiency syndrome there is consensus to use (dual) growing rods.⁸ The development of motorized implants lowered the heavy psycho-social burden of repetitive surgical implant lengthening under general anaesthesia, and the complication rate appears to be less. First reports on early follow-up with magnetically

¹ Orthopaedic Department, Children's Hospital, University of Basel, Basel, Switzerland

² Institute for Surgical Technologies and Biomechanics, University of Bern, Bern, Switzerland

Correspondence should be sent to Daniel Studer, MD, Children's Hospital, University of Basel, Spitalstrasse 33, CH-4056 Basel. E-mail: daniel.studer@ukbb.ch

controlled growing rods (MCGR) are promising but, as with any medical achievement, this new technique must stand the test of time.⁹⁻¹¹ Recent reports have pointed to problems that can only be objectively determined through continuous evaluation and documentation and the establishment of central registries.¹²⁻¹⁴

We would like to report on the radiographic parameters and complications experienced in our first 30 patients who underwent MCGR implantation and compare our findings with the existing literature. We also describe a fixation technique that enables the use of MCGR even in very young children with a small bony anatomy. In addition, we address challenges and problems in patients who underwent conversion to MCGR from previous non-motorized growth-sparing surgical treatment.

Patients and methods

After getting written informed consent from the patients and their families/care givers, and with the approval of the institutional review board, the medical records of patients having had implantation of MCGRs (MAGEC System; NuVasive, San Diego, California) were screened for demographics, aetiology of the EOS according to the C-EOS-classification system,¹⁵ previous treatment, as well as complications and unplanned returns to the operating room (OR). Complications were considered for all 30 patients, regardless of follow-up time. The severity of the complications was classified as proposed by Smith et al.¹⁶ Existing imaging was analyzed for changes in major curve (Cobb's angle) and main kyphosis before and after MCGR insertion, as well as at latest follow-up for patients with a minimum follow-up of two years after MCGR implantation ($n = 18$). Furthermore, changes in T1 to T12 and T1 to S1 distances were documented. T1 to T12 and T1 to S1 distances were defined as the length of a straight line on an anteroposterior (AP) whole spine radiograph connecting the midpoint of the upper endplate of T1 to the midpoint of the lower endplate of T12, or the midpoint of the upper endplate of S1, respectively. In addition, kind and levels of fixation were documented. Separate analyses were carried out for patients who were previously treated with non-motorized growth-sparing implants.

According to our treatment protocol, outpatient MCGR extensions take place every three months. At each consultation the amount of implant lengthening is objectified and documented by ultrasound, and every six months an AP and lateral whole spine radiograph prior to implant extension is performed to check the correct implant position and to document the evolution of the deformity. Until April 2017, the radiograph controls were carried out with a digital radiograph machine (Intuition; Leuag AG, Alpnach Dorf, Obwalden, Switzerland) and from May 2017 this

was done with the EOS imaging system (EOS Imaging; EOS Imaging SA, Paris, France). The change of the radiograph unit had to be taken into account when evaluating the changes in the T1 to T12 and T1 to S1 distances, since the ray divergence of the digital radiograph (Intuition) system initially used results in a magnification of the image, which is not the case with the EOS Imaging system that relies on a linear ray pattern.

Statistical analysis

The major curve, main kyphosis and the T1 to S1 length were evaluated at each time point of the procedure; preoperatively, immediately postoperatively and after several implant elongations at three months (one elongation), nine months (three elongations), 18 months (five elongations), 21 months (seven elongations) and at 27 months (nine elongations). Paired *t*-tests were performed to compare the change in angle or length between subsequent timepoints. Paired *t*-tests were also used to compare the preoperative situation with the situation after nine elongations. Comparisons were performed for all the patients as well as for two subgroups; patients who underwent conversion from non-motorized growth-sparing implants and patients who received MCGR as primary surgical treatment.

Results

Between April 2015 and March 2018, 30 patients (20 female, ten male) underwent MCGR implantation at our institution. All patients and/or their families/care givers agreed to be enrolled in the study. Demographic data, aetiology of the EOS, previous treatment and kind and level of fixation are summarized in Table 1. Mean age at the time of MCGR implantation was 9.4 (SD 3.5; 1.8 to 18.4). In all, 12 patients were older than ten years at the time of MCGR insertion. In ten of these 12 patients the Risser stage¹⁷ was still 0. The oldest patient was 18.4 years at index surgery with a congenital EOS due to a vertebral defect, anal atresia, cardiac defects, tracheo-esophageal fistula, renal anomalies and limb abnormalities (VACTERL) syndrome. Despite being Risser stage 4, his bone age determined with the BoneXpert software (BoneXpert, Visiana, Horsholm, Denmark) was four years retarded and his body height was only 147 cm. In addition, a tethered cord was present on MRI, requiring neurosurgical intervention. Respecting these factors and according to the patient's wish, the decision to delay final fusion surgery and to use MCGR was made. Another female patient with idiopathic EOS, Risser stage 2 and a body height of 150 cm had MCGR insertion at 14.9 years of age.

In all, 25/30 (83%) suffered from non-idiopathic EOS (11 congenital, ten neuromuscular, four syndromic) and

Table 1 Overview of demographic, health-related and technical data of patients undergoing treatment with magnetically controlled growing rods (MCGRs)

ID	Gender	C-EOS	Previous treatment	Age (yrs) at MCGR implantation	Risser at MCGR implantation	Mono/bilateral MCGR	MAGEC system	Proximal foundation	Distal foundation	Additional surgical procedures
MCGR01	Female	Neuromuscular	Brace	7.4	0	Bilateral	4.5 mm, 90 mm	Hooks T4 to T6	Screws L4 to L5	
MCGR02	Male	Syndromic	Cast	4.1	0	Bilateral	4.5 mm, 70 mm	Hooks T1 to T3	Screws L3 to L4	
MCGR03	Female	Neuromuscular	VEPTR	6.6	0	Monolateral	5.5 mm, 70 mm	VEPTR rib cradle	Screws T12 to L1	
MCGR04	Female	Syndromic	VEPTR	12.7	0	Bilateral	5.5 mm, 90 mm	VEPTR rib cradles	VEPTR Ala hooks	
MCGR05	Male	Congenital	VEPTR	9.8	0	Monolateral	5.5 mm, 70 mm	VEPTR rib cradle	Screws L2 to L3	
MCGR06	Female	Idiopathic	Brace	10.0	0	Bilateral	5.5 mm, 90 mm	Hooks T2 to T4	Screws L3 to L4	
MCGR07	Female	Idiopathic	Brace	12.6	0	Bilateral	5.5 mm, 90 mm	Hooks T2 to T4	Screws L1 to L2	
MCGR08	Male	Congenital	VEPTR	9.8	0	Bilateral	6.0 mm, 90 mm	VEPTR rib cradles	VEPTR Ala hooks	
MCGR09	Female	Neuromuscular	Brace	7.5	0	Monolateral	4.5 mm, 70 mm	Hooks T3 to T5	Screws L3 to L5	
MCGR10	Female	Neuromuscular	Brace	10.6	0	Bilateral	5.5 mm, 90 mm	Hooks T2 to T4	Screws L3 to L5	
MCGR11	Male	Congenital	None	7.3	0	Bilateral	4.5 mm, 70 mm	Screws T2 to T3	Screws T12 to L1	
MCGR12	Male	Congenital	VEPTR	10.5	0	Monolateral	6.0 mm, 70 mm	VEPTR rib cradle	Screws T12 to L1	
MCGR13	Female	Congenital	VEPTR	8.6	0	Monolateral	6.0 mm, 70 mm	VEPTR rib cradle	Screws T12 to L1	Apical convex pedicle screw epiphyseodesis
MCGR14	Female	Neuromuscular	None	10.9	0	Bilateral	5.5 mm, 90 mm	Hooks T3 to T5	Screws L2 to L3	
MCGR15	Male	Congenital	VEPTR	9.7	0	Monolateral	4.5 mm, 70 mm	Hooks T3 to T5	Screws T12 to L1	Apical convex pedicle screw epiphyseodesis and convex side trolley construct
MCGR16	Female	Congenital	VEPTR	7.6	0	Monolateral	4.5 mm, 90 mm	Hooks T2 to T3	Screws L1 to L2	Apical convex pedicle screw epiphyseodesis
MCGR17	Female	Neuromuscular	Brace	5.3	0	Bilateral	4.5 mm, 90 mm	Hooks T1 to T5	Screws L4 to ilium	
MCGR18	Female	Congenital	None	9.1	0	Bilateral	5.5 mm, 90 mm	Hooks T2 to T4	Screws L2 to L3	
MCGR19	Female	Idiopathic	Brace	12.0	0	Bilateral	5.5 mm, 90 mm	Hooks T3 to T5	Screws L2 to L3	
MCGR20	Female	Syndromic	Cast	1.8	0	Bilateral	4.5 mm, 70 mm	Hooks T3 to T5	Screws L2 to L3	
MCGR21	Female	Congenital	Brace	11.9	0	Bilateral	5.5 mm, 90 mm	Hooks T3 to T5	Screws L1 to L2	
MCGR22	Female	Idiopathic	Brace	14.9	II	Bilateral	5.5 mm, 90 mm	Hooks T2 to T4	Screws T12 to L1	Apical convex pedicle screw epiphyseodesis
MCGR23	Male	Congenital	Brace	18.4	IV	Bilateral	5.5 mm, 90 mm	Hooks T3 to T4	Screws L3 to L4	
MCGR24	Male	Congenital	None	14.2	0	Bilateral	5.5 mm, 90 mm	Hooks T1 to T3	Screws T12 to L1	
MCGR25	Male	Neuromuscular	None	12.0	0	Bilateral	4.5 mm, 70 mm	Hooks T1 to T2	Screws T10 to T12	
MCGR26	Male	Neuromuscular	tGR	9.2	0	Bilateral	4.5 mm, 90 mm	Hooks T2 to T3	Screws T11 to T12	
MCGR27	Female	Neuromuscular	None	10.3	0	Bilateral	4.5 mm, 90 mm	Hooks T2 to T5	Screws L4 to ilium	
MCGR28	Female	Neuromuscular	None	3.5	0	Bilateral	5.5 mm, 70 mm	Hooks T1 to T4	Screws T12 to L1	
MCGR29	Female	Idiopathic	Brace	6.5	0	Bilateral	5.5 mm, 90 mm	Hooks T3 to T5	Screws L1 to L2	
MCGR30	Female	Syndromic	None	6.8	0	Bilateral	5.5 mm, 90 mm	Hooks T2 to T3	Screws T12 to L1	

C-EOS, classification of early onset scoliosis; VEPTR, vertical expandable titanium rib prosthesis

only five patients were treated for idiopathic EOS. In 13 patients either serial casting or brace treatment was applied prior to MCGR insertion. Nine patients had previous treatment with non-motorized distraction-based implants. Eight of them underwent conversion from vertical expandable titanium rib prosthesis (VEPTR) and one patient had his traditional growing rods (tGR) exchanged for MCGR. Eight patients did not have specific treatment before getting MCGR.

Mean follow-up time of all patients was 25 months (SD 10; 6 to 42). In all, 18 patients had a minimum follow-up of two years after MCGR insertion. Eight of these 18 patients had conversion from non-motorized implants (all VEPTR). Two of these 18 patients had graduated from growth-sparing treatment and underwent final fusion surgery. One of them with conversion from VEPTR to MCGR had a staged procedure with removal of MCGR and 21 days of inpatient halo-gravity traction followed by posterior instrumented spinal fusion (PISF). The other patient underwent one-time MCGR removal and PISF.

Deformity evolution was analyzed for patients with a minimum follow-up of two years (18/30) after MCGR insertion (Fig. 1). Mean major curve Cobb angle before

MCGR insertion was 66° (SD 19°; 35° to 106°), changing to 47° (SD 13°; 29° to 79°) after MCGR implantation (29% correction rate; $p < 0.001$). Mean main kyphosis angle changed from 52° (SD 31°; 9° to 146°) before to 42° (SD 25°; 8° to 119°) after MCGR implantation (19% correction rate; $p = 0.023$). Mean major curve before MCGR and curve correction with MCGR insertion was less in patients with previous growth-sparing surgical treatment (58°; 14%) compared with patients without previous spine surgery (72°; 38%). On the other hand, mean main kyphosis before MCGR was higher in patients who underwent conversion from non-motorized implants (63° versus 43°). After a minimum follow-up period of two years both, patients with and without previous growth-sparing surgery, showed a steady increase in main kyphosis with subsequent lengthenings. Patients after conversion from non-motorized spinal implants even showed a loss of major curve correction, reaching the levels before MCGR insertion.

There was a relevant increase in both T1 to T12 (+ 1.8 cm; SD 1.1; $p < 0.001$) and T1 to S1 (+ 2.7 cm; SD 1.6; $p < 0.001$) distance with MCGR implantation. Like the changes in major curve Cobb angle, the increase in T1 to T12 and

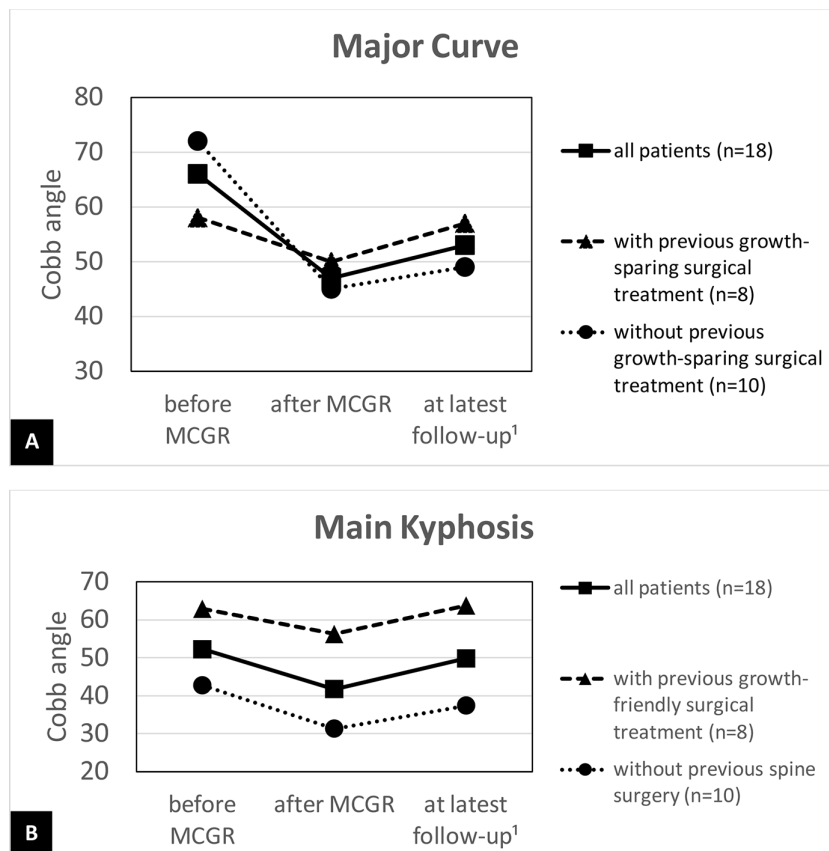


Fig. 1 Changes in major curve (a) and main kyphosis (b) before and after implantation of magnetically controlled growing rods (MCGR), and at latest follow-up ('only patients with a minimum follow-up period of two years are included) for all patients (continuous line), for patients with previous growth-sparing surgical treatment (dashed line) and for patients without previous growth-sparing surgical treatment (dotted line).

T1 to S1 length for patients converted from non-motorized implants was less (+ 0.6 cm for T1 to T12 and + 1.3 cm for T1 to S1) compared with patients without previous spine surgery (+ 2.2 cm for T1 to T12 and + 3.3 cm for T1 to S1). Due to the heterogeneity of the cohort in terms of age, aetiology and extent of the deformity, as well as the length of the instrumented part of the spine, we focused on the changes in T1 to S1 distance during treatment. Interestingly, there was a slight loss of T1 to S1 distance in the interval between MCGR implantation and the first lengthening. In the further course of the treatment there was a steady increase of the T1 to S1 distance, however, with a smaller gain in length over time (Fig. 2).

In all, 23 patients had bilateral MCGR implantation. Six of the seven patients with unilateral MCGR insertion had previous unilateral VEPTR treatment. In one female patient with neuromuscular scoliosis due to a myopathy, only one concave-sided rod could be inserted, considering the extent of curvature (Cobb angle of 83°) and the limited soft-tissue coverage at a body weight of just under 12 kg. Apart from one case, all patients without previous growth-sparing surgery had a hybrid instrumentation consisting of hooks for the proximal and pedicle screws for the distal foundation. In patients pre-operated with VEPTR, the cranial fixation was mostly performed using the *in situ* VEPTR rib hooks. Changes to pedicle hooks were performed in two cases. In the caudal region, the original VEPTR fixation was used in all pre-operated patients. When implanting the MCGR, we tried to use the longer actuator (90 mm) and a 5.5-mm rod whenever possible. Depending on the anatomical conditions and the deformity, we used a special fixation technique in some of the

cases. In order to be able to use the 5.5-mm MAGEC rods even in small children with limited bony anatomy, 4.5-mm anchor points were used, which were connected to a 5.5-mm rod via side-to-side connectors (Fig. 3). This has enabled the use of the 5.5-mm/90-mm actuator MAGEC in 76% (16/21) of the patients without previous spine surgery.

So far, a total of 249 elective outpatient implant lengthenings have been performed. Considering a six-month interval for surgical extension of non-motorized implants, the use of MCGR enabled the avoidance of 116 elective inpatient surgical extensions under general anaesthesia. There were 12 documented complications in 11/30 (37%) patients leading to a total of 13 unplanned returns to the OR (Table 2). In all, 4/9 (44%) of patients after conversion from VEPTR or tGR treatment and 7/21 (33%) of patients without previous growth-sparing surgery were affected. Two complications were rated as severity grade I,¹⁶ not requiring unplanned surgery. In one case, delayed wound healing occurred after the index surgery. In the second patient, both rods failed, leading to premature indication for definitive spondylodesis. During the definitive spondylodesis, after removal of the MCGR, a pronounced metallosis at the level of the actuator could be observed (Fig. 4). Seven complications were rated as severity grade IIA, requiring one additional surgery. In one girl with idiopathic EOS one of the MAGEC rods had to be exchanged due to rod malfunction. Four of the patients with previous VEPTR treatment sustained failure of proximal (three times) or distal (one time) implant fixation. Two other patients required extension/refixation of the proximal foundation due to proximal junctional kyphosis (PJK). One of these

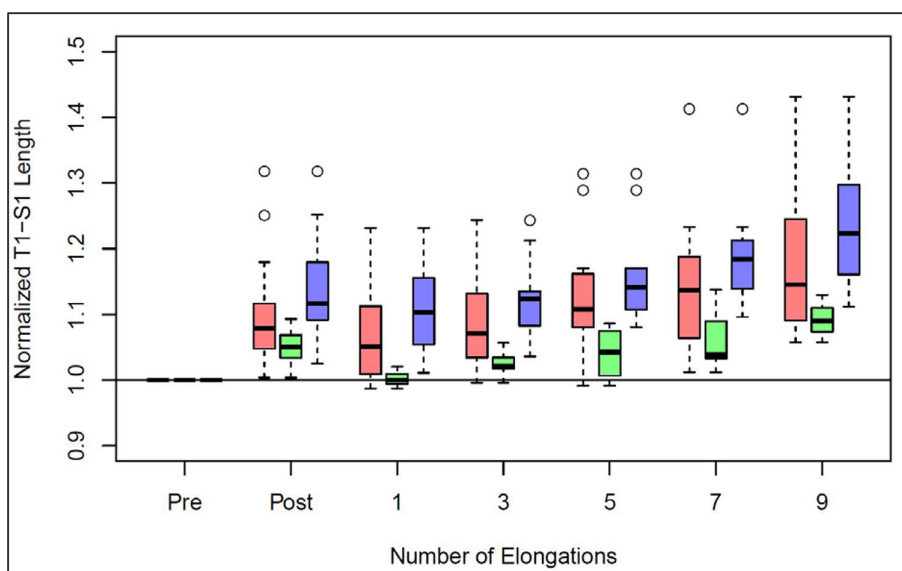


Fig. 2 Normalized changes in T1 to S1 distance during treatment with magnetically controlled growing rods in patients with a minimum follow-up period of two years (red = all patients (n = 18); green = patients with previous growth-sparing surgical treatment (n = 8); blue = patients without previous growth-sparing surgical treatment (n = 10)).

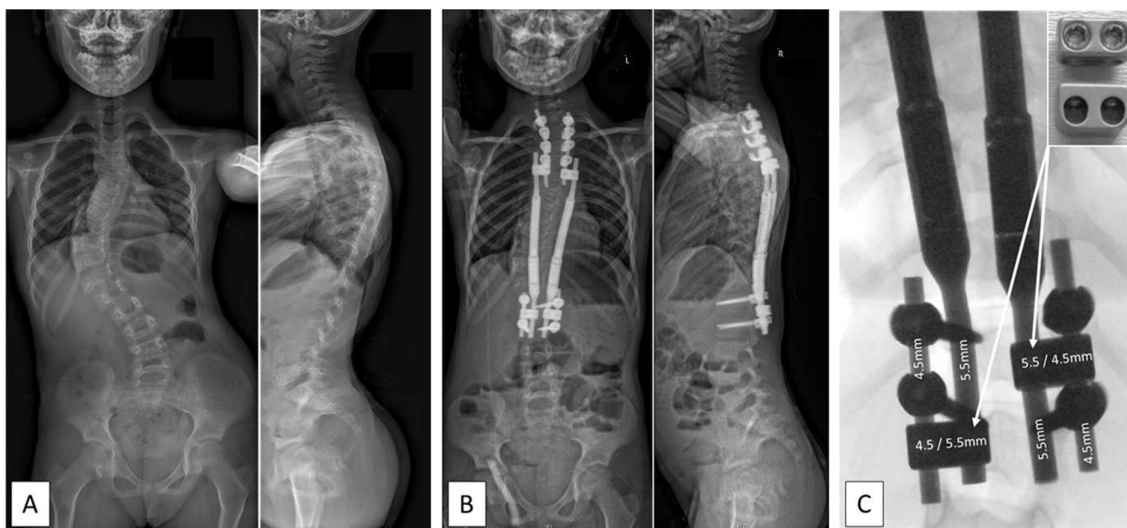


Fig. 3 Radiographs of a six-year-old girl with an idiopathic early onset scoliosis before (a) and after (b) insertion of magnetically controlled growing rods (MCGR). A 4.5-mm system was used for the proximal and distal foundations and the foundations were linked to the 5.5-mm MCGRs by 4.5-/5.5-mm side-by-side rod connectors (c) enabling the use of two 90-mm actuator MCGRs.

Table 2 Complications after implantation of magnetically controlled growing rods (MCGR)

ID	Gen-der	C-EOS	Previous treatment	Complication(s)	Mono/bilateral MCGR	Severity score*	Delay until complication(s)†	Treatment
MCGR02	Male	Syndromic	Cast	Delayed wound healing	Bilateral	I	0	None
MCGR04	Female	Syndromic	VEPTR	Dislocation of VEPTR ala hook	Bilateral	IIA	11	Refixation of ala hook
MCGR05	Male	Congenital	VEPTR	Dislocation of VEPTR rib cradle	Monolateral	IIA	7	Refixation of rib cradle
MCGR06	Female	Idiopathic	Brace	MAGEC rod failure right side	Bilateral	IIA	10	Change of MAGEC rod
MCGR07	Female	Idiopathic	Brace	MAGEC rod failure bilateral	Bilateral	I	17	Premature indication for definitive spondylodesis
MCGR08	Male	Congenital	VEPTR	Dislocation of VEPTR rib cradle	Bilateral	IIA	21	Refixation of VEPTR rib cradle
MCGR12	Male	Congenital	VEPTR	Dislocation of VEPTR rib cradle	Monolateral	IIA	1	Refixation of VEPTR rib cradle
MCGR17	Female	Neuromuscular	Brace	2 × PJK	Bilateral	IIA	1. 10 2. 17	1. Proximal extension of the instrumentation 2. Extension of the instrumentation to the occiput
MCGR21	Female	Congenital	Brace	PJK	Bilateral	IIA	10	Proximal extension of the instrumentation
MCGR28	Female	Neuromuscular	None	SSI	Bilateral	IIB	0	3 × wound revision including insertion of a liquor drainage
MCGR29	Female	Idiopathic	Brace	SSI	Bilateral	IIB	0	2 × wound revision including insertion of a liquor drainage

*complication severity score according to Smith et al(16)

†months after index surgery

C-EOS, classification of early onset scoliosis; PJK, proximal junctional kyphosis; SSI, surgical site infection; VEPTR, vertical expandable titanium rib prosthesis

patients with a neuromuscular scoliosis due to a central core myopathy had an additional operation with fixation up to the occiput. A further two complications were rated as severity grad IIB. Both patients sustained a deep surgical site infection (SSI) after the index operation. In both cases, a cerebrospinal fluid leak could be objectified during the revision operation and three, respectively two, unplanned operations were necessary.

Discussion

The availability of motorized implants for the therapeutic management of EOS and the abandonment of regular surgical device lengthening has led to a significant improvement in health-related quality of life of affected patients.¹⁸ In addition, there is a potential for cost savings due to the reduced number of inpatient stays and operations under general anaesthesia.¹⁹⁻²¹ These developments are of

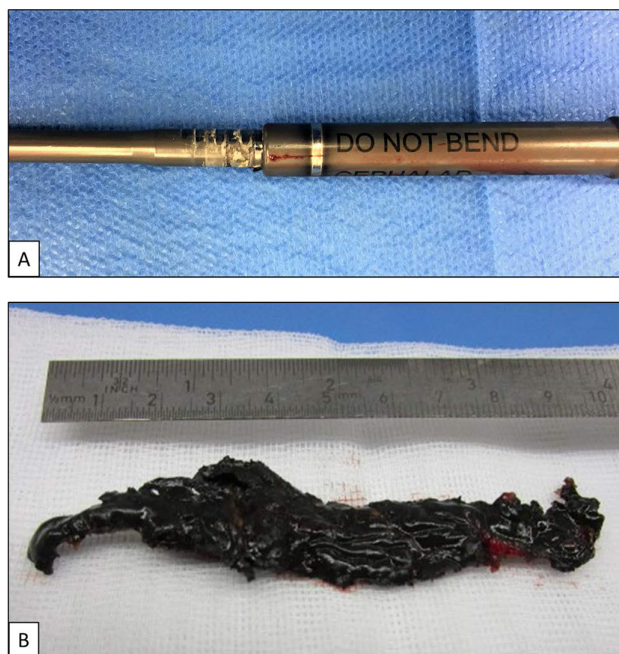


Fig. 4 (a) Shows clear material abrasion in the telescoping part of the explanted magnetically controlled growing rod (MCGR) in a female patient with idiopathic early onset scoliosis; (b) illustrates the pronounced metallosis present in the excised soft tissues surrounding the telescoping portion of the MCGR.

particular benefit for our young patients, but, nevertheless, a reflective approach to indicate the use of MCGR is still required.

Although more than 100 elective implant lengthening surgeries could be avoided in our cohort by using MCGR, the complication rate (37%) and the rate of unplanned returns to the OR (30%) are not insignificant. This has also been confirmed by other authors. Thakar et al¹² just recently presented a systematic review on the complication profile of MCGR in EOS. They included 15 publications including 336 patients with an average follow-up of 30 months. Although studies reporting on the use of MCGR as part of a hybrid growing system were excluded, the reported mean complication rate (45%) and the rate of unplanned revision surgery (33%) were very similar to our results. And, as with our patients, most of the complications were implant-related. Like them, we could not show a significant difference between primary and conversion procedures, although, in our series the complication rate in patients converted from non-motorized implants was 44% compared with 33% in patients without previous surgical treatment. The overall rate of deep SSIs appears to be less when using MCGR compared with non-motorized distraction-based systems. In a large series of 379 tGR patients, Kabirian et al²² found a rate of 11.1% of SSI requiring unplanned surgery and a study on our own VEPTR patients showed a 21.7% (5/23) rate of SSI²³. Thakar et al¹² in their review on patients treated with MCGR reported only 3.3% deep SSI with two SSIs in 30 patients; our SSI

rate is 6.7%. This is likely due to the reduced number of elective surgeries for implant lengthening. At least, we have shown that bacterial implant colonization is detectable in 48% of VEPTR patients undergoing repetitive surgical lengthening.²⁴

Our PJK rate of 6.7% (2/30) is higher compared with those reported by Thakar et al¹² (3.8%) and Bess et al²⁵ (2.1%). Another study, however, reported on significantly higher rates of PJK of up to 28%.²⁶ The known risk factors to develop PJK, namely preoperative thoracic hyperkyphosis and increased pelvic incidence,²⁶ were met in our two patients with PJK.

The marked deformity correction with the index surgery, especially in patients without conversion procedures, has already been described for tGR and other non-motorized implants. And, it would be surprising if different results were obtained with the use of MCGR, given the same spectrum of indications and using an equal operation technique. The extent to which this also applies to the law of diminishing returns described by Sankar et al²⁷ has not yet been conclusively clarified. Whether or not shorter intervals between scheduled implant lengthening proceeded with the use of MCGR lead to greater gain in spinal length and help to avoid spontaneous autofusion of the affected segments of the spine is debated. The fact that with an increasing number of extensions, the ultrasound-controlled gain in rod length decreases in our patients (Fig. 5) is in line with the statement of Ahmad et al²⁸ who reported on a rather gradual linear decline in

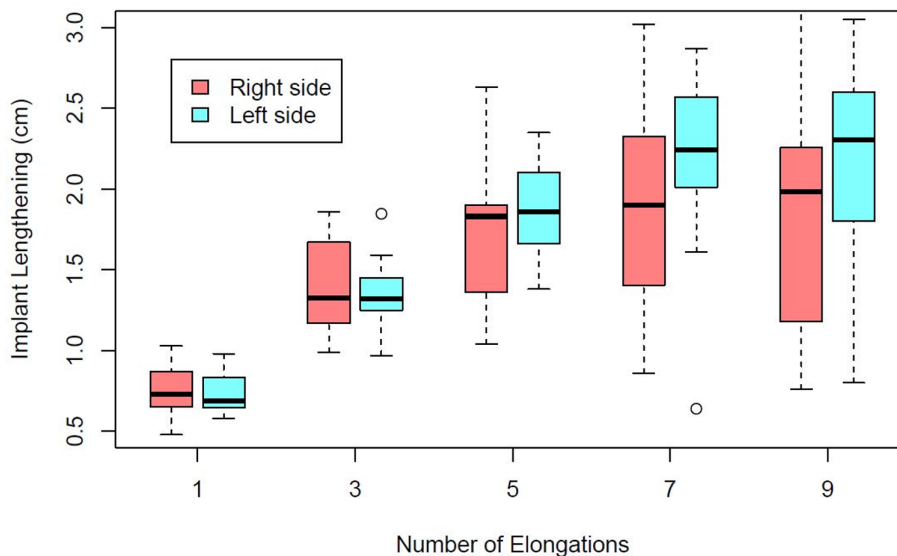


Fig. 5 Progression of implant length measured with ultrasound dependent on the number of elongations.

lengthening when using MCGR compared with a rapid initial decline in tGR treatment, and Prof. Kenneth Cheung recently called it “the law of diminished gain in length” at the 2018 International Congress on Early Onset Scoliosis (ICEOS) meeting in Lisbon.

Also uncertain are the effects of the sometimes pronounced peri-implant metallosis and the associated release of metal ions into the surrounding soft tissues and into the bloodstream.¹³ We have also found an obvious metallosis at the time of elective or unplanned rod exchanges most of the time, especially in the area of the telescoping part of the rod. However, the most pronounced finding was in a patient with an idiopathic EOS who underwent premature definitive instrumented fusion due to bilateral rod failure (Fig. 4). The extent to which rod failure and the presence of metallosis are related is not yet known. Several publications by different authors have drawn attention to this problem and, in addition to the recommendation to meticulously monitor individual patients, the demand has been made for an international register of patients with MCGR.^{13,29-31}

So far, two of our MAGEC patients had a definitive instrumented fusion. One of them was previously treated with bilateral VEPTR, including a fixation to the pelvis. With final fusion surgery the rigidity of the autofused spine and thorax did not allow relevant deformity correction, even with preoperative halo-gravity traction. In the second patient with an idiopathic EOS, the fusion was performed early due to bilateral rod failure. With Risser stage III and an age of 14.8 years, we, as well as the patient and her parents, did not wish to continue with growth-sparing treatment. With final spondylodesis, the Cobb angle of the major curve was corrected from 46° to 35° without extending the instrumented levels.

Recently, several studies have been published on so-called graduates from growth-sparing surgical techniques,³²⁻³⁵ and Cheung et al¹⁰ gave a glimpse of five MCGR graduates in their mean six-year follow-up report on MCGR patients. Not surprisingly, the prerequisites and decision-making processes for the choice of definitive treatment at skeletal maturity seem to correspond to those of non-motorized distraction-based systems. Foundations are fused, and the part of the spine bridged by the implants is not necessarily fused, but functionally stiff.

Conclusion

The use of motorized implants has clearly improved the quality of life of EOS patients. Nevertheless, we must be aware of a considerable complication and re-operation rate and that we are still a long way from reaching our goal of non-fusion surgical management of EOS. The spectrum of indications and the surgical technique still largely correspond to those of non-motorized distraction-based systems. Accordingly, we will be confronted with the same difficulties and challenges in the decision-making process when shaping the final treatment strategy at the end of growth. Uniform protocols regarding extension intervals and extent of the desired lengthening are missing as well as aetiology-dependent treatment algorithms. In addition, there are implant-associated factors, like metallosis and reduced gain in length over time, the consequences of which we do not yet have a clear understanding of. Propagated patient and treatment registries should be implemented, as should the proposal for a prospective randomized controlled trial,³⁶ to clarify these open questions and provide optimal protection for our patients.

Received 18 December 2018; accepted after revision 31 January 2019.

COMPLIANCE WITH ETHICAL STANDARDS

FUNDING STATEMENT

No benefits in any form have been received or will be received from a commercial party related directly or indirectly to the subject of this article.

OA LICENCE TEXT

This article is distributed under the terms of the Creative Commons Attribution-Non Commercial 4.0 International (CC BY-NC 4.0) licence (<https://creativecommons.org/licenses/by-nc/4.0/>) which permits non-commercial use, reproduction and distribution of the work without further permission provided the original work is attributed.

ETHICAL STATEMENT

Ethical approval: All procedures performed in studies involving human participants were in accordance with the ethical standards of the institutional and/or national research committee and with the 1964 Helsinki declaration and its later amendments or comparable ethical standards. The study was approved by the local ethics committee (EKNZ Ref-Nr. 2018-00941).

Informed consent: Informed consent was obtained from all individual participants included in the study.

ICMJE CONFLICT OF INTEREST STATEMENT

All authors declare that they have no conflict of interest.

AUTHOR CONTRIBUTIONS

DS: study design, performed measurements, manuscript preparation.

PB: study design, statistical analysis, manuscript preparation.

CH: study design, manuscript preparation.

CCH: study design, manuscript preparation.

All authors contributed to the conception of the work and interpretation of the data and were involved in drafting and revising the manuscript, before giving final approval to the version to be published.

REFERENCES

1. **El-Hawary R, Akbarnia BA.** Early onset scoliosis - time for consensus. *Spine Deform* 2015;3:105-106.
2. **Skaggs DL, Akbarnia BA, Flynn JM, et al.** A classification of growth friendly spine implants. *J Pediatr Orthop* 2014;34:260-274.
3. **Mehta MH.** Growth as a corrective force in the early treatment of progressive infantile scoliosis. *J Bone Joint Surg [Br]* 2005;87-B:1237-1247.
4. **Waldron SR, Poe-Kochert C, Son-Hing JP, Thompson GH.** Early onset scoliosis: the value of serial risser casts. *J Pediatr Orthop* 2013;33:775-780.
5. **Demirkiran HG, Bekmez S, Celilov R, et al.** Serial derotational casting in congenital scoliosis as a time-buying strategy. *J Pediatr Orthop* 2015;35:43-49.
6. **Hasler CC.** Early-onset scoliosis: contemporary decision-making and treatment options. *J Pediatr Orthop* 2018;38:S13-S20.
7. **Yang JS, McElroy MJ, Akbarnia BA, et al.** Growing rods for spinal deformity: characterizing consensus and variation in current use. *J Pediatr Orthop* 2010;30:264-270.
8. **Xu GJ, Fu X, Tian P, Ma JX, Ma XL.** Comparison of single and dual growing rods in the treatment of early onset scoliosis: a meta-analysis. *J Orthop Surg Res* 2016;11:80.
9. **Ridderbusch K, Rupprecht M, Kunkel P, Hagemann C, Stücker R.** Preliminary results of magnetically controlled growing rods for early onset scoliosis. *J Pediatr Orthop* 2017;37:e575-e580.
10. **Cheung JPY, Yiu K, Kwan K, Cheung KMC.** Mean 6-year follow-up of magnetically controlled growing rod patients with early onset scoliosis: a glimpse of what happens to graduates. *Neurosurgery* 09 August 2018. (Epub ahead of print)
11. **Lebon J, Batailler C, Wargny M, et al.** Magnetically controlled growing rod in early onset scoliosis: a 30-case multicenter study. *Eur J Spine* 2017;26:1567-1576.
12. **Thakar C, Kieser DC, Mardare M, et al.** Systematic review of the complications associated with magnetically controlled growing rods for the treatment of early onset scoliosis. *Eur J Spine* 2018;27:2062-2071.
13. **Yilgor C, Efendiye A, Akbiyik F, et al.** Metal ion release during growth-friendly instrumentation for early-onset scoliosis: a preliminary study. *Spine Deform* 2018;6:48-53.
14. **Rushton PRP, Smith SL, Forbes L, et al.** Force testing of explanted magnetically controlled growing rods. *Spine (Phila Pa 1976)* 23 July 2018. (Epub ahead of print)
15. **Williams BA, Matsumoto H, McCalla DJ, et al.** Development and initial validation of the Classification of Early-Onset Scoliosis (C-EOS). *J Bone Joint Surg [Am]* 2014;96:1359-1367.
16. **Smith JT, Johnston C, Skaggs D, Flynn J, Vitale M.** A new classification system to report complications in growing spine surgery: a multicenter consensus study. *J Pediatr Orthop* 2015;35:798-803.
17. **Risser JC.** The iliac apophysis: an invaluable sign in the management of scoliosis. *Clin Orthop Relat Res* 1958;11:111-119.
18. **Doany ME, Olgun ZD, Kinikli GI, et al.** Health-related quality of life in early-onset scoliosis patients treated surgically: EOSQ Scores in traditional growing rod versus magnetically controlled growing rods. *Spine* 2018;43:148-153.
19. **Wong CKH, Cheung JPY, Cheung PWH, Lam CLK, Cheung KMC.** Traditional growing rod versus magnetically controlled growing rod for treatment of early onset scoliosis: cost analysis from implantation till skeletal maturity. *J Orthop Surg (Hong Kong)* 2017;25:2309499017705022.
20. **Charroin C, Abelin-Genevois K, Cunin V, et al.** Direct costs associated with the management of progressive early onset scoliosis: estimations based on gold standard technique or with magnetically controlled growing rods. *Orthop Traumatol Surg Res* 2014;100:469-474.
21. **Eltorai AEM, Fuentes C.** Magnetic growth modulation in orthopaedic and spine surgery. *J Orthop* 2018;15:59-66.
22. **Kabirian N, Akbarnia BA, Pawelek JB, et al.** Deep surgical site infection following 2344 growing-rod procedures for early-onset scoliosis: risk factors and clinical consequences. *J Bone Joint Surg [Am]* 2014;96:e128.
23. **Hasler CC, Mehrkens A, Hefti F.** Efficacy and safety of VEPTR instrumentation for progressive spine deformities in young children without rib fusions. *Eur J Spine* 2010;19:400-408.
24. **Plaass C, Hasler CC, Heining U, Studer D.** Bacterial colonization of VEPTR implants under repeated expansions in children with severe early onset spinal deformities. *Eur J Spine* 2016;25:549-556.
25. **Bess S, Akbarnia BA, Thompson GH, et al.** Complications of growing-rod treatment for early-onset scoliosis: analysis of one hundred and forty patients. *J Bone Joint Surg [Am]* 2010;92:2533-2543.

26. **El-Hawary R, Sturm P, Cahill P, et al.** What is the risk of developing proximal junctional kyphosis during growth friendly treatments for early-onset scoliosis? *J Pediatr Orthop* 2017;37:86-91.
27. **Sankar WN, Skaggs DL, Yazici M, et al.** Lengthening of dual growing rods and the law of diminishing returns. *Spine* 2011;36:806-809.
28. **Ahmad A, Subramanian T, Panteliadis P, et al.** Quantifying the 'law of diminishing returns' in magnetically controlled growing rods. *Bone Joint J* 2017;99-B:1658-1664.
29. **Rushton PRP, Siddique I, Crawford R, et al.** Magnetically controlled growing rods in the treatment of early-onset scoliosis: a note of caution. *Bone Joint J* 2017;99-B:708-713.
30. **Teoh KH, von Ruhland C, Evans SL, et al.** Metallosis following implantation of magnetically controlled growing rods in the treatment of scoliosis: a case series. *Bone Joint J* 2016;98-B:1662-1667.
31. **Joyce TJ, Smith SL, Rushton PRP, Bowey AJ, Gibson MJ.** Analysis of explanted magnetically controlled growing rods from seven UK spinal centers. *Spine* 2018;43:E16-E22.
32. **Flynn JM, Tomlinson LA, Pawelek J, et al.** Growing-rod graduates: lessons learned from ninety-nine patients who completed lengthening. *J Bone Joint Surg [Am]* 2013;95:1745-1750.
33. **Sawyer JR, de Mendonça RG, Flynn TS, et al.** Complications and radiographic outcomes of posterior spinal fusion and observation in patients who have undergone distraction-based treatment for early onset scoliosis. *Spine Deform* 2016;4:407-412.
34. **Johnston CE, Tran DP, McClung A.** Functional and radiographic outcomes following growth-sparing management of early-onset scoliosis. *J Bone Joint Surg [Am]* 2017;99:1036-1042.
35. **Pizones J, Martín-Buitrago MP, Sánchez Márquez JM, et al.** Decision making of graduation in patients with early-onset scoliosis at the end of distraction-based programs: risks and benefits of definitive fusion. *Spine Deform* 2018;6:308-313.
36. **Feinberg N, Matsumoto H, Hung CW, et al.** Expert consensus and equipoise: planning a randomized controlled trial of magnetically controlled growing rods. *Spine Deform* 2018;6:303-307.