

A patient with traumatic chylothorax

Amina Barkat¹
Ilham Benbouchta¹
Lamia Karboubi¹
Zineb Ghanimi²
Meryem Kabiri¹

¹National Reference Center in Neonatology and Nutrition, Children's Hospital, Rabat, Morocco; ²University Mohammed V souissi of Rabat, Rabat, Morocco

Abstract: Chylothorax refers to the accumulation of chyle in the pleural cavity. Although rare, it is the most frequent cause of pleural effusion in the neonatal period. Its incidence is estimated at one in 15,000 neonates. The causes of chylothorax are multiple, and there are several major types of chylothorax defined by origin, ie, traumatic (and iatrogenic) chylothorax, medical (spontaneous) chylothorax, and congenital chylothorax. A case of neonatal chylothorax following surgery for esophageal atresia and our therapeutic approach to this entity are presented. Conservative therapy with total enteral nutrition and drainage were sufficient. Treatment for chylothorax is essentially medical, ie, pleural drainage, removal of dietary fats, treatment of any medical cause, and use of drugs to reduce production of chyle. In the event of failure or reappearance of a large effusion, surgical treatment is needed.

Keywords: chylothorax, octreotide, somatostatin, children

Introduction

Chylothorax refers to pleural effusion of chyle. The causes of chylothorax are multiple, and there are several major types of chylothorax defined by their origins, ie, traumatic (and iatrogenic) chylothorax, medical (or spontaneous) chylothorax, and congenital chylothorax. Treatment is primarily medical, but in the event of failure or reappearance of a large effusion, surgical treatment is needed. We present the case of a newborn who developed chylothorax after surgery for esophageal atresia, and outline the different ways of treating this complication.

Case report

A male newborn, delivered vaginally, was admitted to the neonatal intensive care unit of the Children's Hospital in Rabat, Morocco, in the early hours of life, to support preoperative and postoperative esophageal atresia. The esophageal atresia was diagnosed immediately in the delivery room, and confirmed with an x-ray of the esophagus showing an air-filled pouch and air in the stomach and intestine. A feeding tube had been inserted, and appeared to be coiled in the upper esophagus. No other abnormalities were identified, except for a lower thoracic vertebral anomaly and 13 pairs of ribs.

Surgery was performed on the second day of life for an esophageal atresia with a distal tracheoesophageal fistula. Treatment consisted of surgical repair to close the fistula and reconnect the two ends of the esophagus, with chest drainage. The patient was extubated on the fourth postoperative day without complications. On the fifth postoperative day, the patient developed respiratory distress. A chest x-ray was performed and showed pleural fluid (Figure 1). Insertion of a chest drain produced approximately

Correspondence: Amina Barkat
National Center of Neonatology
and Nutrition, Children's Hospital,
Rabat, Morocco
Tel +00212661385108
Email barakatamina@yahoo.fr

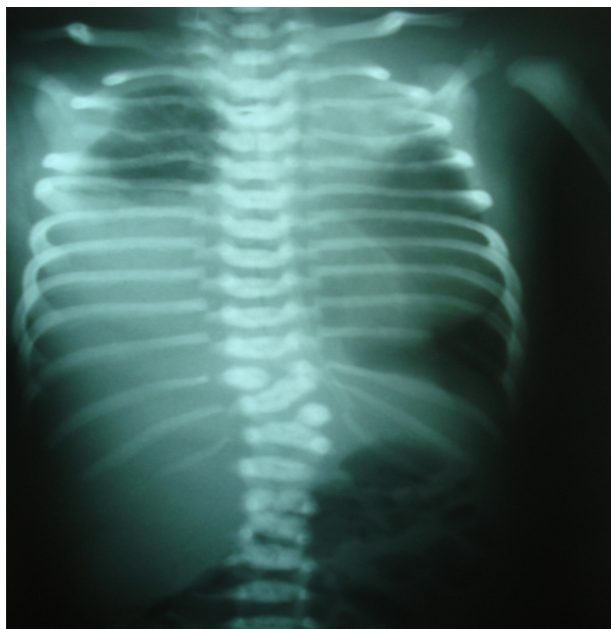

Figure 1 Chest X-ray showing pleural effusion in right pulmonary hemifield.

100 mL of yellow and increasingly opaque fluid (protein 4.5 g/dL, triglycerides 325 mg/dL), and enteral feeding was started. An infectious cause was eliminated. Esophageal opacification was normal. These findings were suggestive of a chylous leak. In view of the lack of availability of parenteral nutrition products in our hospital, oral feedings were started using formula containing medium-chain triglycerides. One week later, the chylous drainage had decreased, and the patient's clinical condition, in particular respiratory status, was gradually stabilizing. Protein losses were replaced and immunoglobulins were given to compensate for antibody loss. The chyle leak had resolved completely ten days later (Figure 2).

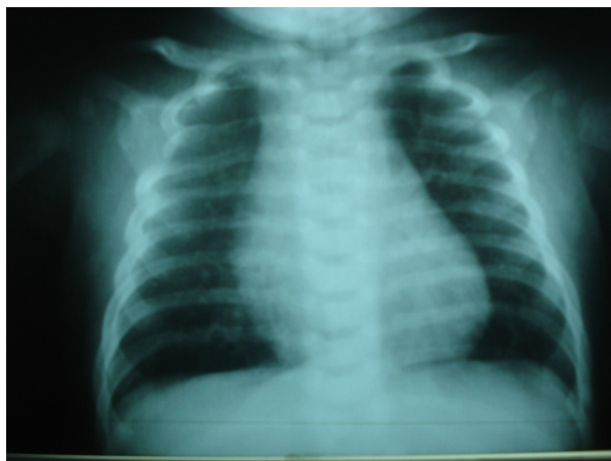


Figure 2 Chest X-ray 10 days later showing resolution of chyle leak.

Discussion

Chylothorax is a serious complication that may follow any thoracic procedure requiring dissection in the proximity of the thoracic duct.¹ The estimated incidence is 0.25%–0.5% after cardiovascular surgery. It has also been reported after esophageal, mediastinal, diaphragmatic, and pleuropulmonary surgery.^{1,2}

In 1948, Lampson introduced a procedure for thoracic duct ligation that offered a surgical alternative when spontaneous healing of chylothorax appeared unlikely. Further reduction in morbidity and mortality has been achieved more recently by the use of total parenteral nutrition and enteral formulae containing medium-chain triglycerides,^{3,4} so the majority of these effusions can now heal without ligation.⁵ Most of our knowledge about the management of chylothorax in children comes from small case series, and none of the available treatments has been subject to randomized controlled trials.^{6–9}

The principles of management for chylothorax in children are drainage, dietary modification, somatostatin and its synthetic analog (octreotide), surgery, and prevention and treatment of complications. The effect of combination of different medical therapies has not been assessed and remains controversial. However, it is important to know that use of simple, accessible, and inexpensive therapeutics may enable healing and avoidance of surgery. This message is especially important for countries with limited resources. In our case, we used both tube drainage and dietary modification.

Drainage is the initial step in all cases, both for diagnostic purposes and to quantify pleural fluid with regard to fluid imbalance. Some centers have adopted a therapeutic approach, with daily drainage as a guide to clinical improvement or failure (<10 mL/kg/day improvement, >10 mL/kg/day failure, after 4 weeks of nonsurgical management).⁶ If the size of the effusion compromises respiration and/or the collection is likely to recur, a chest tube should be inserted for continuous drainage of the pleural space, and this option was used in our patient.

The aim of dietary modification is to reduce the flow of chyle through the thoracic duct while awaiting spontaneous healing. Knowledge of lipid metabolism is required to understand the relationship between diet, fat content, and thoracic duct flow. Medium-chain triglycerides containing 6–12 chain carbon fatty acids are absorbed from the gastrointestinal tract directly into the portal circulation, and transported to the liver for metabolism. Long-chain triglycerides contain >12 carbon chain fatty acids, constitute up to 95% of total triglycerides in the diet, and are

insoluble in water. Therefore, they need to be transformed into lipoproteins (chylomicrons) before they can be transported in the blood. Chylomicrons are macromolecules rich in long-chain triglycerides, cholesterol, phospholipids, and proteins. They are extruded from intestinal mucosal cells into lacteals, and from there into the lymphatic system through the thoracic duct into the venous system.¹⁰ This explains the milky appearance of chyle. During fasting, chyle is usually clear because of its low fat and protein content, as was observed in our case as a result of the constitution of chylothorax before feeding. These data explain why chylothorax is usually managed by a fat-free diet with the addition of medium-chain triglycerides.

A more aggressive option is complete enteric rest using total parenteral nutrition. Because of immunoglobulin loss and progressive lymphopenia, secondary immune deficiency can occur. Adjuvant treatment is essential in most cases, with the aim of maintaining fluid balance and compensating for loss of immunoglobulins.

Drugs such as somatostatin or its synthetic analog, octreotide, are now being used more widely in chylothorax. Octreotide reduces digestive secretions, intrahepatic venous pressure, and splanchnic blood flow. The advantage of octreotide is that it can be administered subcutaneously, whereas somatostatin requires continuous intravenous infusion. Roehr et al published a systematic review on the use of somatostatin or octreotide for chylothorax in children. A total of 35 children treated for chylothorax were reviewed, of whom ten were given somatostatin and the remaining 25 received octreotide. Somatostatin was given as an intravenous infusion at a median dose of 204 (range 10–288) $\mu\text{g}/\text{kg}/\text{day}$. Octreotide was administered mainly as an intravenous infusion at a median dose of 68 (range 7.2–240) $\mu\text{g}/\text{kg}/\text{day}$. When given subcutaneously, the median dose was 40 (range 2–68) $\mu\text{g}/\text{kg}/\text{day}$. The median duration of treatment was 9.5 days for somatostatin compared with 7 days for intravenous octreotide and 17 days for subcutaneous octreotide. Both somatostatin and octreotide are considered to be safe. Side effects are unusual but include hyperglycemia, hypothyroidism, cramps, nausea, diarrhea, renal impairment, necrotizing enterocolitis, and liver dysfunction.¹¹ The challenge for countries with limited resources is the cost and unavailability of these therapeutic agents. We recommend using them as second-line therapy when dietary modification alone for up to 2 weeks is insufficient. The response to medical treatment of chylothorax (dietary modification and/or adjunctive medication) may take several weeks to become apparent. Most series performed in children recommend

persisting with medical treatment for up to 2–4 weeks before considering surgical intervention. A surgical approach, ie, ligation of the thoracic duct, is recommended in most cases of chylothorax in children, given the poor response to medical management.

Conclusion

Chylothorax is a rare cause of pleural effusion in the neonate which can be difficult to diagnose and manage. The diagnosis should be suspected in patients with pleural effusion following cardiothoracic or mediastinal surgery. Nonoperative management of chylothorax in children is successful in more than 80% of reported cases, including those with chylothorax following cardiothoracic surgery. Prospective randomized controlled studies should be performed to identify factors predictive of the success of any specific treatment early in the course of the illness, to compare different therapeutic approaches, to determine the ideal dosage regimen, time of initiation, and route of administration for somatostatin and octreotide. However, for countries with limited resources it is important to know that management can be undertaken using tube drainage and dietary modification.

Disclosure

The authors report no conflicts of interest in this work.

References

- Hargus EP, Carson SD, McGrath RL. Chylothorax and chylopericardial tamponade following Blalock-Taussig anastomosis. *J Thorac Cardiovasc Surg.* 1978;75:642–645.
- Cevese PG, Vecchioni R, D'Amico DF, et al. Postoperative chylothorax: six cases in 2500 operations with a survey of the world literature. *J Thorac Cardiovasc Surg.* 1975;69:966–971.
- Hashim S, Roholt HB, Babayan VK, Vanitallie TB. Treatment of chyluria and chylothorax with medium-chain triglyceride. *N Engl J Med.* 1964;270:756–761.
- Bozzetti F, Arullani A, Baticci F, et al. Management of lymphatic fistulas by total parenteral nutrition. *JPEN J Parenter Enteral Nutr.* 1982;6:526–527.
- Donato L, Scheib-Brolly C. Inherited lymphatic disorders of the lung. *Arch Pédiatr.* 2010;17:693–694. French.
- Beghetti M, La Scala G, Belli D, Bugmann P, Kalangos A, Le Coultre C. Etiology and management of pediatric chylothorax. *J Pediatr.* 2000;136:653–658.
- Büttiker V, Fanconi S, Burger R. Chylothorax in children: guidelines for diagnosis and management. *Chest.* 1999;116:682–687.
- Johnstone DW. Postoperative chylothorax. *Chest Surg Clin N Am.* 2002;12:597–603.
- Nguyen DM, Shum-Tim D, Dobell AR, Tchervenkov CI. The management of chylothorax/chylopericardium following pediatric cardiac surgery: a 10-year experience. *J Card Surg.* 1995;10(4 Pt 1):302–308.
- Merrigan BA, Winter DC, O'Sullivan GC. Chylothorax. *Br J Surg.* 1997;84:15–20.
- Roehr CC, Jung A, Proquitté H, et al. Somatostatin or octreotide as treatment options for chylothorax in young children: a systematic review. *Intensive Care Med.* 2006;32:650–657.

International Journal of General Medicine**Dovepress****Publish your work in this journal**

The International Journal of General Medicine is an international, peer-reviewed open-access journal that focuses on general and internal medicine, pathogenesis, epidemiology, diagnosis, monitoring and treatment protocols. The journal is characterized by the rapid reporting of reviews, original research and clinical studies across all disease areas.

A key focus is the elucidation of disease processes and management protocols resulting in improved outcomes for the patient. The manuscript management system is completely online and includes a very quick and fair peer-review system. Visit <http://www.dovepress.com/testimonials.php> to read real quotes from published authors.

Submit your manuscript here: <http://www.dovepress.com/international-journal-of-general-medicine-journal>