

**Acalculous cholecystitis with multiple organ failure and disseminated intravascular coagulation in a patient with adult onset Still's disease**

**Natalia G. Vallianou<sup>a</sup>, Charikleia Kouvidou<sup>b</sup>,  
Anna Naxaki<sup>a</sup>, Aristos Aristodimou<sup>a</sup>**

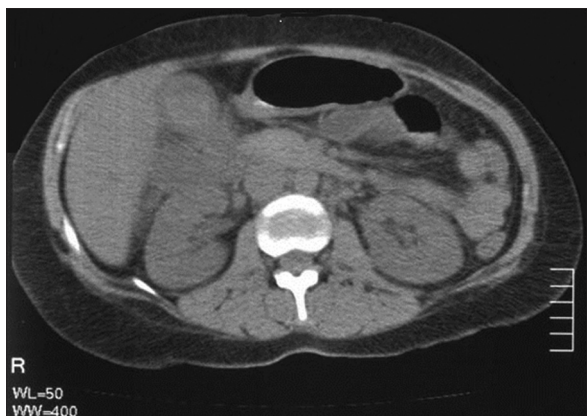
Evangelismos General Hospital, Athens, Greece

Acute acalculous cholecystitis usually occurs in critically ill patients. Herein, we describe a young female patient on prednisone and anakinra therapy due to adult onset Still's disease who presented to the hospital with shock and multiple organ failure.

A 28-year-old female patient presented to the emergency department with fever and vomiting, a temperature of 40°C, with no peripheral pulse, difficulty communicating and abdominal pain with severe and diffuse tenderness. Her systolic blood pressure was 50 mmHg and intravenous fluids were rigorously administered together with antimicrobial chemotherapy with ciprofloxacin, meropenem and metronidazole. The patient was referred for abdominal ultrasound that was normal and for abdominal CT scan, which revealed the presence of acalculous cholecystitis (Fig. 1).

From her medical history, the patient had adult onset Still's disease and had been receiving prednisone 10 mg/d and anakinra daily. Laboratory findings together with the clinical presentation of the patient were compatible with shock with multiple organ failure and disseminated intravascular coagulation. The patient received fresh frozen plasma and was referred for laparoscopic cholecystectomy. On histopathology, chronic cholecystitis with signs of acute inflammation with invasion of many neutrophils was present. Her clinical signs gradually improved and she was stabilized. Defervescence occurred and the patient recovered, but five days afterwards, she experienced a temperature of 38.3°C without any abdominal pain and with negative blood cultures. After consultation with rheumatologists, she was administered prednisone and naproxen with complete resolution of fever.

Acalculous cholecystitis accounts for 5-15% of cases of cholecystitis and has usually a more severe presentation and worse prognosis than calculous cholecystitis. It occurs predominantly in critically ill patients and has a high morbidity and mortality rate [1]. Its pathophysiology remains largely unknown, but it is suggested that ischemia and prolonged hypoperfusion of the gallbladder play an important role in its pathogenesis [2]. It is commonly seen secondary to sepsis, trauma, burns, diabetes mellitus, vasculitis, prolonged fasting or the prolonged use of total parenteral nutrition and generally any critical illness [1-3].



**Figure 1** Abdominal CT scan depicting an enlarged gallbladder with edema, findings suggestive of acute cholecystitis

Acalculous cholecystitis has been reported as a very rare manifestation of systemic lupus erythematosus either alone or in combination with rheumatoid arthritis or Sjögren's syndrome [4-6]. Vasculitides and connective tissue disorders are well-known factors predisposing to acalculous cholecystitis. It is noteworthy that in connective tissue disorders and vasculitides, acalculous cholecystitis is usually a manifestation of the disease itself and not the result of immunosuppression [7]. In some cases of vasculitis- or connective tissue disorder-related acute acalculous cholecystitis, surgical intervention was usually preferred over enhanced doses of corticosteroids. Others administered high-dose corticosteroids and immunosuppressive agents instead of surgery, with fine results. Of course, the role of antimicrobial chemotherapy cannot be overlooked.

To our knowledge, acute acalculous cholecystitis has only been reported once in adult onset Still's disease to date [8]. The presence of acute acalculous cholecystitis in the context of Still's disease must not be overlooked as the administration of corticosteroids, non-steroid anti-inflammatory drugs or immunomodulatory agents could be beneficial. Another possibility is that surgery could be substituted by corticosteroids or immunomodulatory therapy.

## References

1. McChesney J, Northup P, Dickston S. Acute acalculous cholecystitis associated with systemic sepsis and visceral arterial hypoperfusion. *Dig Dis Sci* 2003;**48**:1960-1967.
2. Aitken E, Lyon A, Felstenstein I. An unusual case of acalculous cholecystitis heralding presentation of acute mesenteric ischaemia with typical radiological findings. *Int J Surg Case Rep* 2012;**3**:346-248.
3. Huffman J, Schenker S. Acute acalculous cholecystitis: a review. *Clin Gastroenterol Hepatol* 2010;**8**:15-22.
4. Hegarty J, Chiu DY, Middleton RJ, et al. Systemic lupus erythematosus, eosinophilic vasculitis and acalculous cholecystitis. *Nephrol Dial Transplant* 2006;**21**:792-795.
5. Shin SJ, Na KY, Jung SS, et al. Acute acalculous cholecystitis associated with systemic lupus erythematosus with Sjogren's syndrome. *Korean J Intern Med* 2002;**17**:61-64.
6. Mendonca J, Marques-Neto J, Prando P, Appenzeller S. Acute acalculous cholecystitis in juvenile systemic lupus erythematosus. *Lupus* 2009;**18**:561-563.
7. Meier M, Holl-Ulrich K, Perras B. A rare manifestation of cryoglobulinemic vasculitis: acalculous cholecystitis. *Clin Gastroenterol Hepatol* 2005;**3**:26.
8. Park JH, Bae JH, Choi JS, et al. Adult-onset Still's disease with disseminated intravascular coagulation and multiple organ dysfunctions dramatically treated with cyclosporine A. *J Korean Med Sci* 2004;**19**:137-141.

Departments of \*Internal Medicine (Natalia G. Vallianou, Anna Naxaki, Aristos Aristodimou); <sup>b</sup>Pathology (Charikleia Kouvidou), Evangelismos General Hospital, Athens, Greece

Conflict of Interest: None

Correspondence to: Natalia Vallianou, MD, PhD, 5 Pyramidon str, 190 05, Municipality of Marathon, Athens, Greece, Tel.: +30 22940 92359, e-mail: natalia.vallianou@hotmail.com

Received 20 January 2014; accepted 23 January 2014