



Circulating tumor DNA accurately predicts disease progression and genotype alterations in postoperative adjuvant EGFR-TKI resistance: a case report

Zhen Zeng^{1#}, Chengwu Liu^{1#}, Senyi Deng¹, Feng Lin¹, Hatim Husain², Mariacarmela Santarpia³, Lunxu Liu¹

¹Department of Thoracic Surgery and Institute of Thoracic Tumor, West China Hospital, Sichuan University, Chengdu, China; ²Department of Medicine, University of California San Diego, La Jolla, CA, USA; ³Medical Oncology Unit, Department of Human Pathology “G. Barresi”, University of Messina, Messina, Italy

[#]These authors contributed equally to this work.

Correspondence to: Professor Lunxu Liu. Department of Thoracic Surgery and Institute of Thoracic Tumor, West China Hospital, Sichuan University, No. 37, Guoxue Alley, Chengdu 610041, China. Email: lunxu_liu@aliyun.com.

Background: Circulating tumor DNA (ctDNA) is receiving more and more attention for its role in tumor screening and disease surveillance in cancer patients. However, it is unclear whether ctDNA can be used to predict recurrence and metastasis in patients after radical resection due to the resulting lower tumor burden. The published literature on postoperative ctDNA levels is also currently limited.

Case Description: In this article, we report a rare case in which ctDNA accurately predicted relapse, disease progression and mechanism of resistance to epidermal growth factor receptor-tyrosine kinase inhibitor (EGFR-TKI) in adjuvant setting in an *EGFR*-mutated lung adenocarcinoma patient. The 49-year-old male patient was a current smoker and denied any family history. Chest computed tomography (CT) scans revealed a 5.7×4.3 mass in the left upper lobe. He received adjuvant gefitinib after surgery for a stage IIIB (pT3N2M0) pulmonary adenocarcinoma. The ctDNA detection showed that the *EGFR* exon 19 deletion (*EGFR del19*) gene mutation frequencies decreased gradually and even disappeared. However, 8 months after the operation, the *EGFR del19* mutation re-emerged in the blood, accompanied by a newly emerged solitary nodule (2 mm) that was later confirmed to be metastatic. Soon afterward, ctDNA detection revealed the *EGFR T790M* mutation, and the mediastinal lymph nodes rapidly enlarged. The patient's treatment was switched to Osimertinib and the ctDNA detection results showed the *EGFR T790M* gene mutation frequencies steadily decreased to zero. During the treatment period, ctDNA detection accurately predicted each change in disease burden and revealed genotype alterations. The patient ultimately developed severe metastases in the liver after developing resistance to Osimertinib.

Conclusions: This report suggests that ctDNA help monitor disease recurrence and identify genotypes in patients undergoing postoperative adjuvant EGFR-TKI therapy. More clinical researches are needed to support ctDNA is a promising tool for predicting disease progressive.

Keywords: Circulating tumor DNA (ctDNA); gefitinib; osimertinib; postoperative adjuvant therapy; case report

Submitted May 23, 2022. Accepted for publication Sep 02, 2022.

doi: 10.21037/tlcr-22-562

View this article at: <https://dx.doi.org/10.21037/tlcr-22-562>

Introduction

As one of the biomarkers of liquid biopsy, circulating tumor DNA (ctDNA) has great potential for tumor screening and

disease surveillance (1-3). ctDNA based on next-generation sequencing (NGS) and detected a variety of mutations with a high sensitivity. Initial studies have demonstrated

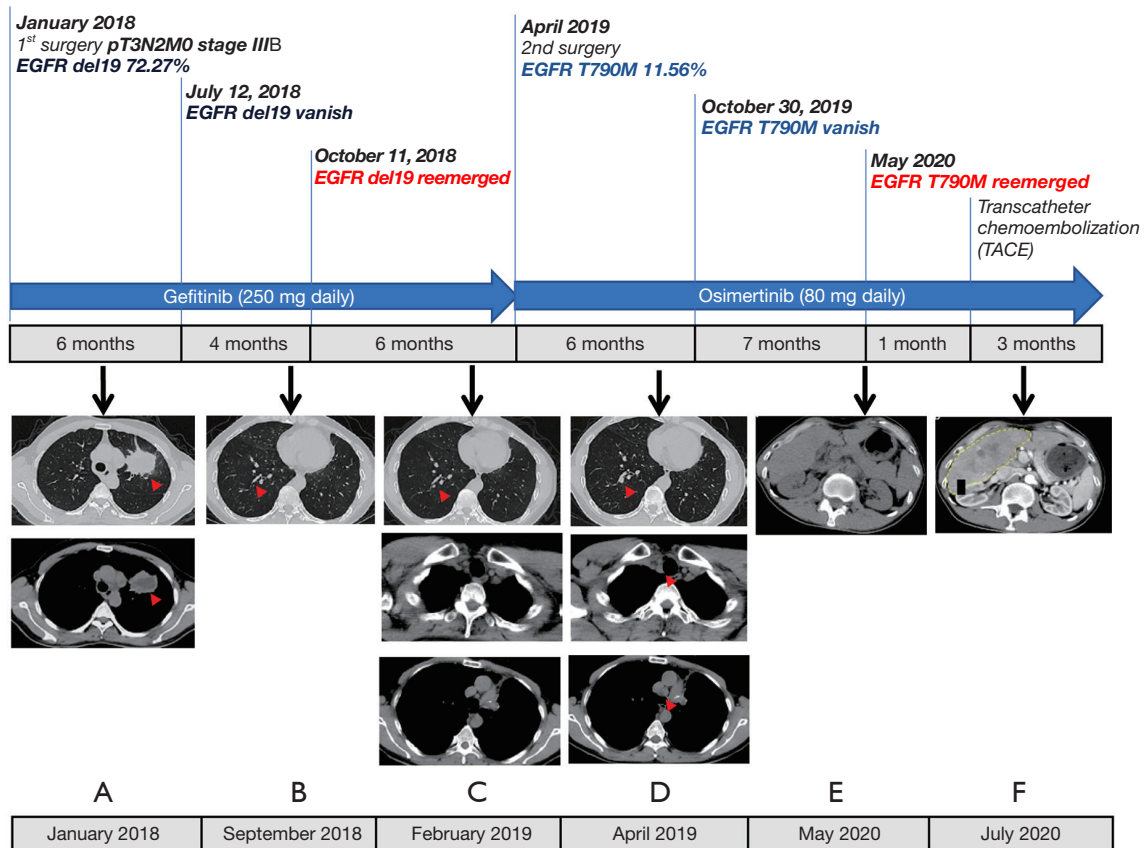


Figure 1 History of treatment. Timeline depicting diagnoses, ctDNA detection, changes in treatment, duration, and medical imaging. (A) CT scan (January 2018) with a left upper lobe lung mass (red triangle) before left pneumonectomy. (B) CT scan (September 2018) with a newly emerged solitary nodule (2 mm) in the right lower lobe (red triangle) after 8 months of gefitinib treatment gefitinib. (C) CT scan (February 2019) with development of the small nodules (red triangle) in the right lung. Normal group 2 and group 4 lymph nodes. (D) CT scan (April 2019) with intermediate size nodules in right lung and with group 2 and group 4 lymph nodes metastases (red triangle). (E) Upper abdomen CT scans (May 2020) with no sign of disease recurrence. (F) Upper abdomen CT scans (July 2020) a huge mass in the liver only 1 month later. ctDNA, circulating tumor DNA; CT, computed tomography.

that ctDNA can be used to assess the tumor burden and monitor disease recurrence in advanced solid tumors (4-7). This biomarker has shown partial validity and high sensitivity (8). However, it is unclear whether ctDNA can be used to predict recurrence and metastasis in patients after radical resection due to the resulting lower tumor burden. The published literature on postoperative ctDNA levels is currently limited. In this article, we report a rare case in which ctDNA accurately predicted disease progression at each stage during postoperative adjuvant therapy with an epidermal growth factor receptor-tyrosine-kinase inhibitor (EGFR-TKI). This case provides new ideas for ctDNA predicting disease progressive after radical resection in the future studies. We present the following article in

accordance with the CARE reporting checklist (available at <https://tldr.amegroups.com/article/view/10.21037/tlcr-22-562/rc>).

Case presentation

A 49-year-old man, who was a current smoker, presented with productive cough for 1 month in January 2018. Chest computed tomography (CT) scans revealed a 5.7×4.3 mass in the left upper lobe. He denied any family history. The Carcinoma Embryonic Antigen (CEA) level is 45.6 ng/mL and the CA125 level is 52.87 ng/mL. Surgery was indicated, and thoracoscopic left upper lobectomy and systemic lymph node dissection were promptly performed (Figure 1). The

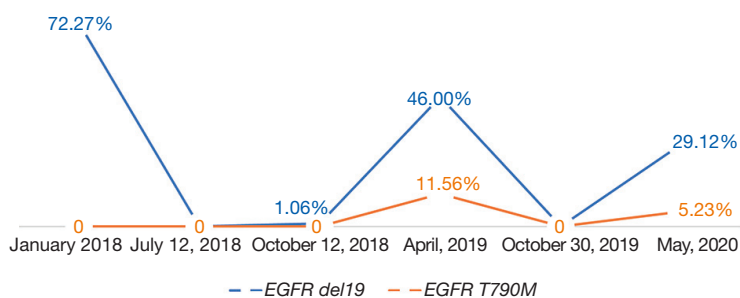


Figure 2 The ctDNA monitorization in *EGFR del19* and *EGFR T790M*. ctDNA, circulating tumor DNA; *EGFR*, epidermal growth factor receptor.

postoperative pathology identified a poorly and moderately differentiated adenocarcinoma (pT3N2M0, stage IIIB) with an *EGFR* exon 19 deletion (*EGFR del19*) mutation (Figure 1A). Adjuvant gefitinib (250 mg daily) was administered after surgery without any adverse events. The patient then underwent regular follow-up and ctDNA detection which was based on NGS. The time points for liquid biopsy are 3 days, 1 month, 3 months and every 3 months after surgery. For each time, 20–25 mL of peripheral blood was collected and 10 mL of plasma were used for ctDNA extraction.

Initially, the patient was in a stable condition with no recurrence. The ctDNA detection (LOD: 0.01%) showed that the *EGFR del19* gene mutation frequencies decreased gradually from 72.27% before surgery to zero 6 months after surgery (July 12, 2018). However, 9 months after the surgery, the *EGFR del19* mutation re-emerged (1.06%) in the blood, accompanied by a newly emerged solitary nodule (2 mm) in the right lower lobe on September 10, 2018 (Figure 1B). At the same time, the *STAT3 M726I* mutation appeared in the ctDNA detection results. The patient continued treatment with gefitinib. However, the nodule in the right lower lobe continues to grow in the following 6 months (Figure 1C). Additionally, the group 2 and group 4 lymph nodes rapidly enlarged, but were still normal in February 2019 (Figure 1C). At 15 months after the operation, the nodule had grown to 1.0 cm × 1.2 cm (Figure 1D), and an *EGFR T790M* mutation (11.56%) had emerged in the blood (April 4, 2019), while the *EGFR del19* gene mutation frequency was 46.0%.

The patient requested resection of the nodule, and the positron emission tomography (PET)/CT revealed no other diseases. He was performed a lobectomy with resection of lymph nodes and the pathologic examination of the surgical specimen confirmed metastatic adenocarcinoma with lymph

node metastasis, and tissue gene sequencing confirmed an *EGFR T790M* mutation on April 20, 2019. After the second surgery, the patient continued Gefitinib treatment until May 2019, when he was switched to Osimertinib (80 mg daily). The *EGFR T790M* gene mutation frequencies in the blood steadily decreased to zero and the monitorization through liquid biopsy was shown Figure 2.

13 months after the second surgery, the chest and upper abdominal CT scans revealed no signs of disease recurrence until May 2020 (Figure 1E). However, only one month later, he began to develop progressive epigastralgia and abdominal distension. The *EGFR T790M* mutation (5.23%) re-emerged in the blood with a variant allele frequency of 5.23% and *EGFR del19* with 29.12% in ctDNA, and a large mass was found in the liver by upper abdominal contrast-enhanced CT scans (Figure 1F). Transcatheter chemoembolization was performed for the hepatic lesion. The patient remains in follow up as of October 2020, and has ongoing cachexia.

All procedures performed in this study were conducted in accordance with the ethical standards of the institutional and/or national research committee(s) and with the Helsinki Declaration (as revised in 2013). Written informed consent was obtained from the patient for publication of this case report and accompanying images. A copy of the written consent is available for review by the editorial office of this journal.

Discussion

EGFR-TKIs have been shown to be efficient and safe as postoperative adjuvant therapy for patients with *EGFR* mutation-positive pulmonary adenocarcinoma (9). However, drug resistance still occurs in a considerable number of patients. Additionally, the integration of tools that have high sensitivity for disease surveillance are still lacking.

The current conventional clinical surveillance approach for patients is radiographic imaging, including CT, magnetic resonance imaging, and PET/CT. However, these methods may not be sensitive enough to identify therapeutic response or disease progression in a timely manner. It has been difficult for oncologists to adapt treatment accordingly and promptly. As a result, patients can have a larger disease burden before a diagnosis of drug resistance or disease progression can be made. Further, patients generally need to undergo a new biopsy to understand the mechanisms of resistance. Unfortunately, tissue biopsy is not always feasible or safe for patients.

As a non-invasive technique, ctDNA detection can be performed frequently to track tumor-associated genetic information and monitor residual diseases (10,11). Previous studies have confirmed the feasibility of ctDNA in monitoring EGFR-TKI resistance-related genetic mutations (1). Compared to routine methods, ctDNA detection can identify disease recurrence significantly earlier (12). In our patient, the ctDNA detection accurately predicted disease progression at each stage after the patient developed resistance to postoperative adjuvant EGFR-TKIs.

During the initial period, the primary mutation of *EGFR del19* reappeared as the patient developed a new solitary metastatic nodule in another lobe. The accompanying gene mutation detected was in *STAT3*, which has been reported to promote tumor growth (13). This was the first time that ctDNA detection revealed the patient's drug resistance. Soon thereafter, the ctDNA detection revealed the *EGFR T790M* mutation, and the mediastinal lymph nodes rapidly enlarged. The time points for ctDNA detection are 3 days, 1 month, 3 months and every 3 months after surgery. During the following period, the ctDNA detection accurately predicted each change in disease burden. Unfortunately, the therapeutic plan could not be promptly adjusted when the ctDNA detection indicated disease progression. The patient ultimately developed additional metastases in the liver after developing resistance to Osimertinib, and subsequent therapy had limited control.

Conclusions

Our case highlights that ctDNA is an emerging tool for monitoring disease recurrence and revealing genotypes in patients undergoing postoperative adjuvant EGFR-TKI therapy. Prospective studies are needed to correlate ctDNA changes with imaging changes.

Questions to be further discussed and considered

Q1: *Our results suggest that ctDNA is a promising tool for monitoring disease recurrence and predicting genotypes in patients with a lower tumor burden after radical resection. Is there any difference in using ctDNA detection for patients with low or high tumor burdens?*

Hatim Husain: Yes, there is more likely to have a negative baseline result in patients with low tumor burdens.

Mariacarmela Santarpia: The tumor stage and overall tumor burden can influence the abundance of ctDNA found in blood. Therefore, highly sensitive blood-based techniques should be used for ctDNA analysis when present at lower concentrations.

Q2: *As an effective tool for monitoring cancer recurrence, what is the recommended frequency for ctDNA detection in the follow-up period?*

Hatim Husain: In order to be able to correlate with imaging, it is advisable to obtain ctDNA measurements in synchrony with imaging correlates.

Mariacarmela Santarpia: More prospective studies are needed to define the optimal frequency of ctDNA analysis during post-operative follow-up in lung cancer patients.

Q3: *Radiographic imaging is a routine clinical surveillance approach for patients. How can therapeutic responses or disease progression be identified in a timely manner using a combination of medical imaging and ctDNA?*

Hatim Husain: Imaging can be used to characterize anatomy and structural changes as it pertains to cancer, however ctDNA can be used to qualitatively characterize genomic tumor changes to understand if there is genomic resistance over time that can affect the applicability of therapy.

Mariacarmela Santarpia: ctDNA collection and analysis could be performed before at baseline (at diagnosis) and in parallel to radiographic imaging used as surveillance after definitive therapy, in accordance to non-small cell lung cancer guidelines (e.g., every 6 months for 3 years for early-stage patients undergoing surgery and adjuvant therapy). Since liquid biopsy represents a surrogate for tumor tissue for noninvasive assessment of tumor specific biomarkers, ctDNA analysis could also be performed more frequently

than radiographic imaging in the post-operative setting for high-risk tumors (e.g., for stage III, every 3–6 months for 5 years).

Acknowledgments

The authors appreciate the academic support from the AME Thoracic Surgery Collaborative Group.

Funding: This work was supported by the Basic Science Program (grant number 2019YJ0077 to LF), the Science and Technology Department of Sichuan Province, NSFC (grant number 81672311 to LLX), and the 1.3.5 Project for Disciplines of Excellence of West China Hospital, Sichuan University (grant number ZYGD18021 to LLX).

Footnote

Reporting Checklist: The authors have completed the CARE reporting checklist. Available at <https://tldr.amegroups.com/article/view/10.21037/tlcr-22-562/rc>

Conflicts of Interest: All authors have completed the ICMJE uniform disclosure form (available at <https://tldr.amegroups.com/article/view/10.21037/tlcr-22-562/coif>). HH has received consulting fees from Janssen and Astrazeneca and honoraria from Janssen, Astrazeneca, Neogenomics, and Foundation Medicine. The other authors have no conflicts of interest to declare.

Ethical Statement: The authors are accountable for all aspects of the work, including ensuring that any questions related to the accuracy or integrity of any part of the work have been appropriately investigated and resolved. All procedures performed in this study were conducted in accordance with the ethical standards of the institutional and/or national research committee(s) and with the Helsinki Declaration (as revised in 2013). Written informed consent was obtained from the patient for publication of this case report and accompanying images. A copy of the written consent is available for review by the editorial office of this journal.

Open Access Statement: This is an Open Access article distributed in accordance with the Creative Commons Attribution-NonCommercial-NoDerivs 4.0 International License (CC BY-NC-ND 4.0), which permits the non-commercial replication and distribution of the article with the strict proviso that no changes or edits are made and the

original work is properly cited (including links to both the formal publication through the relevant DOI and the license). See: <https://creativecommons.org/licenses/by-nc-nd/4.0/>.

References

1. Wu TH, Hsiue EH, Yang JC. Opportunities of circulating tumor DNA in lung cancer. *Cancer Treat Rev* 2019;78:31-41.
2. Yoshinami T, Kagara N, Motooka D, et al. Detection of ctDNA with Personalized Molecular Barcode NGS and Its Clinical Significance in Patients with Early Breast Cancer. *Transl Oncol* 2020;13:100787.
3. Weber S, van der Leest P, Donker HC, et al. Dynamic Changes of Circulating Tumor DNA Predict Clinical Outcome in Patients With Advanced Non-Small-Cell Lung Cancer Treated With Immune Checkpoint Inhibitors. *JCO Precis Oncol* 2021;5:1540-53.
4. Rolfo C, Mack PC, Scagliotti GV, et al. Liquid Biopsy for Advanced Non-Small Cell Lung Cancer (NSCLC): A Statement Paper from the IASLC. *J Thorac Oncol* 2018;13:1248-68.
5. Johann DJ Jr, Steliga M, Shin IJ, et al. Liquid biopsy and its role in an advanced clinical trial for lung cancer. *Exp Biol Med (Maywood)* 2018;243:262-71.
6. Alimirzaie S, Bagherzadeh M, Akbari MR. Liquid biopsy in breast cancer: A comprehensive review. *Clin Genet* 2019;95:643-60.
7. Peng Y, Mei W, Ma K, et al. Circulating Tumor DNA and Minimal Residual Disease (MRD) in Solid Tumors: Current Horizons and Future Perspectives. *Front Oncol* 2021;11:763790.
8. Cohen JD, Javed AA, Thoburn C, et al. Combined circulating tumor DNA and protein biomarker-based liquid biopsy for the earlier detection of pancreatic cancers. *Proc Natl Acad Sci U S A* 2017;114:10202-7.
9. Wu YL, Tsuboi M, He J, et al. Osimertinib in Resected EGFR-Mutated Non-Small-Cell Lung Cancer. *N Engl J Med* 2020;383:1711-23.
10. Tamiya A, Isa SI, Taniguchi Y, et al. Prospective Observational Study of Treatment Resistance-related Gene Screening Using Plasma Circulating Tumor DNA in Third-generation EGFR-TKI Osimertinib Therapy (Elucidator). *Clin Lung Cancer* 2021;22:e336-41.
11. Shi J, Wang Z, Zhang J, et al. Genomic Landscape and Tumor Mutational Burden Determination of Circulating Tumor DNA in Over 5,000 Chinese Patients with Lung Cancer. *Clin Cancer Res* 2021;27:6184-96.

12. Chaudhuri AA, Chabon JJ, Lovejoy AF, et al. Early Detection of Molecular Residual Disease in Localized Lung Cancer by Circulating Tumor DNA Profiling. *Cancer Discov* 2017;7:1394-403.
13. Shahmarvand N, Nagy A, Shahryari J, et al. Mutations in

the signal transducer and activator of transcription family of genes in cancer. *Cancer Sci* 2018;109:926-33.

(English Language Editor: L. Huleatt)

Cite this article as: Zeng Z, Liu C, Deng S, Lin F, Husain H, Santarpia M, Liu L. Circulating tumor DNA accurately predicts disease progression and genotype alterations in postoperative adjuvant EGFR-TKI resistance: a case report. *Transl Lung Cancer Res* 2022;11(9):1961-1966. doi: 10.21037/tlcr-22-562