



Combined extracorporeal shockwave lithotripsy and ERCP for chronic calcific pancreatitis with the patient under general anesthesia in one session: an introduction to extracorporeal shockwave lithotripsy and a case example

Sheetal Patel, MD, Victoria Gómez, MD, FASGE

The role of extracorporeal shockwave lithotripsy (ESWL) in the management of patients with chronic calcific pancreatitis is evolving. The European Society of Gastrointestinal Endoscopy recommends ESWL for the clearance of radiopaque obstructive main pancreatic duct (PD) stones larger than 5 mm located in the head or body of the pancreas because standard ERCP methods are less likely to result in successful stone clearance.¹ However, although it is known to improve pain and quality of life in chronic calcific pancreatitis according to case studies and meta-analyses,² ESWL is not currently widely available in the United States because of a lack of randomized controlled trials or lack of equipment, as well as difficulty in setting up such a procedure. Herein, we report the successful clearance of a very large PD calculus by safely performing a single-anesthesia, combined ESWL-ERCP procedure within the endoscopy suite, thus bypassing the need for an operating room and separate anesthesia sessions (Video 1, available online at www.VideoGIE.org).

A 76-year-old white woman with diabetes mellitus and alcohol-related chronic calcific pancreatitis presented to our facility for a second opinion regarding a Puestow pro-

cedure. The patient's symptoms included steatorrhea and weight loss without significant abdominal pain. One year earlier, when presenting to her referring physicians, she was diagnosed with acute pancreatitis; evaluation revealed a very large pancreatic calculus. Prior imaging studies, including CT of the abdomen and pelvis and magnetic resonance imaging with MRCP, revealed pancreas divisum with a very dilated PD and a large PD stone impacted at the minor papilla (Figs. 1 and 2). Prior attempts to remove the stone endoscopically at the outside facility were unsuccessful. Therefore, the decision was made to proceed with ESWL and to fragment the stone to attempt cannulation of the minor papilla and decompression of the PD.

ESWL was first used for the treatment of kidney stones in 1980 and has subsequently been applied to the treatment of gallstones and PD stones. The basis of lithotripsy entails concentrating focused shockwaves on stones, resulting in their fragmentation; this is followed by either spontaneous passage of the calculi or ERCP to achieve

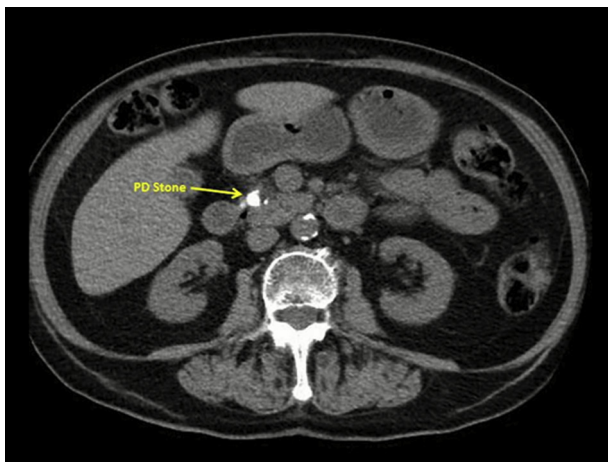


Figure 1. CT of the abdomen and pelvis revealed a large pancreatic duct stone.

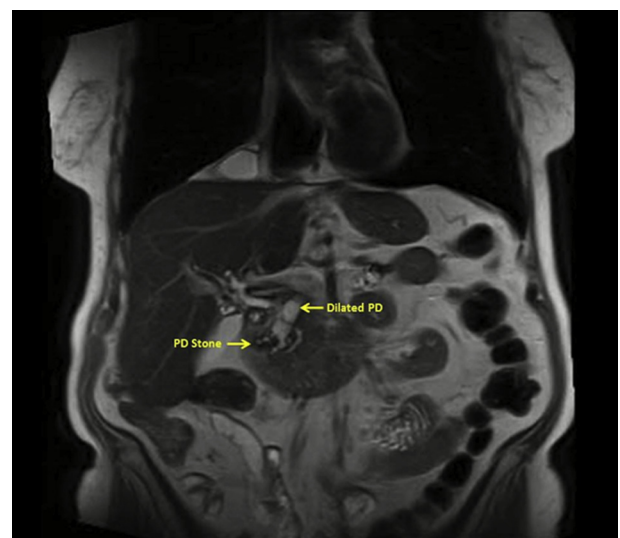


Figure 2. Magnetic resonance imaging with MRCP revealed pancreas divisum with a very dilated pancreatic duct and a large pancreatic duct stone impacted at the minor papilla.

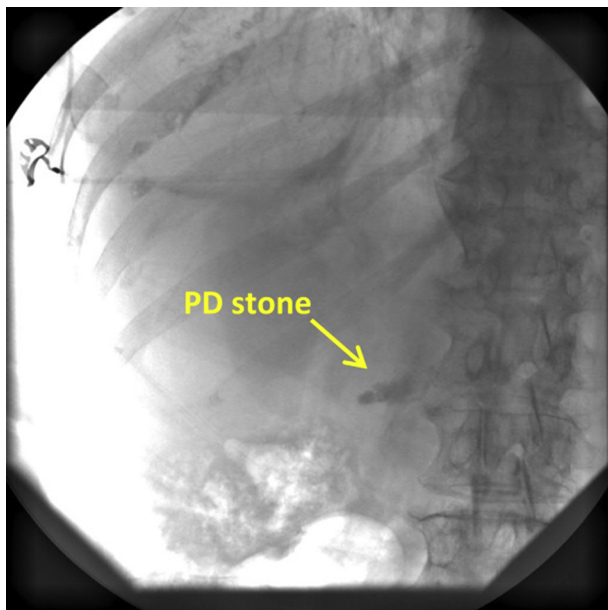


Figure 3. Visualization of the pancreatic duct stone on control film before initiation of extracorporeal shockwave lithotripsy.

ductal clearance. Shockwaves can be generated by 3 methods: (1) spark discharge (Dornier system), (2) piezoelectric elements (Wolf system), or (3) electromagnetic deflection of a metal membrane (Siemens system). Spark discharge is the established system used in our practice. Commercial lithotripters were originally designed for treatment of renal and ureteral calculi⁵; thus, using this equipment for the treatment of PD stones is an off-label use. Therefore, counseling the patient on the indications, benefits, risks, and alternatives of ESWL is of utmost importance.

ESWL for PD stones is indicated for patients with recurrent attacks of pancreatic pain and/or evidence of pancreatic insufficiency due to an obstructing PD stone and moderate-to-marked changes in the pancreatic ductal system. Generally, stones located toward the head or ampulla, stones greater than 5 mm, impacted stones, and the concomitant presence of ductal strictures can make stone removal without prior fragmentation difficult.¹ In such cases, ESWL may prove beneficial.^{2,4} Most importantly, the stone of interest must be well located and visualized on fluoroscopy to adequately target it with ESWL (Fig. 3). Otherwise, ERCP would need to be performed before ESWL to place a PD stent to mark the stone's location.

Contraindications to ESWL include coagulation disorders, pregnancy, the presence of implanted cardiac pacemakers or defibrillators, and the presence of bone, calcified aneurysms, or lung tissue in the shockwave path. Because our patient did not have any of these contraindications, we proceeded with the ESWL-ERCP procedure.

As in this case, patients receive general endotracheal anesthesia because of the prolonged nature of this com-

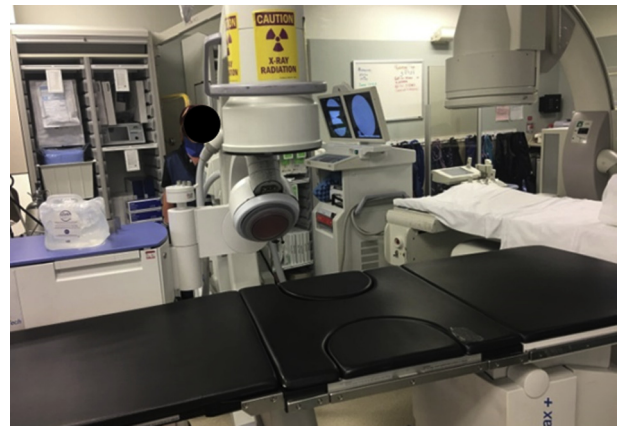


Figure 4. Spark discharge (Dornier system) portable lithotripsy system in the endoscopy suite. Here, visualized is the integrated C-arm for fluoroscopy, a fully motorized patient table, and the therapy head, which delivers the shockwave with a coupling cushion.

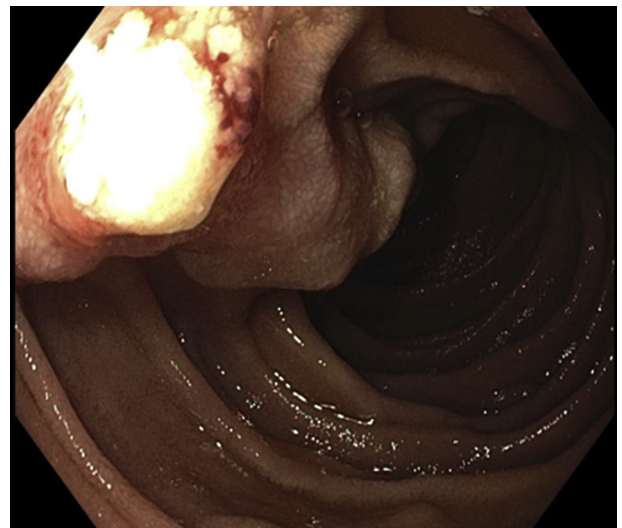

Figure 5. EGD performed after extracorporeal shockwave lithotripsy demonstrated stone fragments emanating from the minor papilla.

bined treatment and to reduce respiratory motion, which may compromise shockwave delivery. We typically do not administer antibiotics. Unless contraindicated, all patients also receive 100 mg of rectal indomethacin to reduce the risk of post-ERCP pancreatitis.

The portable lithotripter is set up before transport of the patient into the endoscopy suite. It has an integrated C-arm for fluoroscopy, a fully motorized patient table, and a therapy head that delivers the shockwave with a coupling cushion (Fig. 4).

The newer lithotripter systems allow patients to remain in the supine position, making transfer of the patient easy. Fluoroscopy is then used to locate the stone in 2 dimensions, anteroposteriorly and obliquely, to ensure that a clear shockwave path to the stone is seen, avoiding the

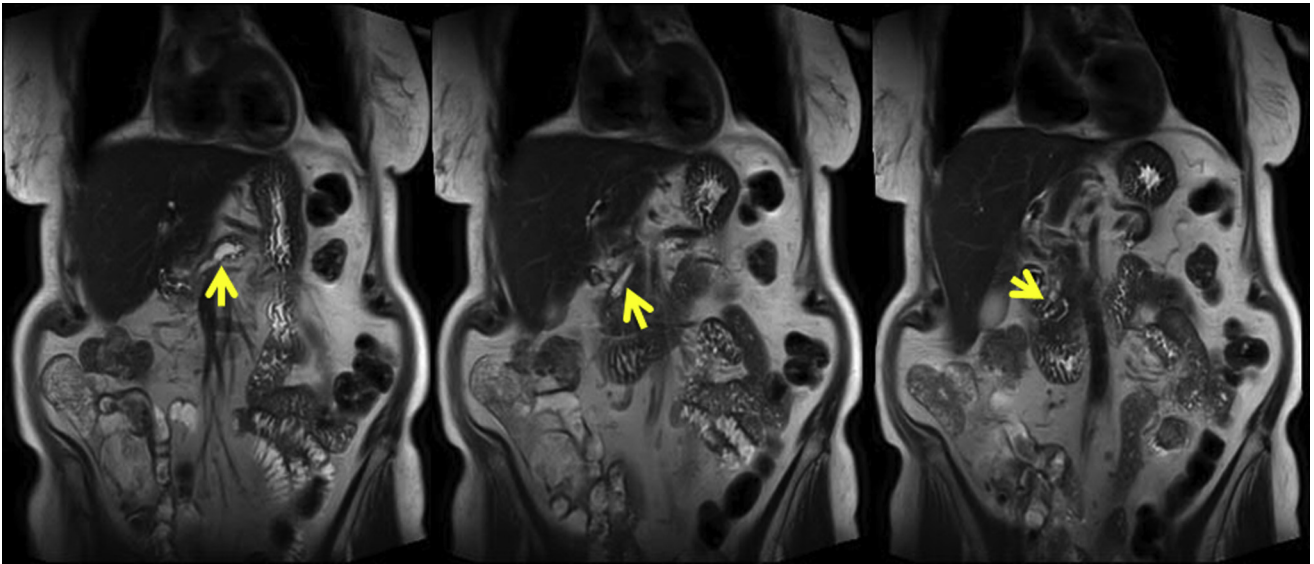


Figure 6. Repeat magnetic resonance imaging with MRCP after the third extracorporeal shockwave lithotripsy treatment demonstrated decreased pancreatic stone burden and decreased main duct dilation.

spine and other bony structures to reduce the risk of tissue injury. Once the stone is visualized well, an acoustic transmission gel is applied to the patient's abdomen and the therapy head cushion, and the cushion is inflated. This contact between the cushion and gel is imperative to effectively deliver shockwaves to the patient.

Older models of lithotripters use basins of water, whereas newer models now allow for dry contact shockwave lithotripsy. Up to 5000 shockwaves are delivered at a rate of 90 shockwaves per minute. Every 500 shockwaves, we assess the morphology of the stone on fluoroscopy. Several observations may be made, including increased surface area of the stone and tapering of the stone toward the ampulla, both of which are suggestive of stone fragmentation.

Although there are no established guideline recommendations on energy level, we never exceed 0.62 mJ/mm^2 because of a potential risk of inducing trauma to the pancreas and small intestine. One treatment session lasts approximately 60 minutes. Repeat ESWL may be needed if stones have incompletely disintegrated; a maximum of 5000 shockwaves is usually delivered per session.¹ Risks of ESWL are low, and the majority of adverse events are related to ERCP. Mild adverse events include skin erythema and petechiae. Moderate-to-severe adverse events include abdominal pain, bleeding, pancreatitis, perforation, infection, and acute stone incarceration in the papilla.

Upon completion of lithotripsy, the lithotripter unit is moved out of the room and the patient is transferred from the lithotripter table to the fluoroscopy table for ERCP. Diagnostic EGD is performed to assess for any mucosal trauma. Often, one can see stone fragments emanating from the papilla, suggestive of successful frag-

mentation of the stone (Fig. 5). The endoscopist can then proceed with accessing the PD, performing sphincterotomy, removing stone fragments, and placing a stent in the PD. Given the stone burden and significant manipulation of the PD, we prefer to leave the internal flaps of the plastic stent intact to provide prolonged drainage assistance.

The patient presented in this case had an uneventful overnight hospital observation after the procedure, without abdominal pain. She required a total of 3 sessions of ESWL-ERCP to adequately fragment the PD stone and access the dorsal PD. Access to the minor papilla was also aided by needle-knife papillotomy. Repeat magnetic resonance imaging with MRCP performed 6 weeks after the third session of ESWL demonstrated decreased pancreatic stone burden and decreased main duct dilation after ESWL, sphincterotomy, and stent placement (Fig. 6). The patient returned for a repeat ERCP to remove the stent and additional stone fragments. She remains asymptomatic and has done very well after treatment, with stabilization of her weight.

In conclusion, single-anesthesia, combined ESWL-ERCP within the endoscopy suite is feasible. Several important questions remain with this practice. First, it is unknown whether patients should undergo ESWL alone or ESWL combined with ERCP. Some patients may be suitable for only ESWL and achieve passive clearance of the pancreatic calculi fragments, whereas some patients may require combined ESWL and ERCP. The risks of ERCP are not to be taken lightly, so patient selection is imperative. Second, although endoscopic treatment is considered first-line therapy for PD stones, emerging data support going straight to a definitive pancreatic operation in certain patients. Definitive clinical guidelines are still being defined.

Despite these uncertainties, the role of ESWL in the management of patients with chronic pancreatitis is evolving. With good communication and coordination among nurses, technicians, the endoscopist, and the anesthesia team, ESWL-ERCP can safely, efficiently, and successfully be performed within the endoscopy suite.

ACKNOWLEDGMENT

Supported by a Robert W. Summers grant from the American Society for Gastrointestinal Endoscopy.

DISCLOSURE

Dr Gomez is a consultant for Olympus Corporation of the Americas. All other authors disclosed no financial relationships.

Abbreviations: ESWL, extracorporeal shockwave lithotripsy; PD, pancreatic duct.

REFERENCES

1. Dumonceau JM, Delhaye M, Tringali A, et al. Endoscopic treatment of chronic pancreatitis: European Society of Gastrointestinal Endoscopy (ESGE) Clinical Guideline. *Endoscopy* 2019;51:179-93.
2. Suzuki Y, Sugiyama M, Inui K, et al. Management for pancreatolithiasis: a Japanese multicenter study. *Pancreas* 2013;42:584-8.
3. Tandan M, Reddy DN. Extracorporeal shock wave lithotripsy for pancreatic and large common bile duct stones. *World J Gastroenterol* 2011;17:4365-71.
4. Farnbacher MJ, Schoen C, Rabenstein T, et al. Pancreatic duct stones in chronic pancreatitis: criteria for treatment intensity and success. *Gastrointest Endosc* 2002;56:501-6.

Mayo Clinic, Jacksonville, Florida.

If you would like to chat with an author of this article, you may contact Dr Patel at Patel.Sheetal@Mayo.edu.

Copyright © 2020 American Society for Gastrointestinal Endoscopy. Published by Elsevier Inc. This is an open access article under the CC BY-NC-ND license (<http://creativecommons.org/licenses/by-nc-nd/4.0/>).

<https://doi.org/10.1016/j.vgie.2020.06.009>

Endoscopedia

Endoscopedia has a new look! Check out the redesign of the official blog of *GIE* and *VideoGIE*. Keep up with the latest news and article discussions and post your comments or questions to *VideoGIE* authors. Visit us at www.endoscopedia.com.