



Serratus anterior dysfunction examination: wall push-up or shoulder flexion resistance test?

Ryan Lohre, MD, FRCSC*, Bassem Elhassan, MD

Department of Orthopaedic Surgery, Harvard Medical School, Massachusetts General Hospital, Boston Shoulder Institute, Boston, MA, USA

ARTICLE INFO

Keywords:

Scapula
Scapulothoracic abnormal motion
Physical examination
Winging
Serratus anterior
Scapulopecty

Level of evidence: Level IV; Case series

Background: Wall push-up is the most common examination used for the diagnosis of scapular winging secondary to serratus anterior dysfunction. The wall push-up test (WPUT) however may not be able to differentiate causes of scapulothoracic abnormal motion (STAM) or winging. We introduce a novel physical examination maneuver, the shoulder flexion resistance test (SFRT), and we propose that this test is more specific and accurate in determining serratus anterior dysfunction as the cause of STAM.

Methods: Fifty patients with STAM are included in this study. All patients underwent clinical scapular examination using both WPUT and SFRT. The SFRT is performed by resisting shoulder flexion while the elbow is fully extended at 30°, 60°, and 100°. All patients additionally received preoperative electromyography. All patients underwent exploration and intraoperative stimulation of the distal serratus anterior to characterize color, thickness, and contractility at the time of their arthroscopic pectoralis minor release and scapulopecty or tendon transfer if the serratus was paralyzed. The preoperative clinical examination findings were then correlated with intraoperative findings.

Results: Abnormal distal serratus anterior was seen intraoperatively in 5/50 patients (10%) with marked alterations in color, thickness, and contractility. All (n = 50) patients had positive WPUT manifested by increased winging of the scapula off the chest wall (STAM) with 45 false positive tests. The WPUT was 100% (95% confidence interval [CI] 47.82%-100%) sensitive but 0% (95% CI 0%-7.87%) specific for lower serratus anterior deficiency. The SFRT was 100% sensitive (95% CI 47.82%-100%) and 100% specific (95% CI 92.13%-100%) for serratus anterior dysfunction as the cause of STAM. Using area under the curve (AUC) of receiver operating characteristic (ROC) curves for WPUT and SFRT tests, WPUT had clinically insignificant accuracy (AUC 0.5) compared to the excellent accuracy (AUC 1.0) of SFRT.

Conclusion: SFRT is specific and accurate in determining serratus anterior dysfunction as a cause of STAM. Based on this study, the SFRT should replace the WPUT as the physical exam of choice to determine dysfunction of the serratus anterior muscle and guide operative management of STAM.

© 2022 The Authors. Published by Elsevier Inc. on behalf of American Shoulder and Elbow Surgeons. This is an open access article under the CC BY-NC-ND license (<http://creativecommons.org/licenses/by-nc-nd/4.0/>).

Scapulothoracic abnormal motion (STAM) defines alterations in dynamic scapular positioning secondary to muscular control of the scapulothoracic articulation.³⁶ Periscapular muscular discordance reduces or alters the normal multiplanar motion of the scapula and normal scapulohumeral coupling, thereby destabilizing the glenohumeral joint, reducing functional range of motion and power of the arm, and contributing to painful impingement and dynamic nerve compressions.^{1,3,8,15,16,24,32,38} The scapula should be stable on the chest wall, and the distal aspect of the scapula should translate

anteriorly (protract) on the chest wall and externally rotate sufficiently to allow acromial elevation and prevent glenohumeral impingement during normal glenohumeral elevation.^{8,14,22,27} The net effect of pectoralis minor and serratus anterior dysfunction can alter this normal motion to produce STAM, with prominence of the medial scapular border at rest or through arc of motion. This has classically been referred to as scapular winging.^{14,18,22,33,39}

Examination for STAM involves both static and dynamic physical examinations with varying reliability, validity, and diagnostic capacity evidenced through systematic reviews and consensus statements. Reported examinations include scapular protraction against resistance, scapular assistance and compression tests, dynamic scapular dyskinesia tests (SDTs), and manual muscle testing, including stressing or fatiguing the serratus anterior through wall push-ups.^{12,25,26} The wall push-up test (WPUT) biomechanically

This work received institutional review board approval through the Mass General Brigham IRB (Protocol #2021P002544).

*Corresponding author: Ryan Lohre, MD, FRCSC, 55 Fruit Street, Suite 3200, Boston, MA 02114, USA

E-mail address: rlohre@mg.harvard.edu (R. Lohre).

<https://doi.org/10.1016/j.jseint.2022.05.002>

2666-6383/© 2022 The Authors. Published by Elsevier Inc. on behalf of American Shoulder and Elbow Surgeons. This is an open access article under the CC BY-NC-ND license (<http://creativecommons.org/licenses/by-nc-nd/4.0/>).

does not consider the entire dynamic scapular musculature as contributing to STAM. The WPUT examines the scapula in 2 planes of motion, scapular translation and external rotation, and does not account for tilt and combined motion in 3 planes by the effects of abnormal sequence of pectoralis minor and serratus anterior muscle activation around the scapula.^{20,21} Current scapular physical examination including the WPUT may be unreliable in discerning serratus anterior function and thus appropriate surgical management.

We propose a novel examination technique in conjunction with other focused scapular examination maneuvers to assess patients with clinically evident STAM to discern its etiology. The examination maneuver is termed the shoulder flexion resistance (SFRT) test and is performed by positioning the shoulder passively at 30, 60, and 100 degrees relative to the horizontal and then applying resistance on the forearm with the elbow in full extension. A positive SFRT at each degree interval is determined by the presence of STAM, whereas a negative examination does not produce STAM. The intervals are chosen to differentiate muscular contribution to STAM, namely, pectoralis minor hyperactivity, distal serratus anterior paralysis or hypoactivation, or a combination of these. Pectoralis minor exhibits forces on the scapula causing downward scapular rotation, internal rotation, anterior tilt, and protraction because of the line of pull (attachment on ribs 3-5 and predominant insertion on the medial coracoid).^{7,31,40} The serratus anterior comprises 3 muscular slips of superior, middle, and distal serratus.⁷ The distal serratus anterior originates from ribs 5-9 and inserts on the anteromedial aspect of the inferomedial scapular border. The distal serratus anterior is the most important part of the serratus contributing to scapular stabilization and mobility and thus, if deficient, produces STAM and visualized winging.⁷ At 100 degrees of shoulder elevation, the pectoralis minor excursion is minimized and will not contribute to STAM, effectively isolating the contribution of the distal serratus anterior to produce scapular winging^{2,4,5} (Fig. 1). Between 30 and 60 degrees of elevation, both the pectoralis minor and lower serratus are active, and serratus deficiency or pectoralis minor hyperactivity will present as STAM or winging.^{4,5} Combining resisted forward elevation at these intervals theoretically allows the clinician to differentiate true serratus anterior palsy vs. discordant periscapular muscle activity as the cause of STAM (winging) and pathology⁵ (Fig. 2). The SFRT considers scapular tilt, translation, and rotational effects by assessing serratus anterior dysfunction and offers clinicians a novel assessment that directly changes surgical management options.

Our hypothesis is that the SFRT is an accurate test to determine serratus anterior dysfunction as a cause of STAM. Our primary objective is to determine the sensitivity, specificity, and test accuracy of the SFRT compared with the WPUT for patients presenting with STAM. Our secondary objective is to determine the accuracy of electromyography (EMG) testing in the diagnosis of STAM.

Materials and methods

Demographics and inclusion

Patients diagnosed with STAM and consecutively receiving surgical intervention by the senior author (B.E.) were included for this study. Institutional review board and ethical review board approval were obtained from 3 different institutions where the patients were seen, examined, and operated on.

Patients with symptomatic STAM were clinically evaluated by the senior author (B.E.) before surgery using both the WPUT and shoulder flexion resistance test (SFRT).⁷

Our examination of the shoulder and scapula for STAM

Following a focused history, patients are examined in a well-lit room with appropriate gowning to assure visualization of the neck, back, scapula, and arms. We begin with general inspection, looking for notable cervical spine deformity (lordosis) or torticollis, thoracic kyphosis, and overall stance of the shoulders and scapula. Focused shoulder examination is conducted, followed by scapular examination and special tests.

Shoulder examination

Both active and passive range of motion of the shoulder is performed, looking for deficiencies, which are seen in forward elevation and abduction. If there is concern for additional shoulder pathology including stiffness, additional physical examination is performed as indicated. Neurologic and vascular examinations of the limb are performed with testing of peripheral nerves and nerve roots if there are noted deficiencies.

Scapular examination

The periscapular and shoulder musculature is examined for evidence of wasting in keeping with neurogenic pathology or trauma. At rest, the scapula may be positioned laterally and inferiorly, appearing as a drooped shoulder in cases of trapezial palsy, or with posterior translation of the medial scapular border and rotation of the inferior scapular pole in cases of serratus anterior palsy. Next, periscapular musculature is tested, including upper and middle/lower trapezius (symmetric shoulder shrug, scapular retraction with shoulder flexion), levator scapula (tested with the hand behind the back and instruction to elevate the ipsilateral elbow), rhomboids major and minor (scapular retraction), serratus anterior, and pectoralis minor. Dynamic scapular testing including stabilization and assistance are performed. Stabilizing the scapula by compression against the chest wall can show improvement in range of motion. The scapular assistance test involves counteracting the posterior and medial translation of the medial border and internal rotation of the inferior scapular border using the thumb and index fingers along the medial and lateral border of the inferior scapular pole.¹⁴ With the contralateral hand palpating the upper trapezius, the scapula can be assisted into correct motion. This test allows for dynamic control of the deformity through compression and scapular rotation. An improvement in active forward elevation and abduction is indicative of a positive test. Our serratus anterior examination begins with active forward elevation of the shoulder. STAM manifested with gross winging of the scapula of the chest wall may be indicative of a lower serratus anterior palsy. Our second examination that we perform to diagnose serratus dysfunction is active scapular protraction against resistance. This is performed by blocking the anterior shoulder (proximal humerus) with the palm of the examiner and then asking the patient to push horizontally against the examiner. The only muscle that protracts the distal tip of the scapula on the chest wall is the distal serratus anterior muscle.⁷ If the serratus anterior is weak or dysfunctional, then the distal tip of the scapula will retract and wing off the chest wall instead of appropriately protracting. We examine sequelae of pectoralis minor hyperactivity by looking for tenderness to palpation over its insertion on the medial coracoid, as well as reproducible neurologic phenomenon as a Tinel sign over the brachial plexus medial to the coracoid and deep to the pectoralis minor muscle.

If STAM is the result of pectoralis minor hyperactivity, then we must rule out the serratus as the reason for the STAM. To do this, we perform special tests, including the SFRT.

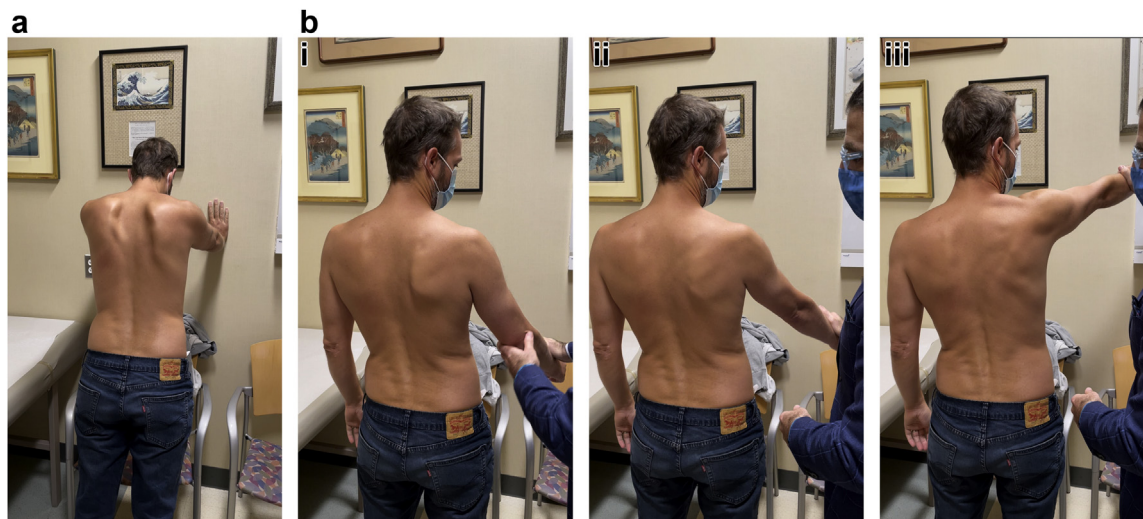

Figure 1 (a) The wall push-up test demonstrating STAM. (b) The shoulder flexion against resistance test (SFRT) performed at (b (i)) 30, (b (ii)) 60, and (b (iii)) 100 degrees showing STAM at 30 and 60 degrees with a negative (absent STAM) SFRT test at 100 degrees. STAM, scapulothoracic abnormal motion.

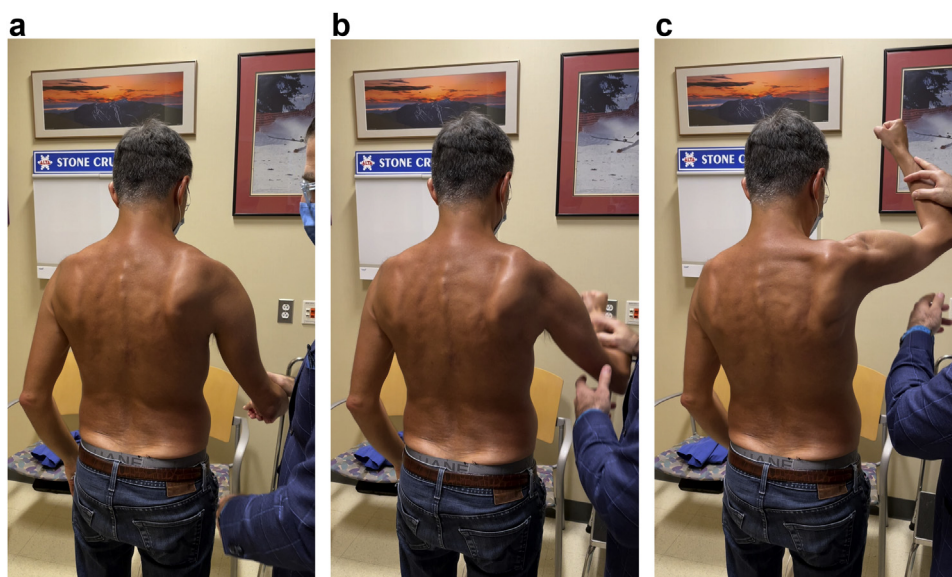


Figure 2 Shoulder flexion against resistance test (SFRT) positive at (a) 30, (b) 60, and (c) 100 degrees indicating distal serratus anterior weakness as a contributing cause of STAM. STAM, scapulothoracic abnormal motion.

Special tests of the serratus anterior

Wall push-up test

The WPUT was performed as previously described with patients facing a wall with shoulder forward elevation to horizontal, elbows in extension, and wrists in extension. With palms against the wall in this position, patients slowly bent their elbows, allowing their body weight to move closer to the wall and the position of their scapula was examined.^{12,37,39} The WPUT test was considered positive in the presence of winging of the scapula (STAM).

Shoulder flexion resistance test

Patients were also examined using the novel SFRT test. The SFRT is performed with the clinician standing and facing the patient’s posterolateral aspect of the affected extremity. The patients’ shoulder is positioned passively at 30, 60, and 100 degrees relative to the ground with the elbow extended and forearm in a neutral

rotation. At each noted degree interval, the patient is instructed to then actively resist a downward directed force by the clinician as a “break test.” The clinician carefully examines the position of the scapula on the chest wall, looking for translation, rotation, and elevation of the inferior scapular pole in keeping with a winged scapula (STAM).²³ A positive SFRT is defined as scapular winging with resisted forward elevation at 30, 60, or 100 degrees. A positive SFRT may be produced at each degree interval separately. A negative SFRT test produces no winging and may be produced at each degree interval (Fig. 1). In most instances, this test does not cause shoulder pain except if patients have shoulder pathology (Fig. 2).

Electromyography

All patients diagnosed with STAM were further evaluated with EMG testing for long thoracic nerve injury before surgery.

Table 1
Demographic data, physical examination, and diagnostic testing results.

Variable	Cumulative	Normal intraoperative serratus anterior	Abnormal intraoperative serratus anterior	P value
Age	Mean: 24.6 (SD 13.3) Median: 19 (range 14-63)	Mean: 21.0 (SD 7.9) Median: 19 (range 14-44)	Mean: 57 (SD 4.5) Median: 57 (range 51-63)	<.001
Gender	Male: 9 Female: 41	Male: 5 Female: 40	Male: 4 Female: 1	.025
EMG	Positive: 36 Negative: 14	Positive: 31 Negative: 14	Positive: 5 Negative: 0	-
WPUT	Positive: 50 Negative: 0	Positive: 45 Negative: 0	Positive: 5 Negative: 0	-
SFRT 30	Positive: 45 Negative: 5	Positive: 40 Negative: 5	Positive: 5 Negative: 0	-
SFRT 60	Positive: 41 Negative: 9	Positive: 36 Negative: 9	Positive: 5 Negative: 0	-
SFRT 100	Positive: 5 Negative: 45	Positive: 0 Negative: 45	Positive: 5 Negative: 0	-

EMG, electromyography; WPUT, wall push up test; SFRT, shoulder flexion against resistance test

Surgical procedure

All patients received surgical treatment for STAM with either arthroscopic pectoralis minor release and open scapulopexy or pectoralis major transfer.^{9,10,13} Both procedures were performed in the lateral decubitus position, with the operative arm free-draped and without traction. The pectoralis minor release was performed using a 30-degree arthroscope and a 2 or 3 portal technique with radiofrequency ablation. The scapulopexy was performed via an open approach to the inferomedial border of the scapula with tethering of the inferior scapular pole to a rib using tibialis posterior allograft.⁹ At this time, lower serratus anterior evaluation was performed with attention to color, contractility, and consistency. Muscular stimulation was performed using the Checkpoint Nerve Stimulator (Checkpoint Surgical, OH, USA). The device was used to determine muscle excitability by amplitude and pulse duration of 0.5 mA and 200 μs, with concerted, continuous contraction of the entire muscle group denoting a normal response. Atrophic, scarred, blanched or thin, noncontractile musculature was considered abnormal. Five patients underwent transfer of the sternal head of the pectoralis major muscle with its bony insertion to the distal corner of the scapula for abnormal distal serratus musculature.¹⁰

Statistical analysis

Data are presented as median and range for demographic data as well as mean and standard deviation. Sample size for study was determined considering a single diagnostic test with alpha 0.05, 80% power (beta 0.2), and an area under the curve (AUC) cutoff of 0.7 and allocation ratio of 1. The appropriate sample size considering a case-control format in this instance would be 48 patients. Diagnostic testing parameters, including sensitivity, specificity, likelihood ratios (LRs), predictive values, and disease prevalence were determined, using 2 × 2 tables with 95% confidence intervals (95% CIs). The diagnostic accuracy for each test was examined using receiver operating characteristic (ROC) curves and the AUC. AUC values were presented with 95% CI and P values for significance testing. Significance was considered at P < .05. AUC was described as “excellent” (≥0.9), “good” (≥0.8), “fair” (≥0.70), and “poor” (<0.70) as previously described for biomedical research.³⁵ Data were tested for normality and comparative statistics produced using Mann-Whitney U testing with significance considered P < .05. Statistical testing was performed using R (R Foundation for Statistical Computing, Vienna, Austria).

Results

Fifty patients with diagnosis of STAM were included in the study. There were 41 women (82%) and 9 men (18%) evaluated. The median age was 19 years (range 14-63 years), with a mean age of 24.6 years (SD 13.3). EMG studies were collected in all patients to assess long thoracic nerve function. EMG results indicated 36 long thoracic nerve (LTN) derangements (80%) and 14 negative (20%) results. Table 1 provides demographic data and physical examination results.

The WPUT was positive in all (n = 50, 100%) recruited patients. The SFRT was positive in 45 (90%) of patients at 30 degrees and negative in 5 (10%). There were 3 patients with a negative SFRT at 30 degrees with concordant negative EMG results and 2 patients with positive EMG results. Four of these patients were female and 1 male. SFRT testing at 60 degrees had 41 positive examination findings (82%) and 9 (8%) negative testing. All patients testing SFRT negative at 60 degrees were female. Forty-five patients (n = 45/50; 90%) had a negative SFRT test at 100 degrees. Gender distribution was 5 male (n = 5/45; 11%) and 40 female (n = 40/45; 89%). EMG testing was negative for LTN neuropathy in 13 (n = 13/14; 93%) patients with negative SFRT at 100 degrees.

Intraoperative findings suggested normal lower serratus anterior color, consistency, and contractility with muscular stimulation in (n = 45; 90%) patients and abnormal results in n = 5 (10%). The disease prevalence of true lower serratus anterior palsy producing STAM was therefore 10% (n = 5/50). Patients with a normal lower serratus anterior received arthroscopic pectoralis minor release and scapulopexy (n = 45), whereas patients with abnormal, paralytic lower serratus anterior received a pectoralis major transfer (n = 5). All patients with abnormal lower serratus anterior musculature demonstrated abnormalities in all finding categories (color, consistency, and contractility). The SFRT was positive at 30, 60, and 100 degrees for all patients (n = 5) with intraoperative findings of true serratus anterior pathology. EMG testing similarly was positive for LTN neuropathy in all 5 patients with intraoperative findings of true serratus anterior palsy. The mean age was 57 years (SD 4.5; median 57, range 51-63 years). Patients with intraoperative findings of true serratus anterior deficiency were older (P < .001) and more predominantly male (P = .025) than those with normal intraoperative findings and absence of visual serratus anterior pathology.

Sensitivity, specificity, LRs, positive predictive value (PPV), and accuracy of testing were produced for WPUT and SFRT at 30, 60, and 100 degrees in relation to lower serratus anterior deficiency as a cause of scapular winging. Sensitivity and specificity for SFRT at each

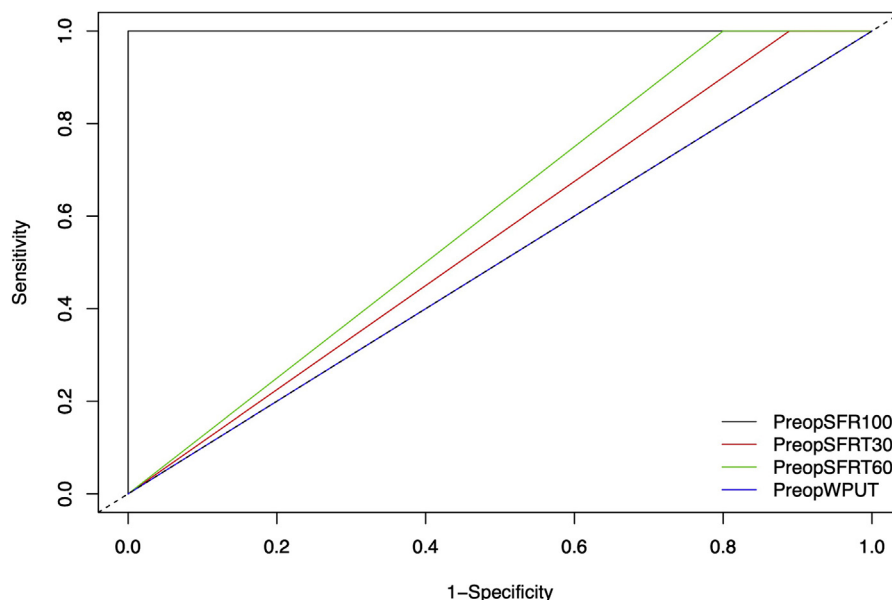


Figure 3 An ROC curve was produced for WPUT and the SFRT at 30, 60, and 100 degrees. The SFRT at 100 degrees showed an AUC of 1.0 in our patient cohort. ROC, receiver operating characteristic; WPUT, wall push up test; SFRT, shoulder flexion against resistance test; AUC, area under the curve.

of 30, 60, and 100 degrees were produced as well as combined SFRT and WPUT. The WPUT was seen to be 100% sensitive (95% CI 88.78%–100%) with 0% (95% CI 0%–7.87%) specificity. The PPV of the WPUT alone was 10%. The SFRT was 100% (95% CI 47.82%–100%) sensitive at each interval of 30, 60, and 100 degrees. The specificity of the SFRT varied by degree of SFRT testing, showing 11.11% (95% CI 3.71%–24.05%) at 30 degrees, 20.0% (95% CI 9.58%–34.60%) at 60 degrees, and 100% (95% CI 92.13%–100%) at 100 degrees. Combined SFRT testing at 30, 60, and 100 degrees showed both sensitivity and specificity of 100%. Positive LR for SFRT at 30 and 60 degrees was 1.12 (95% CI 1.01–1.25) and 1.25 (95% CI 1.08–1.45), respectively. The diagnostic accuracy of each test was examined using ROC curves with AUC. The AUC of WPUT was 0.5. The AUC and diagnostic accuracy of SFRT was 0.55 (95% CI 0.51–0.61; $P = .02$) at 30 degrees, 0.60 (95% CI 0.54–0.66; $P = .001$) at 60 degrees, and 1.0 at 100 degrees. **Figure 3** provides the ROC curve for the WPUT and SFRT. Adding WPUT to SFRT testing did not improve diagnostic sensitivity, specificity, or accuracy of lower serratus anterior dysfunction as a cause of STAM. The results are shown in **Table II**. EMG testing had a 100% (95% CI 48.82%–100%) sensitivity, 31.1% (95% CI 18.17%–46.65%) specificity, positive LR of 1.45 (95% CI 1.19–1.77), a PPV of 13.9% (11.70%–16.41%), and a negative predictive value (NPV) of 100%.

Discussion

Our study has shown that novel SFRT testing at 30, 60, and 100 degrees is highly sensitive, specific, and accurate for evaluating patients with STAM for lower serratus anterior dysfunction when compared with WPUT alone. In our cohort study, 100% of patients screened positive for scapular winging using WPUT. WPUT produced a high false negative rate ($n = 45/50$; 90%) when considering intraoperative findings of true serratus anterior deficiency. The addition of WPUT to the SFRT testing did not increase the sensitivity, specificity, or diagnostic accuracy of true serratus anterior deficiency as a cause of STAM with scapular winging. In contrast, the SFRT was able to both diagnose STAM with scapular winging and determine the muscle deficiency or hyperactivity causing the pathology. A negative SFRT at 30, 60, and 100 degrees provides evidence of pectoralis minor hyperactivity as the cause of STAM, whereas a positive test at 30, 60, and 100 degrees confirms serratus

anterior dysfunction as the cause. In actuality, this scapular abnormal motion is a result of the decoupling of the muscular pull of both the serratus anterior and the pectoralis minor. With STAM because of this muscular discord, the pectoralis minor anteriorly tilts the scapula, rotates internally in the axial plane, and prevents the serratus anterior from externally rotating, translating, and preventing the medial scapular border from rotating posteriorly away from the hemithorax. Our study showed true serratus anterior dysfunction in 5 patients and produced positive SFRT tests at 30, 60, and 100 degrees. These patients also demonstrated abnormal EMG findings. A negative SFRT at 100 degrees seen in 45 patients with normal intraoperative serratus anterior muscle testing provides a specificity of 100%, and effectively can rule out isolated serratus anterior pathology as a cause of STAM (scapular winging). Therefore, these 45 patients had developed symptomatic STAM through pectoralis minor hyperactivity, receiving an arthroscopic pectoralis minor release and scapulopexy. The SFRT test was also seen to have “excellent” accuracy of diagnosing serratus anterior dysfunction as a cause of STAM, with a negative SFRT producing an AUC of 1.0. In contrast, the WPUT had a “poor” and ineffectual accuracy shown by an AUC of 0.5. **Figure 4** provides a treatment algorithm based on SFRT examination and intraoperative findings of the serratus anterior.

Treatment modalities for STAM have largely focused on correcting the effects of serratus anterior palsy. Surgical options include microneurolysis of the long thoracic nerve, nerve transfer or grafting, pectoralis major and split pectoralis major transfers, scapulopexy without arthrodesis, or scapulothoracic fusion.^{10,11,19,28,29,36,37} Broadly, treatment categories include nerve repair or reconstruction, muscle transfer, or fusion. Appropriately indicated surgical treatment is hinged on accurate diagnosis. Perhaps the best discussion of this comes from Warner and Navarro’s analysis of 8 patients with symptomatic STAM.³⁷ They caution surgeons to use collective history, physical examination, and adjunctive diagnostic modalities such as EMG to discern the true cause of STAM. Five patients before referral had initially received incorrect diagnoses, resulting in a total of 17 contraindicated and ineffectual procedures at reducing STAM, pain, or dysfunction. The diagnostic accuracy of EMG alone did not suffice in determining the cause, as only 5 of 8 patients had LTN palsy

Table II
Sensitivity, specificity, likelihood ratios, PPV, NPV, and accuracy (AUC) for WPUT and SFRT examination at 30, 60, and 100 degrees considering abnormal intraoperative findings for serratus anterior deficiency.

Test	Sensitivity (95% CI)	Specificity (95% CI)	Positive likelihood ratio (95% CI)	PPV (95% CI)	NPV (95% CI)	Accuracy (AUC)
WPUT	100% (88.78%-100%)	0% (0%-7.87%)	1.0	10%	-	0.50
SFRT 30	100% (47.82%-100%)	11.11% (3.71%-24.05%)	1.12 (1.01-1.25)	11.11% (10.13%-12.17%)	100%	0.55 (0.51%-0.61)
SFRT 60	100% (47.82%-100%)	20.0% (9.58%-34.60%)	1.25 (1.08-1.45)	12.2% (10.72%-13.85%)	100%	0.60 (0.54-0.66)
SFRT 100	100% (47.82%-100%)	100% (92.13%-100%)	-	100%	100%	1.0
SFRT Combined	100%	100%	-	100%	100%	1.0
SFRT + WPUT	100%	100%	-	100%	100%	1.0

PPV, positive predictive value; NPV, negative predictive value; AUC, area under the curve; CI, confidence interval; WPUT, wall push up test; SFRT, shoulder flexion against resistance test.

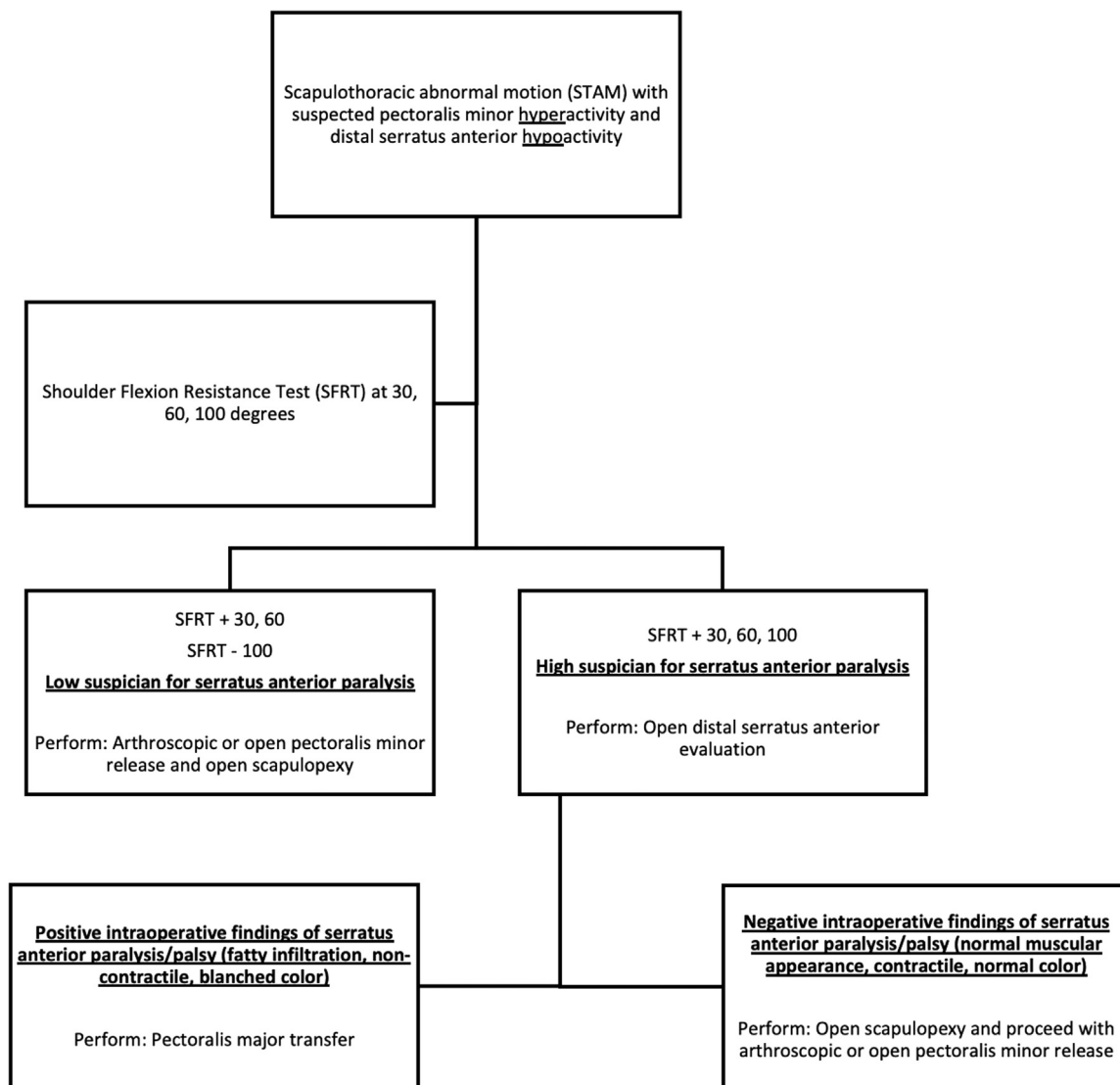


Figure 4 A treatment algorithm for the management of STAM based on physical examination and intraoperative findings. A positive SFRT at 100 degrees produces a high suspicion for a paralytic and deficient serratus anterior, warranting evaluation for possible pectoralis major transfer. STAM, scapulothoracic abnormal motion; SFRT, shoulder flexion against resistance test.

described by EMG. All patients in their series received a split pectoralis major transfer, with 7 patients having resolution of STAM and improved measurable function.³⁷

Our series of 50 consecutive patients with STAM receiving surgical treatment shows a high false positive rate of EMG testing when considering clinical evaluation for serratus anterior deficiency (n = 36/50; 72%), although the test was highly sensitive with

a negative predictive value of 100%. Pairing physical examination using WPUT with adjunctive investigation using EMG in patients with STAM based on our cohort would be inaccurate and nonspecific for serratus anterior deficiency. This traditional patient work-up would provide a high false positive rate of serratus anterior deficiency, potentially leading to contraindicated surgery. In contrast, the use of SFRT and EMG testing preoperatively provides a

highly sensitive, specific, and accurate diagnostic algorithm to discern true serratus anterior deficiency. It is possible that patients with this deficiency would benefit more from tendon transfers such as split pectoralis major tendon transfer. In contrast, patients with STAM due to muscle imbalance and pectoralis minor hypertrophy may benefit more from pectoralis minor release and scapulopecty. Leechavengvongs et al showed in a small series of 8 patients with brachial plexus injury that scapulopecty with suture tape improved flexion and abduction and University of California at Los Angeles Shoulder Scores scores and reduced VAS pain scores at 2-year follow-up.¹⁹ Elhassan et al recently reported on 23-month follow-up of 31 patients receiving arthroscopic pectoralis minor release and scapulopecty for STAM in the absence of nerve palsy.⁹ Eighty-one percent demonstrated improved VAS pain, Constant, SSV scores, as well as range of motion and improvements in subjective posterior instability. The authors highlight that patients may present with functional causes of STAM, including pectoralis minor hyperactivity and distal serratus hypoactivity outside of nerve palsy. Careful evaluation using physical examination maneuvers such as the SFRT is important to delineate the etiology of STAM for appropriate treatment. Ongoing study is required to validate these promising procedures as an acceptable treatment for STAM.¹⁹

The strengths of our study include an appropriately sized and powered sample, clear definitions of serratus anterior deficiency with intraoperative evaluation, and an easy-to-administer, reproducible clinical examination. The limitations of this study include the use of a single examiner and lack of reliability measurement. A multicenter study of all consecutive patients presenting with symptomatic STAM for evaluation and treatment would provide a higher level of evidence than our current cohort study. Our sample size calculation was produced based on determination of AUC using ROC curves. Our recruited sample size demonstrated both a statistically and clinically significant differentiator between these physical examination tests and therefore minimizes type 1 error. Given that the WPUT was globally positive, fatigability and repetition of the examination were not necessary to appropriately administer the examination. Similarly, the SFRT does not require repeated fatigability testing to delineate serratus anterior dysfunction as a cause of STAM. The handheld nerve stimulator used to assess the contractility of the serratus anterior muscle has been previously validated in the assessment of nerves during thyroid surgery.¹⁷ Although quality and contractility were able to be determined; ultimately, muscle power, force, and contractile kinetics are not able to be recorded in vivo with our method, and discrepancies may in fact be present. Patients included were significantly symptomatic to receive treatment and may not represent the general population of patients with STAM, as this may be seen as a normal physiological variant in certain groups. Our population showed significantly more females than males. Varying evidence is present on the sex distribution of STAM, with some studies showing a higher rate and predisposition to females.^{9,30} Our study population showed a discrepancy in diagnosis and treatment by age, with older patients having a serratus anterior palsy requiring pectoralis major transfer compared with younger patients. Previous studies have shown similar age ranges for patients with serratus anterior palsy.^{6,10,34} Future study using multiple, blinded examiners to determine the rater reliability may provide further evidence for the use of this examination. We did not include clinical outcome of the surgical procedures received, as this is not a clinical outcome study, and our focus was on differentiating the cause of STAM through physical examination.

Many clinicians are familiar with literature describing medial scapular winging and scapular dyskinesia, both of which rely on more restrictive diagnoses and considers the serratus anterior as globally dysfunctional. Our updated STAM terminology and

examination asks the clinician to consider muscular imbalances as a cause of STAM (previously termed winging), including pectoralis minor contribution, rather than classic serratus palsy alone. Awareness by orthopedic surgeons to the differentiating causes of scapular pain and STAM, coupled with an improved and highly accurate physical examination, can lead to improved patient care. Morbidity from inappropriate or ineffectual management of STAM can be mitigated with appropriate diagnostic testing and management options.

Conclusion

The SFRT is highly sensitive, specific, and accurate in diagnosing serratus anterior dysfunction as a cause of STAM. The wall push-up test is inaccurate and nonspecific in comparison and does not assist the surgeon in delineating the cause of STAM for appropriate directive treatment. Based on our study, we recommend that the SFRT should replace the WPUT as the physical examination of choice in patients presenting with STAM.

Disclaimers:

Funding: No funding was disclosed by the authors.
Conflicts of interest: The authors, their immediate families, and any research foundation with which they are affiliated have not received any financial payments or other benefits from any commercial entity related to the subject of this article.

References

1. Bagg SD, Forrest WJ. Electromyographic study of the scapular rotators during arm abduction in the scapular plane. *Am J Phys Med* 1986;65:111-24.
2. Borstad JD, Ludewig PM. The effect of long versus short pectoralis minor resting length on scapular kinematics in healthy individuals. *J Orthop Sports Phys Ther* 2005;35:227-38. <https://doi.org/10.2519/jospt.2005.35.4.227>.
3. Burkhart SS, Morgan CD, Kibler W Ben. The disabled throwing shoulder: spectrum of pathology Part III: the SICK scapula, scapular dyskinesis, the kinetic chain, and rehabilitation. *Arthroscopy* 2003;19:641-61. <https://doi.org/10.1016/j.arthro.2003.03.00389-x>.
4. Castelein B, Cagnie B, Parlevliet T, Cools A. Serratus anterior or pectoralis minor: which muscle has the upper hand during protraction exercises? *Man Ther* 2016;22:158-64. <https://doi.org/10.1016/j.math.2015.12.002>.
5. Castelein B, Cagnie B, Parlevliet T, Danneels L, Cools A. Optimal Normalization tests for muscle activation of the levator Scapulae, pectoralis minor, and rhomboid major: an electromyography study using maximum Voluntary Isometric contractions. *Arch Phys Med Rehabil* 2015;96:1820-7. <https://doi.org/10.1016/j.apmr.2015.06.004>.
6. Chalmers PN, Saltzman BM, Feldheim TF, Mascarenhas R, Mellano C, Cole BJ, et al. A comprehensive analysis of pectoralis major transfer for long thoracic nerve palsy. *J Shoulder Elbow Surg* 2015;24:1028-35. <https://doi.org/10.1016/j.jse.2014.12.014>.
7. Crowe MM, Elhassan BT. Scapular and shoulder girdle muscular anatomy: its Role in periscapular tendon transfers. *J Hand Surg Am* 2016;41:306-14. <https://doi.org/10.1016/j.jhssa.2015.06.123>.
8. von Eisenhart-Rothe R, Matsen FA 3rd, Eckstein F, Vogl T, Graichen H. Pathomechanics in atraumatic shoulder instability: scapular positioning correlates with humeral head centering. *Clin Orthop Relat Res* 2005;429:82-9. <https://doi.org/10.1097/01.blo.0000150338.27113.14>.
9. Elhassan BT, Dang KH, Huynh TM, Harstad C, Best MJ. Outcome of arthroscopic pectoralis minor release and scapulopecty for the management of STAM (ScapuloThoracic abnormal motion). *J Shoulder Elbow Surg* 2021;31:1208-14. <https://doi.org/10.1016/j.jse.2021.10.046>.
10. Elhassan BT, Wagner ER. Outcome of transfer of the sternal head of the pectoralis major with its bone insertion to the scapula to manage scapular winging. *J Shoulder Elbow Surg* 2015;24:733-40. <https://doi.org/10.1016/j.jse.2014.08.022>.
11. Goel DP, Romanowski JR, Shi LL, Warner JJP. Scapulothoracic fusion: outcomes and complications. *J Shoulder Elbow Surg* 2014;23:542-7. <https://doi.org/10.1016/j.jse.2013.08.009>.
12. Gregg JR, Labosky D, Harty M, Lotke P, Ecker M, DiStefano V, et al. Serratus anterior paralysis in the young athlete. *J Bone Joint Surg Am* 1979;61(6A):825-32.
13. Hendrix ST, Hoyle M, Tokish JM. Arthroscopic pectoralis minor release. *Arthrosc Tech* 2018;7:e589-94. <https://doi.org/10.1016/j.eats.2018.02.003>.

14. Kibler W Ben, McMullen J. Scapular dyskinesis and its relation to shoulder pain. *J Am Acad Orthop Surg* 2003;11:142-51. <https://doi.org/10.5435/00124635-200303000-00008>.
15. Kibler W Ben, Kuhn JE, Wilk K, Sciascia A, Moore S, Laudner K, et al. The disabled throwing shoulder: spectrum of pathology-10-year update. *Arthroscopy* 2013;29:141-61. <https://doi.org/10.1016/j.arthro.2012.10.009>.
16. Kibler W, Sciascia A, Wilkes T. Scapular dyskinesis and its relation to shoulder injury. *J Am Acad Orthop Surg* 2012;20:364-72. <https://doi.org/10.5435/JAAOS-20-06-364>.
17. Lawson BR, Kamani D, Shama M, Kyriazidis N, Randolph GW. Safety and reliability of a handheld stimulator for neural monitoring during thyroid surgery. *Laryngoscope* 2020;130:561-5. <https://doi.org/10.1002/lary.28027>.
18. Lee S, Savin DD, Shah NR, Bronsnick D, Goldberg B. Scapular winging: evaluation and treatment: AAOS exhibit selection. *J Bone Joint Surg Am* 2015;97:1708-16. <https://doi.org/10.2106/JBJS.O.00727>.
19. Leechavengvongs S, Jiamton C, Uerpaiojkit C, Malungpaishorpe K, Wittoonchart K, Poonotoke P. Polyester tape scapulopexy for chronic upper extremity brachial plexus injury. *J Hand Surg Am* 2015;40:1184-1189.e3. <https://doi.org/10.1016/j.jhssa.2015.01.038>.
20. Ludewig PM, Hoff MS, Osowski EE, Meschke SA, Rundquist PJ. Relative Balance of serratus anterior and upper trapezius muscle activity during push-up exercises. *Am J Sports Med* 2004;32:484-93. <https://doi.org/10.1177/0363546503258911>.
21. Lunden JB, Braman JP, LaPrade RF, Ludewig PM. Shoulder kinematics during the push-up Plus Exercise. *J Shoulder Elbow Surg* 2010;19:216-23. <https://doi.org/10.1016/j.jse.2009.06.003>.
22. Lukasiewicz AC, McClure P, Michener L, Pratt N, Sennett B. Comparison of 3-dimensional scapular position and orientation between subjects with and without shoulder impingement. *J Orthop Sports Phys Ther* 1999;29:574-6.
23. McClure P, Tate AR, Kareha S, Irwin D, Zlupko E. A clinical method for identifying scapular dyskinesis, part 1: Reliability. *J Athl Train* 2009;44:160-4. <https://doi.org/10.4085/1062-6050-44.2.160>.
24. McQuade KJ, Dawson J, Smidt GL. Scapulothoracic muscle fatigue associated with alterations in scapulohumeral rhythm kinematics during maximum resistive shoulder elevation. *J Orthop Sports Phys Ther* 1998;28:74-80.
25. Morais N, Cruz J. The pectoralis minor muscle and shoulder movement-related impairments and pain: Rationale, assessment and management. *Phys Ther Sport* 2016;17:1-13. <https://doi.org/10.1016/j.ptsp.2015.10.003>.
26. Moseley JBJ, Jobe FW, Pink M, Perry J, Tibone J. EMG analysis of the scapular muscles during a shoulder rehabilitation program. *Am J Sports Med* 1992;20:128-34.
27. Mueller AM, Entezari V, Rosso C, McKenzie B, Hasebrock A, Cereatti A, et al. The effect of simulated scapular winging on glenohumeral joint translations. *J Shoulder Elbow Surg* 2013;22:986-92. <https://doi.org/10.1016/j.jse.2012.09.010>.
28. Nath RK, Lyons AB, Bietz G. Microneurolysis and decompression of long thoracic nerve injury are effective in reversing scapular winging: long-term results in 50 cases. *BMC Musculoskelet Disord* 2007;8:25. <https://doi.org/10.1186/1471-2474-8-25>.
29. Novak CB, Mackinnon SE. Surgical treatment of a long thoracic nerve palsy. *Ann Thorac Surg* 2002;73:1643-5. [https://doi.org/10.1016/s0003-4975\(01\)03372-0](https://doi.org/10.1016/s0003-4975(01)03372-0).
30. Picco BR, Vidt ME, Dickerson CR. Scapular kinematics by sex across elevation planes. *J Appl Biomech* 2018;34:141-50. <https://doi.org/10.1123/jab.2017-0082>.
31. Provencher MT, Kirby H, McDonald LS, Golijanin P, Gross D, Campbell KJ, et al. Surgical release of the pectoralis minor tendon for scapular dyskinesia and shoulder pain. *Am J Sports Med* 2017;45:173-8. <https://doi.org/10.1177/0363546516664720>.
32. Speer K, Garrett WJ. Muscular control of motion and stability about the pectoral girdle. In: Matsen FI, Fu F, Hawkins R, editors. *The shoulder: A Balance of mobility and stability*. Rosemont, IL: American Academy of Orthopaedic Surgeons; 1993. p. 159-72. ISBN: 978-0892030910.
33. Sriksunaran U, Wells JH, Freehill MT, Tan EW, Higgins LD, Warner JJP, et al. Scapular Winging: a great masquerader of shoulder disorders: AAOS exhibit selection. *J Bone Joint Surg Am* 2014;96:1-13. <https://doi.org/10.2106/JBJS.M.01031>.
34. Streit JJ, Lenarz CJ, Shishani Y, McCrum C, Wanner JP, Nowinski RJ, et al. Pectoralis major tendon transfer for the treatment of scapular winging due to long thoracic nerve palsy. *J Shoulder Elbow Surg* 2012;21:685-90. <https://doi.org/10.1016/j.jse.2011.03.025>.
35. Swets JA, Dawes RM, Monahan J. Psychological Science can improve diagnostic Decisions. *Psychol Sci Public Interest* 2000;1:1-26.
36. Tomaino MM. Neurophysiologic and clinical outcome following medial pectoral to long thoracic nerve transfer for scapular winging: a case report. *Microsurgery* 2002;22:254-7. <https://doi.org/10.1002/micr.10046>.
37. Warner JJ, Navarro RA. Serratus anterior dysfunction. Recognition and treatment. *Clin Orthop Relat Res* 1998:139-48.
38. Warner JJP, Micheli LJ, Arslanian LE, Kennedy J, Kennedy R. Scapulothoracic motion in normal shoulders and shoulders with glenohumeral instability and impingement syndrome: a study using Moire topographic analysis. *Clin Orthop Relat Res* 1992:191-9.
39. Wiater JM, Flatow EL. Long thoracic nerve injury. *Clin Orthop Relat Res* 1999:17-27.
40. Yeşilyaprak SS, Yüksel E, Kalkan S. Influence of pectoralis minor and upper trapezius lengths on observable scapular dyskinesis. *Phys Ther Sport* 2016;19:7-13. <https://doi.org/10.1016/j.ptsp.2015.08.002>.