

Primary Effusion Lymphoma Presenting As Parapneumonic Pleural Effusion

Rahul Gujarathi ¹, Narsimha Candula ¹, Venu Chippa ², Meet Kadakia ³, Ahmad Alkhasawneh ⁴

Review began 06/26/2022

Review ended 07/06/2022

Published 07/12/2022

© Copyright 2022

Gujarathi et al. This is an open access article distributed under the terms of the Creative Commons Attribution License CC-BY 4.0., which permits unrestricted use, distribution, and reproduction in any medium, provided the original author and source are credited.

1. Hospital Medicine, University of Florida Health, Jacksonville, USA 2. internal Medicine, St Vincent Medical Center, Evansville, USA 3. Hematology/Oncology, University of Florida College of Medicine – Jacksonville, Jacksonville, USA 4. Pathology, University of Florida College of Medicine – Jacksonville, Jacksonville, USA

Corresponding author: Rahul Gujarathi, dr_grahul@yahoo.com

Abstract

Primary effusion lymphoma (PEL) is a rare form of high-grade non-Hodgkin's lymphoma that usually occurs in patients with compromised immunity or human immunodeficiency virus (HIV) infection. PEL is a B-cell lymphoma that principally presents as effusions without a tumor mass. We present a case of a 56-year-old African-American male with a medical history of HIV admitted to the hospital with right lung lower lobe pneumonia and parapneumonic effusion. Thoracentesis and pleural fluid cytology led to the diagnosis of PEL. He received treatment with chemotherapy and antiretroviral therapy (ART). The emphasis is to investigate immunocompromised patients presenting with pleural effusion for PEL, as it is a rare ailment with a high mortality rate.

Categories: Internal Medicine, HIV/AIDS, Oncology

Keywords: hhv-8, hiv aids antiretroviral therapy, rare cause of pleural effusion, immunocompromised patient, non hodgkin's lymphoma

Introduction

A primary effusion lymphoma (PEL) is a rare form of high-grade non-Hodgkin's lymphoma (NHL) that usually occurs in patients with compromised immunity or HIV infection. As per the Centers for Disease Control and Prevention (CDC) in the United States of America (USA), approximately 1.2 million people have HIV. PEL is a rare HIV-associated NHL with a predilection for body cavities (pleural space, peritoneum, and pericardium). PEL is strongly causally related to Human herpes virus-8 (HHV8), also known as Kaposi's sarcoma herpes virus (KSHV), and its presence has been incorporated as a diagnostic criterion for PEL [1]. PEL accounts for less than 4% of all HIV-related lymphoma [2-4]. The incidence of AIDS-related NHL and primary central nervous system lymphoma has significantly decreased with ART since the 1990s [3]. Though PEL is commonly seen with HIV, it is also reported in people after solid organ transplantation, receiving immunosuppression therapy [5-8]. About 2% of HIV-positive individuals develop pleural effusion; the most common causes are parapneumonic effusions, empyema, tuberculosis, Kaposi sarcoma, and rarely Pneumocystis carinii infection [9]. Pleural effusion in HIV patients should be thoroughly worked up for possible infections and malignancies like lymphoma as it has different treatment and outcomes.

Case Presentation

A 56-year-old African-American male with a medical history of HIV not on ART, an active smoker presented to the emergency department with complaints of productive cough, shortness of breath, and associated right-sided pleuritic chest pain for the last four weeks. The patient was admitted to the hospital four weeks ago for right lower lobe pneumonia and was discharged on oral Levofloxacin for five days, which he was not compliant with. The patient returned back to the hospital with no improvement in his symptoms. Upon further elaboration of history, he also reported losing approximately 25 pounds weight in the prior six months and having night sweats for the last three to four weeks.

A physical exam was pertinent for a cachectic male patient in mild respiratory distress. Has oral candidiasis on inspection and decreased breath sounds on the right side compared to the left side on auscultation. Laboratory analysis revealed leukopenia with a white blood cell count of 2.91 thousand per cubic mm, anemia with hemoglobin of 10.9 g/dL, and a platelet count of 209 thousand per cubic mm. His creatinine was 0.97 mg/dL, sodium was 131 mmol/L, and CD4 count was 128 cells/ μ L.

Chest x-ray revealed right-sided pleural effusion. Computed tomography (CT) of the chest revealed right lung lower lobe Pneumonia as shown in the axial view (Figure 1) and large right-sided pleural effusion as shown in the coronal view (Figure 2).

How to cite this article

Gujarathi R, Candula N, Chippa V, et al. (July 12, 2022) Primary Effusion Lymphoma Presenting As Parapneumonic Pleural Effusion. Cureus 14(7): e26794. DOI 10.7759/cureus.26794

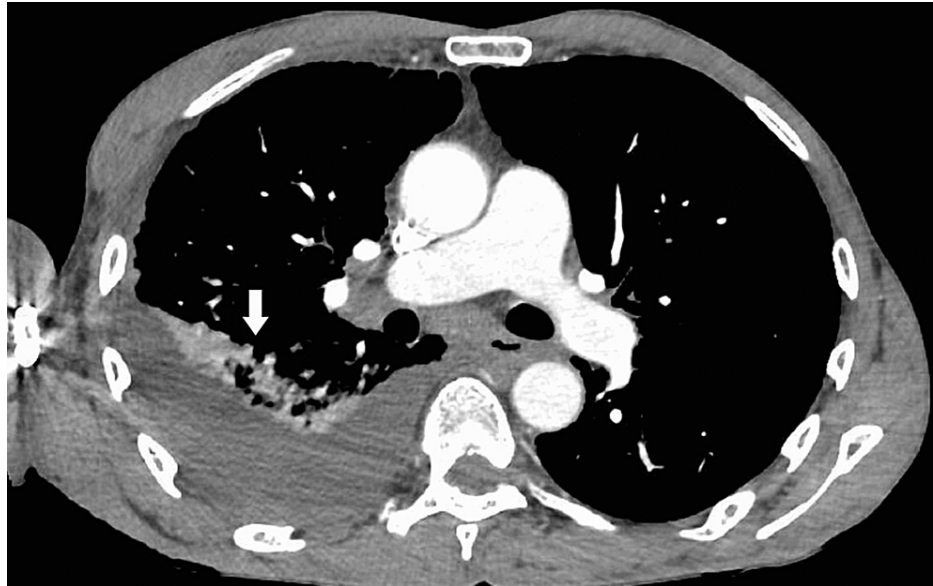


FIGURE 1: CT scan of the chest with contrast (axial view) showing right-sided pleural effusion

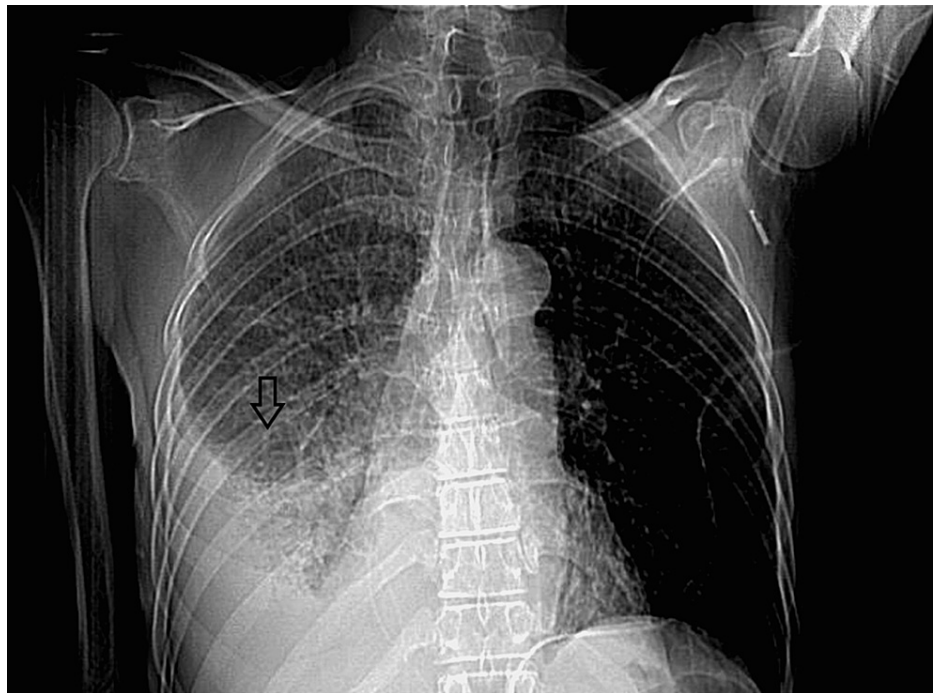

FIGURE 2: CT scan of the chest with contrast (coronal view) showing right-sided pleural effusion

The patient was admitted and started on antibiotics (Cefepime intravenously 2 g every eight hours and Zithromax orally 500 mg every 24 hours) for right-sided pneumonia and parapneumonic effusion. Subsequently, he underwent diagnostic and therapeutic right-sided thoracentesis. Pleural fluid analysis revealed the exudative etiology of pleural effusion. Cytology of pleural fluid was sent given his type-B symptoms, and the results were consistent with PEL. Pleural fluid flow cytometry revealed a monoclonal population compatible with lymphoma of B-cell origin and consistent with the PEL. Pleural fluid immunostain results were positive for markers CD30, MUM-1 (Multiple Myeloma-1), Ki-67 (proliferation marker), Kappa-ISH (in-situ Hybridization), and Epstein-Barr virus-encoded RNA (EBER). Pleural fluid immuno-stain

results were negative for markers such as CD20, PAX-5, CD138, and Lambda-ISH.

Figure 3 shows the neoplastic lymphoid cells of PEL with plasmablastic morphology on the Pap stain and Figure 4 shows the PEL cells immuno-reactive for HHV-8 on the immuno-histochemical stain.

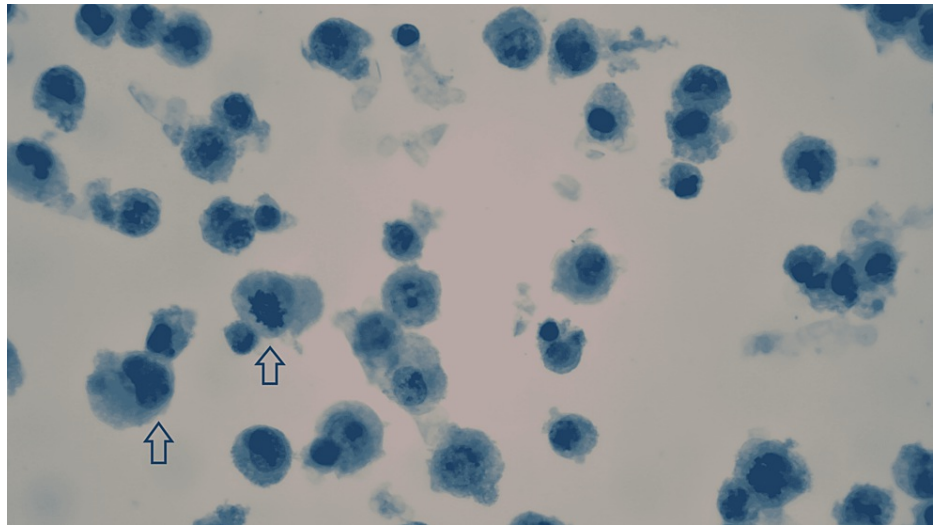


FIGURE 3: Pleural effusion shows numerous neoplastic lymphoid cells with plasmablastic morphology (Pap stain, 630x)

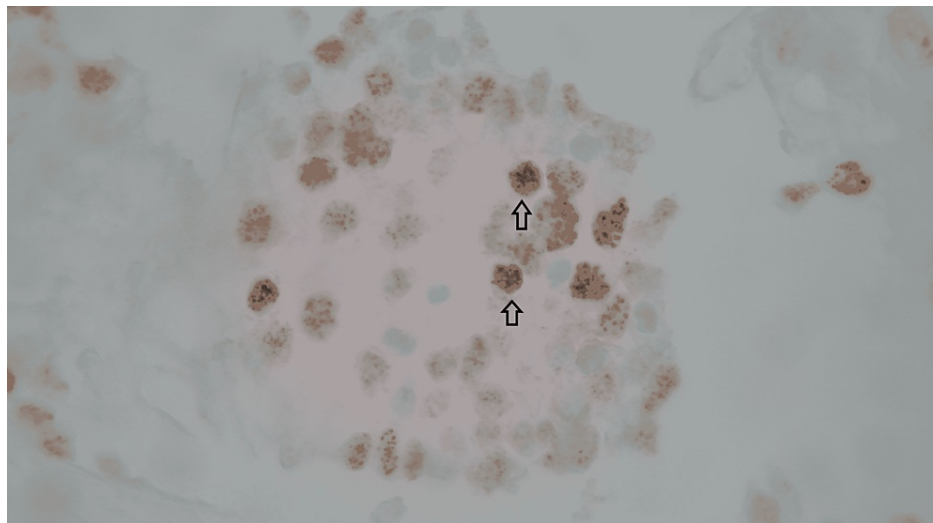


FIGURE 4: The cells are immunoreactive for HHV-8 (Immuno-histochemical stain, 630x)

The patient was promptly started on chemotherapy with EPOCH regimen (Etoposide, Prednisolone, Oncovin (Vincristine), Cyclophosphamide, and Hydroxydaunorubicin (Adriamycin)). He was also started on ART (combination of bicitegravir, emtricitabine, and tenofovir alafenamide) for his AIDS. The patient completed six cycles of chemotherapy treatment without significant side effects except for developing peripheral neuropathy during his cycle four chemotherapy, as a result of which Vincristine was discontinued. The patient was admitted again two months after completion of chemotherapy with acute hypoxic respiratory failure and multi-organ dysfunction leading to his death in the hospital.

Discussion

PEL is a rare B-cell malignancy that most often occurs in immunocompromised patients, such as HIV-infected individuals and patients receiving organ transplantation. The main characteristic of PEL is neoplastic effusions in body cavities without detectable tumor masses [10]. This entity is classified as a mature B-cell neoplasm in the 2001 World Health Organization (WHO) classification of tumors of

hematopoietic and lymphoid tissues. PEL is universally associated with HHV-8 [1]. HHV-8 seems to play a major role in the pathogenesis of PEL by promoting proliferation and impairing apoptosis [11-13].

PEL originates on the serosal surfaces, including the pleura (60% to 90%), peritoneum (30% to 60%), pericardium (up to 30%), joint spaces, and very rarely, the meninges [12,14,15]. Extra-cavitary PEL is a clinical variant of PEL that characterizes by solid tumor lesions without malignant serous fluid, and it accounts for approximately one-third of all cases of PEL [16,17].

Immunohistochemical staining for the viral gene product, latency-associated nuclear antigen (LANA-1), is the most common method for detecting HHV-8 positivity [18]. Over 90% of PEL cases demonstrate expression of CD45, and plasma cell-related markers such as epithelial membrane antigen, CD30, CD38, CD71, and CD138 are usually present [19]. B-cell antigens (CD19, CD20, CD79a) and T-cell-associated antigens are frequently negative but can be seen in a few cases [20]. The malignant cells display a range of morphologic appearances, from large plasmablastic or immunoblastic cells to those with more anaplastic features, and few cells can resemble Reed-Sternberg cells [18].

The differential diagnosis of PEL includes systemic lymphomas with secondary involvement of the body fluid (secondary effusion), lymphomas that develop due to chronic pyothorax (pyothorax-associated lymphoma), and extra-nodal variants of various subtypes of lymphoma (such as extra-nodal large cell lymphoma). PEL is distinguished from these other types of lymphoma by its HHV-8 positivity [19]. Kaposi sarcoma inflammatory cytokine syndrome (KICS) is a relatively new syndrome described in patients co-infected with HIV, and KSHV also falls under the differential diagnosis for PEL [21].

PEL can cause local destruction and consistently has a poor prognosis without treatment [14]. The median overall survival (OS) after PEL diagnosis, without treatment, is approximately two to three months [20]. Even with aggressive chemotherapy, the median OS extended on average to only six months [22,23]. Treatment approaches for PEL include ART, cytotoxic chemotherapy, radiation therapy, and their combinations. Most clinicians advocate the administration of both ART and combination chemotherapy as initial treatment. Case reports have illustrated that some patients with PEL can obtain Complete Remission (CR) with ART alone [4,12,15,19]. However, this approach is reserved for patients with poor performance status or other comorbidities that would preclude using combination chemotherapy. When choosing the ART regimen, it is essential to consider overlapping interference or toxicities of antiretroviral medications with chemotherapeutic medications that may be used in the future.

There is a lack of data to guide treating patients with PEL. Dose-adjusted EPOCH (Cyclophosphamide, Doxorubicin, Etoposide, Vincristine, Prednisone) or CHOP (Cyclophosphamide, Doxorubicin, Vincristine, Prednisone) is used in the treatment of PEL. CODOX-M (Cyclophosphamide, Vincristine, Doxorubicin, high-dose Methotrexate) with IVAC (Ifosfamide, Cytarabine, Etoposide, and intrathecal Methotrexate), also called the Magrath regimen, has been used for tumors with a very high growth fraction. This regimen has more toxicity and is reserved for patients with a few comorbidities and good functional status. Rituximab is incorporated into the regimen [12] in rare cases of PEL composed of B-lymphocyte antigen (CD20)-positive cells. The efficacy of consolidation with hematopoietic cell transplantation (HCT) for PEL is unknown. In one study, OS was 75%, and two-year progression-free survival was 50% in four patients who underwent autologous HCT after achieving a complete response with anthracycline-based combination chemotherapy [24]. Radiation therapy to the body cavity of origin may provide symptomatic relief when chemotherapy is not feasible, or the patient has failed other treatment regimens [25]. There is even less evidence to guide the treatment of patients with PEL who are negative for HIV, as this is a highly uncommon patient population. Since PEL is so rare, there are very few retrospective series and no prospective trials in this patient group.

Conclusions

PEL is an aggressive and rare lymphoma with high mortality, which can present as pleural effusion. Assessing for “B” symptoms, including fever, night sweats, and unintentional weight loss, is vital during history taking process. While it is relevant to evaluate for and treat the infection first, be vigilant not to miss alternative inflammatory, autoimmune, or malignant etiologies. This case report encourages clinicians to consider a broad differential, especially in HIV patients diagnosed with exudative pleural effusion, to investigate further with pleural fluid cytology. Diagnostic suspicion for PEL leads to early identification of the disease and initiation of treatment promptly. Emphasis must be placed on an expedited diagnosis and early enrollment in clinical trials.

Additional Information

Disclosures

Human subjects: Consent was obtained or waived by all participants in this study. **Conflicts of interest:** In compliance with the ICMJE uniform disclosure form, all authors declare the following: **Payment/services info:** All authors have declared that no financial support was received from any organization for the submitted work. **Financial relationships:** All authors have declared that they have no financial relationships at present or within the previous three years with any organizations that might have an

interest in the submitted work. **Other relationships:** All authors have declared that there are no other relationships or activities that could appear to have influenced the submitted work.

References

- Said J, Cesarman E, Harris NL: Primary effusion lymphoma. WHO Classification of Tumours of Haematopoietic and Lymphoid Tissues. Swerdlow SH (ed): IARC Press, Lyon, France; 2008. 260-1.
- Little RF, Gutierrez M, Jaffe ES, Pau A, Horne M, Wilson W: HIV-associated non-Hodgkin lymphoma: incidence, presentation, and prognosis. *JAMA*. 2001, 285:1880-5. [10.1001/jama.285.14.1880](https://doi.org/10.1001/jama.285.14.1880)
- Chen YB, Rahemtullah A, Hochberg E: Primary effusion lymphoma. *Oncologist*. 2007, 12:569-76. [10.1634/theoncologist.12-5-569](https://doi.org/10.1634/theoncologist.12-5-569)
- Simonelli C, Spina M, Cinelli R, et al.: Clinical features and outcome of primary effusion lymphoma in HIV-infected patients: a single-institution study. *J Clin Oncol*. 2003, 21:5948-54. [10.1200/JCO.2003.06.013](https://doi.org/10.1200/JCO.2003.06.013)
- Noureddin R, Athar S, Nagrale V, Gaba W: Primary effusion lymphoma (PEL) in a renal transplant patient. *Clin Med (Lond)*. 2020, 20:s53-4. [10.7861/clinmed.20-2-s53](https://doi.org/10.7861/clinmed.20-2-s53)
- Jones D, Ballestas ME, Kaye KM, et al.: Primary-effusion lymphoma and Kaposi's sarcoma in a cardiac-transplant recipient. *N Engl J Med*. 1998, 339:444-9. [10.1056/NEJM199808133390705](https://doi.org/10.1056/NEJM199808133390705)
- Dotti G, Fiocchi, et al.: Primary effusion lymphoma after heart transplantation: a new entity associated with human herpesvirus-8. *Leukemia*. 1999, 13:664-70. [10.1038/sj.leu.2401390](https://doi.org/10.1038/sj.leu.2401390)
- Melo NC, Sales MM, Santana AN, Costalonga EC, Pedreira AB, Ianhez LE: Pleural primary effusion lymphoma in a renal transplant recipient. *Am J Transplant*. 2008, 8:906-7. [10.1111/j.1600-6143.2008.02156.x](https://doi.org/10.1111/j.1600-6143.2008.02156.x)
- Light RW, Hamm H: Pleural disease and acquired immune deficiency syndrome. *Eur Respir J*. 1997, 10:2658-45. [10.1183/09031936.97.10112638](https://doi.org/10.1183/09031936.97.10112638)
- <https://doi.org/10.1182/blood-2018-03-791426>
- Wies E, Mori Y, Hahn A, Kremmer E, Stürzl M, Fleckenstein B, Neipel F: The viral interferon-regulatory factor-3 is required for the survival of KSHV-infected primary effusion lymphoma cells. *Blood*. 2008, 111:320-7. [10.1182/blood-2007-05-092288](https://doi.org/10.1182/blood-2007-05-092288)
- Carbone A, Ghoghini A: KSHV/HHV8-associated lymphomas. *Br J Haematol*. 2008, 140:13-24. [10.1111/j.1365-2141.2007.06879.x](https://doi.org/10.1111/j.1365-2141.2007.06879.x)
- Du MQ, Bacon CM, Isaacson PG: Kaposi sarcoma-associated herpesvirus/human herpesvirus 8 and lymphoproliferative disorders. *J Clin Pathol*. 2007, 60:1350-7. [10.1136/jcp.2007.047969](https://doi.org/10.1136/jcp.2007.047969)
- Nador RG, Cesarman E, Chadburn A, et al.: Primary effusion lymphoma: a distinct clinicopathologic entity associated with the Kaposi's sarcoma-associated herpes virus. *Blood*. 1996, 15:645-56. [10.1182/blood.V88.2.645.bloodjournal882645](https://doi.org/10.1182/blood.V88.2.645.bloodjournal882645)
- Ortega MEV, Santos PM, Aguado FG, Quintana FB, Cuesta FL, Vázquez VS, Lahoz JG: Primary cavity-based lymphoma and HIV infection (Article in Spanish). *Rev Clin Esp*. 1999, 199:73-7.
- Chadburn A, Hyjek E, Mathew S, Cesarman E, Said J, Knowles DM: KSHV-positive solid lymphomas represent an extra-cavitary variant of primary effusion lymphoma. *Am J Surg Pathol*. 2004, 28:1401-16. [10.1097/01.pas.0000138177.10829.5c](https://doi.org/10.1097/01.pas.0000138177.10829.5c)
- Grogg KL, Miller RF, Dogan A: HIV infection and lymphoma. *J Clin Pathol*. 2007, 60:1365-72. [10.1136/jcp.2007.051953](https://doi.org/10.1136/jcp.2007.051953)
- Banks PM, Warnke RA: Primary effusion lymphoma. World Health Organization Classification of Tumours. Pathology and Genetics of Tumours of Haematopoietic and Lymphoid Tissues. Jaffe ES, Harris NL, Stein H, Vardiman JW (ed): IARC Press, Lyon, France; 2001. 179.
- Oksenhendler E, Clauvel JP, Jouvesshomme S, et al.: Complete remission of a primary effusion lymphoma with antiretroviral therapy. *Am J Hematol*. 1998, 10:25-3. [10.1002/\(SICI\)1096-8652\(199803\)57:3<266::AID-AJH25>3.0.CO;2-7](https://doi.org/10.1002/(SICI)1096-8652(199803)57:3<266::AID-AJH25>3.0.CO;2-7)
- Komanduri KV, Luce JA, McGrath MS, et al.: The natural history and molecular heterogeneity of HIV-associated primary malignant lymphomatous effusions. *J Acquir Immune Defic Syndr Hum Retrovirol*. 1996, 1:215-26.
- Dumic I, Radovanovic M, Igandan O, et al.: A fatal case of Kaposi sarcoma immune reconstitution syndrome (KS-Iris) complicated by Kaposi sarcoma inflammatory cytokine syndrome (KICS) or multicentric Castlemans disease (MCD): a case report and review. *Am J Case Rep*. 2020, 21:e926433. [10.12659/AJCR.926433](https://doi.org/10.12659/AJCR.926433)
- Karcher DS, Alkan S: Human herpesvirus-8-associated body cavity-based lymphoma in human immunodeficiency virus-infected patients: a unique B-cell neoplasm. *Hum Pathol*. 1997, 28:801-8. [10.1016/S0046-8177\(97\)90153-2](https://doi.org/10.1016/S0046-8177(97)90153-2)
- Boulanger E, Daniel MT, Agbalika F, Oksenhendler E: Combined chemotherapy including high-dose methotrexate in KSHV/HHV8-associated primary effusion lymphoma. *Am J Hematol*. 2003, 75:145-8. [10.1002/ajh.10341](https://doi.org/10.1002/ajh.10341)
- Mirza AS, Dholaria BR, Hussaini M, et al.: High-dose therapy and autologous hematopoietic cell transplantation as consolidation treatment for primary effusion lymphoma. *Clin Lymphoma Myeloma Leuk*. 2019, 19:e513-20. [10.1016/j.clml.2019.03.021](https://doi.org/10.1016/j.clml.2019.03.021)
- Cassoni A, Ali U, Cave J, Edwards SG, Ramsay A, Miller RF, Lee SM: Remission after radiotherapy for a patient with chemotherapy-refractory HIV-associated primary effusion lymphoma. *J Clin Oncol*. 2008, 26:5297-9. [10.1200/JCO.2008.18.3350](https://doi.org/10.1200/JCO.2008.18.3350)