

Heart transplantation for end-stage heart failure combined with Q fever isolated to the heart: a case report

Marcel van 't Veer¹, Luuk Otterspoor ^{1*}, Marieke de Regt ²,
Kathinka Peels¹, Jola evens³, Aryan Vink⁴, and Nicolaas de Jonge ⁵

¹Department of Cardiology, Catharina Hospital Eindhoven, Michelangelolaan 2, 5623 EJ Eindhoven, The Netherlands; ²Department of Internal Medicine, Onze Lieve Vrouwe Gasthuis, Oosterpark 9, 1091 AC, Amsterdam, The Netherlands; ³Department of Cardiothoracic Surgery, University Medical Center, Utrecht, The Netherlands; ⁴Department of pathology, University Medical Center, Utrecht, The Netherlands; and ⁵Department of Cardiology, University Medical Center Utrecht, Heidelberglaan 100, 3584 CX, Utrecht, The Netherlands

Received 28 June 2020; first decision 28 July 2020; accepted 27 October 2020; online publish-ahead-of-print 5 December 2020

Background

Active infection is generally considered a contraindication for heart transplantation. The rare combination of a patient with an active *Coxiella burnetii* infection and a congenital corrected transposition of the great arteries requiring heart transplantation impose challenging treatment decisions. We would like to demonstrate that if Q fever is restricted to the heart only, heart transplantation is also beneficial from an infectious point of view, therefore treating two severe conditions simultaneously.

Case summary

A patient with end-stage heart failure due to congenital corrected transposition of the great arteries and requiring heart transplantation developed chronic Q fever and endocarditis. Different antibiotic regimes were tried due to severe adverse reactions. Antibiotic treatment was precisely monitored by measuring Q fever polymerase chain reaction (PCRs) and phase I IgG antibody titres. A positron emission tomography scan revealed that Q fever was confined to the heart only after which it was decided to perform heart transplantation. Based on the results of PCR and antibody testing, antibiotic treatment was stopped after 1 year. After 5 years of follow-up, patient is still in an optimal condition.

Discussion

In case of a patient with end-stage heart failure and chronic Q fever, a combined treatment with PCR-/antibody monitored antibiotics and heart transplantation can cure both conditions.

Keywords

Heart transplantation • *Coxiella burnetii* • Q fever • Endocarditis • Heart failure • Case report

Learning points

- Q fever infection, if limited to the heart, should not be considered as a contraindication for heart transplantation.
- Heart transplantation combined with antibiotic therapy may cure Q fever, if limited to the heart.
- Careful follow-up of polymerase chain reactions and IgG titres is needed to guide antibiotic therapy and to decide on its duration.

* Corresponding author. Tel: +31 (0) 40 239 7004, Fax: +31 (0) 40 246 4837, Email: luuk.otterspoor@catharinaziekenhuis.nl

Handling Editor: Sylvia Krupickova

Peer-reviewers: Filippo Puricelli and Alberto Bouzas-Mosquera

Compliance Editor: Gemima Doolub

Supplementary Material Editor: Ross Thomson

© The Author(s) 2020. Published by Oxford University Press on behalf of the European Society of Cardiology.

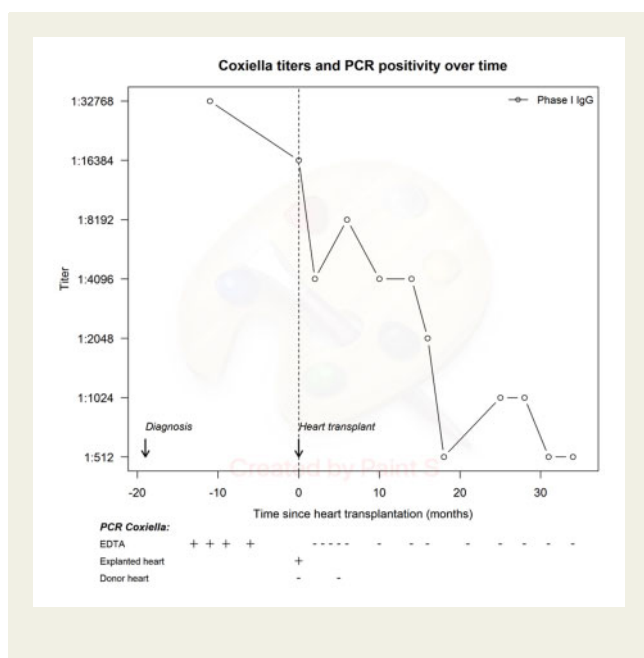
This is an Open Access article distributed under the terms of the Creative Commons Attribution Non-Commercial License (<http://creativecommons.org/licenses/by-nc/4.0/>), which permits non-commercial re-use, distribution, and reproduction in any medium, provided the original work is properly cited. For commercial re-use, please contact journals.permissions@oup.com

Introduction

Q fever is a zoonotic infection caused by the pathogen *Coxiella burnetii*, which is a short, pleomorphic rod that is a strict intracellular bacterium. Patients may present with a wide spectrum of acute and chronic disease manifestations, varying from fever and pneumonia to vascular infections and endocarditis. Particularly patients with underlying valvular disease are at increased risk of developing sub-acute or chronic endocarditis when infected with *C. burnetii*. Large outbreaks with Q fever have been reported, with the largest outbreak ever occurring in the Netherlands in 2009, where it was previously unknown.¹

We report a case of a young patient with advanced heart failure and valvular disease, requiring heart transplantation, who developed streptococcal endocarditis, after which coincidentally chronic Q fever was detected. The combination of these disorders laid large debate on treatment decisions between cardiothoracic surgeons, infectiologists, and transplantation cardiologists, since no evidence was available on comparable cases.

Timeline



Case presentation

A 33-year-old male was admitted with ongoing fever and progressive fatigue. His medical history revealed a congenital corrected transposition of the great arteries, congenital atrioventricular block, tricuspid valve replacement (Medtronic Mosaic[®]) at the age of 19, and progressive heart failure for which heart transplantation was considered. In the years before admission, echocardiography revealed progressive deterioration of left ventricular function as

well as severe degeneration of the tricuspid (system AV-) valve bioprosthesis, resulting in severe regurgitation and moderate stenosis.

At first, blood cultures revealed *Streptococcus mutans*, but no endocardial vegetations valve were observed on transoesophageal echocardiography. Because infectious endocarditis was still clinically suspected, treatment was started with IV Ceftriaxone for 6 weeks. Short after admission he also tested positive for active Q fever infection based on phase I and phase II IgG titres of 1:32 768, as well as positive *C. burnetii* polymerase chain reaction (PCR) on plasma. Initial Q fever treatment consisted of doxycycline in combination with hydroxychloroquine. The latter drug was not well tolerated because of nausea and antibiotic treatment was changed to a combination of doxycycline and rifampicin. Subsequently, the use of rifampicin led to acute liver failure. Therefore, again another antibiotic regimen had to be selected, resulting in the combination of doxycycline and moxifloxacin orally.

After successful antibiotic treatment, resulting in negative blood cultures for *S. mutans*, both serology and PCR on plasma confirmed an active invasive infection with *C. burnetii*. A positron emission tomography-computed tomography (PET-CT) demonstrated increased fluorodeoxyglucose uptake around the tricuspid valve prosthesis suggestive of active endocarditis, possibly due to persisting Q fever (Figure 1). Due to the critical fact that the infection was limited strictly to the heart and no other spots for infection were revealed, it was decided to place the patient on the waiting list for heart transplantation, while antibiotic treatment with doxycycline and moxifloxacin was continued. Despite repeatedly positive *C. burnetii* EDTA plasma PCRs and phase I IgG antibody titres, a successful heart transplantation was performed, 2 years after initiation of antimicrobial Q fever treatment. Examination of the explanted heart did not reveal endocardial vegetations but confirmed the *C. burnetii* endocarditis of the tricuspid valve prosthesis (Figure 2). Fortunately, *C. burnetii* PCRs on plasma samples taken in the weeks post-transplantation were all negative, supporting the hypothesis that the Q fever infection was confined to the explanted heart. However, to minimize the risk of relapse, it was decided to continue antimicrobial Q fever treatment during the 1st year post-transplantation, consisting of doxycycline in addition to the immunosuppressive medication. All consecutive PCRs performed on plasma and donor heart tissue after transplantation remained negative and serology titres declined gradually (Timeline). One year after transplantation doxycycline was stopped, after which *C. burnetii* phase I IgG titres remained low and plasma PCRs remained negative.

The patient is now 5 years after transplantation and still in an excellent clinical condition.

Discussion

Coxiella burnetii is increasingly recognized as a cause for endocarditis worldwide. Screening for *C. burnetii* is performed routinely in Dutch hospitals after a major outbreak of Q fever in the Netherlands between 2007 and 2010.¹ Unfortunately, due to late

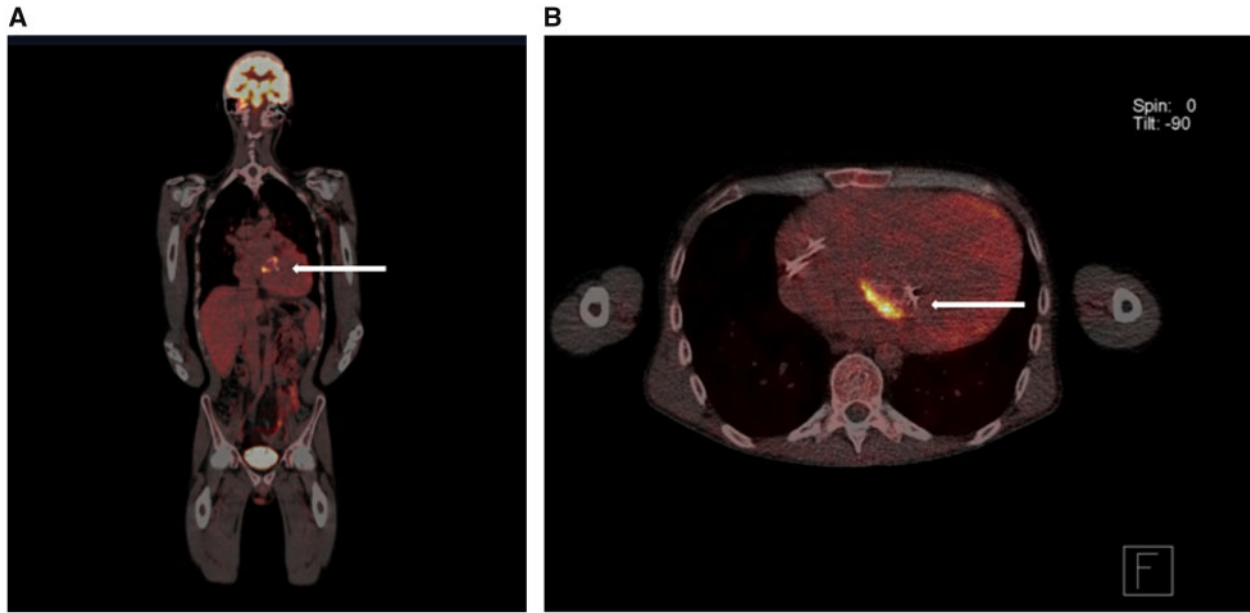


Figure 1 Longitudinal (A) en transversal (B) positron emission tomography-computed tomography (PET-CT) images, demonstrating uptake of the fluorodeoxyglucose (FDG) at the tricuspid valve (systemic atrioventricular valve) indicating inflammation (arrows). No other parts of the body are affected, proving the isolated infection of the heart only.

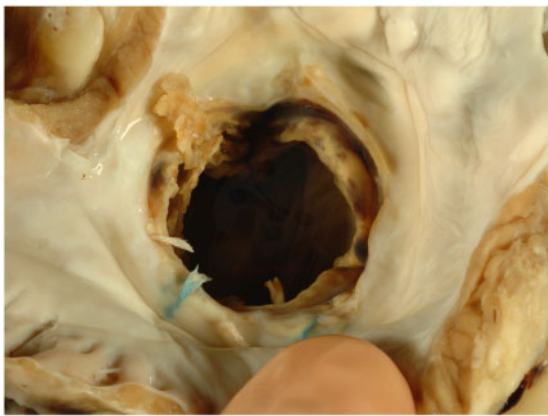


Figure 2 Gross picture of bioprosthesis (view from atrium) with destruction of the valve leaflets

recognition of the extent and impact of this epidemic, chronic Q fever still forms an important and growing healthcare problem, especially in patients with underlying cardiac valve or vascular defects or prostheses.²

Our patient, in need of heart transplantation due to end-stage heart failure, developed a chronic Q fever endocarditis during this outbreak, which seriously diminished his chances of a successful transplantation. Even though it is considered a contraindication,

occasional cases are described in which heart transplantation was performed in patients with an active infection. Heart transplantation was considered a last-resort procedure in patients with intractable infective endocarditis³ and in only one case report, *C. burnetii* was described as the pathogen associated with endocarditis of a native bicuspid aortic valve.⁴ In that case, in which there were negative cell cultures, the complicated treatment course underlines the complex microbiology of this intracellular, Gram-negative bacterium. As the infection seemed to be confined to the heart on PET-CT, in the end, our patient was considered eligible for transplantation.

Although the source of the chronic Q fever infection was believed to be eliminated, antimicrobial treatment with doxycycline was continued post-transplantation. In contrast to the choice for an indefinite antibiotic treatment with doxycycline, as reported in the case by Blanche *et al.*,⁴ we chose to stop doxycycline 1 year after transplantation because of persistent negative PCRs and declining IgG titres. No recurrence of infection has been observed since.

Conclusion

The successful outcome in our case demonstrates that in patients in need of heart transplantation, concomitant Q fever infection, if limited to the heart, should not be considered as a contraindication and might, under the guise of 'ubi pus evacua', even serve as a cure. The duration of post-transplantation antibiotic treatment remains a matter of debate since no evidence is available.

Lead author biography



Marcel van 't Veer is medical engineer focusing on cardiovascular research enabling decision support tools through combining physical and statistical models. These tools use a wide variety of input data including images, invasive and non-invasive measurements, and other clinical data.

Supplementary material

[Supplementary material](#) is available at *European Heart Journal - Case Reports* online.

Acknowledgements

We thank Heidi Ammerlaan for reviewing the manuscript.

Slide sets: A fully edited slide set detailing this case and suitable for local presentation is available online as [Supplementary data](#).

Consent: The authors confirm that written consent for submission and publication of this case report including image(s) and associated text has been obtained from the patient in line with COPE guidance.

Conflict of interest: none declared.

Funding: none declared.

References

1. Hogema BM, Slot E, Molier M, Schneeberger PM, Hermans MH, van Hanne E *et al*. *Coxiella burnetii* infection among blood donors during the 2009 Q-fever outbreak in the Netherlands. *Transfusion* 2012;**52**:144–150.
2. Eldin C, Mélenotte C, Mediannikov O, Ghigo E, Million M, Edouard S *et al*. From Q fever to *Coxiella burnetii* infection: a paradigm change. *Clin Microbiol Rev* 2017;**30**: 115–190.
3. Aymami M, Revest M, Piau C, Chabanne C, Le Gall F, Lelong B *et al*. Heart transplantation as salvage treatment of intractable infective endocarditis. *Clin Microbiol Infect* 2015;**21**:371.e1.
4. Blanche C, Freimark D, Valenza M, Czer LS, Trento A. Heart transplantation for Q fever endocarditis. *Ann Thorac Surg* 1994;**58**:1768–1769.