



## Original article

# Measurement of quality of life among patient undergoing arthroplasty of the thumb to treat CMC arthritis<sup>☆</sup>



Marcio Aurélio Aita\*, Rafael Saleme Alves, Luis Felipe Longuino, Carlos Henrique Vieira Ferreira, Douglas Hideki Ikeuti, Luciano Muller Reis Rodrigues

Faculdade de Medicina do ABC, Departamento Clínico-Cirúrgico IV, Disciplina de Ortopedia e Traumatologia, Santo André, SP, Brazil

## ARTICLE INFO

## Article history:

Received 3 August 2015

Accepted 5 October 2015

Available online 6 June 2016

## Keywords:

Quality of life

Trapezium bone

Arthroplasty

Thumb

## ABSTRACT

**Objective:** To present the clinical and functional results, including measurement of quality of life, of patients undergoing trapeziometacarpal arthroplasty.

**Method:** This was a prospective evaluation on 45 patients (53 thumbs) with a diagnosis of idiopathic rhizarthrosis who underwent resection arthroplasty and interposition of an uncemented Ascension® implant, made of pyrocarbon. The clinical and functional results were analyzed through radiography, range of motion (ROM) in degrees (°), visual analog scale (VAS) for pain and the disability of arm, shoulder and hand (DASH) questionnaire for quality of life. In the group analyzed, 38 were women and seven were men, and their mean age was 63.17 years (range: 50–78). Eight patients were treated bilaterally.

**Results:** After 42.08 months of follow-up (range: 8–73), the subjective pain evaluation (VAS) score was 1.37 (range: 1–4). The complete ROM of the thumb increased to 95.75% (range: 75–100%) in relation to the contralateral side. The mean DASH questionnaire score was 9.98 (range: 1–18). The complication rate (negative events) was 11.32%. Five patients presented dislocation of the thumb prosthesis. All of them were reoperated by means of dorsal capsuloplasty using a portion of the retinaculum of the extensors as a graft, and good clinical evolution was achieved in these cases. One patient presented fracturing of the metacarpal and was treated by means of osteosynthesis using Kirschner wires.

**Conclusion:** This method is effective for treating rhizarthrosis, according to the measurements made on the clinical and functional results, even after taking the complication rate into consideration. Moreover, it provides an improvement of quality of life for these patients.

© 2016 Published by Elsevier Editora Ltda. on behalf of Sociedade Brasileira de Ortopedia e Traumatologia. This is an open access article under the CC BY-NC-ND license (<http://creativecommons.org/licenses/by-nc-nd/4.0/>).

<sup>☆</sup> Study conducted at Hospital Mario Covas, Santo André, SP, Centro Hospitalar Municipal de Santo André, SP; and Hospital de Ensino Padre Anchieta de São Bernardo do Campo, São Bernardo do Campo, SP, Brazil.

\* Corresponding author.

E-mail: [marcioaita@me.com](mailto:marcioaita@me.com) (M.A. Aita).

<http://dx.doi.org/10.1016/j.rboe.2016.06.003>

2255-4971/© 2016 Published by Elsevier Editora Ltda. on behalf of Sociedade Brasileira de Ortopedia e Traumatologia. This is an open access article under the CC BY-NC-ND license (<http://creativecommons.org/licenses/by-nc-nd/4.0/>).

## Mensuração da qualidade de vida dos pacientes submetidos a artroplastia do polegar no tratamento da rizartrose

### R E S U M O

**Palavras-chave:**  
Qualidade de vida  
Trapézio  
Artroplastia  
Polegar

**Objetivo:** Apresentar os resultados clínico-funcionais e a mensuração da qualidade de vida dos pacientes submetidos à artroplastia trapézio-metacárpica.

**Método:** Avaliação prospectiva de 45 pacientes e 53 polegares acometidos, com diagnóstico de rizartrose idiopática submetidos à artroplastia de ressecção e interposição, com o implante Ascension®, não cimentado, de pirocarbono. Foram analisados os resultados clínico-funcionais: análise radiográfica, o arco de movimento (ADM) em graus (°), dor (VAS: *visual analog score*), qualidade de vida (Dash: *disability shoulder, arm, and hand questionnaire*). No grupo analisado, 38 são mulheres e sete são homens e a idade média é de 63,17 anos (50-78). Foram operados oito pacientes com acometimento bilateral dos polegares.

**Resultados:** Após 42,08 meses (8-73) de seguimento, a avaliação subjetiva da dor (VAS) foi de 1,37 (1-4). O arco do movimento completo do polegar teve um aumento de 95,75% (75-100) do lado contralateral. O questionário Dash foi em média de 9,98 (1-18). A taxa de complicações ou eventos negativos foi de 11,32%. Observamos cinco pacientes com luxações das próteses de polegares. Todos foram reoperados e fez-se a capsuloplastia dorsal, com o uso como enxerto de uma porção da retináculo dos extensores, obteve-se uma boa evolução clínica nesses casos. Um paciente apresentou fratura do metacarpo e foi tratado com osteossíntese com fio de Kirschner.

**Conclusão:** O método é eficaz no tratamento da rizartrose de acordo com os valores apurados dos resultados clínico-funcionais, mesmo considerando-se as taxas de complicações. Além disso, proporciona a melhoria da qualidade de vida desses pacientes.

© 2016 Publicado por Elsevier Editora Ltda. em nome de Sociedade Brasileira de Ortopedia e Traumatologia. Este é um artigo Open Access sob uma licença CC BY-NC-ND (<http://creativecommons.org/licenses/by-nc-nd/4.0/>).

## Introduction

Rhizarthrosis is the most common degenerative disease and the one that most restricts the thumb of middle-aged women, especially in the fifth and sixth decades of life. It can also be observed in men with history of repetitive joint use and in young women with ligamentous laxity.<sup>1</sup>

There are many recommended surgical techniques for the treatment of this disease: trapeziectomy; trapezio-metacarpal arthrodesis; ligament reconstruction; partial or total arthroplasty; and arthroscopic resection, replacement, or interposition.

Arthroscopic resection and interposition are well established for the treatment of rhizarthrosis and present good results in 85% of patients. Currently, numerous partial or complete prostheses are being developed and improved to maintain axial length of the first ray of the hand, shorten postoperative recovery time,<sup>2</sup> and allow for a total recovery of pinch strength. However, results are not well documented.<sup>3</sup>

This study aimed to present clinical and functional results and measurement in quality of life of patients undergoing trapezio-metacarpal arthroplasty with uncemented pyrocarbon Ascension® implant.

## Material and methods

The study assessed 65 patients who attended a pre-operative visit in the hand surgery outpatient clinic of the university

hospitals linked to the institution. Forty-five patients and 53 thumbs were selected. However, in the postoperative period, patients were followed-up in a single outpatient clinic. All patients had the diagnosis of primary rhizarthrosis stages II and III according to the Eaton and Littler classification, *apud* Martin-Ferrero et al. (Table 1).<sup>2</sup>

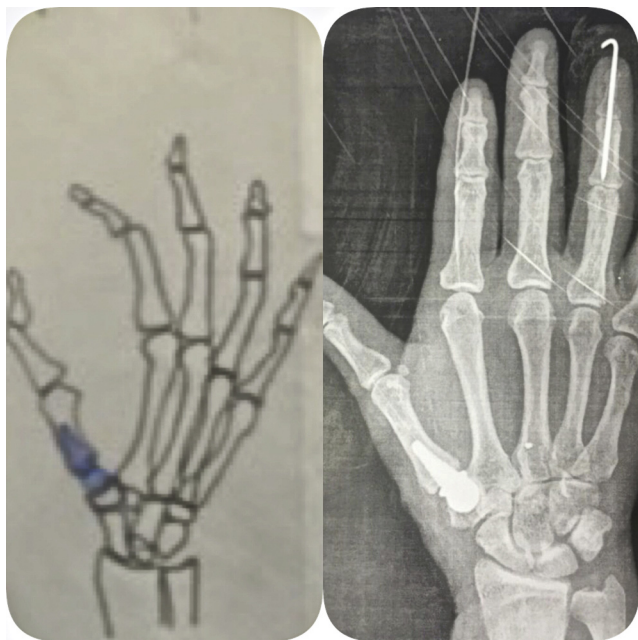
Patients' demography consisted of 38 females and seven males. Eight patients were surgically addressed for both hands. This was a prospective study, with mean follow-up of 42.08 months (8-73). Mean age was 63.17 years (50-78).

Patients were assessed in a preoperative evaluation and in the postoperative period through the following methods:

1. Application of the DASH questionnaire to assess quality of life;

**Table 1 – Eaton and Littler classification *apud* Martin-Ferrero et al.<sup>2</sup>**

Stage	Radiological criteria – Eaton and Littler
I	Normal joint contours; the interlining articulate may be widened secondary to laxity or joint effusion
II	Slight narrowing of the interlining articulate; joint debris and osteophytes <2 mm Normal ST joint
III	Marked degenerative changes with no interlining articulate, geodes, osteophytes, and sclerosis >2 mm; variable degrees of subluxation; normal ST joint
IV	Similar to stage III but with degenerative changes of the ST joint



**Figure 1 – Image to compare the pre-operative planning and radiograph aspects post operative.**

2. Measurement of the range of motion of the affected and unaffected thumbs with a specific goniometer. Value expressed indicated the percentage of thumb range of motion relative to the unaffected thumb;
3. Subjective analysis of pain by visual analog scale (VAS).

Surgical technique was the same for all patients and was applied by the same surgeon (Fig. 1):

1. Patient in standard-fashion supine position and preparation under local anesthesia;
2. Dorsal and longitudinal approach for the affected thumb in the trapezio-metacarpal region;
3. Dissection of the sensitive branch of the dorsal nerve to the thumb;
4. Opening of the dorsal capsule and careful dissection for later reinsertion;
5. Creation of the proximal and distal components of the arthroplasty with resection of metacarpal and trapezium osteophytes;
6. Creation of the metacarpal tunnel with specific mills;
7. Placement of proof prosthesis to verify the accurate size;
8. Creation of an orifice in the trapezium, with specific mills, for perfect congruence with the distal component of the prosthesis;
9. Placement of the pyrocarbon prosthesis on the metacarpal in press-fit; performance of thumb bending, abduction, and circumduction maneuvers to confirm stability of the prosthesis under direct visualization and fluoroscopy;
10. Soft-tissue balancing with dorsal capsule suture and verification of the stability of the arthroplasty;
11. Layer by layer closure and stitching;

12. Occlusive dressing and placement of a previously made functional thumb orthotics.

Patients in the postoperative follow-up returned every week to change dressings and undergo control X-rays. Thumb orthotic was maintained for six weeks; rehabilitation began in the second week at the occupational therapy group of the institution, with activities for analgesia, scarring management, and passive mobility of the thumb.

The presented study was approved by the Research Ethics Committee under the protocol No. 1,083,641 and an informed consent form was provided for all participants, who voluntarily read and signed.

## Results

Subjective assessment of pain (VAS) was 1.37 (1–4). Thumb range of motion was 95.75% (75–100) of the unaffected side. Mean DASH questionnaire score was 9.98 (–18).

Complication rate was 11.32%, as there were five dislocations; all these patients underwent reoperation with the dorsal capsuloplasty technique, using a dorsal wrist retinaculum graft. These patients presented a good clinical outcome. Another patient had a metacarpal fracture and was treated with internal fixation with Kirschner wires. None of the operated patients had functional or postural complaints regarding the re-operated thumbs (Table 2).

Regarding the pyrocarbon prosthesis, no patients presented implant loosening or fracture.

## Discussion

There are numerous recommended surgical techniques for treating rhizarthrosis. They all aim to reduce pain and deformity, increasing mobility and thumb pinch strength.

The isolated trapeziectomy described by Gervis apud Ibsen-Sorensen<sup>3</sup> or associated with interposition presents excellent results,<sup>3-6</sup> but has the disadvantage of decreasing the length of the first radius and the degree of pinch strength.<sup>7</sup>

Ligamentous reconstruction techniques associated with trapezoidal resection showed preservation of the radius length, and theoretically, preservation of pinch strength.<sup>2,4,8-11</sup> However, they require a multiple or wide access route, using adjacent structures that require a lengthy scarring and rehabilitation time.

Searching for more physiological and less invasive procedures, aiming to preserve the axial axis of motion and the degree of clamp force, as well as to reduce the earlier postoperative recovery time, arthroscopy techniques<sup>12</sup> (with or without interposition of structures) and several partial or total replacement prosthesis have been developed.

In the present study, the partial uncemented pyrocarbon Ascension® prosthesis<sup>13-15</sup> was implanted with a dorsal access route, showing good functional results and improved quality of life in patients post procedure, despite the complication rate of 11.32%.

This study showed lower rates of complications and better functional outcomes than the study by Szalay et al.,<sup>16</sup> who used pyrocarbon interposition prostheses.

**Table 2 – Epidemiological aspects and clinical and functional outcomes of patients undergoing thumb arthroplasty.**

N	Age (years)	Sex	Dominance	Follow-up (months)	DASH	ROM (°)	VAS	Complications
1	68	F	ND	73	1	100	1	
2	65	M	ND	72	1	98	1	
3	62	F	D	69	6	91	2	
4	63	F	D	69	1	100	1	
5	60	F	D	68	1	95	2	
6	65	F	D	67	1	93	1	Dislocation
7	59	F	D	65	18	88	3	
8	70	F	ND	64	1	100	1	
9	59	F	ND	62	1	100	1	
10	75	F	ND	62	6	85	2	Metacarpal fracture
11	64	M	D	61	1	100	1	
12	74	F	D	59	6	90	1	Dislocation
13	64	M	D	56	1	100	1	
14	62	F	ND	56	12	83	2	Dislocation
15	56	M	D	56	6	80	1	Dislocation
16	68	F	D	55	1	100	1	
17	70	F	D	55	1	100	1	
18	60	F	D	55	1	100	1	
19	67	F	D	54	1	100	1	
20	61	F	ND	54	1	100	1	
21	64	F	D	54	1	100	1	
22	58	M	D	54	1	100	1	
23	60	F	D	53	2	91	1	Dislocation
24	66	F	D	48	1	100	1	
25	64	F	D	47	1	100	1	
26	59	F	ND	47	1	100	1	
27	56	F	D	43	1	100	1	
28	69	F	L	42	12	85	2	
29	64	F	ND	41	1	100	1	
30	66	F	D	39	1	100	1	
31	59	F	D	37	24	100	4	
32	62	F	ND	35	1	100	1	
33	60	M	D	34	1	100	1	
34	60	F	D	34	1	100	1	
35	67	F	D	31	1	100	1	
36	61	F	ND	28	1	100	1	
37	57	F	D	28	1	100	1	
38	70	F	D	27	1	100	1	
39	62	F	ND	26	1	100	1	
40	50	M	D	24	12	78	3	
41	70	F	D	18	1	100	1	
42	63	F	ND	17	1	100	1	
43	58	F	D	16	1	100	1	
44	60	F	D	14	1	100	1	
45	78	F	D	14	6	92	2	
46	62	F	D	13	18	75	3	
47	59	M	D	13	12	83	3	
48	60	F	D	12	18	80	3	
49	62	F	D	12	1	100	1	
50	68	F	D	36	18	88	2	
51	64	F	ND	25	1	100	1	
52	59	F	D	28	1	100	1	
53	58	F	ND	8	1	100	1	

Source: SAME.

DASH, disability the arm, shoulder, and hand; ROM, range of motion; VAS, visual analog score; kgf, kilogram-force; ND, non-dominant; D, dominant.

Comparing the present study with that by Ibsen-Sorensen,<sup>3</sup> which used a cemented metal-polyethylene total prosthesis, similar results were observed for pain improvement, complication rate, and range of motion gain. In the present

study, there were five dislocations in 53 operated thumbs vs. five dislocations in the 54 cases operated by Ibsen-Sorensen.

The clinical and functional results of the present study are also similar to those of trapezectomy<sup>5,6,17,18</sup> or ligament

reconstruction,<sup>4,9-11,16</sup> with patient satisfaction rates close to 90%.

Some comparative studies have shown the advantages of arthroplasty with interposition of pyrocarbon implants when compared to ligament reconstruction without implant interposition.<sup>19</sup>

Although the present study had a short follow-up time (42.08 months), the final results do not change much six months after surgery.

Prosthesis stability is due to several factors, including implant-trapezoid congruence and, moreover, healing of the soft tissue envelope around the trapeziometacarpal joint, especially the dorsal capsule.

Pyrocarbon osseointegration was observed in all cases in the present study, without implant loosening or fracture, which is in agreement with the study by Beckenbaugh-Klawitter.<sup>14</sup>

The pyrocarbon prosthesis used in this technique has advantages over other implants. It preserves bone mass due to a basic minimal resection of the first metacarpal; trapezium resection is not necessary, and therefore thumb height is maintained. As these are uncemented prostheses that fixate to the metacarpal through press fit, and given that pyrocarbon has the same hardness as the bone, these prostheses allow for maximum grip with the metacarpal and do not generate debris or stress shielding. Furthermore, pyrocarbon has excellent biocompatibility.<sup>20</sup>

Complication rate in the present study was 11.32%. Five patients presented single dislocations, which were resolved with dorsal capsuloplasty.

The study by Szalay et al.,<sup>16</sup> who used pyrocarbon interposition prosthesis, presented a higher rate of complications and worse functional outcomes when compared with the present study.

The present authors believe that replacement arthroplasty of the base of the first metacarpal bone associated with interposition arthroplasty of the trapezium, using a single component, preserves thumb length and range of motion, as well as quality of life for these patients. The mobility of this joint, which was previously sellar, becomes spherical with the use of this prosthesis; this demonstrates that this procedure is effective in treating rhizarthrosis.

The authors note that pain improvement is only observed sixth months after the procedure; the reason for this is still unknown, as pyrocarbon is a recent material in orthopedics.

The present study limited itself to presenting the clinical and functional results and assessing the quality of life of patients after the described procedure.

## Conclusion

Thumb arthroplasty is effective in treating rhizarthrosis, according to clinical and functional outcomes and complications rate, and provides better quality of life for these patients.

## Conflicts of interest

The authors declare no conflicts of interest. All material was provided by the company that owns the material, which allowed the study to be conducted at no extra cost to the Brazilian Unified Healthcare System.

## REFERENCES

- Martou G, Veltri K, Thoma A. Surgical treatment of osteoarthritis of the car-pometacarpal joint of the thumb: a systematic review. *Plast Reconstr Surg.* 2004;114(2):421-32.
- Martin-Ferrero MH, Vega C, Lomo JA. Long-term results (more than 10 years) follow up of total joint arthroplasty in the treatment of thumb carpometacarpal joint osteoarthritis. *J Hand Surg Eur.* 2011;36 1 Suppl.:S46-7.
- Ibsen-Sorensen A. The elektra prosthesis for total replacement of the first cmc-joint. Prospective study with follow-up of one to six years. *J Hand Surg Eur.* 2011;36 1 Suppl.:S50.
- Burton RI, Pellegrini VD Jr. Surgical management of basal joint arthritis of the thumb. Part II. Ligament reconstruction with tendon interposition arthroplasty. *J Hand Surg Am.* 1986;11(3):324-32.
- Murley AH. Excision of the trapezium in osteoarthritis of the first carpometacarpal joint. *J Bone Joint Surg Am.* 1960;42:502-7.
- Dell PC, Muniz RB. Interposition arthroplasty of the trapeziometacarpal joint for osteoarthritis. *Clin Orthop Relat Res.* 1987;(220):27-34.
- Eaton RG, Lane LB, Littler JW, Keyser JJ. Ligament reconstruction for the painful thumb carpometacarpal joint: a long-term assessment. *J Hand Surg Am.* 1984;9(5):692-9.
- Vermeulen GM, Brink SM, Sluiter JBA, Elias MGS, Hovius RES, Moojen TM. Ligament reconstruction arthroplasty for primary thumb carpometacarpal osteoarthritis (Weilby Technique): prospective cohort study. *J Hand Surg Am.* 2009;34:1393-401.
- Davis TR, Brady O, Dias JJ. Excision of the trapezium for osteoarthritis of the trapeziometacarpal joint: a study of the benefit of ligament reconstruction or tendon interposition. *J Hand Surg Am.* 2004;29(6):1069-77.
- Hartigan JB, Stern PJ, Kiefhaber TR. Thumb carpometacarpal osteoarthritis: arthrodesis compared with ligament reconstruction and tendon interposition. *J Bone Joint Surg Am.* 2001;83(10):1470-8.
- Tomaino MM. Ligament reconstruction tendon interposition arthroplasty for basal joint arthritis. Rationale, current technique, and clinical outcome. *Hand Clin.* 2001;17(2):207-21.
- Da Rin F, Mathoulin C. Arthroscopic treatment of osteoarthritis of scaphotrapezotrapezoid joint. *Chir Main.* 2006;25 Suppl 1:S254-8.
- Thompson JS. Suspensionplasty. *J Orthop Surg Tech.* 1989;4:1-13.
- Beckenbaugh RD, Klawitter J, Cook S. Osseointegration and mechanical stability of pyrocarbon and titanium hand implants in a load-bearing in vivo model for small joint arthroplasty. *J Hand Surg Am.* 2006;31(7):1240-1.
- Nuñez VA, Citron ND. Short-term results of the Ascension pyrolytic carbon metacarpophalangeal joint replacement arthroplasty for osteoarthritis. *Chir Main.* 2005;24(3-4):161-4.

16. Szalay G, Schleicher I, Alt V, Pavlidis T, Schnettler R. Operative treatment of rhizarthritis: comparison of ligament reconstruction according to Epping with trapezectomy and interposition of pyrocarbon spacers as replacement of the trapezium. *Orthopade*. 2011;40(3):237-46.
17. Gervis WH. Excision of the trapezium in osteoarthritis of the trapezio-metacarpal joint. *J Bone Joint Surg Br*. 1949;31(4):537-9.
18. Iyer KM. The results of excision of the trapezium. *Hand*. 1981;13(3):246-50.
19. Colegate-Stone TJ, Garg S, Subramanian A, Mani GV. Outcome analysis of trapezectomy with and without pyrocarbon interposition to treat primary arthrosis of the trapeziometacarpal joint. *Hand Surg*. 2011;16(1):49-54.
20. Daecke W, Veyel K, Wieloch P, Jung M, Lorenz H, Martini AK. Osseointegration and mechanical stability of pyrocarbon and titanium hand implants in a load-bearing in vivo model for small joint arthroplasty. *J Hand Surg Am*. 2006;31(1):90-7.