

# Preoperative diagnosis of cavernous hemangioma presenting with melena using wireless capsule endoscopy of the small intestine

## Authors

Yu Akazawa<sup>1</sup>, Katsushi Hiramatsu<sup>1</sup>, Takuto Nosaka<sup>1</sup>, Yasushi Saito<sup>1</sup>, Yoshihiko Ozaki<sup>1</sup>, Kazuto Takahashi<sup>1</sup>, Tatsushi Naito<sup>1</sup>, Kazuya Ofuji<sup>1</sup>, Hidetaka Matsuda<sup>1</sup>, Masahiro Ohtani<sup>1</sup>, Tomoyuki Nemoto<sup>1</sup>, Hiroyuki Suto<sup>1</sup>, Akio Yamaguchi<sup>2</sup>, Yoshiaki Imamura<sup>3</sup>, Yasunari Nakamoto<sup>1</sup>

## Institutions

<sup>1</sup> Second Department of Internal Medicine  
<sup>2</sup> First Department of Surgery, Faculty of Medical Sciences, Fukui University  
<sup>3</sup> Division of Surgical Pathology, University of Fukui Hospital, Fukui, Japan

submitted 26. October 2016  
accepted after revision 9. December 2015

## Bibliography

DOI <http://dx.doi.org/10.1055/s-0041-111321>  
Published online: 4.2.2016  
Endoscopy International Open 2016; 04: E249–E251  
© Georg Thieme Verlag KG  
Stuttgart · New York  
E-ISSN 2196-9736

## Corresponding author

**Yasunari Nakamoto, MD, PhD**  
Second Department of Internal Medicine  
Faculty of Medical Sciences,  
Fukui University  
23-3 Matsuoka Shimoaizuki,  
Eiheiji-cho, Yoshida-gun  
Fukui 910-1193  
Japan  
Phone: +81-776-61-8351  
Fax: +81-776-61-8110  
nakamoto-med2@med.u-fukui.ac.jp

**Background and study aims:** Primary neoplasms of the small intestine are relatively rare in all age groups, accounting for about 5% of all gastrointestinal tumors [1]. Cavernous hemangiomas of the small intestine are also rare, can cause gastrointestinal bleeding, and are extremely difficult to

diagnose preoperatively [2]. We present a patient who presented with melena and iron deficiency anemia, for whom wireless capsule endoscopy and single-balloon enteroscopy facilitated the diagnosis of cavernous hemangioma.

## Introduction

Cavernous hemangioma of the small intestine is a rare disease. Because hemangiomas can cause massive gastrointestinal bleeding, emergency surgery may be required; however, the preoperative diagnosis of these growths is difficult. Here, we report a case of cavernous hemangioma of the small intestine that was diagnosed using wireless capsule endoscopy and single-balloon enteroscopy. Our patient presented with melena and iron deficiency anemia. Neither gastroscopy nor colonoscopy detected any remarkable findings. Thus, we performed wireless capsule endoscopy and single-balloon enteroscopy, which revealed a blue submucosal lesion (length, 2 cm) with a small red spot on its surface in the distal jejunum. Accordingly, we diagnosed the lesion as a cavernous hemangioma. Laparoscopic-assisted small intestinal resection was performed successfully. This case highlights the usefulness of wireless capsule endoscopy of the small intestine as a diagnostic tool for preoperative detection of the causes of obscure gastrointestinal bleeding, including cavernous hemangioma of the small intestine.

symptoms persisted, she was referred and admitted to our hospital for further evaluation 50 days after her first visit to her local hospital. The woman had a history of surgery for uterine fibroid tumors and appendicitis. Furthermore, she had been receiving treatment for articular rheumatism at her local hospital. She had not been taking nonsteroidal anti-inflammatory or antiplatelet drugs.

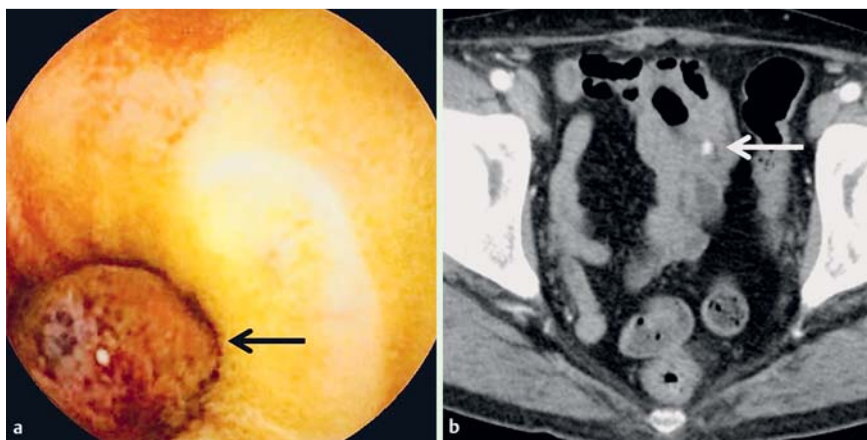
On admission, physical examination of the patient revealed pale conjunctivae. A clinical examination of the abdomen did not detect any pain, masses, or vascular bruits. However, laboratory analysis revealed marked anemia (hemoglobin, 6.7 g/dL), and low serum iron and ferritin levels. The patient received a blood transfusion, and her hemoglobin levels improved (> 10 g/dL). An investigation of her small intestine was performed using a wireless capsule endoscope, and an elevated red lesion was found in the jejunum (Fig. 1a). The lesion was not bleeding, and no other lesions were detected in the small intestine. On contrast-enhanced computed tomography, the mass (diameter, 2 cm) showed enhancement and was located in the pelvic region of the small intestine (Fig. 1b). Single-balloon enteroscopy performed using an antegrade approach revealed that the lesion was located in the distal jejunum, 1.5 m from Treitz's ligament. It was approximately 2 cm in diameter, appeared to be a submucosal tumor, and was blue with superficial red spots (Fig. 2). Based on the findings from wireless capsule endoscopy and single-balloon enteroscopy, we diagnosed the lesion as a cavernous hemangioma.

## Case Report

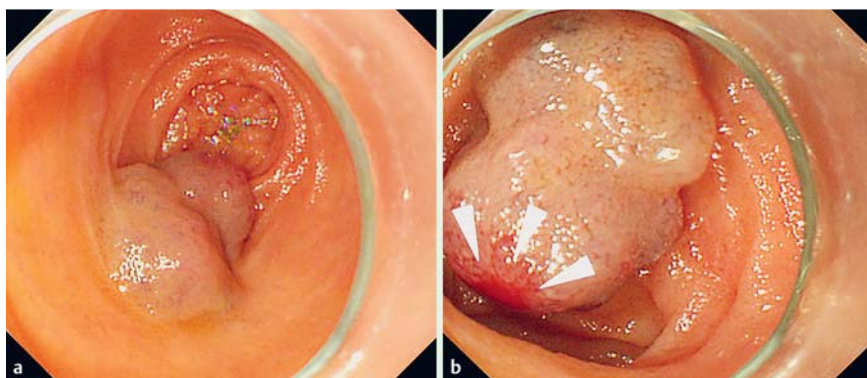
A 56-year-old woman visited her local hospital because of worsening fatigue and melena that had persisted for a week. Gastroscopy and colonoscopy were performed but no active bleeding or lesions were detected. Because the patient's

## License terms

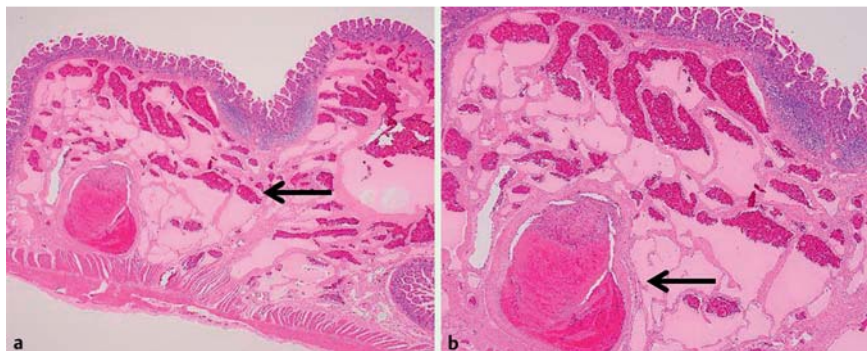




**Fig. 1** a Wireless capsule endoscopy showing a reddish elevated lesion in the jejunum (black arrow). b Contrast-enhanced computed tomography of the abdomen and pelvis showing the mass exhibiting enhancement (white arrow).



**Fig. 2** Images of the Single-balloon enteroscopy. a The lesion showed a blue submucosal tumor. b The tumor had a red spot on the surface (arrow heads).



**Fig. 3** Histologic image of the surgically resected tumor specimen. a The tumor was composed of numerous dilated, blood-filled vessels within the submucosal layer (black arrow) (hematoxylin-eosin stain,  $\times 20$ ). b Some vessels displayed thrombotic phenomena (black arrow) (hematoxylin-eosin stain,  $\times 40$ ).

On the 20th hospital day, laparoscopy-assisted small intestinal resection was performed with jejuno-jejunal reanastomosis. Macroscopic examination of the resected specimen revealed that the lesion measured  $1.3 \times 1.0$  cm and was elastic, soft, and purplish-blue. Pathological examination showed vascular proliferation within the submucosa; that is, large, dilated, blood-filled vessels lined by flattened endothelia (some of which displayed thrombotic phenomena) were observed (► **Fig. 3**). The histological diagnosis was cavernous hemangioma of the small intestine. Postoperatively, the patient recovered well and her symptoms have not recurred.

## Discussion

Cavernous hemangioma of the small intestine is a rare disease, accounting for 5% to 10% of all small-bowel benign neoplasms [3]. Hemangioma accounted for 19 cases of 676 small intestinal tumors reported between January 1995 and December 1999 [4]. Of 144 cases of small intestinal tumors detected with double-bal-

loon endoscopy between September 2000 and December 2005, hemangiomas were identified in 3 cases [5]. Although it is an uncommon cause of gastrointestinal bleeding, hemangioma of the small bowel often leads to the development of acute hemorrhage [6] or chronic anemia [7].

We retrieved from the PUBMED and i-chu-shi (Japan) databases reports of cavernous hemangiomas presenting with gastrointestinal bleeding that were published beginning in 2000; 46 cases (22 women, 24 men; mean age, 34.6 years) were retrieved and reviewed. The most common site of small intestinal hemangiomas was the jejunum (46%), and melena was observed in 65% of the cases. The mean diameter of the lesions was 2.93 cm. Twenty-two of the 46 lesions (48%) were diagnosed preoperatively (► **Table 1**) [2, 3, 7, 8]. Of these cases, seven were detected with capsule endoscopy and 10 were diagnosed using balloon enteroscopy. Compared with the cases reported before 2000, a markedly increased proportion of cases were diagnosed preoperatively using capsule endoscopy and balloon enteroscopy from 2000 onward. According to the algorithms for the diagnosis and treatment of obscure gastrointestinal bleeding proposed by the American Gas-

**Table 1** Reports since 2000 on preoperative diagnosis of small intestinal cavernous hemangiomas.

Author, Year	Age (years)	Sex	Symptom	Preoperative diagnosis examination	Hemangioma size (cm)	Hemangioma location	Treatment
Shimizu et al., 2006	44	M	Melena	Computed tomography	2.0	Ileum	Laparotomy
Fukumura et al., 2006	9	F	Anemia	Colon endoscopy	1.0	Multiple	Laparotomy
Zeng et al., 2008	21	M	Abdominal pain	Computed tomography	2.2	Jejunum	Laparotomy
Deng et al., 2008	6	M	Melena	Balloon enteroscopy	1.0	Multiple	Conservative treatment
Deng et al., 2008	6	M	Melena	Balloon enteroscopy	1.0	Multiple	Conservative treatment
Deng et al., 2008	7	M	Melena	Balloon enteroscopy	1.0	Multiple	Conservative treatment
Willert et al., 2008 [3]	19	M	Anemia	Capsule endoscopy + balloon enteroscopy	1.4	Multiple	Endoscopic treatment
Pinho et al., 2009 [2]	9	F	Anemia	Capsule endoscopy	2.5	Ileum	NA
Tsutsui et al., 2009	40	F	Anemia	Balloon enteroscopy	5.0	Jejunum	Laparotomy
Morita et al., 2009	69	M	Anemia	Capsule endoscopy + balloon enteroscopy	0.5	Ileum	Laparoscopic operation
Sakoda et al., 2009	40	F	Melena	Computed tomography	6.0	Jejunum	NA
Endo et al., 2009	49	F	Melena	Small intestinal imaging	1.2	Multiple	Endoscopic treatment
Takayama et al., 2010	71	F	Abdominal pain	Computed tomography	3.0	Ileum	Laparotomy
Abdul Aziz et al., 2011	6	F	Abdominal pain	Ultrasonography	15	Ileum	Laparotomy
Rodriguez-Zentner et al., 2011	46	M	Anemia	Colon endoscopy	2.3	Ileum	Laparoscopic operation
Mikami et al., 2011	45	F	Melena	Capsule endoscopy + balloon enteroscopy	0.9	Multiple	Endoscopic treatment
Pera et al., 2012 [7]	16	M	Anemia	Capsule endoscopy + balloon enteroscopy	4.2	Jejunum	Laparoscopic operation
Guardiola et al., 2012	19	M	Melena	Capsule endoscopy	1.0	Ileum	Laparoscopic operation
Miyamoto et al., 2012	61	F	Anemia	Computed tomography	4.0	Ileum	Laparotomy
Dhumane et al., 2013 [8]	60	M	Anemia	Capsule endoscopy + balloon enteroscopy	7.0	Jejunum	Laparoscopic operation
Tanioka T et al., 2013	16	F	Anemia	Balloon enteroscopy	1.5	Jejunum	Laparoscopic operation
Sato M et al., 2013	9	F	Abdominal pain	Computed tomography	2.5	Jejunum	Laparotomy
Our case, 2013	56	F	Melena	Capsule endoscopy + balloon enteroscopy	1.3	Jejunum	Laparoscopic operation

M, male; F, female; NA, not available

troenterological Association in 2007, capsule endoscopy should be used for the initial examination. When positive findings are acquired, balloon enteroscopy should be performed [9]. In the current case, capsule endoscopy and balloon enteroscopy were performed based on these guidelines, and we were able to detect the characteristic findings of cavernous hemangioma, e.g., a blue submucosal lesion with a bleeding spot on its surface. Regarding the treatment of bleeding hemangiomas, most of the previous cases were treated surgically [10]. Endoscopic treatment was performed in only three cases. One of the hemangiomas was clipped, another was subjected to sclerotherapy, and the third was removed by means of snare polypectomy [3]. In these three cases, bleeding occurred frequently, and the multiple lesions were relatively small. In our case, we did not perform endoscopic treatment because active bleeding was not present at that time, and there seemed to be a risk for massive bleeding after endoscopic treatment. Future studies are needed to determine the indications for endoscopic treatment. In conclusion, we encountered a case of cavernous hemangioma of the small intestine that was diagnosed preoperatively using wireless capsule endoscopy. Capsule endoscopy is clearly useful for preoperative diagnosis of hemangiomas in the small intestine.

**Competing interests:** None

## References

- 1 de Mascarenhas-Saraiva M, da Silva Araújo Lopes LM. Small-bowel tumors diagnosed by wireless capsule endoscopy: report of five cases. *Endoscopy* 2003; 35: 865–868
- 2 Pinho R, Rodrigues A, Proenca L et al. Solitary hemangioma of the small bowel disclosed by wireless capsule endoscopy. *Gastroenterol Clin Biol* 2008; 32: 15–18
- 3 Willert RP, Chong AK. Multiple cavernous hemangiomas with iron deficiency anemia successfully treated with double-balloon enteroscopy. *Gastrointest Endosc* 2008; 67: 765–767
- 4 Yao T, Yao T, Furukawa K et al. Primary small intestinal tumors. *Stom Intest* 2001; 36: 871–881
- 5 Mitsui K, Tanaka S, Yamamoto H et al. Role of double-balloon endoscopy in the diagnosis of small-bowel tumors: the first Japanese multi-center study. *Gastrointest Endosc* 2009; 70: 498–504
- 6 Ohira S, Hasegawa H, Ogiso S et al. A case of hemangioma of the small intestine in which the region could be diagnosed preoperatively. *Nihon Shokakibyo Gakkai Zasshi* 2003; 100: 166–169
- 7 Pera M, Márquez L, Dedeu JM et al. Solitary cavernous hemangioma of the small intestine as the cause of long-standing iron deficiency anemia. *J Gastrointest Surg* 2012; 16: 2288–2290
- 8 Dhumane P, Mutter D, D'Agostino J et al. Small bowel exploration and resection using single-port surgery: a safe and feasible approach. *Colorectal Dis* 2013; 15: 109–114
- 9 Raju GS, Gerson L, Das A et al. American Gastroenterological Association (AGA) Institute technical review on obscure gastrointestinal bleeding. *Gastroenterology* 2007; 133: 1697–1717
- 10 Khurana V, Dala R, Barkin JS. Small bowel cavernous hemangioma. *Gastrointest Endosc* 2004; 60: 96