

## Case Report

# Sildenafil Citrate: Novel Therapy in the Management of Ovarian Torsion

Kedar N. Ganla, Rana A. Choudhary, Priyanka H. Vora, Umesh V. Athavale<sup>1</sup>

Department of Reproductive Medicine, Ankoor Fertility Clinic, 'Athavale Imaging Centre, Mumbai, Maharashtra, India

ABSTRACT

Ovarian torsion is defined as partial or complete rotation of ovarian vascular pedicle, leading to the obstruction of venous outflow and arterial inflow. It is an emergency condition with an incidence of 2%–15% in patients with adnexal masses. The main risk in ovarian torsion is an ovarian mass or an enlarged ovary with a long pedicle. Due to the rotation of ovarian tissue axis on its vascular pedicle, there is compression of vessels followed by stromal edema, hemorrhagic infarction, and necrosis of adnexa. Expedient diagnosis poses a difficult challenge because clinical presentation is a variable and often misleading. We report a case of right ovarian torsion after oocyte retrieval for *in vitro* fertilization, where vaginal sildenafil citrate was successfully used to reduce ovarian edema by improving venous drainage. It also helped in maintaining ovarian tissue perfusion and preventing reperfusion injury and spontaneous detorsion of the ovary without any surgical intervention.

**KEYWORDS:** Antioxidant, detorsion, edema, ovarian torsion, reperfusion injury, sildenafil citrate

## INTRODUCTION

With the introduction of ovulation induction and *in vitro* fertilization (IVF), the incidence of ovarian torsion has increased, as ovaries become enlarged and rise from the pelvis into the abdomen. The diagnosis of ovarian torsion after oocyte retrieval is challenging as symptoms are nonspecific. The IVF specialist needs to salvage the twisted ovary in addition to considering fate of contralateral ovary and future fertility.

## CASE REPORT

A 29-year-old woman underwent ovulation induction using antagonist and freeze all protocol for IVF. She received recombinant follicle-stimulating hormone (Recagon) 300 IU subcutaneously for 10 days. Injection ganirelix 0.25 mg (orgalutran) was added from the 5<sup>th</sup> day. Injection triptorelin (decapeptyl) 0.2 mg subcutaneously was given for final maturation of oocytes and oocyte retrieval done after 34–35 h. Eighteen oocytes were retrieved. The procedure was uneventful, and she was discharged on the same day.

Four days after oocyte retrieval, the patient came with sudden onset of severe right-sided abdominal pain. On examination, there was right lower abdomen tenderness and guarding. She was admitted and injectable hyoscine butylbromide (buscopan) was given, but there was no relief. Abdominal and transvaginal ultrasound showed that both ovaries were enlarged, right more than the left-right ovary: 9.1 cm × 7.1 cm × 8.5 cm (vol = 250 cc) and left ovary: 7.1 cm × 4.0 cm × 5.1 cm (vol. = 130 cc) [Figure 1].

Color Doppler imaging showed a significant reduction in blood supply of the right ovary while the left ovary had normal blood supply, suggestive of right ovarian torsion [Figure 2a and b].

As the patient came to our clinic within 2 h of experiencing symptoms and was diagnosed within the next few hours, the decision to use vaginal

**Address for correspondence:** Dr. Rana A. Choudhary, 2501, A – Wing, Klassic Towers, Dr. A. R. Nair Road, Agripada, Mumbai - 400 011, Maharashtra, India. E-mail: dr.ranakhan@gmail.com

Received: 10-04-2019

Revised: 25-06-2019

Accepted: 01-11-2019

Published: 17-12-2019

### Access this article online

Quick Response Code:



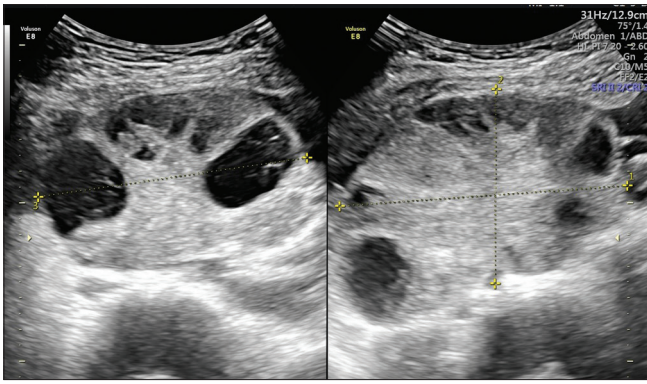
Website:  
www.jhrsonline.org

DOI:  
10.4103/jhrs.JHRS\_52\_19

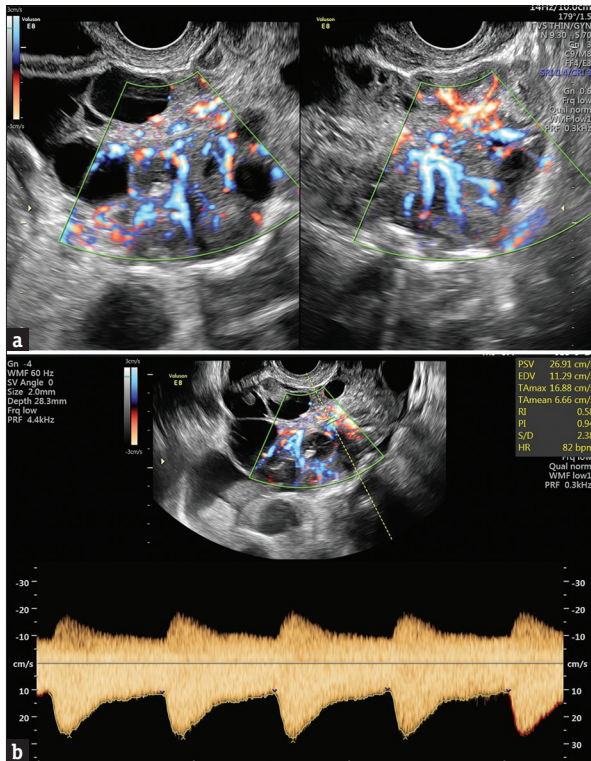
This is an open access journal, and articles are distributed under the terms of the Creative Commons Attribution-NonCommercial-ShareAlike 4.0 License, which allows others to remix, tweak, and build upon the work non-commercially, as long as appropriate credit is given and the new creations are licensed under the identical terms.

For reprints contact: reprints@medknow.com

**How to cite this article:** Ganla KN, Choudhary RA, Vora PH, Athavale UV. Sildenafil Citrate: Novel Therapy in the management of ovarian torsion. J Hum Reprod Sci 2019;12:351-4.

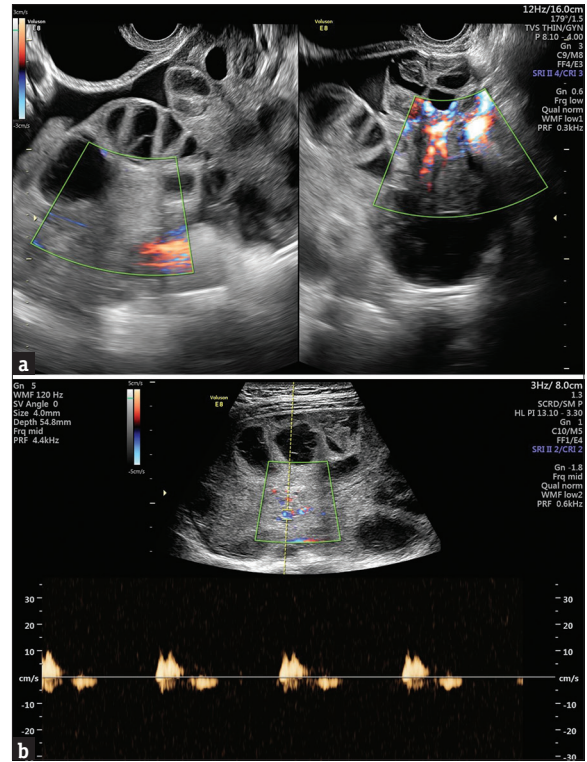


**Figure 1:** Postovocyte retrieval (day 4) ultrasonography showing significantly enlarged right ovary as compared to the left ovary

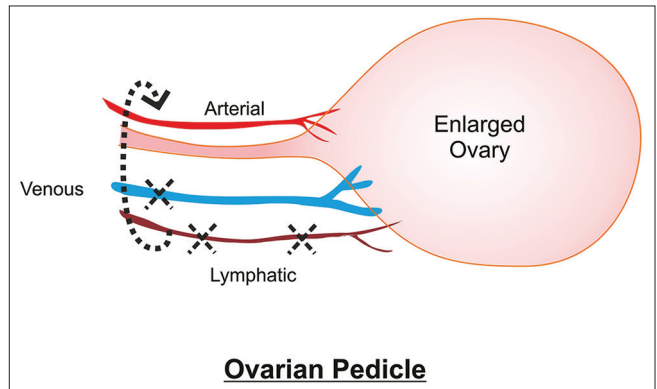


**Figure 3:** (a) Ultrasound colour doppler 24 h after starting sildenafil citrate showing decrease in volume of right ovary with improvement of ovarian blood supply. (b) Doppler ultrasonography showing restoration of ovarian blood flow and spontaneous detorsion

sildenafil citrate was taken with the consent of patient and her guardian. We attempted to improve venous drainage of the twisted ovary along with maintaining its perfusion using vaginal sildenafil citrate (25 mg 8 hourly). Antispasmodic (hyoscine butylbromide) and antibiotics were continued while the patient was kept fasting for an emergency detorsion surgery if required. The patient responded to medical therapy, and her symptoms improved markedly. A repeat ultrasonography (USG) Doppler done after 24 h showed a significant reduction in right ovarian volume (170 cc) along with the restoration



**Figure 2:** (a) Ultrasound colour doppler showing (day 4) of post ovocyte retrieval showing enlarged right ovary with reduction in vascularity. (b) Ultrasound doppler showing reduction in vascularity (torsion of the right ovary)



**Figure 4:** Mechanism of torsion

of ovarian blood supply [Figure 3a and b]. These findings were suggestive of reduction in edema of the right ovary due to better venous drainage leading to reduction in size of the ovaries and possibly reversal of torsion of the right ovary. This could be due to Sildenafil-mediated increase in nitric oxide (NO) bioavailability and sensitivity, causing increase in cGMP and relaxation of endothelial smooth muscles of vessels. As the patient presented with severe right-sided abdominal pain and USG suggestive of the right ovarian torsion, these symptoms could not be due to ovarian hyperstimulation syndrome (OHSS);

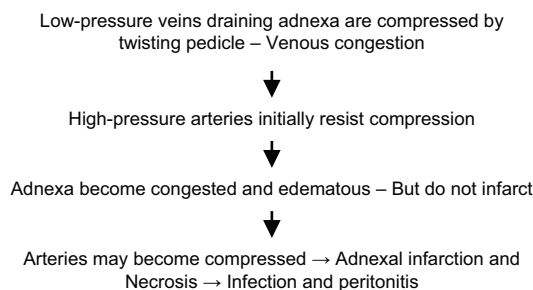
further she responded symptomatically to sildenafil citrate and repeat Doppler confirmed restoration of the blood supply of the right ovary. Patient was continued on vaginal sildenafil citrate for 3 days and recovered completely without the need for surgical intervention.

## DISCUSSION

Ovarian torsion is the fifth common gynecological emergency.<sup>[1-3]</sup> Torsion of the hyperstimulated ovary is much rarer.<sup>[1,4]</sup> It is commonly seen in young women between 20 and 30 years of age with right ovary being more commonly affected, as sigmoid colon leaves limited space on the left.<sup>[1]</sup> Predisposing factors are ovarian enlargement, adnexal masses, ovulation induction, and pregnancy. Kemmann *et al.* reported an incidence of 1 in 1730 in patients with ovulation induction and higher risk in women with OHSS.<sup>[4,5]</sup>

The classical presentation in ovarian torsion is sharp localized lower abdominal pain and tenderness with occasionally a palpable mass and peritoneal signs. USG shows an enlarged ovary with an increase in volume by multiple times.<sup>[1,4]</sup> Hallmark characteristics on USG Doppler include the complete absence of blood flow in a morphologically abnormal ovary.<sup>[3]</sup> Although the classic finding is absent arterial flow, most frequent finding is decreased or absent venous flow due to early collapse of venous vessels as arterial supply is maintained due to resistant vessel wall, as was seen in our patient<sup>[5]</sup> [Figure 4].

Reduction in venous outflow causes congestion in ovarian tissue leading to increase in ovarian volume. In our patient, vaginal sildenafil citrate was started when the arterial supply was still maintained. Sildenafil citrate increased venous return of twisted ovarian pedicle and hence lead to reduction of ovarian edema and volume. Prolonged torsion can lead to arterial thrombosis and adnexal infarction as explained in Flowchart 1. There is increase in reactive oxygen species (ROS) such as superoxide ( $O_2^-$ ), hydrogen peroxide ( $H_2O_2$ ), reactive nitrogen species, and hydroxyl-free radical ( $H_2O_2$ ).<sup>[6,7]</sup> These ROS and their by-products damage the



**Flowchart 1:** Pathophysiology of torsion

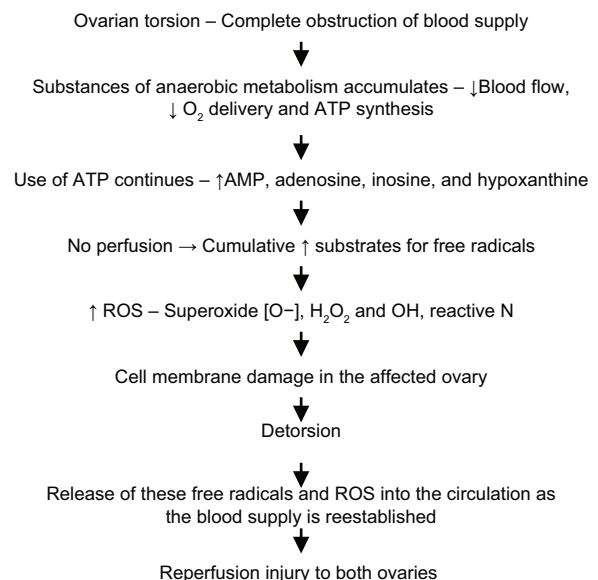
cell membrane of the ovarian tissue.<sup>[6,7]</sup> With detorsion, there is reperfusion, which causes further damage to both ovaries due to the release of these accumulated ROS as explained in Flowchart 2.<sup>[2,7,8]</sup>

Animal model study by Arikan *et al.* in a rat model showed significant decrease in ovarian tissue damage and increase in NO levels after use of tadalafil.<sup>[8]</sup> This was supported by a significant decrease in tissue malondialdehyde levels and increase in tissue catalase and superoxide dismutase activities. Other phosphodiesterase-5 inhibitor Sildenafil citrate, by its antioxidant properties as demonstrated by animal model studies by Filho *et al.* and Shimizu *et al.* in testicular torsion has the potential to reduce accumulation of ROS and prevent tissue damage due to reperfusion injury<sup>[2,7-10]</sup> [Figure 5].

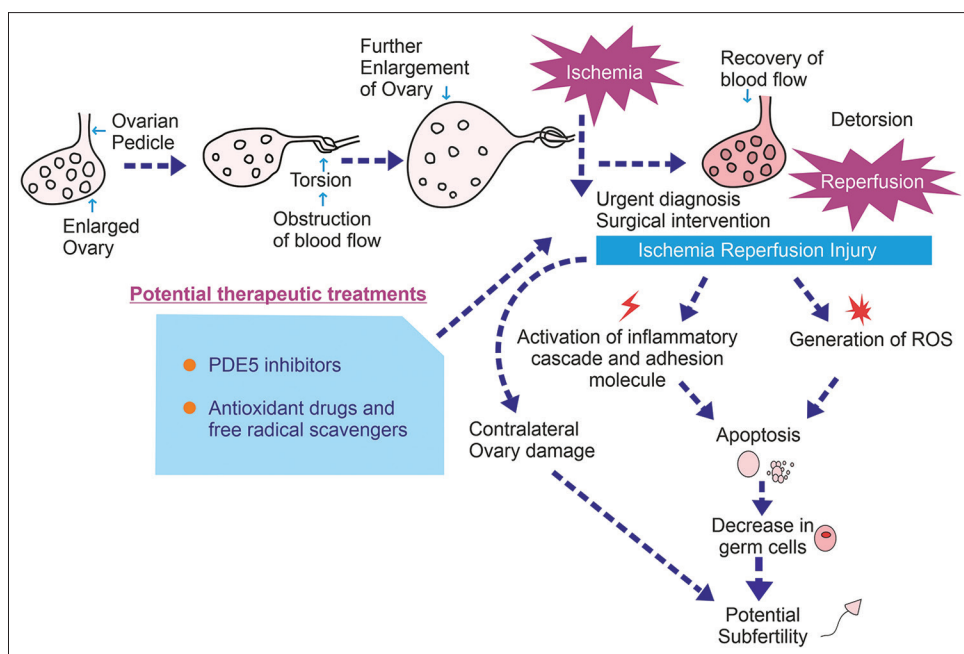
However it is important to note that Sildenafil cannot replace surgical intervention once it is indicated, and the decision whether to proceed with laparoscopy is solely based on the patient's clinical condition. Sildenafil treatment can be suggested only in cases where observation is possible, and even in the final event of laparoscopy, sildenafil treatment can be used as an adjunct to reduce tissue damage by preventing reperfusion injury in the ovaries.

## CONCLUSION

Ovarian enlargement following controlled ovarian stimulation (COS) during *In vitro* fertilisation (IVF) treatment is a risk for developing adnexal torsion. Early diagnosis and prompt intervention is needed to protect the ovaries and preserve future fertility. Medical management in the form of vaginal sildenafil citrate may be useful in selected cases by



**Flowchart 2:** Mechanism of reperfusion injury in torsion



**Figure 5:** Role of sildenafil citrate in the prevention of reperfusion injury

improving venous drainage, tissue perfusion, and decreasing tissue damage by preventing reperfusion injury. This case defines the importance of awareness, early diagnosis, and a novel intervention, (vaginal sildenafil citrate) to preserve the ovarian integrity.

#### Declaration of patient consent

The authors certify that they have obtained all appropriate patient consent forms. In the form the patient(s) has/have given his/her/their consent for his/her/their images and other clinical information to be reported in the journal. The patients understand that their names and initials will not be published and due efforts will be made to conceal their identity, but anonymity cannot be guaranteed.

#### Financial support and sponsorship

Nil.

#### Conflicts of interest

There are no conflicts of interest.

#### REFERENCES

- Chang HC, Bhatt S, Dogra VS. Pearls and pitfalls in diagnosis of ovarian torsion. *Radiographics* 2008;28:1355-68.
- Incebiyik A, Seker A, Camuzcuoglu H, Kocaslan S, Camuzcuoglu A, Hilali NG, *et al.* Does sildenafil have protective effects against ovarian ischemia-reperfusion injury in rats? *Arch Gynecol Obstet* 2015;291:1283-8.
- Michele B, Giovanni S, Paolo T, Roberta Z, Vincenzo M. Adnexal torsion. *Ultrasound Clin* 2008;3:109-19.
- Chew S, Ng SC. Laparoscopic treatment of a twisted hyperstimulated ovary after IVF. *Singapore Med J* 2001;42:228-9.
- Kemmann E, Ghazi DM, Corsan GH. Adnexal torsion in menotropin-induced pregnancies. *Obstet Gynecol* 1990;76:403-6.
- Kang HJ, Davis OK, Rosenwaks Z. Simultaneous bilateral ovarian torsion in the follicular phase after gonadotropin stimulation. *Fertil Steril* 2006;86:462.e13-4.
- Filho DW, Torres MA, Bordin AL, Crezcynski-Pasa TB, Boveris A. Spermatic cord torsion, reactive oxygen and nitrogen species and ischemia-reperfusion injury. *Mol Aspects Med* 2004;25:199-210.
- Arikan DC, Bakan V, Kurutas EB, Sayar H, Coskun A. Protective effect of tadalafil on ischemia/reperfusion injury of rat ovary. *J Pediatr Surg* 2010;45:2203-9.
- Shimizu S, Tsounapi P, Dimitriadis F, Higashi Y, Shimizu T, Saito M, *et al.* Testicular torsion-detorsion and potential therapeutic treatments: A possible role for ischemic preconditioning. *Int J Urol* 2016;23:454-63.
- Huang C, Hong MK, Ding DC. A review of ovary torsion. *Ci Ji Yi Xue Za Zhi* 2017;29:143-7.