



Knot free technique for Laparoscopic Ventral Mesh Rectopexy



Hammad Zaidi*, Ajay Gupta, Niraj Khetan, Khalid Habib

Doncaster and Bassetlaw Hospitals NHS Trust, UK

HIGHLIGHTS

- A systematic search of the literature was done to find out alternate ways to fix the mesh over the anterior surface of rectum.
- Instead of using normal intra-corporeal or extra-corporeal suturing, a novel technique was used to secure the Ethibond 2/0 suture using endo clip.
- The Technique provides alternate way of securing the suture in laparoscopic mesh rectopexy.

ARTICLE INFO

Article history:

Received 11 February 2017

Received in revised form

29 May 2017

Accepted 30 May 2017

Keywords:

Knot free
Laparoscopic
Ventral
Mesh
Rectopexy

ABSTRACT

Aim: The aim of our study was to describe and assess a new method of mesh fixation using clips in Laparoscopic Ventral Mesh Rectopexy (VMR). This technique avoids knots while suturing in pelvis and saves time.

Method: A systematic search of the literature (PUBMED, EMBASE) was done to find out alternate ways to fix the mesh over the anterior surface of rectum. This technique has not been used before. We performed five operations using this technique. Indication for surgery was full thickness rectal prolapse in all of them. Majority of patients were female (four) and one was male with age range of 32–69 years. Two patients had previous abdominal surgery. Laparoscopic access included four ports and 30° scope in all cases. Biological mesh was used in 4 cases and synthetic in remaining one. Instead of using normal intra-corporeal or extra-corporeal suturing, a novel technique was used to secure the Ethibond 2/0 suture using endo clip. The mesh fixation to sacral promontory was done with tacker.

Results: These patients were prospectively followed up to assess the effectiveness of repair and to assess for the recurrence. The median follow up so far is 8 months (range 5–11). None of the patients had any major complication. No patient has reported recurrence either.

Conclusion: Our study with limitations of small group and relatively shorter follow up has proven to be a safe technique. This technique has a potential of replacing intra or extracorporeal knot with endo clips and requires less time compared to conventional suturing. It also advantage of having a minimal learning curve.

Crown Copyright © 2017 Published by Elsevier Ltd on behalf of IJS Publishing Group Ltd. This is an open access article under the CC BY-NC-ND license (<http://creativecommons.org/licenses/by-nc-nd/4.0/>).

1. Introduction

The definitive treatment of rectal prolapse is surgery; however the repair procedures and techniques are evolving [1,4].

Laparoscopic VMR is performed for patients with external rectal prolapse. It is also used in patients with symptoms of obstructive defecation who have an internal prolapse (Rectal intussusception). The VMR is the effective treatment in appropriately selected patients.

There is a trend towards using biological mesh in view of some reports of synthetic mesh erosions [2]. Stitching a biological mesh in the deep pelvis is difficult and time consuming [3].

This study is the first report of the new and easy technique for fixation of mesh in the ventral rectopexy procedure.

2. Materials and methods

A systematic search of the literature (PUBMED, EMBASE) was done to find out alternate ways to fix the mesh over the anterior surface of rectum. There are various techniques described in the literature. Our technique has not been used before.

We used this technique in the last five cases done between May

* Corresponding author. University Hospital of Coventry and Warwickshire NHS Trust, Clifford Bridge road, Coventry, CV2 2DX, UK.

E-mail address: h.zaidi@nhs.net (H. Zaidi).

to December 2015. All patients had full thickness rectal prolapse. The age range was 32–69 years. Two patients had previous abdominal surgery and one patient had family history of bowel cancer.

Demographics, results of imaging studies, morbidity were assessed as per case records and functional outcomes were prospectively followed.

2.1. Knot free technique

Lap VMR is relatively low risk surgery as no bowel is removed. The nerves are avoided and constipation only very rarely gets worse. However it involves suturing in narrow space in deep pelvis. This space is limited and requires higher intracorporeal knotting skills to fix the mesh [6]. A pocket is created between the lower rectum and vagina and the mesh is sutured on to the front of the rectum, whilst the other end is fixed to the sacrum.

The operation was performed under general anaesthetic. Four laparoscopic ports and 30° scope was used in all cases. Biological mesh was used in four cases and synthetic in remaining one. First procedure was performed with synthetic mesh but the mesh used in subsequent operations was biological mesh. The reason for change in use of mesh material was recent reports on mesh erosions using synthetic material (see Figs. 1–3).

Instead of using normal intra-corporeal or extra-corporeal suturing, a novel technique was used to secure the Ethibond 2/0 suture using endo clip. It also keeps the mesh flat and avoids folding on itself. The mesh fixation to sacral promontory was done with tackler.

The median operating time for surgery was 94 min IQR (Interquartile range) 80–134 min.

Knot free suturing was performed in our last 5 consecutive cases of VMR, It not only saves time but was also easy to perform. This technique saved us an average of 5–10min per knot compared to intra-corporeal methods as per our experience. There was an

additional advantage of simplicity of technique whilst working in deeper cavity i.e. narrow pelvis especially in males.

Procedure was performed laparoscopically with meticulous adhesiolysis to release small bowel loops if adherent on pelvic floor. This was intended to prevent the small bowel from returning to the pelvis.

During the operation, rectum was mobilized to one side. A mesh made of polypropylene in one case and biologic mesh in other four cases was sutured to the front of rectum. Suturing was performed using knot free technique.

The mesh was then fixed to sacrum using special tacks. This has the effect of pulling up the rectum and preventing it prolapsing downwards.

Care was taken to avoid suture entrapment of the ureters, iliac vessels and the pelvic nerves at the sacral promontory.

Note: Stepwise procedure description is illustrated with diagrams in photographs.

3. Results

Our case series comprised of five patients including one male and four females. Median age was 55 (Range 32–69). The common indication for all the patients was full thickness rectal prolapse. No undesirable effects were associated with the procedure. All patients were successfully completed laparoscopically. Patients stayed for median of 2 days (range 2–5).

The patients were followed for a median of 8 months (range 5–11). After a mean follow-up of 8 months no major morbidity or recurrence was recorded.

This technique requires less time compared to conventional suturing and has a minimal learning curve.

4. Discussion

Full thickness rectal prolapse is a challenging surgical problem

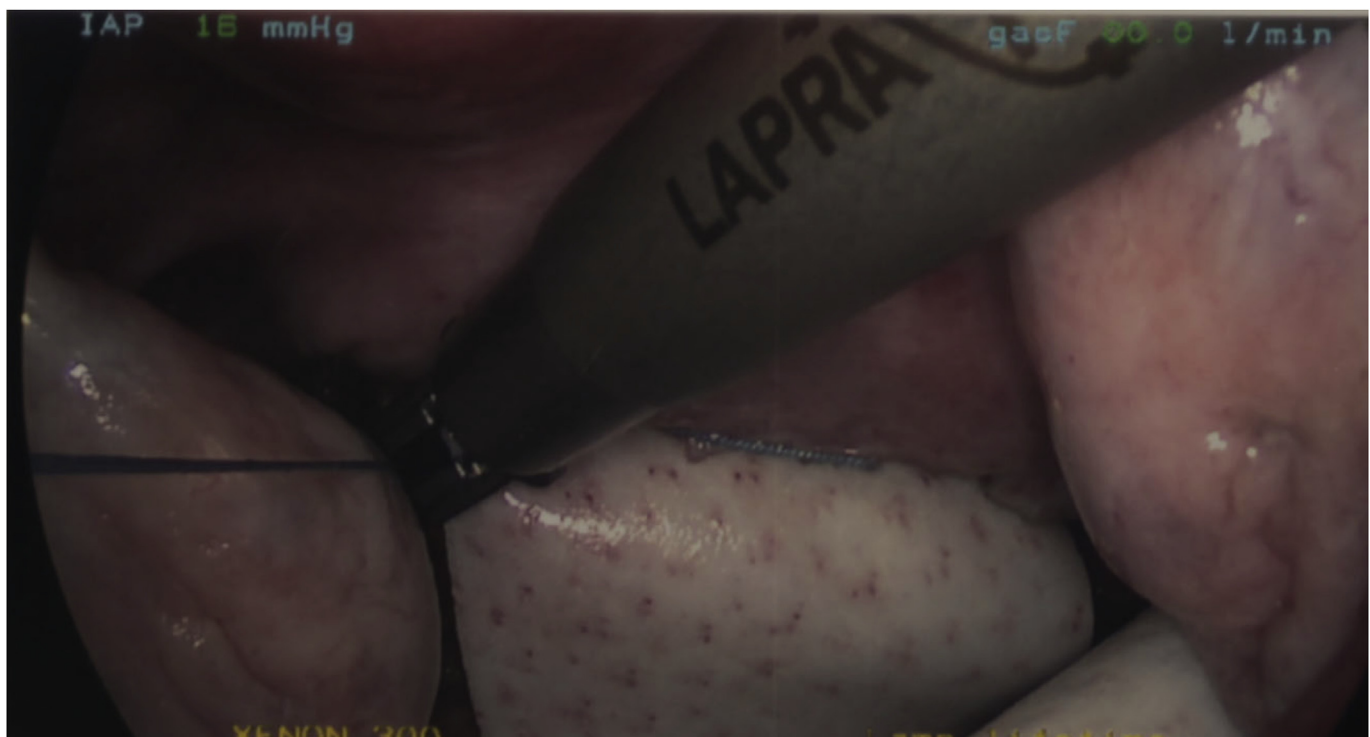

Fig. 1. An Ethibond 4/0 suture is passed using laparoscopic needle holder through the mesh anchoring the mesh to the rectum and then brought back in a u shaped manner. A clip is applied on two limbs of suture securing the mesh instead of traditional knot.

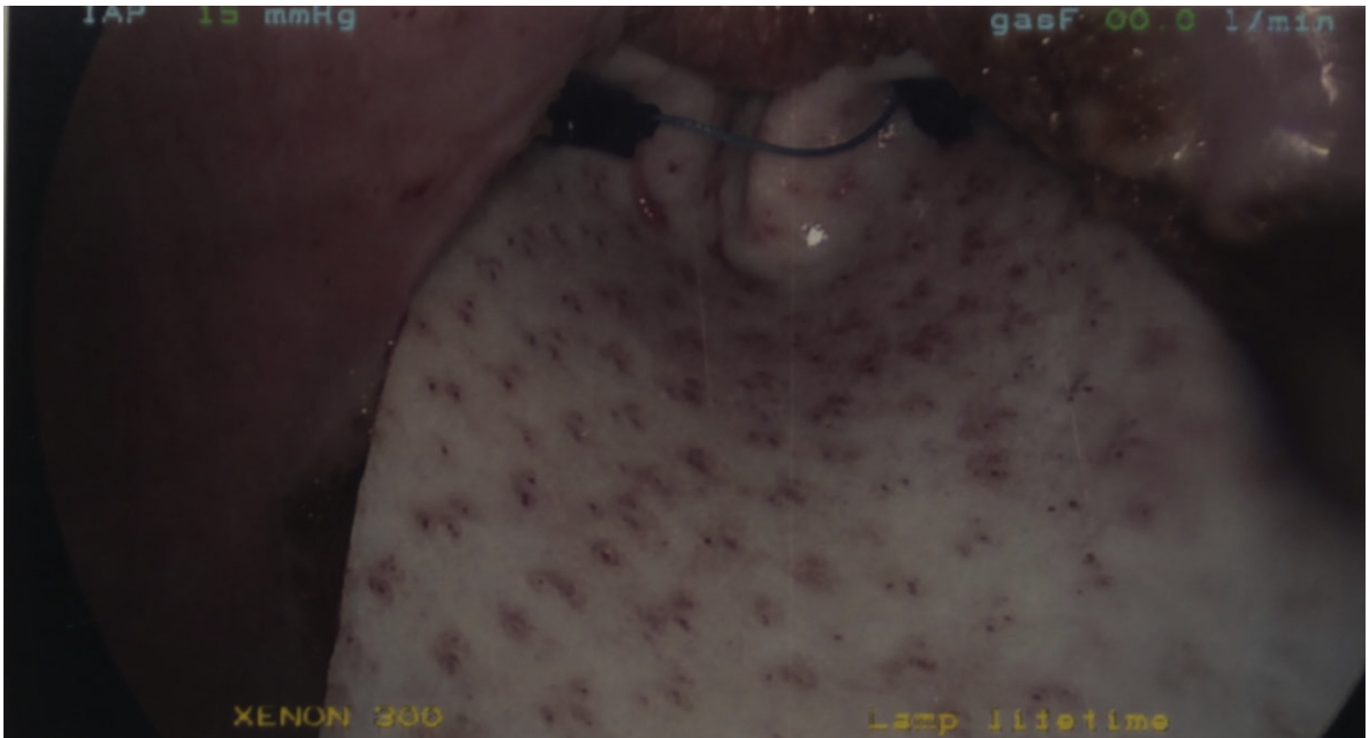


Fig. 2. Another suture is placed on the other side of mesh to complete distal row of sutures.

for decades. Different approaches have been used to tackle with the problem. There is no consensus on best surgical technique used to repair full thickness rectal prolapse. There is limited good quality evidence on surgical repair. More surgical options are being explored even in elderly patients because of advancement in

anesthetic techniques [7]. Laparoscopic VMR has gained popularity over last decade as a safe alternative technique and is associated with very low morbidity [1]. In the medium term, it provides good result for prolapse and associated symptoms. The suturing is difficult with current laparoscopic instruments as instruments are

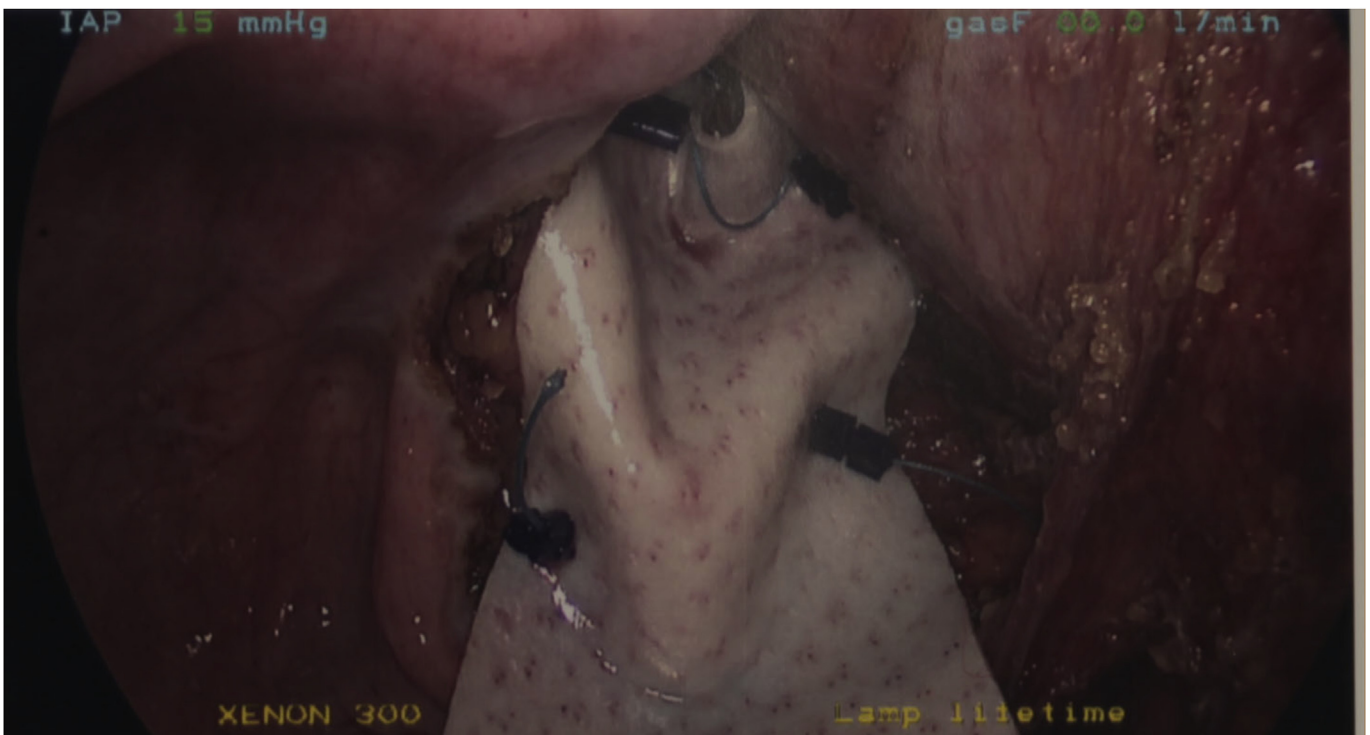

Fig. 3. Step 1 and 2 are repeated few centimetre above to complete proximal row of sutures.

parallel to each other in a narrow pelvic space. Various Techniques to suture the mesh in the pelvis have been described.

These include. 1-V-loc[®] 2-a new method of fixation using a self-adhesive prosthesis (Adhesix[™]) in laparoscopic VMR. 3- Extra corporeal knot technique.

There have been case reports of bowel obstruction after using V-loc[®] suture. The risk of bowel obstruction from the V-lock[®] following Laparoscopic VMR is not negated by burying or cutting its barbed end flush [5].

Our technique did not have any undesirable effects. This was a small series and was aimed to assess the feasibility for a larger study. It appeared to be a safe technique compared with other available techniques. It is easy to learn and there is a short learning curve. The problems with our study are small sample size and small follow up. As our experience is growing we aim to add more cases with longer median follow up in future. The functional outcome and recurrence in this study were assessed on clinical history and examination. We aim to get functional assessment of patients before and after surgery by performing anorectal physiology investigations in our future study.

Ethical approval

Clinical governance approval was obtained from local institution. As this was not research project, no ethical approval was required.

Sources of funding

Funding was not required for this project.

Author contribution

Hammad Zaidi, Doncaster and Bassetlaw Hospitals NHS trust.
Ajay Gupta, Doncaster and Bassetlaw Hospitals NHS trust.
Niraj Khetan, Doncaster and Bassetlaw Hospitals NHS trust.
Khalid Habib, Doncaster and Bassetlaw Hospitals NHS trust.

Conflicts of interest

I have no conflicts of interest.

Guarantor

Hammad Zaidi, University Hospitals of Coventry and Warwickshire NHS trust.

Research registration unique identifying number (UIN)

This was not required as this was not a research project.

Trial registry number – ISRCTN

Study was not a RCT.

Acknowledgements

This work was presented at the Association of Surgeons of Great Britain & Ireland (ASGBI) 2016 International Surgical Congress (Belfast May 11–13, 2016). H. Zaidi Department of General and Gastrointestinal Surgery, Doncaster Royal Infirmary, Armthorpe Road, Doncaster DN2 5LT, UK. E-mail:h.zaidi@nhs.net.

References

- [1] I. Lindsy, K. Nugent, T. Dixon, *Pelvic Floor Disorders for Colorectal Surgeon*, Oxford University Press, 2010.
- [2] Senapati A, et al. PROSPER: a randomized comparison of surgical treatments for rectal prolapse. *Colorectal Dis.* 2013; 15(7):858–868.
- [3] M. Solmon, C. Young, A. Evers, A. Roberts, *Randomised clinical trial of laparoscopic versus open abdominal rectopexy for rectal prolapse*, *BJS* 89 (2002) 35–39.
- [4] O. De Oliveira, S. Stein, K. Trencheva, T. Sonoda, J. Milsom, J. Lee, *Comparative outcomes of elderly patients undergoing alteimer's procedure versus laparoscopic rectopexy for rectal prolapse*, *Asian J. Endosc. Surg.* (2009). ISSN 1758–5902.
- [5] S. Sakata, S. Kabir, D. Petersen, M. Doudle, A.R. Stevenson, *Are we burying our heads in the sand? Preventing small bowel obstruction from the V-loc[®] suture in laparoscopic ventral rectopexy*, *Colorectal Dis. Off. J. Assoc. Coloproctol. G. B. Irel.* 17 (9) (2015) O180–O183, <http://dx.doi.org/10.1111/codi.13057>.
- [6] R.M. Van der Weiden, *The optimal strategy for proximal mesh fixation during laparoscopic ventral rectopexy for rectal prolapse*, *Surg. Endosc.* 27 (9) (2013 Sep) 3500, <http://dx.doi.org/10.1007/s00464-013-2925-4>. Epub 2013 Mar 19.
- [7] P.B. Murphy, K. Wanis, C.M. Schlachta, N.A. Alkhamisi, *Chir Minerva, Systematic Review on Recent Advances in the Surgical Management of Rectal Prolapse*, 2016 Oct 6. PMID: 27711030.