

Efficacy of Kirschner-wires and tension band in hip arthroplasty for aged patients with unstable intertrochanteric osteoporotic fracture

A 2-to-11-year follow-up

Hua Zhang, MD, PhD, Zhongwei Xu, MD, Aiguo Zhou, MD, PhD, Wenlong Yan, MD, Pei Zhao, MD, Xiao Huang, MD, Jian Zhang, MD, PhD*

Abstract

The aim of this study was to evaluate the efficacy of supplementary fixation in hip arthroplasty with the use of Kirschner-wires and tension band for geriatric patients suffering unstable intertrochanteric osteoporotic fractures. A total of 103 patients aged more than 75 years were recruited. A bipolar or total hip replacement was performed with additional application of Kirschner-wires and tension band, and the participants were followed up for 2 to 11 years. Physical component summary (PCS), mental component summary (MCS), visual analog scale (VAS), and Harris hip score were utilized to evaluate patients' hip pain and function, as well as the mental condition postoperatively after 1.5 months, 3 months, 6 months, 1 year, and annually thereafter until the latest follow-up in 2015. Patients showed a significant improvement in all scores between 1.5 months and 1 year ($P < 0.001$), with the good efficacy lasting at least until the 2-year follow-up. None of the patients showed dislocation, implant loosening, or nonunion of the fracture throughout the follow-up period. In conclusion, it was beneficial to treat unstable intertrochanteric osteoporotic fractures in aged patients with hip arthroplasty coupled with Kirschner-wires and tension band.

Abbreviations: MCS = mental component summary, PCS = physical component summary, VAS = visual analog scale.

Keywords: elderly patient, hip arthroplasty, intertrochanteric fracture, Kirschner-wire, osteoporosis

1. Introduction

Unstable intertrochanteric fracture is commonly concerned in elderly populations because of the increased risk of minor trauma resulting from accompanied osteoporosis. It accounts for 45% to 52% in all hip fractures of aged people, with a number of 340,000 in USA and Canada in 2008 and estimated more than 580,000 in 2040.^[1–4] It is therefore necessary to explore effective therapies to avoid the functional impairment which can even lead to death among old people.

There are 2 accepted operations to treat unstable intertrochanteric osteoporotic fracture, internal fixation, and acute arthroplasty. Internal fixation, like sliding screw plate or proximal femoral nail, has been effective in many cases but with a high

incidence of complications because of the instability and osteoporosis. The complications such as internal fixation failure, malunion, or reduction loss,^[5–7] always result in unsatisfactory hip function and long-time-stay in bed which increase the risk of pneumonia, urinary tract infection, venous thrombosis, and bed sores. Acute arthroplasty was recommended by most surgeons especially in treating aged osteoporotic patients with severe preexisting arthritis who would be faced with a higher risk of failure or complications if treated with internal fixation.^[2,6,8,9] Furthermore, elderly patients who underwent arthroplasty could benefit from early functional exercises with partial weight bearing which is not allowed when an internal fixation is performed.^[6]

However, hip arthroplasty without any reinforcement could not guarantee a high stability of prosthesis because of the weakened hip muscles in aged osteoporotic patients. With purpose of avoiding complications and obtaining long-term stability, we proposed an innovative surgical scheme for treating patients by primary arthroplasty coupled with K-wires and tension band, as well as cerclage if necessary. In this study, 103 patients older than 75 years with unstable intertrochanteric osteoporotic fracture were recruited and treated by the enhanced arthroplasty, and then a 2- to 11-year follow-up was conducted. With reconstruction of the metaphyseal bone fragments and greater trochanter, we hypothesized that an acceptable efficacy would be achieved with such surgical procedures.

2. Methods

2.1. Participants

A total of 103 patients (70 women and 33 men) with unstable intertrochanteric osteoporotic fracture (AO/OTA A2.2 or A2.3) were recruited in this study between January 2002 and January

Editor: Boyko Gueorguiev.

The authors have no funding and conflict of interests to disclose.

Supplemental Digital Content is available for this article.

Department of Orthopaedics, the First Affiliated Hospital of Chongqing Medical University, Chongqing, People's Republic of China.

* Correspondence: Jian Zhang, Department of Orthopaedics, the First Affiliated Hospital of Chongqing Medical University, No.1 Youyi Road, Yuzhong District, Chongqing, P.R.China (e-mail: zhangjian@hospital.cqmu.edu.cn).

Copyright © 2017 the Author(s). Published by Wolters Kluwer Health, Inc. This is an open access article distributed under the terms of the Creative Commons Attribution-Non Commercial License 4.0 (CCBY-NC), where it is permissible to download, share, remix, transform, and buildup the work provided it is properly cited. The work cannot be used commercially without permission from the journal.

Medicine (2017) 96:1(e5614)

Received: 6 June 2016 / Received in final form: 15 November 2016 / Accepted: 17 November 2016

<http://dx.doi.org/10.1097/MD.0000000000005614>

2013. All of the participants underwent hip replacement coupled with K-wires and tension band treatment in the Department of Orthopedics, the First Affiliated Hospital of Chongqing Medical University. In some cases, cerclage was utilized to further fix the greater and lesser trochanters.

This study was approved by the Ethics Committee of Chongqing Medical University, and Institutional Review Board (IRB) approval of Chongqing Medical University was obtained. Written informed consents were obtained from all participants.

2.2. Surgical procedures

American Society of Anesthesiologists (ASA) physical score was adopted to evaluate the preoperative medical status and surgical risk. All individuals were laterally positioned and operated under spinal or general anesthesia. A posterolateral (Moore's) approach was adopted for hip exposure. The length of incision was chosen longer than that for regular hip replacement in order to obtain sufficient exposure of the proximal femur, and sometimes the insertion of gluteus maximus had to be detached. Following external rotators detachment and arthrotomy, the femoral neck was cut off and then the hip was manually dislocated. With the removal of the femoral head, the greater and lesser trochanters were temporarily repositioned with assistance of bone forceps if necessary. Further, the acetabula was reamed, a cementless cup implanted, the femoral canal prepared for implantation of the hip stem with rasps.

In case a cemented stem was preferred, we preserved the trial inside carefully, repositioned the greater trochanter anatomically, and fixed it by insertion of 2 K-wires (mostly 2.0 mm in diameter) from the tip of the great trochanter to the lateral aspect of the femoral canal. Next, we reduced the displaced posterior and medial fragments in the intertrochanteric region and fixed them with a cerclage if necessary. A transverse hole was made in the lateral aspect of femoral diaphysis 3–5 cm distal to the fragment and a twin stainless steel wire was put through this hole and tied in a figure-of-eight fashion over the tail of the 2 K-wires which were then bent and cut. The hip was reduced with trial, the leg length and hip stability were checked, followed by removal of the trial. With the third generation cementing technique, a cement stem with a length of 170 to 180 mm was inserted into the femoral canal and held at 15 degrees to guarantee physiological acetabular anteversion. The height of prosthesis was referred to the contralateral distance between the center of femoral head and tip of the greater trochanter. Finally, we cleaned the excess cement and those leaking from the fragments' gap, grafted bone tissues harvested from the femoral head, and then tightened the figure-of-eight stainless steel wire.

When a cementless stem was preferred, we removed the trial, reduced the greater trochanter fragments, temporarily maintained them with bone forceps, and then the prosthesis was tapped into the femoral canal. Next, we inserted K-wires, reduced the displaced posteromedial fragment, and tightened the stainless steel cerclage wires.

After implantation of femoral head prosthesis, we checked the leg length and hip stability again. At last, the hip capsule and external rotators were repaired, and a negative pressure drainage tube was used before the incision was closed layer by layer.

2.3. Post-operative management

All individuals were given prophylactic intravenous antibiotic for 24 to 48 hours, and as prophylaxis for deep-vein thrombosis,

every patient received aspirin or low-molecular heparin for 5 weeks. Drainage tubes were removed within 24 hours postoperatively. Rehabilitative exercises in bed were launched from the first day after surgery, and patients were encouraged to perform partial or full weight bearing gait training exercise depending on the type of implanted femoral stem (cemented or cementless) with support of crutches or walking aids as soon as the general condition permitted. Besides, precautions of posterior dislocation were encouraged when patients began early ambulation.

2.4. Statistical analysis

All patients were followed up at regular intervals postoperatively at 1.5 months, 3 months, 6 months, 1 year, and annually thereafter until the latest follow-up in 2015. Hip functions and occurrence of complications like pain, infection of wound, limb swelling and length discrepancy, dislocation and loosening of the prosthesis were recorded. All participants were evaluated clinically and radiologically by physical component summary and mental component summary (SF-12), visual analog scale (VAS), and Harris hip score at visits of 1.5 months, 1 year, and at the latest visit in 2015. The paired *t*-test was performed to check for statistical significance between scores from different follow-ups after passing tests of normality and homogeneity of variance, and the signed rank test was adopted for non-normal data distributions.

3. Results

3.1. Clinical characteristics

The mean age of all participants was 81 years (ranged from 75 to 98), and the average body mass index (BMI) was 21.4 (ranged from 17.3 to 26.3). The mean preoperative T-score of bone mineral density (BMD) was -3.1 (ranged from -4.5 to -2.5). Among all cases, 88% patients (91 out of 103) got a trauma because of a simple fall, and 81% patients (84 out of 103) could walk freely. There were 66% patients (68 out of 103) accompanied with other 1 to 6 diseases, and 78% patients (80 out of 103) operated within 1 week. There were 74% patients (76 out of 103) assigned ASA class II by an experienced anesthesiologist, and the other patients were all assigned class III. According to the degree of acetabular cartilage damage and hip arthritis, 77% patients (79 out of 103) were treated by hemiarthroplasty with bipolar prosthesis, and 23% patients (24 out of 103) were treated by total hip arthroplasty.

Four participants had a failed internal fixation prior to the hip replacement, which was indicated by either nonunion or fracture collapse with hardware cut-out. Six participants were with 1–3 co-existing fractures, including distal radius fracture in 2 cases, proximal humerus fracture in 1 case, and spinal fracture in 3 cases. Fifteen participants suffered from symptomatic osteoarthritis and rheumatoid arthritis.

3.2. Perioperative variables

The mean duration of operation was 65 minutes (ranged from 35 to 120 minutes), and the averaged estimated blood loss was 180 mL (ranged from 50 to 900 mL). Seventeen patients received a blood transfusion (ranged from 1 to 3 units) intraoperatively, and 13 patients received a blood transfusion (ranged from 1 to 4 units) postoperatively. Patients could ambulate with assistance at a mean time of 3 days postoperatively (ranged from 1 to 18 days).

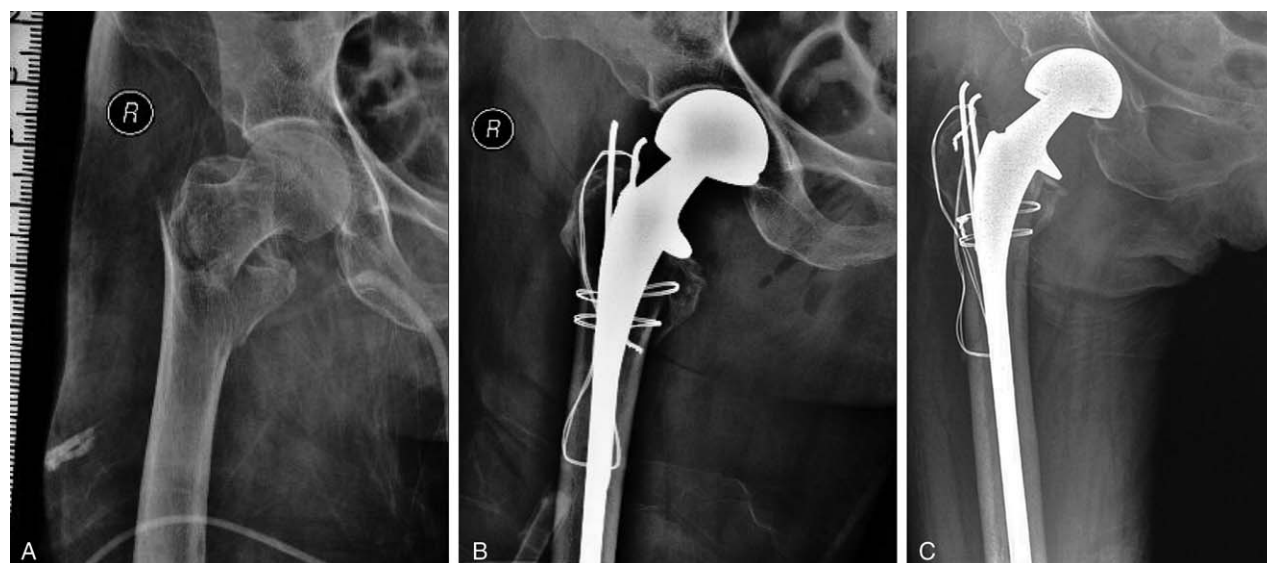


Figure 1. (A) Preoperative anteroposterior radiograph showing an unstable intertrochanteric osteoporotic fracture; (B) 2 days postoperative radiograph demonstrating a hip replacement with satisfying reduction and rigid fixation of the great and lesser trochanters with Kirschner-wires and tension band; (C) 1-year postoperative radiograph demonstrating a bone union of the greater and lesser trochanters.

The average stay was 16 days for patients treated with cementless stem able to perform partial weight-bearing exercise and for those treated with cemented stem able to perform full weight-bearing exercise.

3.3. Surgical efficacy

Prosthesis selection and intraoperative details were recorded in the supplementary material, <http://links.lww.com/MD/B486>. None of the patients showed dislocation, implant loosening, nonunion of the fracture, breakage of the steel wire, osteolysis throughout the 2-to-11-year follow-up. X-ray images of patients were obtained before and after surgery, as well as at each follow-up (Fig. 1). A total of 90 cases at 6 weeks, 86 cases at 1 year, and 85 cases at the last follow-up could ambulate with or without assistance, but only 34 had pain-free hip, whereas the others suffered a mild pain or discomfort at the last follow-up. Harris hip score, physical component summary (PCS), mental component summary (MCS), and VAS score at 6 weeks and 1 year after surgery, as well as those at the latest follow-up were investigated with results displayed in Table 1. All patients showed improved Harris hip score, PCS, MCS, and VAS from 6 weeks to 1 year postoperatively ($P < 0.001$, Table 1, Fig. 2), and there was no significant difference in all scores from 1 year to the latest follow-up (Table 1, Fig. 3).

3.4. Complications

The summary of the complication is described in Table 2. The overall incidence of operation-related complications was 34.0%. Two patients died intraoperatively because of the pulmonary embolism and/or toxicity of bone cement. Four patients died within 6 weeks (11 cases lost), 8 within 1 year (12 cases lost), and 18 at the last follow-up (17 cases lost). Among these patients who died after surgery, 1 patient died of severe wound infection and multiple organ dysfunction syndrome 4 months after surgery, and the others died of causes unrelated to the fracture.

A periprosthetic longitudinal fracture occurred accidentally in 1 case around a cemented stem intraoperatively, which occurred when the K-wires were tapped into the proximal part of the femoral canal (Fig. 4A). A periprosthetic fracture induced by a simple fall in 1 case did not result in cementless implant loosening 8 months after surgery. The 2 secondary fractures above were further fixed with cerclage and plate with cables, respectively. Bone cement leakage from the fragments' crack in 2 cases when the stems were tapped in, both not detected during surgery, turned out no discomfort after surgery. K-wires retrograding occurred in 2 cases within 1 year (Fig. 4B), which caused pain when the patients walked or rose from chair, and the pain disappeared in both cases when the retrograding K-wires were removed. Heterotopic ossification developed in 5 cases (Fig. 4C), with 3 graded III and 2 graded II according to the classification proposed by Brooker et al^[10] but no discomfort was felt.

Symptomatic acetabular cartilage wear occurred 3 years postoperatively in 2 patients who underwent hemiarthroplasty, but revision was not done because of advanced age and mild inguinal pain. Two patients with cementless stem suffered thigh pain within 6 months postoperatively, but the pain released

Table 1

Harris hip score, PCS, MCS, and VAS postoperatively.

Follow-up	Harris	SF-12 (PCS)	SF-12 (MCS)	VAS [*]
1.5 months	60.34 ± 9.34	26.83 ± 3.74	46.29 ± 4.03	2 ± 2
<i>P</i> value [†]	<0.001	<0.001	<0.001	<0.001
1 year	79.08 ± 12.52	34.87 ± 6.75	50.36 ± 4.42	1 ± 1
<i>P</i> value [‡]	0.651	1.000	1.000	0.678
Latest	80.88 ± 9.71	35.57 ± 6.19	50.19 ± 4.45	0 ± 1

MCS = mental component summary, PCS = physical component summary, VAS = visual analog scale.

^{*} Described by using median ± interquartile range (IQR) in non-normal data distribution.

[†] Comparing scores from 1.5-month follow-up with those from 1-year follow-up by using the paired *t*-test or signed rank test.

[‡] Comparing scores from 1-year follow-up with those from the latest follow-up by using the paired *t*-test or signed rank test.

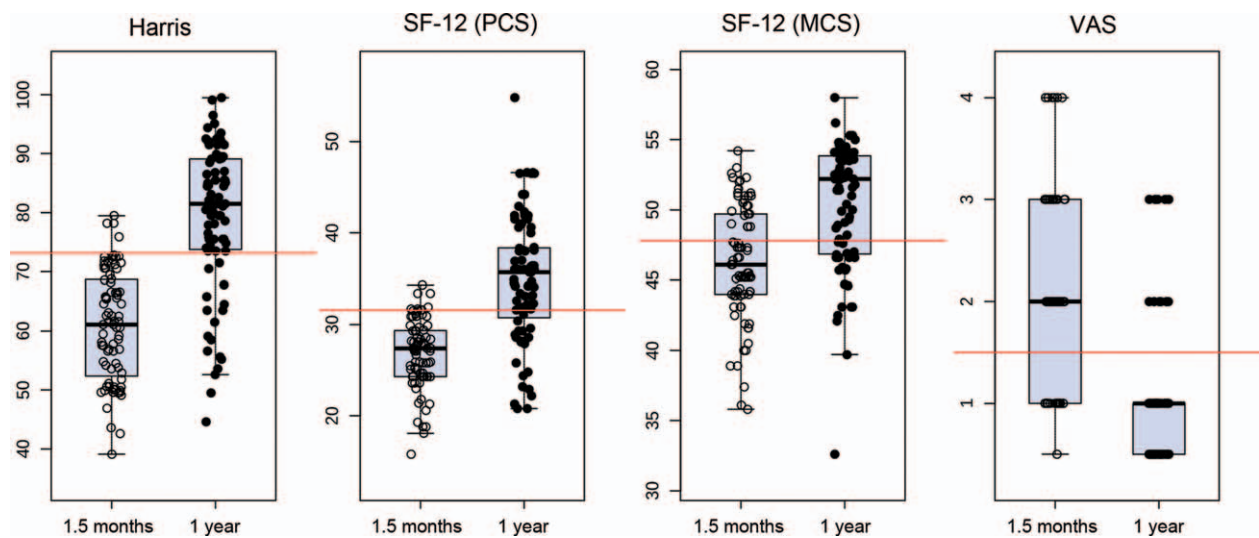


Figure 2. Comparisons of clinical outcomes at 1.5-month follow-up and those at 1-year follow-up, evaluated by using paired *t*-test in the Harris score, SF-12 score, and signed rank test in the VAS score. Statistical significance was found in all scores ($P < 0.001$).

without any treatment thereafter. Wound infection occurred in 2 type-II diabetes mellitus patients whose blood albumins were both below 27g/L. One with superficial infection underwent debridement and then the infection was quickly under control. The other with deep infection rejected re-operation and died 4 months after surgery. Leg length discrepancy occurred in 2 patients, but radiological measurement proved that the difference between legs was less than 1cm, and the discomfort was alleviated gradually within 1 year postoperatively.

There were other complications prior to discharge. Dysphoria occurring in 21 cases was considered as with organic mental disorders, and all involved patients were sedated as required. Finally, all the patients were discharged without psychiatric symptoms. Besides, 8 cases and 4 cases developed pulmonary and urinary infection, respectively. Eight cases had deep-vein thrombosis, and 9 cases had a pressure sore due to delayed

ambulating. All these cases were provided specific treatment and got symptom's remission.

4. Discussion

The traditional treatments of intertrochanteric fractures are open reduction and internal fixation with dynamic hip screws, intramedullary nail or proximal femoral nail. However, elderly patients with osteoporosis have a high prevalence of unsatisfactory outcomes due to inadequate implant hold of bone with a failure rate of 3% to 16.5%,^[6,11] and a low probability to survive the re-operation. In addition, some studies reported a high rate of mortality,^[2] which reached 22% 1 year after surgery,^[12] with most of the cases died because of general complications such as hypostatic pneumonia, urinary tract infection, DVT, pulmonary embolism if patients underwent fixation surgery.

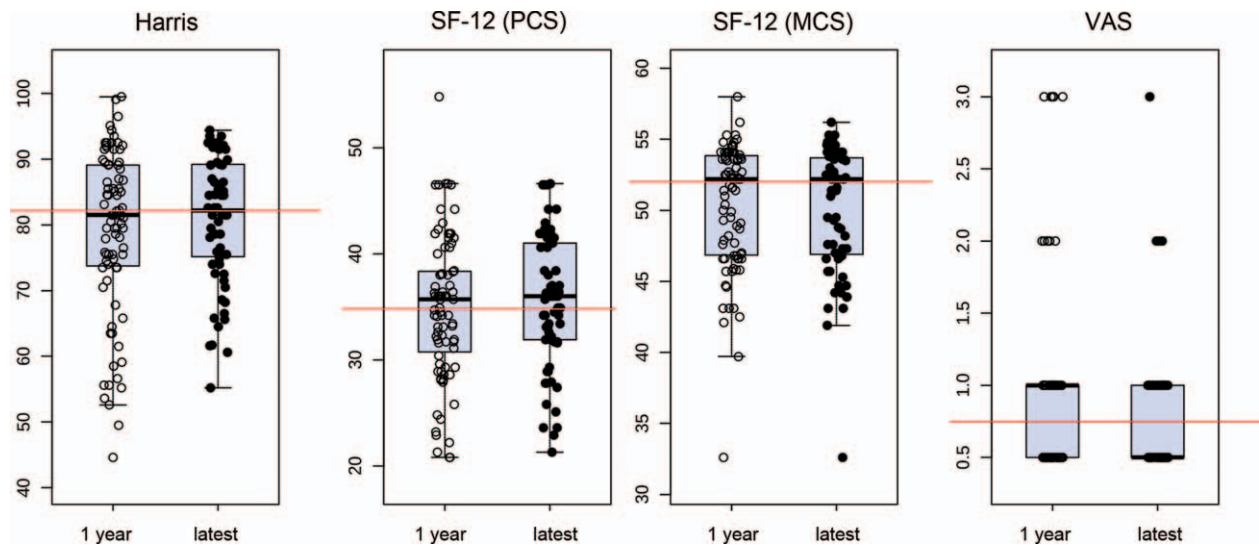


Figure 3. Comparisons of clinical outcomes at 1-year follow-up and those at the last follow-up, evaluated by using the paired *t*-test in the Harris score, SF-12 score, and signed rank test in the VAS score. No statistical significance was found in any score ($P > 0.05$).

Table 2**Complications occurred intra- or postoperatively.**

Complications	No. of patients	Incidence
Intraoperative dead	2	1.9%
Died within 6 weeks	4 (11 cases lost)	6.5%
Died within 1 year	8 (12 cases lost)	8.8%
Pulmonary embolism	1	1.0%
Bone cement toxicity	1	1.0%
Wound infection	2 (12 cases lost)	2.2%
Organic mental disorders	21	20.4%
Deep-vein thrombosis	8	7.8%
Pulmonary infection	8	7.8%
Urinary infection	4	3.9%
Pressure sore	9	8.7%
Thigh pain	2	1.9%
Symptomatic acetabular Cartilage wear	2 (17 cases lost)	2.3%
Heterotopic ossification	5 (17 cases lost)	5.8%
K-wires retrograding	2 (17 cases lost)	2.3%
Bone cement leakage	2	1.9%
Leg length discrepancy	2	1.9%
Peri-prosthetic fracture	2 (17 cases lost)	2.3%

The purpose of treating intertrochanteric fractures in the elderly is to allow immediate ambulating after surgery, improve hip function and life quality, and avoid complications resulted from recumbence and internal fixation. Therefore, hip replacement was recommended as the primary treatment strategy for unstable intertrochanteric fractures by some surgeons.^[2,9,13–22] Our case series also demonstrated a continuous good outcome when treated by arthroplasty, which was reflected by the significantly improved pain and functional scores 1 year after surgery and that of the latest follow-up. However, the mortality rate was 6.5% within 6 weeks and 8.8% within 1 year after surgery, which seems to be acceptable, but we still insisted that patients at this age should be operated with extreme caution because of the various comorbidities which further perplex the management of these osteoporotic fractures. Four or more comorbidities could increase the death rate by 78%.^[23]

It is well accepted that reconstruction and fixation of the greater trochanter are essential in treating intertrochanteric fractures. Several techniques were described to fix the greater trochanter. Most surgeons preferred the cerclage with stainless steel wires or cables, while some preferred plate and screws or suturing.^[24] The former technique was reported possible to develop breakage of steel wires and nonunion postoperatively.^[25] A retrospective study reported a cable breakage rate of 12.8% (5 out of 39) in osteoporotic patients with intertrochanteric fracture who underwent hip replacement with cerclage fixation for the proximal femoral fragments.^[2] Therefore, we optimized the fixation of the greater trochanter with K-wires and tension band which is tight enough for early weight-bearing exercises even in aged patients with advanced osteoporosis and poor bone quality. In this study for up to 11 years, all available participants demonstrated a satisfactory radiological greater trochanter healing without breakage or cut-out of the internal fixation, which was considered as one of the crucial factors for function improvement and pain relief. Besides, it alleviated patients' economic burden which was more meaningful for developing countries. We therefore insisted that rigid suturing was not necessary but plate was not recommended for disadvantages on holding the osteoporotic fragments together, as well as the economic reasons.

Two patients with developed K-wires retrograding but without steel wires' breakage were observed in the present study, which was considered as main disadvantage of this technique. It was considered resulting from osteoporosis, bone absorption around the K-wires, and the movement of gluteus medius. We therefore began to use K-wires with thread near the tip in fixation, and we hypothesized that it could be an effective way to avoid the retrograding of K-wires.

Chu et al^[17] and Lee et al^[18] reported satisfactory outcomes by using hip replacement for the osteoporotic fractures with cementless stem, including Wagner SL and hydroxyapatite-coated long stem. Patterson proposed an insertion of cementless stem in elderly patients accompanied with cardiac or pulmonary disorders generally, in order to prevent cement-related cardiovascular complications.^[26] In this study, 15 patients underwent

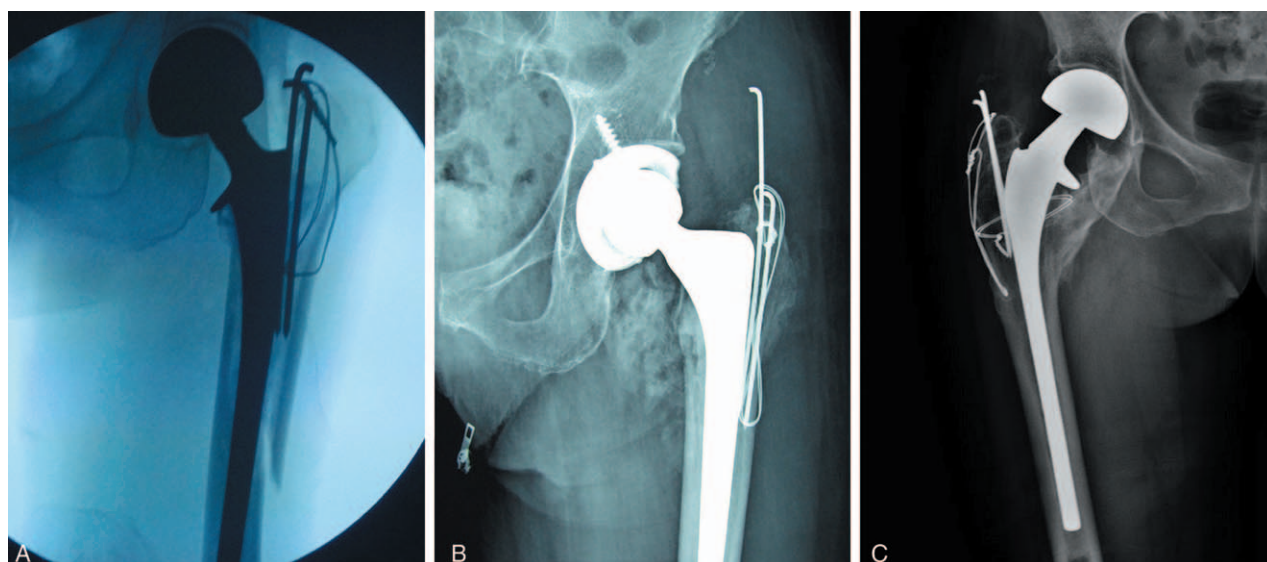


Figure 4. (A) Anteroposterior radiograph demonstrating a peri-prosthetic longitudinal fracture around a cemented stem intraoperatively; (B) anteroposterior radiograph demonstrating a K-wires retrograding; (C) anteroposterior radiograph demonstrating heterotopic ossification around the hip.

hip replacement with Wagner SL stem and 8 patients with AML stem (hydroxyapatite-coated long stem), among which 2 suffered thigh pain and 1 developed a peri-prosthetic fracture. These complications could result from the osteoporotic thinning of the femoral cortex which led to stress concentration. So we performed this surgery with cementless stem mostly. Peri-prosthetic fracture occurred intraoperatively in 1 case with cemented stem, but the K-wires we used in this case were 3.0 mm in diameter which was considered as the possible cause of the fracture due to its loss of elasticity, and that was why we chose K-wires with 2.0 mm in diameter thereafter. Certainly, there were also disadvantages in cemented stem, like bone cement leakage and cement toxicity, which can hardly be avoided and also occurred in the present study. Recently, steroid was intravenously injected during our clinical surgery before use of cement, which can theoretically reduce the occurrence of cement toxicity.

Fan reported results of patients suffering osteoporotic intertrochanteric fractures and treated by bipolar versus total hip replacement, and concluded that bipolar choice seemed to be more beneficial because of its shorter surgical time, lower operation cost, less blood loss, and no dislocation.^[13] In our series, 79 patients underwent bipolar hip replacement, and 24 patients underwent total hip replacement because of damaged cartilage or preexisting arthritis accompanied. Symptomatic acetabular cartilage wear, which should be highly concerned in bipolar hip replacement, occurred only in 2 cases and the pain was not severe. The concern regarding growing pain due to acetabular erosion seemed not to be a big problem during follow-up, which might benefit from low activity among aged patients. Our outcome was in accordance with those reported by Fan et al, and we recommended the bipolar one for the same reason. In addition, we noticed that organic mental disorders occurred in 21 cases, which always led to noncompliance after surgery and easily developed dislocation. Although many studies showed excellent clinical outcomes and patient satisfaction by using hip replacement, it was still controversial which treatment was more beneficial. No significant difference was observed between internal fixation and hip replacement in some studies.^[27]

The main limitation of our retrospective study was the absence of a control group and small amount of cases included, which might bias our outcomes. Therefore, more prospective, randomized double-blind controlled studies were needed to validate the long-term efficacy of hip replacement.

References

- [1] Carson JL, Terrin ML, Noveck H, et al. Liberal or restrictive transfusion in high-risk patients after hip surgery. *N Engl J Med* 2011;365:2453–62.
- [2] Grimsrud C, Monzon RJ, Richman J, et al. Cemented hip arthroplasty with a novel cerclage cable technique for unstable intertrochanteric hip fractures. *J Arthroplasty* 2005;20:337–43.
- [3] Kim SH, Meehan JP, Blumenfeld T, et al. Hip fractures in the United States: 2008 nationwide emergency department sample. *Arthritis Care Res (Hoboken)* 2012;64:751–7.
- [4] Koval KJ, Aharonoff GB, Rokito AS, et al. Patients with femoral neck and intertrochanteric fractures. Are they the same? *Clin Orthop Relat Res* 1996;330:166–72.
- [5] Mattsson P, Larsson S. Unstable trochanteric fractures augmented with calcium phosphate cement. A prospective randomized study using radiostereometry to measure fracture stability. *Scand J Surg* 2004;93:223–8.
- [6] Haentjens P, Lamraski G. Endoprosthetic replacement of unstable, comminuted intertrochanteric fracture of the femur in the elderly, osteoporotic patient: a review. *Disabil Rehabil* 2005;27:1167–80.
- [7] Weiss RJ, Karrholm J, Hailer NP, et al. Salvage of failed trochanteric and subtrochanteric fractures using a distally fixed, modular, uncemented hip revision stem. *Acta Orthop* 2012;83:488–92.
- [8] Archibeck MJ, Carothers JT, Tripuraneni KR, et al. Total hip arthroplasty after failed internal fixation of proximal femoral fractures. *J Arthroplasty* 2013;28:168–71.
- [9] Abdelkhalik M, Ali AM, Abdelwahab M. Cemented bipolar hemiarthroplasty with a cerclage cable technique for unstable intertrochanteric hip fractures in elderly patients. *Eur J Orthop Surg Traumatol* 2013;23:443–8.
- [10] Brooker AF, Bowerman JW, Robinson RA, et al. Ectopic ossification following total hip replacement. Incidence and a method of classification. *J Bone Joint Surg* 1973;55:1629–32.
- [11] Davis TR, Sher JL, Horsman A, et al. Intertrochanteric femoral fractures. Mechanical failure after internal fixation. *J Bone Joint Surg* 1990;72:26–31.
- [12] Aprin H, Kilfoyle RM. Treatment of trochanteric fractures with Ender rods. *J Trauma* 1980;20:32–42.
- [13] Fan L, Dang X, Wang K. Comparison between bipolar hemiarthroplasty and total hip arthroplasty for unstable intertrochanteric fractures in elderly osteoporotic patients. *PLoS One* 2012;7:e39531.
- [14] Gu GS, Wang G, Sun DH, et al. Cemented bipolar hemiarthroplasty with a novel cerclage cable technique for unstable intertrochanteric hip fractures in senile patients. *Chin J Traumatol* 2008;11:13–7.
- [15] Hsu CJ, Chou WY, Chiou CP, et al. Hemi-arthroplasty with supplemental fixation of greater trochanter to treat failed hip screws of femoral intertrochanteric fracture. *Arch Orthop Trauma Surg* 2008;128:841–5.
- [16] Karthik K, Natarajan M. Unstable trochanteric fractures in elderly osteoporotic patients: role of primary hemiarthroplasty. *Orthop Surg* 2012;4:89–93.
- [17] Chu X, Liu F, Huang J, et al. Good short-term outcome of arthroplasty with Wagner SL implants for unstable intertrochanteric osteoporotic fractures. *J Arthroplasty* 2014;29:605–8.
- [18] Lee YK, Ha YC, Chang BK, et al. Cementless bipolar hemiarthroplasty using a hydroxyapatite-coated long stem for osteoporotic unstable intertrochanteric fractures. *J Arthroplasty* 2011;26:626–32.
- [19] Sancheti Kh, Sancheti P, Shyam A, et al. Primary hemiarthroplasty for unstable osteoporotic intertrochanteric fractures in the elderly: a retrospective case series. *Indian J Orthop* 2010;44:428–34.
- [20] Siwach R, Jain H, Singh R, et al. Role of hemiarthroplasty in intertrochanteric fractures in elderly osteoporotic patients: a case series. *Eur J Orthop Surg Traumatol* 2012;22:467–72.
- [21] Sidhu AS, Singh AP, Singh AP, et al. Total hip replacement as primary treatment of unstable intertrochanteric fractures in elderly patients. *Int Orthop* 2010;34:789–92.
- [22] Waddell JP, Morton J, Schemitsch EH. The role of total hip replacement in intertrochanteric fractures of the femur. *Clin Orthop Relat Res* 2004;49–53.
- [23] Geiger F, Zimmermann-Stenzel M, Heisel C, et al. Trochanteric fractures in the elderly: the influence of primary hip arthroplasty on 1-year mortality. *Arch Orthop Trauma Surg* 2007;127:959–66.
- [24] Kumar Gn K, Meena S, Kumar NV, et al. Bipolar hemiarthroplasty in unstable intertrochanteric fractures in elderly: a prospective study. *J Clin Diagn Res* 2013;7:1669–71.
- [25] Haidukewych GJ, Berry DJ. Hip arthroplasty for salvage of failed treatment of intertrochanteric hip fractures. *J Bone Joint Surg Am* 2003;85-A:899–904.
- [26] Patterson BM, Lieberman JR, Salvati EA. Intraoperative complications during total hip arthroplasty. *Orthopedics* 1995;18:1089–95.
- [27] Kim SY, Kim YG, Hwang JK. Cementless calcar-replacement hemiarthroplasty compared with intramedullary fixation of unstable intertrochanteric fractures. A prospective, randomized study. *J Bone Joint Surg Am* 2005;87:2186–92.