

Titanium Plate Fixation for a Dehisced Sternum Following Coronary Artery Bypass Grafting: A Case Report

Wan Kee Kim, M.D., Joon Bum Kim, M.D., Sung-Ho Jung, M.D., Suk Jung Choo, M.D.,
Cheol Hyun Chung, M.D., Jae Won Lee, M.D.

Sternal dehiscence is one of the most troublesome complications following cardiac surgery. Treatment failure and consequent lethal results are very common, even with all the efforts to resolve sternal dehiscence such as removal of infectious tissue, muscle flap interposition, and sternal rewiring. We report on a case of sternal osteomyelitis following coronary artery bypass grafting that was successfully treated with wide sternal resection, titanium plate fixation, and pectoralis muscle flap interposition.

Key words: 1. Sternum
2. Wound dehiscence
3. Wound infection
4. Reoperation

CASE REPORT

A 62-year-old diabetic male presented to our clinic with swelling, redness, and purulent discharge from a previous sternotomy site. He had undergone off-pump coronary artery bypass grafting 6 months earlier using the bilateral internal thoracic arteries for silent ischemia (three-vessel coronary disease). During the initial hospitalization he suffered from deep sternal wound infection following the coronary surgery, which was treated by debridement and a vacuum suctioning system followed by sternal revision using the Robicsek technique (Fig. 1).

At the present visit, which was four months after sternal reconstruction, the sternomanubrial junction area had bulged with purulent discharge. The white blood cell count was at 7,400 mm³ and the absolute neutrophil count was at 5,800

mm³. The C-reactive protein was at 0.39 mg/dL and other blood laboratory findings were unremarkable. Chest computed tomography (CT) showed destruction of sternal bone with focal sclerotic change and fluid collection, which were compatible with sternal osteomyelitis.

As methicillin resistant *Streptococcus epidermidis* was revealed as the causative pathogen by wound swab culture, intravenous antibiotics treatment (teicoplanin 6 mg/kg once every 2 days) was initiated. For the treatment, surgical debridement and sternal reconstruction was planned. During surgery, the osteolytic lower manubrium and upper sternal body (from the lower margin of the first rib level to the upper margin of the fourth rib level) were removed; only the healthy part of sternum remained and warm saline irrigation was then performed. Sternal stability was restored by two horizontal titanium plates (Angled Universal Fracture Plate; AO Foundation,

Department of Thoracic and Cardiovascular Surgery, Asan Medical Center, University of Ulsan College of Medicine

Received: August 31, 2011, Revised: October 3, 2011, Accepted: October 16, 2011

Corresponding author: Joon Bum Kim, Department of Thoracic and Cardiovascular Surgery, Asan Medical Center, University of Ulsan College of Medicine, 88 Olympic-ro 43-gil, Songpa-gu, Seoul 138-736, Korea
(Tel) 82-2-3010-3580 (Fax) 82-2-3010-6966 (E-mail) jbkim1975@amc.seoul.kr

© The Korean Society for Thoracic and Cardiovascular Surgery. 2012. All right reserved.

© This is an open access article distributed under the terms of the Creative Commons Attribution Non-Commercial License (<http://creativecommons.org/licenses/by-nc/3.0>) which permits unrestricted non-commercial use, distribution, and reproduction in any medium, provided the original work is properly cited.

Davos, Switzerland), which were cut and shaped to be fixed into the curvature of the proximal part of the second and third ribs (Fig. 2). Each titanium plate was fixed to the corresponding rib using three titanium screws for each side. Sternal defects following resection were plugged with pedicled bilateral pectoralis major muscle flaps which were prepared with adequate undermining. The muscle flaps were fixed to the defect site by making several interrupted sutures. After leaving two small draining catheters at the pectoralis muscle flap layer and subcutaneous layer, each, the wound

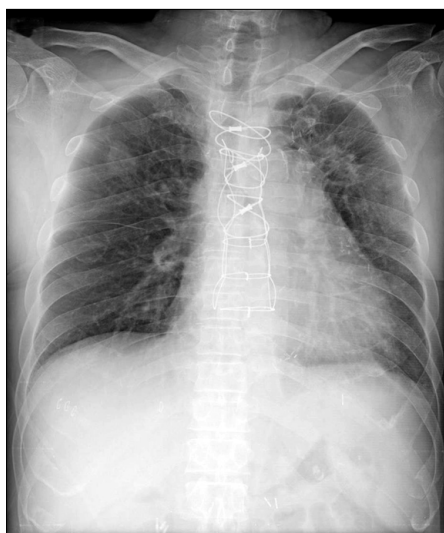


Fig. 1. Simple chest radiography shows the Robicsek wiring technique for sternum revision due to sternal dehiscence following coronary arterial bypass grafting.

was closed using simple interrupted sutures of 1-0 Vicryl for the muscle layer and vertical mattress sutures of 2-0 nylon for the skin closures.

A postoperative course of antibiotic treatment (teicoplanin 6 mg/kg, once every 2 days) was uneventful and the patient was discharged 20 days postoperatively.

A follow-up CT performed before the patient was discharged showed no signs of infection in the sternum or mediastinum but revealed that the chest wall integrity was well maintained. During the 6 month follow-up period after the titanium plate fixation, the patient was doing well without any sternal wound problems (Fig. 3).

DISCUSSION

Sternal wound problems are among the troublesome complications following cardiac surgery and have an occurrence rate of 0.5% to 5.0% [1]. In many cases where sternal revision is required, a simple wire circlage, which is the most common method for sternal wound repair in general [2], may not be enough to restore sternal stability, especially when a significant portion of the sternum is to be resected [3]. In these cases, simple wire-circlage can result in further sternal bone injuries to the remaining segments of the sternum because too much tension can be applied to these areas even with the use of the Robicsek technique. Consequently, unstable sternal fixation may also cause healing failure of the wound. Considering the orthopedic principle, limiting the mo-

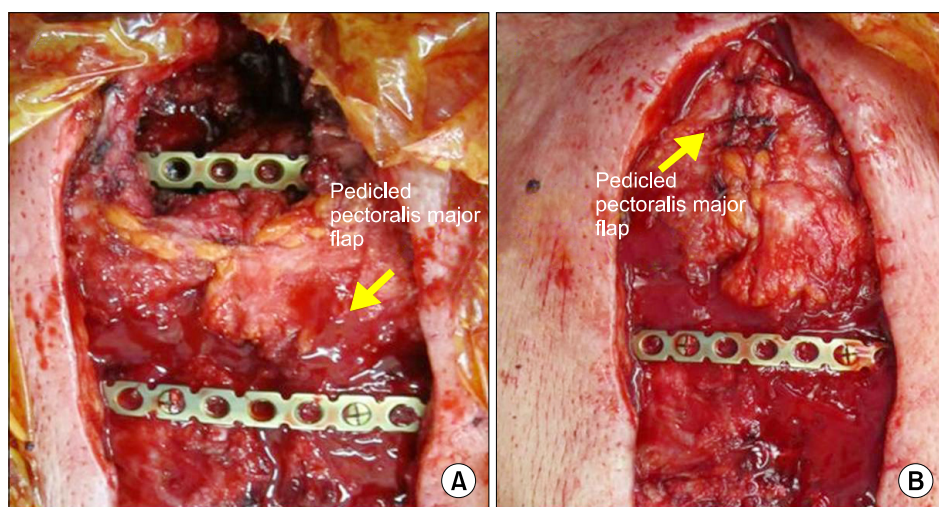


Fig. 2. Intraoperative findings during titanium plate fixation and bilateral pectoralis muscle flap interposition. (A) After massive debridement, two titanium plates were fixed to the second and third ribs with three screws at each end. (B) Pedicled pectoralis muscle flaps were interposed and fixed to the space where the sternum was resected.

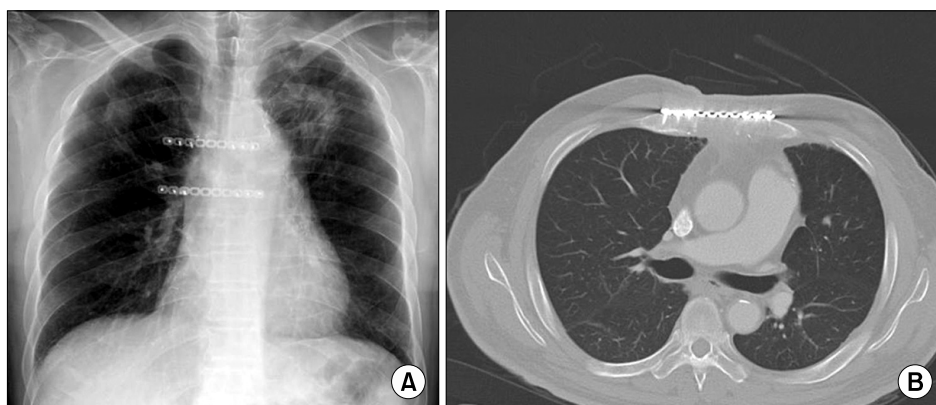


Fig. 3. Last follow-up simple chest radiography (A) and computed tomography findings (B) at 6 months following titanium plate fixation. Chest wall integrity was well maintained without any signs of infection.

tion between broken segments of bone is the utmost importance for bone healing [4]. In this regard, metal plating of the sternum can provide stabilization and immobilization of a separated sternum, which is the most important factor for sternal reunion, and therefore has been reported as promising for treatment of a complicated sternum following major cardiac surgery [5-7]. However, experiences with this treatment method have not been reported in the literature published in Korea.

In the present case, conventional methods had failed to resolve the sternal wound problem. This may have been partly attributable to an overly conservative approach to debridement of the infected tissue because in order to close the sternum using conventional methods (either simple wiring or the Robicsek technique), much of the sternum should remain intact. If the sternal stability can be guaranteed even after aggressive sternal resection, more complete debridement of infective tissue can be achieved without concerns of post-operative sternal instability and consequent healing failure. In this sense, titanium plating was very effective in restoring the sternal stability even after wide resection of the sternum, as can be seen in the current case. The dead space was filled by interpositioning a pectoralis muscle flap to eliminate room for potential infection sources.

Although the sternal defect size was not large enough to require sternal reconstruction in the present case, chest wall instability was induced because the resected site involved a sternal angle that necessitated an additional procedure to restore stability. The other portions of the sternum were closed using conventional wire-circlage for the following reasons: 1)

bone condition was uncomplicated to allow simple wiring; 2) simple wiring is much less time-consuming and less costly. In many cases, to obtain a large area of a pectoralis muscle flap in cases where chest wall reconstruction is required, cutting the humeral head of the muscle is needed. However, in the present case, the dead space was limited to the sternal angle portion, in that only an adequate undermining of the pectoralis major muscle without cutting the humeral head allowed us to fill the dead space.

Several disadvantages have been reported in the use of titanium plates for sternal closure; it costs more than the conventional methods and concealed bleeding at the screw site can occur [8].

In conclusion, we report a case of sternal osteomyelitis following coronary artery bypass grafting, which was successfully treated with wide sternal resection, titanium plate fixation, and pectoralis muscle flap interposition.

REFERENCES

1. Losanoff JE, Richman BW, Jones JW. *Disruption and infection of median sternotomy: a comprehensive review.* Eur J Cardiothorac Surg 2002;21:831-9.
2. Losanoff JE, Jones JW, Richman BW. *Primary closure of median sternotomy: techniques and principles.* Cardiovasc Surg 2002;10:102-10.
3. Song DH, Lohman RF, Renucci JD, Jeevanandam V, Raman J. *Primary sternal plating in high-risk patients prevents mediastinitis.* Eur J Cardiothorac Surg 2004;26:367-72.
4. Claes L, Eckert-Hubner K, Augat P. *The effect of mechanical stability on local vascularization and tissue differentiation in callus healing.* J Orthop Res 2002;20:1099-105.

5. Sargent LA, Seyfer AE, Hollinger J, Hinson RM, Graeber GM. *The healing sternum: a comparison of osseous healing with wire versus rigid fixation.* Ann Thorac Surg 1991;52: 490-4.
6. Snyder CW, Graham LA, Byers RE, Holman WL. *Primary sternal plating to prevent sternal wound complications after cardiac surgery: early experience and patterns of failure.* Interact Cardiovasc Thorac Surg 2009;9:763-6.
7. Cicilioni OJ Jr, Stieg FH 3rd, Papanicolaou G. *Sternal wound reconstruction with transverse plate fixation.* Plast Reconstr Surg 2005;115:1297-303.
8. Voss B, Bauernschmitt R, Will A, et al. *Sternal reconstruction with titanium plates in complicated sternal dehiscence.* Eur J Cardiothorac Surg 2008;34:139-45.