



# Fulminant corporal infection induced by Fournier gangrene: A case report with unusual presentation

Sultan S. Almaiman<sup>a,\*</sup>, Omar B. Alfraidi<sup>b</sup>, Naif K. Alhathal<sup>a</sup>

<sup>a</sup> King Faisal Specialist Hospital and Research Centre (KFSH&RC), Urology Department Riyadh, Saudi Arabia

<sup>b</sup> King Abdulaziz Medical City, NGH, Riyadh, Saudi Arabia

## ARTICLE INFO

### Categories:

Urology  
Infection

### Keywords:

Fournier  
Urethritis  
Corporal abscess

## ABSTRACT

Fournier gangrene is a life-threatening surgical emergency caused by multiple infectious organism usually affecting the subcutaneous perineal, genital or perianal region with high incidence in immunocompromised patients.

In very rare situations such our case when it involves the Deep perineal fascia and invading into the corporal body, the necrotizing tissue spread and control becomes more challenging and lead into devastating events with high mortality rate.

Staged timely debridement with highly daily examination to rule out necrosis spread is highly recommended.

## 1. Introduction

Fournier gangrene is a life-threatening infectious surgical emergency usually caused by multiple organisms of the perineal, genital or perianal region. It has an increased incidence in patients with alcoholism and immunocompromised patients especially uncontrolled diabetes. It often begins as a simple abscess or cellulitis with progression to necrotizing soft tissue infection.

Superficial perineal space (inferior fascia of the urogenital diaphragm with colles fascia) limit the extension of the infection to the perineal body and urogenital diaphragm posteriorly and to the pubic rami laterally.

Usually it does not involve the corporal body due to deferent fascial coverage. The deep fascia termed buck's fascia which fuses deep in the dense tunica albuginea deep in the pelvis, spares the corporal body from infection.

We reviewed the literature and found few studies mentioning Fournier gangrene involving the corporal body.<sup>1,2,3</sup>

## 2. Case

A 57-year-old male patient who is bed bound with poorly controlled diabetes. Presented to our institute KFSH&RC Riyadh with scrotal swelling and discoloration associated with fever and deterioration of consciousness. He was recently discharged from outside hospital where

he was investigated for his recent bilateral lower limb weakness which showed to be due to severely uncontrolled diabetes leading into diabetic neuro/myopathy.

He was discharged with Foley catheter in place for 1 month, with recent history of urethritis. He was having high Fournier gangrene scoring index score (Fig. 1).

The patient underwent multiple staged debridement, initially debridement of the scrotum and the penile skin was done, sparing the penile glans. After 3 days the glans started to get blackish with a picture of dry gangrene (Fig. 2). We took him into other sessions of wound exploration and debridement which ended with total penectomy showing puss inside the corpora, with non-viable urethral plate (Fig. 3).

Which indicate the necrotizing fasciitis entry and starting site to be from the urethra. Perineal urethrostomy was done and the testis was placed into bilateral thigh pouches.

The patient initially was doing fine covered with appropriate antibiotics on Vacuum dressing and Hyperbaric oxygenation chamber. His scrotal wound was clean with good granulation tissue.

After around 10 days he deteriorated clinically and was found to have necrotizing fasciitis of the subcutaneous gluteal area with muscle involvement. The radiological images showed extension from the original necrotizing site of the perineum. The patient eventually died due to multi-organ failure with resistant bacteria.

Literature was reviewed showing 1 study of urethritis causing Fournier gangrene. Also, the patient died eventually after partial

\* Corresponding author. King Faisal Specialist Hospital & Research Centre, Riyadh, MBC 83, PO Box 3354, Riyadh 11211, Saudi Arabia.

E-mail address: [SS.Almaiman@gmail.com](mailto:SS.Almaiman@gmail.com) (S.S. Almaiman).

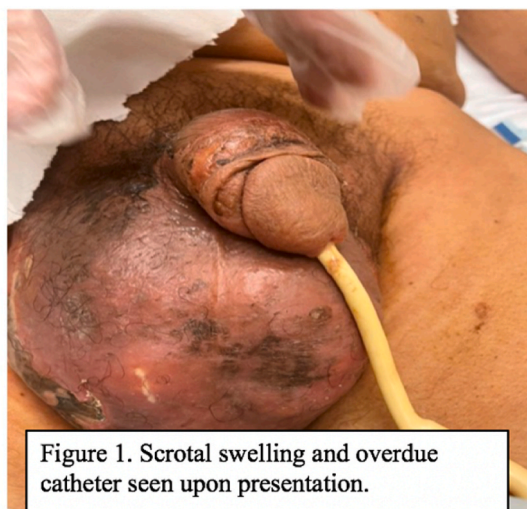

Figure 1. Scrotal swelling and overdue catheter seen upon presentation.

Fig. 1. Scrotal swelling and overdue catheter seen upon presentation.

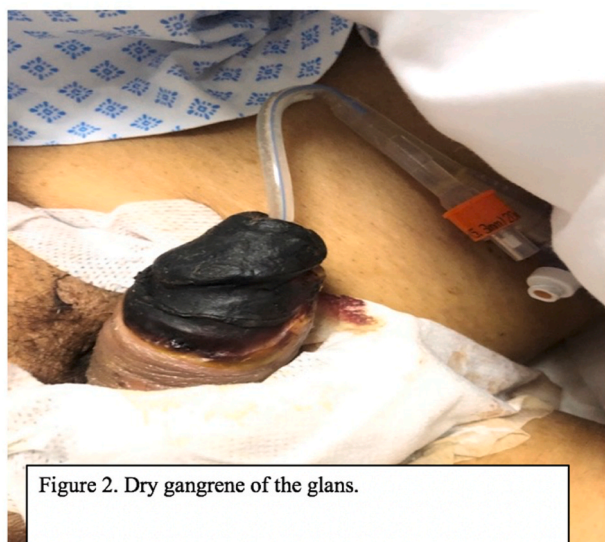

Figure 2. Dry gangrene of the glans.

Fig. 2. Dry gangrene of the glans.

penectomy.<sup>4</sup>

### 3. Conclusion

Fournier gangrene due urethritis is lethal, Foley placement should be carefully placed in a sterile technique and exchanged frequently especially in immunocompromised patients. Staged timely debridement is recommended with raising high suspicion into spread of necrotizing tissue into other place, especially in such cases were the starting point involved the deep perineal fascia.

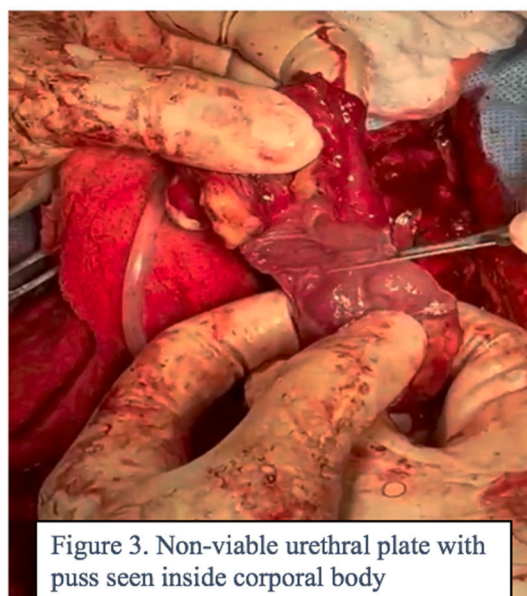


Figure 3. Non-viable urethral plate with puss seen inside corporal body

Fig. 3. Non-viable urethral plate with puss seen inside corporal body.

### Info

All authors have declared that no financial support was received from any organization for the submitted work.

### Financial relationships

All authors have declared that they have no financial relationships at present or within the previous three years with any organizations that might have an interest in the submitted work.

### Other relationships

All authors have declared that there are no other relationships or activities that could appear to have influenced the submitted work.

### Declaration of competing interest

All authors declare the following: Payment/services.

### References

- Pandey S, Sharma D, Aggarwal A, Sharma A. Isolated Fournier's gangrene of the penis with penile autoamputation. *BMJ Case Rep.* 2018;2018. <https://doi.org/10.1136/bcr-2018-226862>. bcr2018226862. Published 2018 Sep. 19.
- De S, Belsante MJ, Tausch TJ, Simhan J. A case of Fournier's gangrene necessitating total penectomy. *Can J Urol.* 2015;22(6):8108–8111.
- Deb PP, Choudhary A, Dey RK, Das RK. Isolated involvement of penis in Fournier's gangrene: a rare possibility. *J Coll Physicians Surg Pak.* 2018;28(2):164–165. <https://doi.org/10.29271/jcpsp.2018.02.164>.
- López Pacios JC, Sánchez Merino JM, Piñero Fernández MC, Bousso Montero M, Parra Muntaner L, García Alonso J. Gangrena de Fournier secundaria a cateterismo uretral [Fournier's gangrene secondary to urethral catheterization]. *Arch Esp Urol.* 2005;58(2):167–170. <https://doi.org/10.4321/s0004-06142005000200012>.