

Access this article online

Quick Response Code:



Website:

www.e-tjo.org

DOI:

10.4103/tjo.tjo_85_20

One-year results of switching to aflibercept for persistent diabetic macular edema resistant to bevacizumab

Mahmoud Alaa Abouhoussein*, Amir Ramadan Gomaa

Abstract:

PURPOSE: The aim of this study is to evaluate the functional and anatomical effects of switching from bevacizumab to aflibercept in patients with persistent diabetic macular edema (DME) resistant to bevacizumab.

MATERIALS AND METHODS: Patients with DME refractory to bevacizumab (1.25 mg/0.05 mL) were subsequently switched to aflibercept. The included patients received five loading doses of intravitreal aflibercept (2 mg/0.05 mL) given monthly. After the loading dose, aflibercept was injected every 2 months. The follow-up duration was 1 year.

RESULTS: The study consisted of 37 eyes of 37 patients. The mean age of the participants was 56.81 ± 7.11 years. The mean central macular thickness at baseline was $428.32 \pm 84.89 \mu\text{m}$, which decreased significantly to $275.54 \pm 50.24 \mu\text{m}$ ($P < 0.003$). There was a significant improvement in the mean best-corrected logMAR visual acuity from 0.627 ± 0.307 at baseline to 0.203 ± 0.235 ($P < 0.017$) at the end of follow-up.

CONCLUSIONS: Aflibercept is effective in patients with persistent DME not responsive to bevacizumab.

Keywords:

Aflibercept, bevacizumab, diabetic macular edema, intravitreal injection

Introduction

Diabetic macular edema (DME) is the most important cause of diminution of vision in diabetic patients.^[1] Risk factors of DME include long duration of diabetes mellitus (DM) and poor metabolic control. DME occurs in about 20% of diabetic patients.^[2]

Macular laser treatment was considered the treatment of choice for DME according to the results published in the Early Treatment Diabetic Retinopathy Study back in the 80s.^[3]

Hyperglycemia in diabetics is responsible for the destruction of the blood-

retinal barrier and damage to capillary endothelial cells.^[4] One of the main involved mediators is vascular endothelial growth factor (VEGF), which leads to new vessels' formation and hyperpermeability of the blood vessels.^[5]

The use of drugs antagonizing VEGF effects was a breakthrough in DME management.^[6] This category of anti-VEGF agents includes three main drugs: the full-length VEGF-A monoclonal antibody bevacizumab (Avastin; Genentech, Inc., San Francisco, CA, USA). Although it is not approved by the United States Food and Drug Administration (FDA) for intraocular use, bevacizumab is widely used according to the results of many studies, for example,

This is an open access journal, and articles are distributed under the terms of the Creative Commons Attribution-NonCommercial-ShareAlike 4.0 License, which allows others to remix, tweak, and build upon the work non-commercially, as long as appropriate credit is given and the new creations are licensed under the identical terms.

For reprints contact: WKHLRPMedknow_reprints@wolterskluwer.com

How to cite this article: Abouhoussein MA, Gomaa AR. One-year results of switching to aflibercept for persistent diabetic macular edema resistant to bevacizumab. Taiwan J Ophthalmol 2021;11:266-72.

Department of
Ophthalmology, Alexandria
University, Alexandria,
Egypt

*Address for correspondence:

Dr. Mahmoud Alaa
Abouhoussein,
8 Hassan Allam
Street, Smouha,
Alexandria, Egypt.
E-mail: nad03alaa@
yahoo.com

Submission: 17-09-2020

Accepted: 30-11-2020

Published: 02-06-2021

the Bevacizumab or Laser Treatment in the Management of Diabetic Macular Edema (BOLT) study.^[7]

Ranibizumab (Lucentis; Genentech, Inc., San Francisco, CA, USA) is a VEGF-A monoclonal antibody fragment. Ranibizumab was shown to be effective in the RISE and RIDE studies. It gained FDA approval as an intravitreal anti-VEGF drug for DME management.^[8]

The most recent drug, aflibercept (Eylea; Bayer Pharma AG, Berlin, Germany), is a fusion protein that acts as a decoy receptor binding all VEGF-A isoforms, VEGF-B, and placental growth factor (PlGF). It gained FDA approval in DME management after the results of the VIVID and VISTA studies.^[9]

Recently, a direct comparison between the three drugs in the treatment of DME was published by the Diabetic Retinopathy Clinical Research Network (Protocol T). The results showed that when baseline diminution of vision was not severe ($>20/40$), the three drugs produced the same results. However, when the initial best-corrected visual acuity (BCVA) was more affected ($<20/50$), a more functional benefit was noticed in the aflibercept group.^[6]

Due to its lower price, bevacizumab intravitreal injection is the first-line treatment of DME in many parts of the world.^[10] It produces good results in many patients suffering from DME. However, even in patients with improved vision, it is not uncommon to see persistent fluid on optical coherence tomography (OCT) in bevacizumab-treated patients undergoing monthly injections.^[11]

Despite regular monthly treatment, a group of patients shows an incomplete response to anti-VEGF agents. According to Protocol T, after 6 monthly injections, 41% of bevacizumab group had persistent central macular edema in contrast with 27% of patients in the aflibercept group.^[6]

The presence of chronic fluid in the macula can cause permanent structural damage in the retina leading to irreversible visual loss.^[12]

Many studies reported that a group of DME patients has a poor response to bevacizumab.^[11,13] Since aflibercept has some theoretical advantages over bevacizumab, it seems logical to convert their treatments to aflibercept in order to obtain better results.^[14] Several studies reported different outcomes following this approach.^[15-17]

The aim of this study is to prospectively document the functional and anatomical effects of switching from bevacizumab to aflibercept in patients with persistent DME resistant to bevacizumab.

Materials and Methods

This prospective interventional case series was conducted in accordance with the tenets of the Declaration of Helsinki. The study was approved by the university ethics committee (Alexandria faculty of medicine ethics committee: IRB No:00007555-FWANO:00018699). Informed consent was obtained from all study patients before participating in the study.

Patients with DME refractory to bevacizumab (1.25 mg/0.05 mL) were subsequently converted to aflibercept (2 mg/0.05 mL). Eligible patients were diabetic patients, older than 18 years, center-involving DME, and central macular thickness (CMT) $> 300 \mu\text{m}$ by spectral-domain OCT (SD-OCT) performed with the commercially available Cirrus HD-OCT Model 4000 (Carl Zeiss Meditec, Dublin, CA, USA). The mean CMT was measured in the 1 mm central and was automatically generated. Included eyes must have received six consecutive monthly intravitreal injections of bevacizumab for the treatment of DME, presenting with persistent central fluid and CMT $> 300 \mu\text{m}$ 1 month after the last bevacizumab injection. The BCVA must be better than 0.05 decimal visual acuity (1.3 logMAR). Only one eye from each patient was included in the study. If both eyes met the inclusion criteria, the eye with worse visual acuity was included. The other eye was treated but not included in the study.

Patients were excluded if they had dense media opacity, pregnancy, previous intravitreal steroid therapy, uncontrolled DM ($\text{HbA1c} \geq 10\%$), and prior intraocular surgery (with the exception of uneventful cataract surgery > 6 months prior to conversion). Other exclusion criteria included active proliferative diabetic retinopathy, tractional maculopathy, macular ischemia, and other ocular diseases: age-related macular degeneration (AMD), central/branch retinal vein occlusion, and glaucoma.

Decimal BCVA was used and converted into logarithm of the minimal angle of resolution (logMAR). The baseline data were recorded 1 month after the last Bevacizumab injection. The first intravitreal aflibercept injection was given after a washout period of 1 month.

Included patients were given 5 monthly injections of intravitreal aflibercept (2 mg/0.05 mL) (Eylea; Bayer, Berlin, Germany). Then, additional injections were given every 2 months. The follow-up duration was 1 year. Included patients were subjected to baseline evaluation, then monthly after the first aflibercept. At each visit, a complete ophthalmic examination was done, including BCVA assessment on a decimal chart and CMT measured using SD-OCT (Carl Zeiss Meditec, Dublin, CA, USA).

Fluorescein angiography was performed using a Kowa VX-10α Fundus camera (Kowa Company Ltd., Nagoya, Japan) at the initial visit and at the end of follow-up.

Intravitreal aflibercept injections were performed in the operating room using a strict aseptic technique. Topical anesthetic drops were given. Sterilization by povidone-iodine was done. 30-gauge needles were used to give the intravitreal injections.

Statistical analysis was done using the Statistical Package for Social Sciences (SPSS, version 22; SPSS Inc., Chicago, Illinois, USA). The statistical tests used were as follows: number and percentage of each category, mean and standard deviation for each parameter, Mann–Whitney U-test for comparison of non-parametric data, T-test for comparison of parametric data, and Pearson correlation coefficient for finding the correlation between two variables. The 5% was chosen as the cutoff level of significance.

Results

This study included 37 eyes of 37 participants. The mean age of the patients was 56.81 ± 7.11 years. There were 10 (27.0%) males and 27 (73.0%) females. Eight patients (21.6%) had type I DM, while 29 patients (78.3%) had type II DM. Nineteen (51.4%) patients were also treated for hypertension and 9 (24.3%) patients were treated for ischemic heart disease. Thirteen (35.1%) patients were pseudophakics, 4 (10.8%) patients had previous panretinal photocoagulation, and 11 (29.7%) patients had previous argon macular focal laser. The baseline HbA1c ranged from 7.5% to 9.3%, with a mean of $8.3 \pm 0.5\%$.

The mean CMT before initiating bevacizumab injections was $460.15 \pm 85.20 \mu\text{m}$ which only was mildly improved to $428.32 \pm 84.89 \mu\text{m}$ after the 6 monthly bevacizumab injections before switching to aflibercept.

The mean best-corrected logMAR visual acuity before initiating bevacizumab injections was 0.720 ± 0.260 which only was mildly improved to 0.627 ± 0.307 after the 6 monthly bevacizumab injections before switching to aflibercept.

The pattern of baseline DME before switching was as follows: combined diffuse and cystoid DME was present in all 37 patients (100%), while subretinal fluid was present in 9 patients (24.3%). Vitreomacular adhesion at the macula was detected in 3 patients (8.1%), while epiretinal membrane at the baseline was detected in 2 patients (5.4%).

All patients had previous 6 monthly intravitreal bevacizumab injections over a 6-month period. All

patients completed 12-month follow-up after the first aflibercept injection. All patients received 8 aflibercept injections: 5 monthly loading dose and 3 bimonthly injections. The final data were recorded 2 months after the 8th injection at the 12-month follow-up visit.

Anatomical outcomes after switching to aflibercept

The mean CMT at baseline was $428.32 \pm 84.89 \mu\text{m}$, which decreased significantly to $275.54 \pm 50.24 \mu\text{m}$ ($P < 0.003$). The change in CMT over the study duration is illustrated in Figure 1. There was a decrease in CMT at different follow-up visits, and this was statistically significant, starting from the 2nd month till the end of the study. All patients had reduced CMT at the end of the follow-up compared to their baseline values. Twenty-eight patients (75.7%) had more than 50 μm reduction in CMT at the end of follow-up compared to baseline, while 9 patients (24.3%) had $< 50 \mu\text{m}$ reduction in CMT [Table 1].

At baseline, 14 patients (37.8%) had CMT $> 400 \mu\text{m}$. At the end of follow-up, all patients had CMT $< 400 \mu\text{m}$.

Table 1: Central macular thickness at baseline and at different periods of follow-up

	$< 400 \mu\text{m},$ $n (\%)$	$> 400 \mu\text{m},$ $n (\%)$	Mean \pm SD (μm)	Range (μm)	P
At baseline	23 (62.2)	14 (37.8)	428.32 \pm 84.89	345-607	
1 m	23 (62.2)	14 (37.8)	403.16 \pm 69.25	330-548	0.123
2 m	25 (67.6)	12 (32.4)	375.19 \pm 58.35	300-510	0.041*
3 m	28 (75.7)	9 (24.3)	359.62 \pm 50.16	266-491	0.036*
4 m	31 (83.8)	6 (16.2)	338.57 \pm 58.48	270-435	0.032*
5 m	31 (83.8)	6 (16.2)	335.84 \pm 39.15	275-420	0.031*
6 m	34 (91.9)	3 (8.1)	335.19 \pm 57.40	260-497	0.03*
7 m	37 (100.0)	0 (0.0)	316.00 \pm 37.99	250-390	0.029*
8 m	37 (100.0)	0 (0.0)	305.62 \pm 48.02	200-380	0.022*
9 m	37 (100.0)	0 (0.0)	302.11 \pm 49.01	200-385	0.02*
10 m	37 (100.0)	0 (0.0)	287.59 \pm 46.44	205-387	0.013*
11 m	37 (100.0)	0 (0.0)	281.43 \pm 49.05	197-382	0.005*
12 m	37 (100.0)	0 (0.0)	275.54 \pm 50.24	194-380	0.003*

SD=Standard deviation

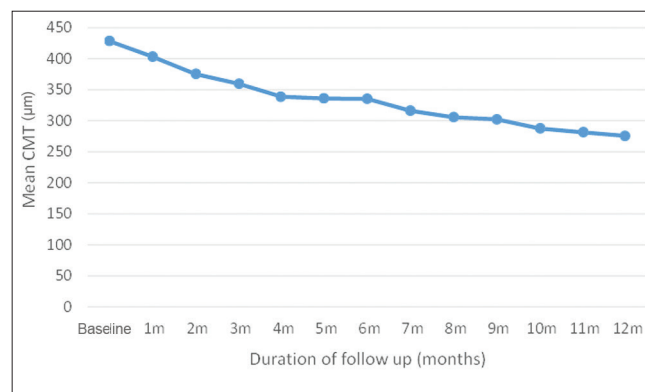


Figure 1: Central macular thickness at baseline and at different periods of follow-up

Complete anatomic response, defined as CMT < 300 μm with no fluid on OCT, was detected in 22 patients (59.4%).

Functional outcomes after switching to aflibercept

There was a significant improvement in the mean best-corrected logMAR visual acuity from 0.627 ± 0.307 at baseline to 0.203 ± 0.235 ($P < 0.017$) at the end of follow-up. Figure 2 shows the change in the BCVA at different time points of the study. After switching from bevacizumab to aflibercept, BCVA improved in 34 eyes (91.9%), remained stable in 3 eyes (9.1%), and there were no cases of deterioration of visual acuity. There was an improvement in visual acuity from the 1st month of follow-up, but it reached a statistically significant level from the 5th follow-up visit till the end of follow-up. At baseline, 11 patients (29.7%) had 6/60 (0.1 decimal VA) or less visual acuity, while at the end of follow-up, all patients had visual acuity better than 6/60. The initial visual acuity of 6/12 or better was present in 3 patients (8.1%), in comparison with 24 patients (64.9%) at the end of the study [Table 2].

Table 2: Best-corrected visual acuity (logMAR) at baseline and at different periods of follow-up

	<0.30, n (%)	>0.30, n (%)	Range	Mean±SD	P
At baseline	3 (8.1)	34 (91.9)	0.2-1	0.627±0.307	
1 m	3 (8.1)	34 (91.9)	0.2-1	0.616±0.267	0.32
2 m	3 (8.1)	34 (91.9)	0.2-1	0.559±0.253	0.13
3 m	4 (10.8)	33 (89.2)	0.2-1	0.559±0.266	0.15
4 m	4 (10.8)	33 (89.2)	0-1	0.478±0.253	0.106
5 m	4 (10.8)	33 (89.2)	0-0.8	0.435±0.229	0.046*
6 m	7 (18.9)	30 (81.1)	0-0.8	0.403±0.232	0.044*
7 m	12 (32.4)	25 (67.6)	0-0.8	0.405±0.260	0.042*
8 m	12 (32.4)	25 (67.6)	0-0.8	0.357±0.214	0.04*
9 m	12 (32.4)	25 (67.6)	0-0.8	0.341±0.233	0.031*
10 m	15 (40.5)	22 (59.5)	0-0.6	0.286±0.195	0.021*
11 m	24 (64.9)	13 (35.1)	0-0.6	0.219±0.227	0.011*
12 m	24 (64.9)	13 (35.1)	0-0.6	0.203±0.235	0.017*

SD=Standard deviation

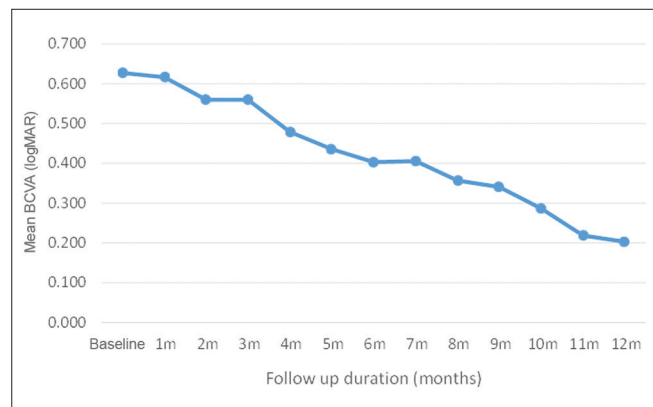


Figure 2: Best-corrected visual acuity (logMAR) at baseline and at different periods of follow-up

Figures 3 and 4 show the OCT of a case at baseline and at the end of follow-up.

There were no significant correlations between baseline characteristics and the anatomic or functional improvement, except for one baseline factor: initial CMT. Baseline CMT more than 400 μm was associated with a significant decrease in CMT and significant visual acuity improvement compared to baseline CMT < 400 μm.

There were no recorded cases of major complications of intravitreal injections either ocular or systemic. Only mild subconjunctival hemorrhage was recorded after 15 injections out of 296 (5% of injections).

Discussion

Intravitreal anti-VEGF injections became the treatment of choice for center-involving DME. Bevacizumab, although not FDA approved, is widely used because of its low cost.^[6] Not all patients respond well to bevacizumab, so the idea of switching to aflibercept was considered.^[15-17]

Aflibercept molecule is different from other anti-VEGF agents: It binds VEGF-A with over 100 times stronger than either ranibizumab or bevacizumab.^[18] Aflibercept additionally binds VEGF-B and PlGF, which both have been implicated in the pathogenesis of DME.^[19] Aflibercept, unlike bevacizumab, does not contain murine antibody components, which can initiate a systemic immune response leading to tachyphylaxis. Conversion to aflibercept may overcome any previous tolerance to anti-VEGF proteins.^[20]

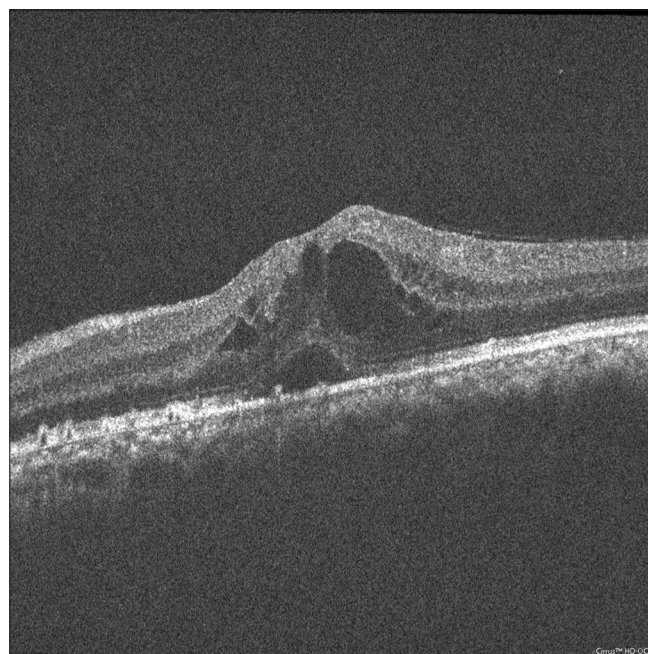


Figure 3: Patient at baseline, central macular thickness 450 μm, best-corrected visual acuity 6/36

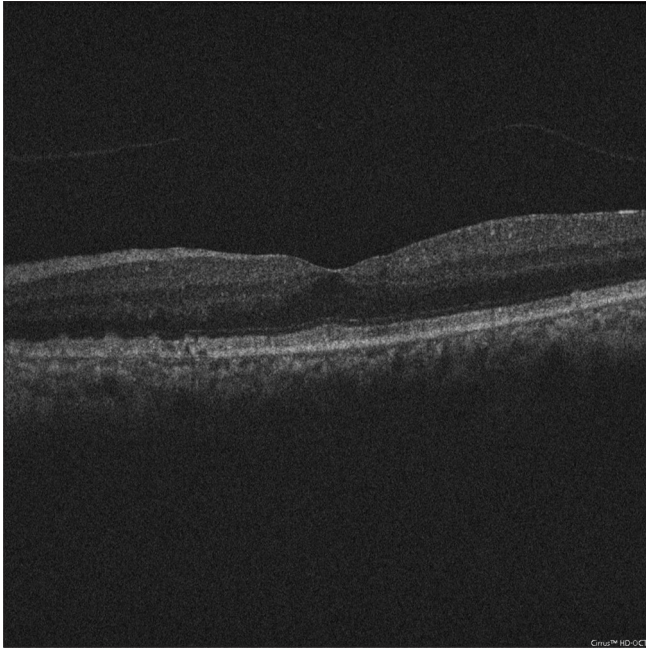


Figure 4: Patient at the end of follow-up, central macular thickness 270 μm, best-corrected visual acuity 6/9

Multiple studies were reported regarding the effects of switching between anti-VEGFs in exudative AMD. Switching to aflibercept in wet AMD showed variable results. In general, there was an anatomical improvement with less visual benefit.^[21-23]

Recently, few studies reported short-term results about the switch from bevacizumab to aflibercept in resistant cases of DME.^[15-17] This study aimed to prospectively document the 1-year outcome of switching to aflibercept in bevacizumab resistant cases of DME. Our results show a statistically significant benefit, both anatomically and functionally after switch to aflibercept.

One previous retrospective study^[17] included 50 eyes converted to aflibercept after prior ranibizumab or bevacizumab injections. Patients had a high number of injections (mean: 13.7) before the switch. The mean number of aflibercept injections was 4.1 and the follow-up duration after the switch was 4.6 months. The reported results showed a statistically significant improvement in CMT with statistically insignificant visual acuity improvement. These patients had a long duration of DME before the switch, so the chronic edema may have affected the visual outcome. Furthermore, the short follow-up duration (4.6 months) may have prevented the detection of significant visual improvement. In our study, the visual improvement reached a statistically significant level at the 5-month follow-up point.

Another retrospective study^[15] included 21 patients with persistent DME after ranibizumab or bevacizumab injections. Patients received three aflibercept injections and the duration

of follow-up was 5 months. Their results showed statistically significant anatomic and functional improvement.

One prospective study^[16] of 14 patients reported 1-month outcome of a single aflibercept injection for DME refractory to ranibizumab or bevacizumab. Their results showed that 11 patients (79%) had statistically significant CMT improvement. Visual acuity improved in 3 patients (21%) after a single aflibercept injection.

Our results support the important role of aflibercept in patients with DME who are refractory to bevacizumab injections. A statistically significant improvement in CMT was detected starting from the 2nd month of follow-up, while statistically significant visual improvement started from the 5th follow-up month. This means that functional improvement lags behind anatomic improvement, so studies with short follow-up duration will not probably detect significant visual gain.

The ideal time for switching from bevacizumab to aflibercept is a matter of debate. Proponents of early switching argue that chronic edema can cause irreversible photoreceptor damage.^[11] Protocol I analysis showed that patients with less response after three injections had a poor response at the end of 3 years.^[24] Others say that some DME patients are late responders, improving after a long period of treatment.^[11] Analysis from the RISE and RIDE studies reported that patients with a poor initial response after three injections achieved the same final visual acuity as those with a good initial response.^[25] In this study, the time of conversion to aflibercept was after 6 monthly bevacizumab injections. This was considered an intermediate period of treatment that allows achievement of the best possible outcome.

At the end of 1 year of follow-up, complete resolution of DME was detected in 59.4% of patients, with 64.9% having 6/12 or better visual acuity. This is a good anatomic and functional outcome in this group of refractory cases. Rahimy *et al.*^[17] reported 24% resolution of edema at the end of 4.6 months of follow-up. It seems that continuing the treatment produces additional benefit in most patients. DME is a multifactorial disease; we do not expect all patients to respond to anti-VEGFs.

There was a short washout period between bevacizumab and aflibercept injections (only 1 month); we thought that delaying the treatment may affect the chances of patients' improvement. Thus, a carryover effect of bevacizumab cannot be excluded. In the VIVID and VISTA studies, the washout period was 3 months. This long period of treatment delay caused the edema to increase leading to worse baseline characteristics with exaggeration of the treatment benefit.^[13]

One of our patients (2.7%) showed mild central macular thinning of 197 and 194 μm at the months 11 and 12, respectively. This patient had improved visual acuity and this thinning was not associated with loss of visual function. One study^[26] evaluated the frequency of central retinal thickness below 200 μm in patients treated for DME. They detected macular thinning in 16% of the included patients with no affection of visual acuity. They concluded that central macular thinning below 200 μm does not seem to be affect visual function in patients treated for DME.

In this study, there was no fluctuation in the CMT after switching from monthly to bimonthly aflibercept injections. It seems that aflibercept has a long duration of action covering the 2-month duration, especially after the 5 monthly injection loading dose.

Conclusion

This study aimed to address the group of patients with persistent DME after monthly bevacizumab injections. Switching to aflibercept with a fixed regimen produced significant anatomic and functional benefits in this commonly encountered group of DME patients.

The limitations of this study include the small number of patients and the absence of a control group. Randomized prospective clinical trials comparing treatment regimens for refractory DME will be useful to further support our results.

Financial support and sponsorship
Nil.

Conflicts of interest

The authors declare that there are no conflicts of interests of this paper.

References

1. Klein R, Klein BE, Moss SE. Visual impairment in diabetes. *Ophthalmology* 1984;91:1-9.
2. Ding J, Wong TY. Current epidemiology of diabetic retinopathy and diabetic macular edema. *Curr Diab Rep* 2012;12:346-54.
3. Photocoagulation for Diabetic Macular Edema. Early Treatment Diabetic Retinopathy Study Report Number 1. Early Treatment Diabetic Retinopathy Study Research Group. *Arch Ophthalmol* 1985;103:1796-806.
4. Zhang C, Wang H, Nie J, Wang F. Protective factors in diabetic retinopathy: Focus on blood-retinal barrier. *Discov Med* 2014;18:105-12.
5. Behl T, Kotwani A. Exploring the various aspects of the pathological role of vascular endothelial growth factor (VEGF) in diabetic retinopathy. *Pharmacol Res* 2015;99:137-48.
6. Wells JA, Glassman AR, Ayala AR, Jampol LM, Aiello LP, Antoszyk AN, *et al.* Aflibercept, bevacizumab, or ranibizumab for diabetic macular edema. *N Engl J Med* 2015;372:1193-203.
7. Rajendram R, Fraser-Bell S, Kaines A, Michaelides MM,

- Hamilton RD, Esposti SD, *et al.* A 2-year prospective randomized controlled trial of intravitreal bevacizumab or laser therapy (BOLT) in the management of diabetic macular edema: 24-month data: Report 3. *Arch Ophthalmol* 2012;130:972-79.
8. Nguyen QD, Brown DM, Marcus DM, Boyer DS, Patel S, Feiner L, Gibson A, Sy J, Rundle AC, Hopkins JJ, Rubio RG, Ehrlich JS; RISE and RIDE Research Group. Ranibizumab for diabetic macular edema: results from 2 phase III randomized trials: RISE and RIDE. *Ophthalmology*. 2012 Apr;119(4):789-801.
9. Brown DM, Schmidt-Erfurth U, Do DV, Holz FG, Boyer DS, Midena E, *et al.* Intravitreal aflibercept for diabetic macular edema: 100-week results from the VISTA and VIVID studies. *Ophthalmology* 2015;122:2044-52.
10. Ross EL, Hutton DW, Stein JD, Bressler NM, Jampol LM, Glassman AR, *et al.* Cost-effectiveness of aflibercept, bevacizumab, and ranibizumab for diabetic macular edema treatment: analysis from the diabetic retinopathy clinical research network comparative effectiveness trial. *JAMA Ophthalmol* 2016;134:888-96.
11. Hussain RM, Ciulla TA. Treatment strategies for refractory diabetic macular edema: Switching anti-VEGF treatments, adopting corticosteroid-based treatments, and combination therapy. *Expert Opin Biol Ther* 2016;16:365-74.
12. Nguyen QD, Tatlipinar S, Shah SM, Haller JA, Quinlan E, Sung J, *et al.* Vascular endothelial growth factor is a critical stimulus for diabetic macular edema. *Am J Ophthalmol* 2006;142:961-9.
13. Do DV, Nguyen QD, Vitti R, Berliner AJ, Gibson A, Saroj N, *et al.* Intravitreal aflibercept injection in diabetic macular edema patients with and without prior anti-vascular endothelial growth factor treatment: outcomes from the phase 3 program. *Ophthalmology* 2016;123:850-57.
14. Ehlik C, Jungmann S, Bohringer D, Agostini HT, Junker B, Pielen A. Switch of anti-VEGF agents is an option for nonresponders in the treatment of AMD. *Eye (Lond)* 2014;28:538-45.
15. Lim LS, Ng WY, Mathur R, Wong D, Wong EY, Yeo I, *et al.* Conversion to aflibercept for diabetic macular edema unresponsive to ranibizumab or bevacizumab. *Clin Ophthalmol* 2015;9:1715-18.
16. Wood EH, Karth PA, Moshfeghi DM, Leng T. Short-term outcomes of aflibercept therapy for diabetic macular edema in patients with incomplete response to ranibizumab and/or bevacizumab. *Ophthalmic Surg Lasers Imaging Retina* 2015;46:950-54.
17. Rahimy E, Shahlaee A, Khan MA, Ying GS, Maguire JJ, Ho AC, *et al.* Conversion to aflibercept after prior anti-VEGF therapy for persistent diabetic macular edema. *Am J Ophthalmol* 2016;164:118-27.
18. Stewart MW, Rosenfeld PJ, Penha FM, Wang F, Yehoshua Z, Bueno-Lopez E, *et al.* Pharmacokinetic rationale for dosing every 2 weeks versus 4 weeks with intravitreal ranibizumab, bevacizumab, and aflibercept (vascular endothelial growth factor Trap-eye). *Retina* 2012;32:434-57.
19. Vandekerckhove KR. Aflibercept versus ranibizumab for treating persistent diabetic macular oedema. *Int Ophthalmol* 2015;35:603-9.
20. Forooghian F, Cukras C, Meyerle CB, Chew EY, Wong WT. Tachyphylaxis after intravitreal bevacizumab for exudative age-related macular degeneration. *Retina* 2009;29:723-31.
21. Arcinue CA, Ma F, Barteselli G, Sharpsten L, Gomez ML, Freeman WR. One-year outcomes of aflibercept in recurrent or persistent neovascular age-related macular degeneration. *Am J Ophthalmol* 2015;159:426-36.e422.
22. Fasnacht-Riederle H, Becker M, Graf N, Michels S. Effect of aflibercept in insufficient responders to prior anti-VEGF therapy in neovascular AMD. *Graefes Arch Clin Exp Ophthalmol* 2014;52:1705-9.
23. Cho H, Shah CP, Weber M, and Heier JS. Aflibercept for exudative AMD with persistent fluid on ranibizumab and/or bevacizumab. *Br J Ophthalmol* 2013;97:1032-35.

24. Ashraf M, Souka A, Adelman R, Forster SH. Aflibercept in diabetic macular edema: evaluating efficacy as a primary and secondary therapeutic option. *Eye (Lond)* 2016;30:1531-41.
25. Pieramici DJ, Wang PW, Ding B, Gune S. Visual and anatomic outcomes in patients with diabetic macular edema with limited initial anatomic response to ranibizumab in RIDE and RISE. *Ophthalmology* 2016;123:1345-50.
26. Prager SG, Schuster M, Mitsch C, Lammer J, Scholda CD, Schmidt-Erfurth U, *et al.* Thinning of the central neurosensory retina during anti-VEGF treatment of diabetic retinopathy. *Invest Ophthalmol Vis Sci* 2015;56:1736.