

## CASE LETTER

### Hidradenocarcinoma<sup>☆,☆☆</sup>



Dear editor,

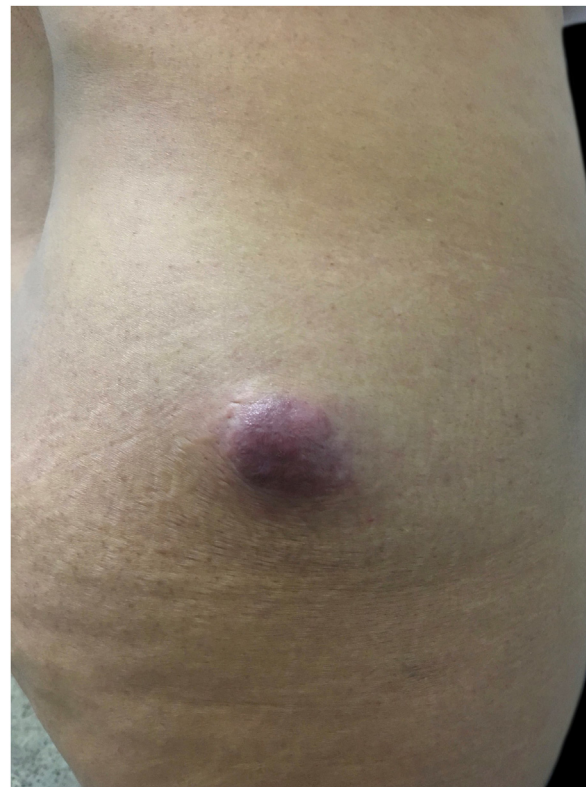Cutaneous hidradenocarcinoma is a rare malignant neoplasm, originating from the eccrine sweat glands, and corresponding to 6% of the eccrine malignant tumors. It presents as a solitary, asymptomatic, slow-growing skin lesion, and may take an aggressive clinical course, with lymph node involvement and distant metastases.<sup>1,2</sup>

Classically, it is a carcinoma reported with *de novo* onset, with no signs of previous hidradenoma. It most often affects patients from the fourth decade of life onwards.<sup>3</sup> Classically, the head and neck are the most affected sites; however, it has been reported in several locations.<sup>4</sup>

In this study, the authors report the case of a 42-year-old female patient who sought care during the National Skin Cancer Campaign complaining of a nine-month-old lesion on the buttock. Dermatological examination evidenced the presence of an erythematous, hardened, asymptomatic tumor, of approximately 5 cm, located in the lateral region of the right gluteus with nine months of evolution (Fig. 1). She denied any trauma or previous injuries at the site.

In view of the clinical picture, the hypotheses of dermatofibrosarcoma and proximal epitheloid sarcoma were raised. A 5-mm punch biopsy was performed for histopathological examination which revealed nests and cords of cuboidal cells in the deep dermis, with eosinophilic cytoplasm, mildly pleomorphic and hyperchromatic nuclei, and formation of tubular structures and ductal lumens, arranged in a myxoid and collagenous stroma, compatible with a skin adnexal tumor (Fig. 2).

The patient returned two months after the biopsy; an increase in the size of the lesion and elimination of continuous hyaline secretion were observed. Spindle-shaped excision was performed, with a safety margin of 2 cm, without recurrence of the lesion after 12 months of follow-up. The immunohistochemical analysis of the excised lesion was positive for cytokeratins of 40, 48, 50, and 50.6 kDa (AE1/AE3), p63 protein (DAK-p63), epithelial tumor gly-

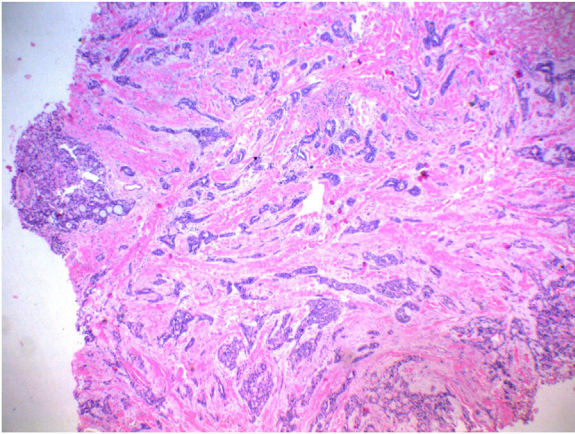


**Figure 1** Asymptomatic, hardened, erythematous tumor, of approximately 5 cm, located in the lateral region of the right gluteus.

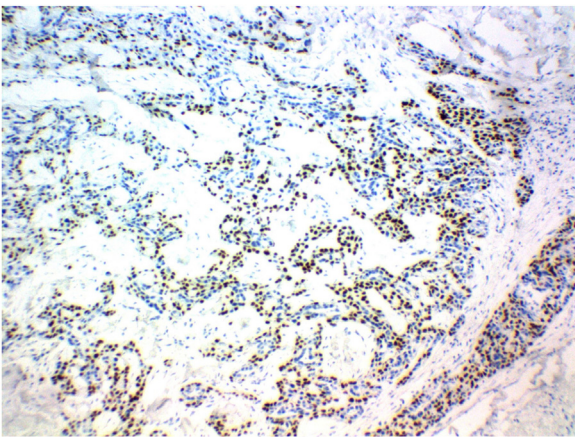
coprotein (BerEp4), and carcinoembryonic antigen – CEA (polyclonal). Partial positivity was observed for epithelial membrane antigen – EMA (E29). Histopathological and immunohistochemical findings favored the diagnosis of hidradenocarcinoma. Tumor blood markers, such as lactic dehydrogenase (DHL), alpha-fetoprotein, and CEA, were normal. Computed tomography (CT) of the abdomen and pelvis without contrast showed the presence of an oval mass with defined contours and margins in the right iliac fossa (ipsilateral to the excised tumor) adjacent to the sartorius muscle, measuring about 4.2 × 2.2 cm, heterogeneous, with areas of soft tissue density (32 uH) and interspaced slightly hypodense areas, with apparently non-specific liquid den-

<sup>☆</sup> How to cite this article: Lima AA, Santos M, Morais PM, Rodrigues CAC. Hidradenocarcinoma. An Bras Dermatol. 2021;96:251–3.

<sup>☆☆</sup> Study conducted at the Fundação de Dermatologia Tropical e Venereologia Alfredo da Matta, Manaus, AM, Brazil.



**Figure 2** Presence, in the deep dermis, of nests and cords of cuboid cells, with eosinophilic cytoplasm, mildly pleomorphic and hyperchromatic, forming tubular structures and ductal lumens, arranged in a myxoid and collagenous stroma, compatible with adnexal skin tumor (Hematoxylin & eosin,  $\times 40$ ).



**Figure 3** Immunohistochemical expression of p63 protein, favoring the diagnosis of metastatic hidradenocarcinoma (P63,  $\times 100$ ).

sity. No abnormalities were observed in the abdominal and pelvic organs.

The patient was referred to an oncologic center. Seven months after the first approach, she underwent another surgery, performed by a surgical oncologist, to remove the oval mass in the right iliac fossa identified by CT of the pelvis. The histopathological study showed malignant neoplasia infiltration of the lymph node, consisting of the proliferation of cells with clear eosinophilic cytoplasm, vesicular nucleus, and evident nucleolus, with foci of ductal differentiation and solid areas, with frequent necrosis and numerous mitoses. The immunohistochemical panel of the affected lymph node showed expression of p63 protein, in addition to EMA and cytokeratin in the ductal areas, favoring the diagnosis of metastatic hidradenocarcinoma (Fig. 3). One year after diagnosis, the patient is being followed-up at the state oncology reference service, with no signs of local recurrence.

The diagnosis of hidradenocarcinoma is fundamentally based on histopathological and immunohistochemical find-

ings. A panel positive for p63, CK15 and D2-40 is observed preferentially in primary adnexal tumors, while the negativity for these markers is found preferentially in skin metastases.<sup>5</sup> In this report, the finding of immunoreactivity with p63 suggests that it was a primary adnexal neoplasia. Local recurrence of hidradenocarcinoma is observed in more than 50% of cases, and distant metastases are observed in approximately 60% of cases, mainly in lymph nodes, lungs, and bones, which is why it is necessary to keep following-up these patients and screening for metastases. The differential diagnosis is challenging because the lesion looks benign and similar to other skin tumors. Hidradenoma (benign variant), lipoma, hemangioma, lymphangioma, squamous cell carcinoma, basal cell carcinoma, malignant melanoma, dermatofibrosarcoma, and other benign and malignant adnexal tumors, in addition to metastatic tumors for the skin, are reported as differential diagnoses. The treatment of choice is complete surgical excision of the lesion with a wide safety margin. Due to the high local recurrence and regional lymph node involvement, surgery with a wide safety margin, not specified in the literature, and resection of regional lymph nodes followed by postoperative radiotherapy appear to be the appropriate initial therapy.<sup>5</sup> It is important to highlight the role of the National Cancer Campaign carried out by the Brazilian Society of Dermatology, where the patient was first seen.

### Financial support

None declared.

### Authors' contributions

Andrey Amorim de Lima: Drafting and editing of the manuscript; critical review of the manuscript.

Monica Santos: Approval of the final version of the manuscript; design and planning of the study; drafting and editing of the manuscript; intellectual participation in propaedeutic and/or therapeutic conduct of the studied cases; critical review of the literature; critical review of the manuscript.

Patricia Motta de Moraes: Intellectual participation in propaedeutic and/or therapeutic conduct of the studied cases; critical review of the literature.

Carlos Alberto Chirano Rodrigues: Intellectual participation in propaedeutic and/or therapeutic conduct of the studied cases.

### Conflicts of Interest

None declared.

### References

1. Cleaveland P, Srivastava P, Oliveira P, Parnham A, Elliott T, Sangar V. A rare presentation of hidradenocarcinoma within the pênis. *Urol Case Rep.* 2019;22:57–9.
2. Elbenaye J, Moumine M, Sinaa M, Elhaouri M. Fatal hidradenocarcinoma of the scalp: a case report. *Eur Ann Otorhinolaryngol Head Neck Dis.* 2017;134:291–2.

3. Ryu WC, Lee YH, Koh IC, Sohn JS, Jang SM, Jang SM. Hidradenocarcinoma of the Dorsum of the Hand. *Chin Med J (Engl)*. 2017;130:1755–6.
4. Miller DH, Peterson JL, Buskirk SJ, Vallow LA, Ta R, Joseph R, et al. Management of metastatic apocrine hidradenocarcinoma with chemotherapy and radiation. *Rare Tumors*. 2015; 7:6082.
5. Hoang MP. Role of immunohistochemistry in diagnosing tumors of cutaneous appendages. *Am J Dermatopathol*. 2011;33: 765–71.

Andrey Amorim de Lima <sup>a,\*</sup>, Monica Santos <sup>a</sup>,  
 Patricia Motta de Moraes <sup>b</sup>,  
 Carlos Alberto Chirano Rodrigues <sup>c</sup>

<sup>a</sup> Teaching and Research Department, Fundação de Dermatologia Tropical e Venereologia Alfredo da Matta, Manaus, AM, Brazil

<sup>b</sup> Department of Dermatopathology, Fundação de Dermatologia Tropical e Venereologia Alfredo da Matta, Manaus, AM, Brazil

<sup>c</sup> Department of Dermatological Surgery, Fundação de Dermatologia Tropical e Venereologia Alfredo da Matta, Manaus, AM, Brazil

\* Corresponding author.

E-mail: [amorim\\_andrey@hotmail.com](mailto:amorim_andrey@hotmail.com) (A.A. de Lima).

Received 21 December 2019; accepted 5 March 2020

Available online 5 February 2021

<https://doi.org/10.1016/j.abd.2020.03.023>

0365-0596/ © 2021 Sociedade Brasileira de Dermatologia.

Published by Elsevier España, S.L.U. This is an open access article under the CC BY license (<http://creativecommons.org/licenses/by/4.0/>).

## A late diagnosis of hyperhomocysteinemia with probable evolution to verrucous elephantiasis nostra and leg ulcers<sup>☆,☆☆</sup>



Dear editor,

Homocysteine is an intermediate amino acid derived from the metabolism of methionine into cysteine, with a demonstrated association with oxidative stress and endothelial damage.<sup>1</sup>

Hyperhomocysteinemia can be caused by genetic disorders in metabolic pathways, nutritional deficiency, renal failure, hypothyroidism, diabetes, and smoking.<sup>1–3</sup> It is an important risk factor for cardiovascular mortality in patients with a history of myocardial infarction, stroke, angina, diabetes, or hypertension.<sup>2</sup>

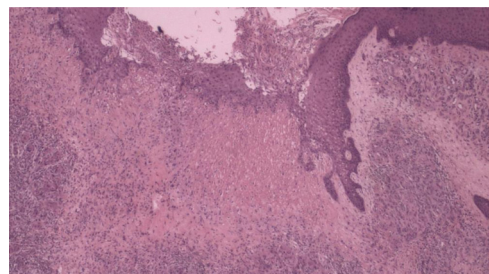
A black male patient, 60 years old, started follow-up with the dermatology service in 2011 due to symptoms of xerosis and lower limb edema in the last eight years. At the time, a biopsy was performed and revealed thickening of the epidermis, acanthosis, lengthening of the grooves, and deposits of dermal mucin. Colloidal iron staining was positive and Congo red staining was negative, the clinical and pathological diagnosis was pre-tibial myxedema.

The patient developed thrombophlebitis in the left lower limb, with no deep venous thrombosis. The authors decided to initiate antibiotic therapy for erysipela and, subsequently, prophylactic intramuscular benzathine benzylpenicillin was prescribed every 21 days. Topical care was

performed with the use of dressings containing collagenase and chloramphenicol.

During evolution, periods of healing were interspersed with worsening. In 2018, when thrombophilia tests became available at the health institution, a panel for hypercoagulable states was performed: protein C and S dosages, antithrombin, total complement and C3, prothrombin gene, Leiden factor mutation, anticardiolipin and lupus antibodies, protein electrophoresis, and ANA, were all within the normal range. There were, serum homocysteine levels of 17.8  $\mu\text{mol/L}$  (normal range: 5 to 12  $\mu\text{mol/L}$ ) and heterozygosity in segments C677T and A1298C for the methylenetetrahydrofolate reductase (MTHFR) mutation was observed.

Another skin biopsy (Fig. 1) and Doppler ultrasonography of the left lower limb were performed. Histopathologically, there was fibroplasia, newly formed vessels associated with inflammatory lymphocytic infiltrate and a neutrophilic exudate in the dermis. Upon ultrasound examination, varicose veins, incontinence of the great saphenous, and popliteal veins associated with recanalized thrombophlebitis of the great saphenous vein were identified.



**Figure 1** Histopathology demonstrating fibroplasia, newly formed vessels associated with an inflammatory infiltrate containing lymphocytes and neutrophils (Hematoxylin & eosin,  $\times 40$ ).

<sup>☆</sup> How to cite this article: Abdalla BMZ, Oliveira RTG, Afonso RI, CriadoPR. A late diagnosis of hyperhomocysteinemia with probable evolution to verrucous elephantiasis nostra and leg ulcers. *An Bras Dermatol*. 2021;96:253–5.

<sup>☆☆</sup> Study conducted at the Faculdade de Medicina do ABC, Santo André, SP, Brazil.