

Hydropic degeneration of leiomyoma in nongravid uterus: The “split fiber” sign on magnetic resonance imaging

Aruna R. Patil, Shrivalli Nandikoor, Ramya Padilu

Department of Radiology and Pathology, Apollo Hospitals, Bengaluru, Karnataka, India

Correspondence: Dr. Aruna R. Patil, Department of Radiology, Apollo Hospitals, Bannerghatta Road, Bengaluru - 560 076, Karnataka, India. E-mail: dr.arunarpatil@gmail.com

Abstract

Extensive hydropic degeneration in uterine leiomyoma is a rare occurrence and is commonly reported in association with pregnancy. It is a close mimicker of malignancy due to rapid growth and atypical imaging appearances. Awareness of the imaging features helps in diagnosis, avoids unnecessary patient anxiety, and hence reassurance especially when encountered in pregnancy. We report two cases of extensive hydropic degeneration of leiomyoma in nonpregnant females with imaging and histopathology correlation. We also propose the “split fiber” sign as a useful magnetic resonance imaging feature for diagnosing this condition.

Key words: Hydropic degeneration; leiomyoma; magnetic resonance imaging; split fiber sign

Introduction

Extensive hydropic degeneration in uterine leiomyoma is a rare occurrence and is commonly reported in association with pregnancy. It mimics malignancy due to rapid growth and atypical imaging appearances. Awareness of the imaging features helps in diagnosis, avoids unnecessary patient anxiety, and hence reassurance especially when encountered in pregnancy. We report two cases of extensive hydropic degeneration of leiomyoma in nonpregnant females with imaging and histopathology correlation. We also propose the “split fiber” sign as a useful magnetic resonance imaging feature for diagnosing this condition.

Case Reports

Case 1

A 37-year-old female presented to the surgical outpatient department with complaints of lower abdominal distension

and vague pain for 2–3 months. No fever or altered bowel habits were present. Her menstrual cycles were regular. Her last child birth was 8 years ago and was a normal vaginal delivery. No past history of abdominal surgery was elicited. Per abdomen examination revealed a firm mass in central and lower quadrants. She was then referred to radiology department for further evaluation. Transabdominal ultrasonography (USG) was done followed by magnetic resonance imaging (MRI) pelvis.

USG revealed a large predominantly isoechoic (to myometrium) mass with peripheral areas of patchy heteroechogeneity [Figure 1]. It was seen to arise from the posterior uterine wall compressing the uterus. On color Doppler, moderate vascularity was seen in the mass that was closer to the uterine attachment and sparse vessels seen peripherally. A linear defect in myometrium was seen at the mass attachment in continuity with the endometrium.

This is an open access journal, and articles are distributed under the terms of the Creative Commons Attribution-NonCommercial-ShareAlike 4.0 License, which allows others to remix, tweak, and build upon the work non-commercially, as long as appropriate credit is given and the new creations are licensed under the identical terms.

For reprints contact: reprints@medknow.com

Cite this article as: Patil AR, Nandikoor S, Padilu R. Hydropic degeneration of leiomyoma in nongravid uterus: The “split fiber” sign on magnetic resonance imaging. *Indian J Radiol Imaging* 2018;28:182-6.

Access this article online	
<p>Quick Response Code:</p> 	<p>Website: www.ijri.org</p> <p>DOI: 10.4103/ijri.IJRI_214_17</p>

Both ovaries and the endometrium were otherwise unremarkable.

MRI pelvis was done without contrast with routine T1 turbo spin echo (TSE), T2 TSE with and without fat saturation along with diffusion weighted imaging (DWI) and fast field echo (FFE) in orthogonal planes. The origin of the mass from the posterior uterine wall was confirmed on MRI. The mass measured approximately 19 × 16 × 12 cm and extended till supraumbilical level. The mass had roughly two parts. The part that was closer to its origin was isointense to the myometrium with multiple vascular channels within and the periphery showed fluid-like hyperintensity on T2 weighted sequence with sparse vessels [Figure 2A–D]. The peripheral T2 hyperintense zone was divided by multiple curvilinear isointense strands [Figure 2D]. Continuity with the endometrial cavity at the mass attachment was seen at the torus uterinus. No hemorrhagic areas were seen on FFE with DWI showing mild variable restriction. The imaging features were in concern for malignancy and a provisional diagnosis of primary sarcoma or sarcomatous change in a fibroid or aggressive angiomyxoma was considered. Possible trans myoendometrial extension and fistulization with the cavity was sought. Exploratory laparotomy with hysterectomy was done, which revealed a large exophytic mass arising from the posterior uterine wall. Cut section revealed a severely edematous tissue in periphery with firm tissue and prominent blood vessels at the attachment site. Histopathology showed extensive fluid accumulation between the smooth muscle proliferation along with cystic changes [Figure 3] along with few preserved areas of more compactly arranged whorls of smooth muscle cells. No obvious myxomatous areas were seen.

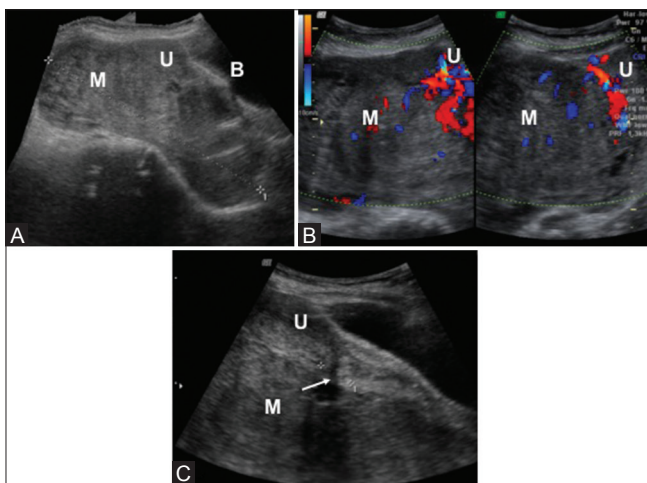


Figure 1 (A-C): (A and C) Transabdominal ultrasonography in sagittal plane shows a large mass predominantly isoechoic to the myometrium with peripheral heteroechoic areas related posteriorly to the uterus compressing the same with suspicious luminal communication (white arrow in C). (B) On Doppler USG, the mass shows prominent vascularity especially near its uterine attachment. (M –mass, U-uterus, B- urinary bladder)

Case 2

A 47-year-old female with dysmenorrhea was referred to radiology department for an USG examination of the pelvis. Her menstrual cycles were irregular and painful for 4–5 months period. No other relevant history was elicited. On transabdominal USG, the uterus was mildly enlarged. A posterior intramural fibroid was seen. Endometrial cavity revealed a heteroechoic mass with linear echogenic areas measuring 9 × 5 cm [Figure 4]. The mass showed very minimal peripheral vascularity. Endometrial mass versus a degenerated submucosal fibroid was considered as possibilities and a MRI pelvis with contrast was ordered.

On MRI, the mass was predominantly hyperintense on T2 weighted sequence and isointense on T1 weighted sequence. On T2, curvilinear hypointense strands were noticed [Figure 5]. The mass was submucosal arising from the anterior wall with focal isointensity at the attachment site. Minimal fluid was seen within the endometrial cavity. On gadolinium contrast, minimal linear enhancement was seen. The posterior intramural fibroid showed avid enhancement. Based on the imaging features, degeneration (myxomatous/hydropic) within the submucosal fibroid was considered. Patient opted for total hysterectomy. Preserved gross specimen shows fleshy submucosal mass corresponding to the degenerated leiomyoma [Figure 6]. Histopathology revealed extensive hydropic degeneration of the submucosal leiomyoma [Figure 7].

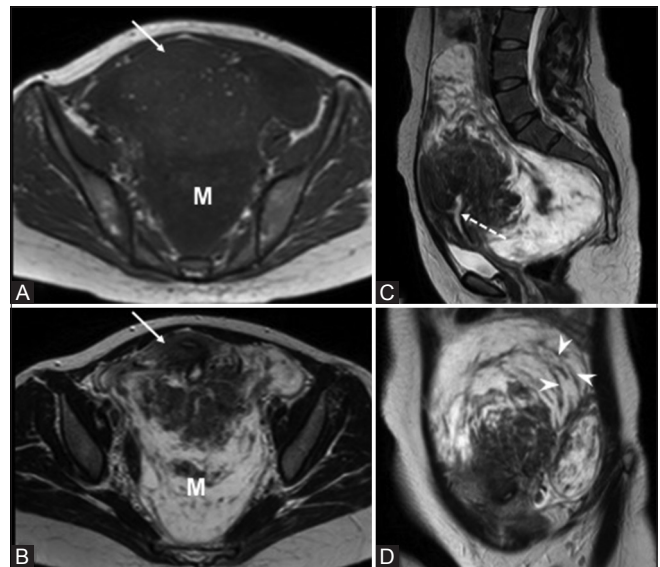


Figure 2 (A-D): (A) On MRI T1 weighted axial section the mass (M) shows roughly two components, isointense to the myometrium with vascular channels closer to the uterine origin (white arrow) and hypointense peripherally. (B-D) MRI T2 weighted images in axial, sagittal and coronal sections. The mass is seen to compress the uterus anteriorly with confirmation of the origin (white dotted arrow in C). Linear hypointense areas are seen within the peripheral hyperintensity corresponding to fibers split up by the edema / fluid accumulation (arrow heads in D)

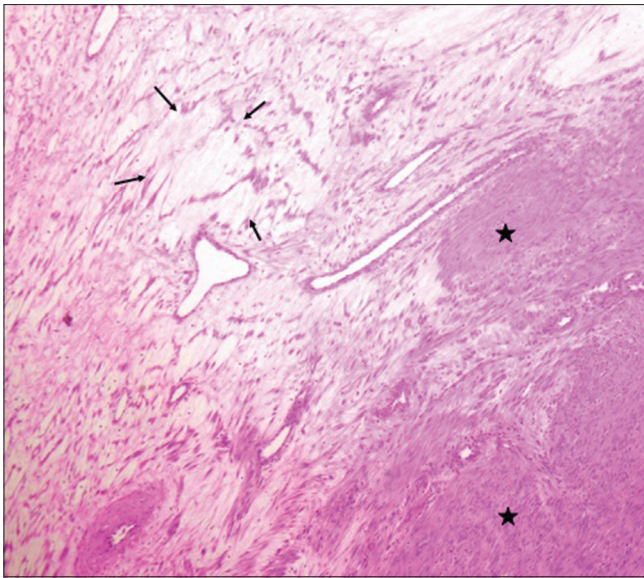


Figure 3: Microphotograph (Hematoxylin and Eosin stain – x40 magnification) showing sparse cellularity and separation of the smooth muscle fibers by intercellular fluid/edema (arrows). Asterisk refers to normal non degenerated portion of fibroid

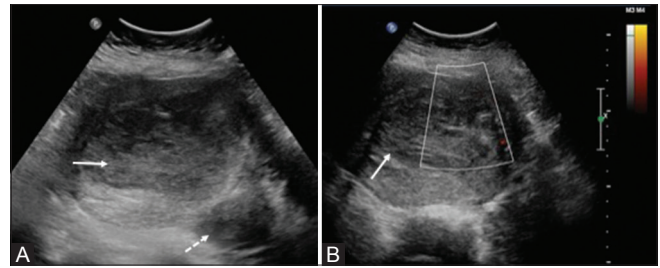


Figure 4 (A and B): (A) Transabdominal ultrasound of pelvis shows a relatively iso- hypoechoic mass within the endometrial cavity (white arrow). Note a subserosal fibroid in left posterolateral wall (white dotted arrow). (B) No vascularity seen on color Doppler

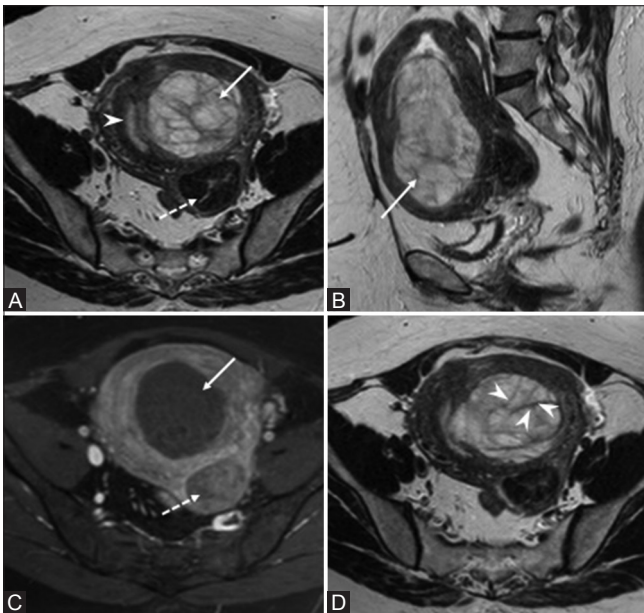


Figure 5 (A-D): (A and B) T2 weighted MRI in axial, sagittal sections shows a mass arising from the anterior submucosal myometrium and filling the endometrial cavity (white arrow). Arrowhead is the compressed endometrium. Dotted arrow is the posterior subserosal fibroid. (C) T1 post gadolinium contrast in axial sections depicts no enhancement of the submucosal mass (white arrow) as opposed to the fibroid posterolaterally which shows homogenous enhancement (dotted arrow). (D) T2 weighted MRI in axial section shows linear hypointense areas corresponding to split fibers (arrowheads)

Discussion

Uterine leiomyomas are very commonly seen in reproductive age females (25–30%) and are benign proliferation of smooth muscle cells separated by fibrous tissue and are

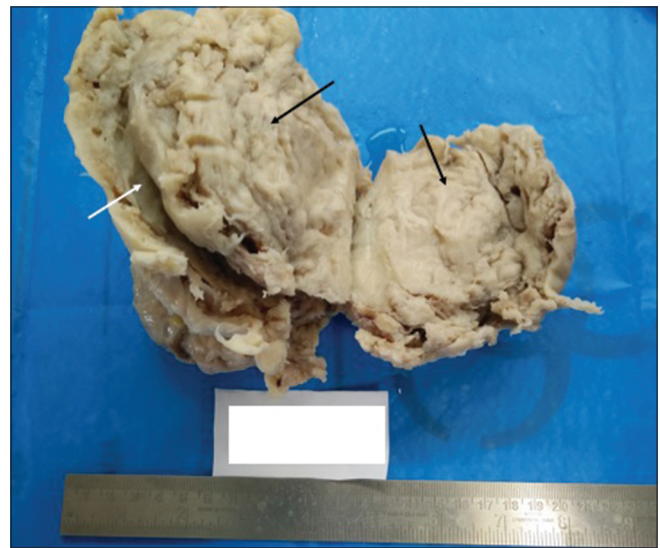


Figure 6: Post operative specimen showing the degenerated submucosal fibroid (black arrows) with whorls and clefts. White arrow is the endometrial cavity

hormone dependent.^[1] They are commonly referred to as fibroids or just myomas. Up to 20–50% are symptomatic with symptoms depending on the size, location, and complications.^[2] Complications include degeneration, torsion, or rupture. Different types of degeneration include hemorrhagic (red), cystic, calcified, myxomatous, lipomatous, and sarcomatous. Rarer forms of degeneration include hydropic and cotyledonoid types, though the latter refers to an atypical pattern of growth rather than degeneration.^[3] The degenerations that occur in fibroid are rarely pure, as mixed types of degeneration can be seen in a fibroid simultaneously on histopathology with imaging depicting the predominant type.

Hydropic degeneration refers to extensive fluid accumulation within the fibroid. Hydropic degeneration as a focal occurrence is seen in up to 50%.^[4] Extensive hydropic degeneration is rare with few published case reports associated with pregnancy^[5-8] and pose significant diagnostic dilemma due to rapid growth. Additionally, elevation in CA-125 can be seen causing pseudo Meigs' syndrome causing more challenge in diagnosis.^[9,10] Incidence

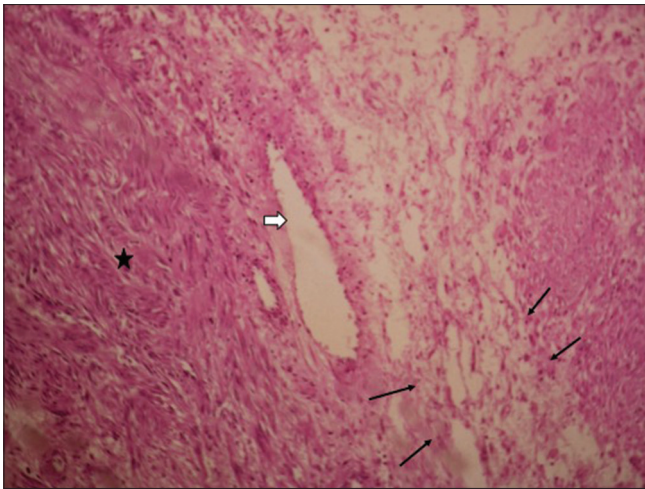


Figure 7: Microphotograph (Hematoxylin and Eosin stain – x40 magnification) showing sparse cellularity and separation of the smooth muscle fibers by intercellular fluid/edema (arrows). White block arrow is a focal cystic change

of hydropic degeneration could not be found due to no large published series in literature. Authors have proposed that venous outflow obstruction caused by pregnancy could predispose to such extensive edematous changes within the leiomyoma^[5] apart from its hormone sensitiveness. Hydropic degeneration of leiomyoma in nongravid female is much more rare.^[11,12]

As different forms of degenerations occur simultaneously in a given fibroid, the categorization on imaging is based on predominant imaging feature. For example, a red degeneration is suggested in the presence of hemorrhagic signals on T1, FFE sequences. Hydropic basically means fluid, hence such degenerations follow fluid signal/density/echogenicity on MRI/computed tomography (CT)/USG, respectively. Imaging can vary from entirely cystic appearing to layers of fluid separating the fiber whorls.

On USG, hydropic degeneration can range from completely cystic, anechoic area to echogenic foci, suggesting inter tissue fluid accumulation. On CT, hypodensity is expected, but may not reliably differentiate. On contrast administration, degenerated areas may not enhance.

MRI is the preferred modality for diagnosis of fibroid degeneration as it can depict tissue characteristics such as hemorrhage/fluid/solid/necrosis with the use of multiple sequences. A nondegenerated fibroid is isointense to myometrium on T1 and hypointense on T2 sequences and shows avid enhancement post contrast. In hydropic degeneration, the fibroid shows focal/diffuse T2 hyperintensity with reduced enhancement.^[13] Extensive hydropic degeneration can mimic malignancy due to large size, rapid growth, and T2 hyperintensities.^[14] In such cases, careful observation of the splitting of the fibers by fluid can aid in differentiating from malignant ones. Post contrast can

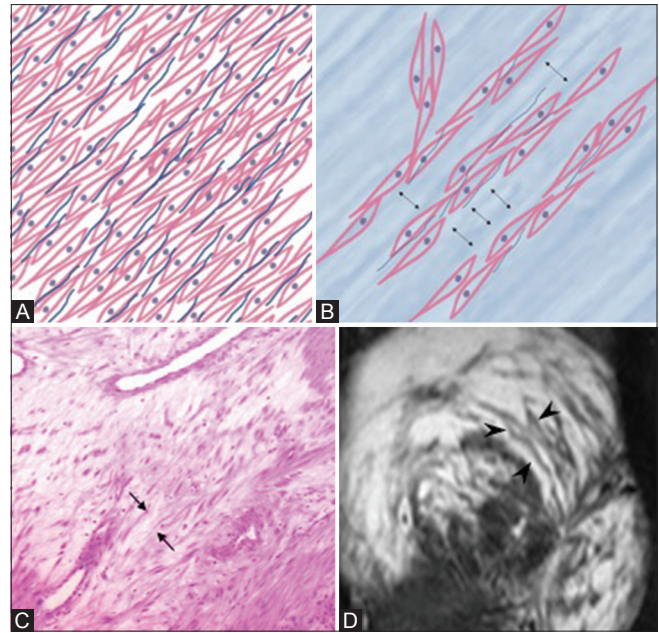


Figure 8 (A-D): (A and B) Illustration of “split fiber” sign. Edema/intercellular fluid separating the smooth muscle cells and fibrous tissue with corresponding histopathology (arrows in C) and T2 weighted MRI image (arrowheads in D)

also help in differentiating as the hydropic degeneration does not enhance or show poor enhancement, whereas malignancies usually show variable enhancement.

Sarcomatous changes within leiomyoma are rare, and differentiation of malignancy from more benign changes, especially in pregnancy, is important for decisions on management. Other imaging differentials for large uterine masses that show pregnancy-related growth include malignant fibrous histiocytoma and aggressive angiomyxoma.

We propose a useful sign to differentiate hydropic leiomyoma from malignancy and we refer to it as the “split fiber” sign. It refers to presence of curvilinear T2 hypointense strands within the degenerated leiomyoma separated by the fluid accumulation and edema [Figure 8]. This sign was seen in both the cases. A similar description of the sign was described in the literature,^[5,8] but we first refer to it as the “split fiber” sign as an easy means to remember and appreciate the imaging feature. Retrospectively, this sign was appreciated in the T2-weighted images of reported cases in the literature.^[5,8] Similar appearance can be seen in myxomatous degeneration with myxoid stroma separating the fibers, though commonly observed on histopathology.

Conclusion

Though uterine leiomyoma is a common condition, degenerations are of rare occurrence. Even rarer occurrence is the extensive hydropic type which closely resembles

malignancy. Diagnosis is important for management purpose and prognostication. We propose the “split fiber” sign on MRI T2-weighted imaging, which can be used to differentiate hydropic degeneration from other grave conditions. Our cases also describe the characteristic MRI features in two proven cases not associated with pregnancy. A larger study evaluating the utility of this sign is open for research.

Declaration of patient consent

The authors certify that they have obtained all appropriate patient consent forms. In the form the patient(s) has/have given his/her/their consent for his/her/their images and other clinical information to be reported in the journal. The patients understand that their names and initials will not be published and due efforts will be made to conceal their identity, but anonymity cannot be guaranteed.

Financial support and sponsorship

Nil.

Conflicts of interest

There are no conflicts of interest.

References

- Clement PB, Young RH, Scully RE. Diffuse, perinodular and other patterns of hydropic degeneration within and adjacent to uterine leiomyomas. *Am J Surg Pathol* 1992;16:26-32.
- Murase E, Siegelman ES, Outwater EK, Perez-Jaffe LA, Tureck RW. Uterine leiomyomas: Histopathologic features, MR imaging findings, differential diagnosis, and treatment. *Radiographics* 1999;19:1179-97.
- Jordan LB, Al-Nafussi A, Beattie G. Cotyledonoid hydropic intravenous leiomyomatosis: A new variant leiomyoma. *Histopathology* 2002;40:245-52.
- Zaloudek CJ, Hendrickson MR, Soslow RA. Mesenchymal tumors of the uterus. In: Kurman RJ, Ellenson LH, Ronnett BM (eds). *Blaustein's pathology of the female genital tract*. New York, NY: Springer, 2011.
- Heffernan E, Köbel M, Spielmann A. Hydropic leiomyoma of the uterus presenting in pregnancy: Imaging features. *Br J Radiol* 2009;82:164-7.
- Awad EE, El-agwany AS, Elhabashy AM, El-zarka A, Abdel Moneim AS. A giant uterine myometrium cyst mimicking an ovarian cyst in pregnancy: An uncommon presentation of hydropic degeneration of uterine fibroid. *Egyptian J Radiol Nucl Med* 2015;46:529-34.
- Moore L, Wilson S, Rosen B. Giant hydropic uterine leiomyoma in pregnancy: Unusual sonographic and Doppler appearance. *J Ultrasound Med* 1994;13:416-8.
- DiPoce J, Liu-Jarin X, Newhouse J. Case 225: Leiomyoma. *Radiology* 2016;278:297-301.
- Amant F, Gabriel C, Timmerman D, Vergote I. Pseudo-Meigs' syndrome caused by a hydropic degenerating uterine leiomyoma with elevated CA 125. *Gynecol Oncol* 2001;83:153-7.
- Dunn JS Jr, Anderson CD, Method MW, Brost BC. Hydropic degenerating leiomyoma presenting as pseudo-Meigs syndrome with elevated CA 125. *Obstet Gynecol* 1998;92:648-9.
- Coard K, Plummer J. Massive multilocular cystic leiomyoma of the uterus: An extreme example of hydropic degeneration. *South Med J* 2007;100:309-12.
- Horta M, Cunha TM, Oliveira R, Magro P. Hydropic leiomyoma of the uterus presenting as a giant abdominal mass. *BMJ Case Rep* 2015;doi: 10.1136/bcr-2015-211929.
- Coad JE, Sulaiman RA, Das K, Staley N. Perinodular hydropic degeneration of a uterine leiomyoma: A diagnostic challenge. *Hum Pathol* 1997;28:249-51.
- Yamashita Y, Torashima M, Takahashi M, Tanaka N, Katabuchi H, Miyazaki K, *et al.* Hyperintense uterine leiomyoma at T2-weighted MR imaging: Differentiation with dynamic enhanced MR imaging and clinical implications. *Radiology* 1993;189:721-5.