

[CASE REPORT]

Remarkable Shrinkage of a Growth Hormone (GH)-secreting Macroadenoma Induced by Somatostatin Analogue Administration: A Case Report and Literature Review

Kiyoe Kurahashi¹, Itsuro Endo¹, Takeshi Kondo¹, Kana Morimoto¹, Sumiko Yoshida¹, Akio Kuroda², Ken-ichi Aihara¹, Munehide Matsuhisa², Kohei Nakajima³, Yoshifumi Mizobuchi³, Shinji Nagahiro³, Masahiro Abe¹ and Seiji Fukumoto⁴

Abstract:

Acromegaly is caused by excessive growth hormone secretion, usually from pituitary adenomas. Somatostatin analogues are widely used as primary or adjunctive therapy in the management of acromegaly. In this report, we present a case with remarkable shrinkage of a tumor after relatively short-term octreotide long-acting release (LAR) administration. During the 30-month follow-up after starting octreotide LAR, there was no recurrence of acromegaly with remarkable shrinkage of the tumor on pituitary magnetic resonance imaging. A literature review of the predictors for tumor shrinkage after the administration of somatostatin analogues in patients with acromegaly is also discussed in relation to this case.

Key words: GH-secreting macroadenoma, somatostatin analogue, remarkable shrinkage

(Intern Med 56: 2455-2461, 2017)

(DOI: 10.2169/internalmedicine.8223-16)

Introduction

Acromegaly results from excessive growth hormone (GH) secretion by pituitary adenomas in over 98% of cases (1). At the time of the diagnosis of acromegaly, more than 70% of patients have macroadenomas. The treatment goals of acromegaly are to normalize the biochemical abnormalities and control the tumor mass in order to prevent worsening of morbidity and mortality (2-4). At present, the main options for the management of acromegaly are surgery, radiotherapy and medical therapies. Long-acting somatostatin analogues, octreotide long-acting release (LAR), slow release lanreotide and lanreotide autogel are currently the treatments of choice in patients with acromegaly as both primary and adjuvant therapies. It has been demonstrated that these medications are effective in controlling GH and insulin-like growth fac-

tor (IGF)-1 levels and reducing pituitary tumor volume (3). Although the biochemical response rates for octreotide LAR and lanreotide autogel are reported to be as high as 70-80%, only a small number of case reports describing the complete disappearance of GH-secreting pituitary tumors as evaluated by magnetic resonance imaging (MRI) have been published (5-9). We herein report a case of acromegaly wherein the GH-secreting pituitary macroadenoma showed remarkable shrinkage with biochemical remission induced by octreotide LAR.

Case Report

A 57-year-old Japanese man presented with an 8-month history of bitemporal hemianopia. MRI revealed a pituitary macroadenoma of 3×5 cm. Given the worsening of his hemianopia, he was admitted to the neurosurgery department

¹Department of Hematology, Endocrinology & Metabolism, Institute of Biomedical Sciences, Tokushima University Graduate School, Japan, ²Diabetes Therapeutics and Research Center, Tokushima University, Japan, ³Department of Neurosurgery, Institute of Health Biosciences, The University of Tokushima Graduate School, Japan and ⁴Institute of Advanced Medical Sciences, Fujii Memorial Institute of Medical Sciences, Tokushima University, Japan

Received: September 5, 2016; Accepted: February 13, 2017; Advance Publication by J-STAGE: August 21, 2017

Correspondence to Dr. Seiji Fukumoto, fukumoto.seiji.1@tokushima-u.ac.jp

Table 1. Patient's Hormonal Data before Octreotide LAR Treatment.

Hormone	Results	Reference range
IGF-1 (ng/mL)	566	82-236
Basal GH (ng/mL)	4.41	<2.47
Nadir GH post-glucose	1.25	<0.4
Nadir GH octreotide test	0.35	
Nadir GH bromocriptine test	0.53	
Prolactin (ng/mL)	1.4	3.8-12.4
ACTH (pg/mL)	57.3	7.2-63.3
Cortisol (µg/dL)	18.1	4.0-18.3
TSH (µU/mL)	1.55	0.5-5.0
Free T ₄ (ng/dL)	0.84	0.7-1.4
LH (mIU/mL)	1.0	1.8-5.2
FSH (mIU/mL)	2.4	2.9-8.2
Free testosterone (pg/mL)	4.3	4.6-109.6

IGF-1: insulin-like growth factor-1, GH: growth hormone, ACTH: adrenocorticotropic hormone, TSH: thyroid-stimulating hormone, Free T₄: free thyroxine, LH: luteinizing hormone, FSH: follicle-stimulating hormone, Free T: free testosterone

of our hospital. Preoperative data showed high GH (4.41 ng/mL) and IGF-1 (566 ng/mL) levels, indicating the presence of acromegaly. He underwent transsphenoidal surgery, and about 20% of his tumor was removed, resulting in some improvement of his hemianopia. He was introduced to our endocrinology department for further evaluation and management.

The patient's height and body weight were 177 cm and 71 kg, respectively (body mass index: 22.5 kg/m³). His waist circumference was 89 cm. His blood pressure was 130/76 mmHg. He had an evident acral enlargement with prominence of the supraciliary arches. The hormonal data before octreotide LAR treatment are shown in Table 1. The diagnosis of acromegaly was confirmed by an elevated level of age-adjusted IGF-1 (566 ng/mL) and based on the high GH concentrations both at baseline (4.41 ng/mL) and after the oral glucose tolerance test (1.25 ng/mL). His prolactin, luteinizing hormone (LH), follicle stimulating hormone (FSH) and free testosterone levels were low. In contrast, his adrenocorticotropic hormone (ACTH)/cortisol and thyroid stimulating hormone (TSH)/free T₄ levels were within the reference ranges. A pathological examination of the partially resected pituitary tumor revealed an acidophilic adenoma by hematoxylin and eosin staining, and immunostaining confirmed the production of GH (Fig. 1A, B). In contrast, ACTH, TSH, FSH and LH were negative, and prolactin was positive in a few tumor cells of the pituitary tumor. Around 95% of the adenoma cells were positive for somatostatin receptor 2 in the cytoplasm (Fig. 1C). The Ki67-index of the tumor cells was ≤0.5% (Fig. 1D). Anti-clarithromycin (CAM)-5.2 immunostaining of tumor cells revealed a dot-like cytokeratin pattern with perinuclear staining in a few tumor cells (Fig. 1E). MRI of the hypothalamus-pituitary region showed the presence of an intrasellar pituitary macroadenoma with T2 iso-intensity, a large suprasellar ex-

pression impinging the optic chiasm both before and after the transsphenoidal surgery (Fig. 2A-E). The lowest GH levels of 0.35 ng/mL and 0.53 ng/mL were observed at 4 hours after testing with 100 µg of octreotide and 2.5 mg of bromocriptine, respectively (Table 1).

Therefore, the monthly administration of 20 mg octreotide LAR was started. His IGF-1 levels decreased to 95 ng/mL, which was within the age-adjusted reference range (82-236), after 1 month. After 6 months of treatment, remarkable tumor shrinkage was observed for the pituitary macroadenoma (Fig. 2F-H). During 30 months of follow-up, there was no recurrence of acromegaly with a post-glucose GH level of 0.14 ng/mL. MRI did not reveal any obvious tumor, either (Fig. 2I-N, 3).

Discussion

Colao et al. summarized the results of treatment with octreotide LAR in patients with acromegaly. A total of 956 patients had been treated with various doses of octreotide LAR (10-40 mg, monthly) for 12-108 months. Control of the GH and IGF-1 levels was achieved in 60% (37-72%) and 59% (34-75%) of patients, respectively (10). Other studies reported tumor shrinkage in 70% (9-88%) of 627 patients treated with octreotide LAR (11-20). On the other hand, the biochemical remission and tumor shrinkage rates-defined as at least 20% reduction-in patients treated with slow-release lanreotide or lanreotide autogel were not higher than those treated with octreotide LAR, or only a few data were reported (21-26).

Only a few cases of complete disappearance of GH-secreting adenomas following the administration of somatostatin analogues have been reported (27-32). Table 2 shows a summary of the previously reported cases. Seven cases were reported, and three patients had macroadenomas. In these 3 cases, long-term treatment (24 to 62 months) with somatostatin analogues was necessary to achieve the complete disappearance of GH-secreting macroadenomas. In addition, two of these three cases with macroadenomas did not reach biochemical remission. Furthermore, pituitary adenoma recurred six months after the discontinuation of lanreotide autogel in one of these patients. These data suggest that GH-secreting macroadenomas may need a longer treatment period for tumor shrinkage than microadenomas. Furthermore, it may be difficult to obtain biochemical remission along with the disappearance of macroadenomas by somatostatin analogues. The present case with GH-secreting macroadenoma achieved biochemical improvement and remarkable tumor shrinkage after six months of treatment with octreotide LAR. Biochemical remission and the near disappearance of the tumor were maintained for 30 months during treatment with a somatostatin analogue.

Some reports have investigated the factors that favor efficacy of somatostatin treatment (33-36). Female gender, an older age at the diagnosis, lower basal GH or IGF-1 levels, low GH levels on the octreotide suppression test, a small tu-

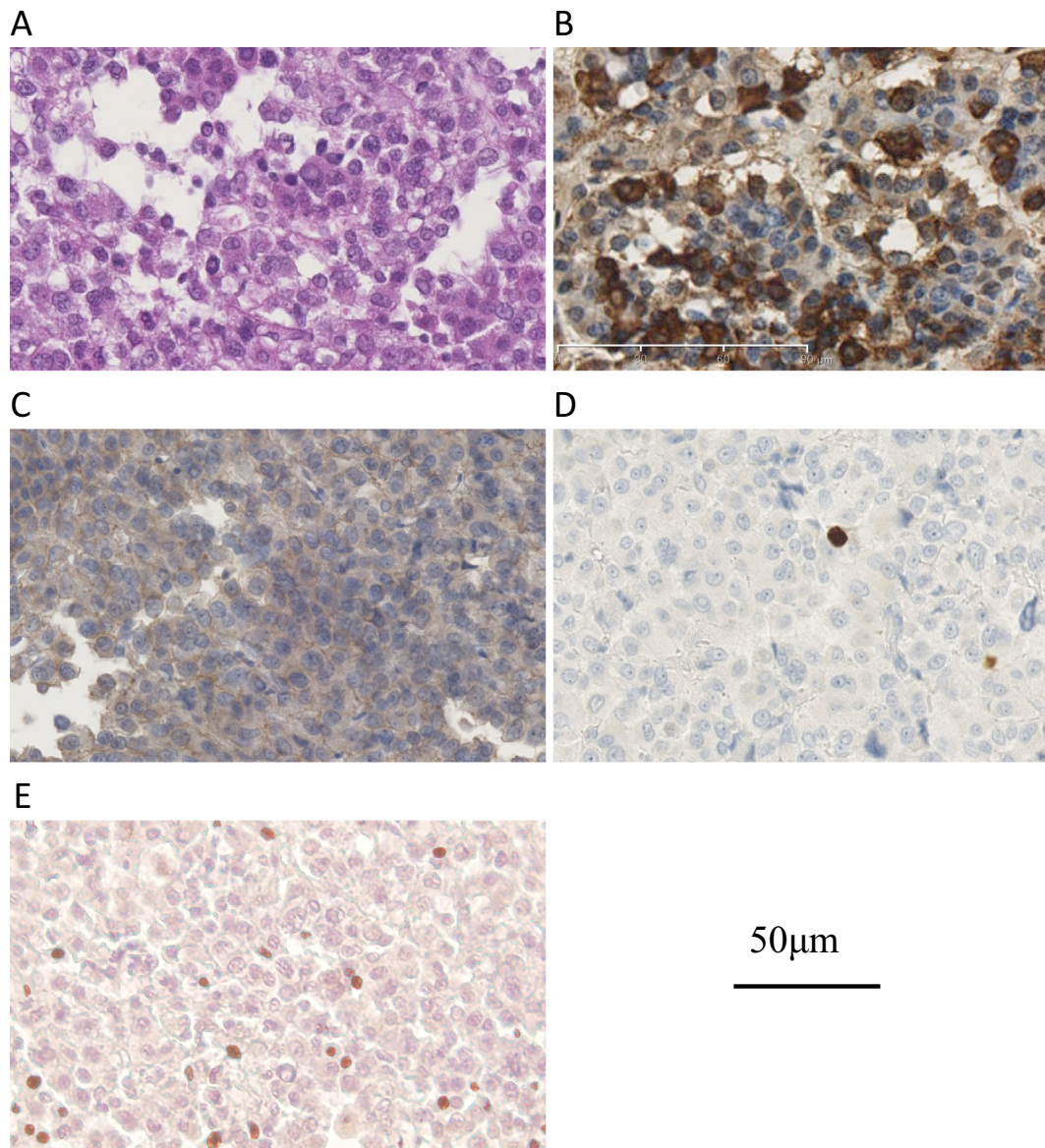


Figure 1. Histology of the resected pituitary tumor. Hematoxylin and Eosin staining shows an acidophilic adenoma (A). Immunohistochemistry indicates strong GH immunostaining (B). Almost all of the pituitary tumor cells expressed somatostatin receptor 2 (SSTR2) (C). Few positive tumor cells were observed in Ki-67 immunostaining (Ki-67 index <0.5%) (D). Anti-CAM-5.2 immunostaining revealed a dot-like cyokeratin pattern with perinuclear staining in a few tumor cells (E).

mor size or at least 75% tumor reduction after surgery, MRI T2 hypo-intensity, granulation pattern by a histological analysis and elevated expression of somatostatin receptor (SSTR) 2,5 and/or ZAC1, a tumor suppression gene, in GH-secreting adenomas are reported to be factors associated with a better response to somatostatin analogues. In contrast, male gender, a younger age at the diagnosis, higher basal GH and IGF-1 levels, large tumors, invasiveness of tumors, T2 high-intensity, sparsely granulated pattern by a histological analysis, lower expression of SSTR, a high labeling index of Ki-67, mutations and/or truncated isoforms of SSTR5 and aryl hydrocarbon receptor interacting protein (AIP) expression with mutations were unfavorable predictors for treatment with somatostatin analogues (Table 3). Female patients likely showed a better response to somatostatin ana-

logues than male patients due to the upregulation of somatostatin receptors by estrogen (37). Younger patients potentially harbor more aggressive GH-secreting pituitary tumors, which may explain why an older age at diagnosis (e.g. >65 years) corresponded to better somatostatin analogue responsiveness (38, 39). Indeed, 6 of the 7 patients who achieved complete disappearance of their tumors were female, and all of them were middle-aged or elderly (Table 2).

Lower GH and IGF-1 levels at diagnosis have also been reported to be independent predictive factors of tumor shrinkage by somatostatin analogues (40). Some reports have shown that an acute suppression test by somatostatin analogues was helpful for predicting the response to long-term treatment (41-43). Our case also showed relatively low basal GH and IGF-1 levels compared with extremely large

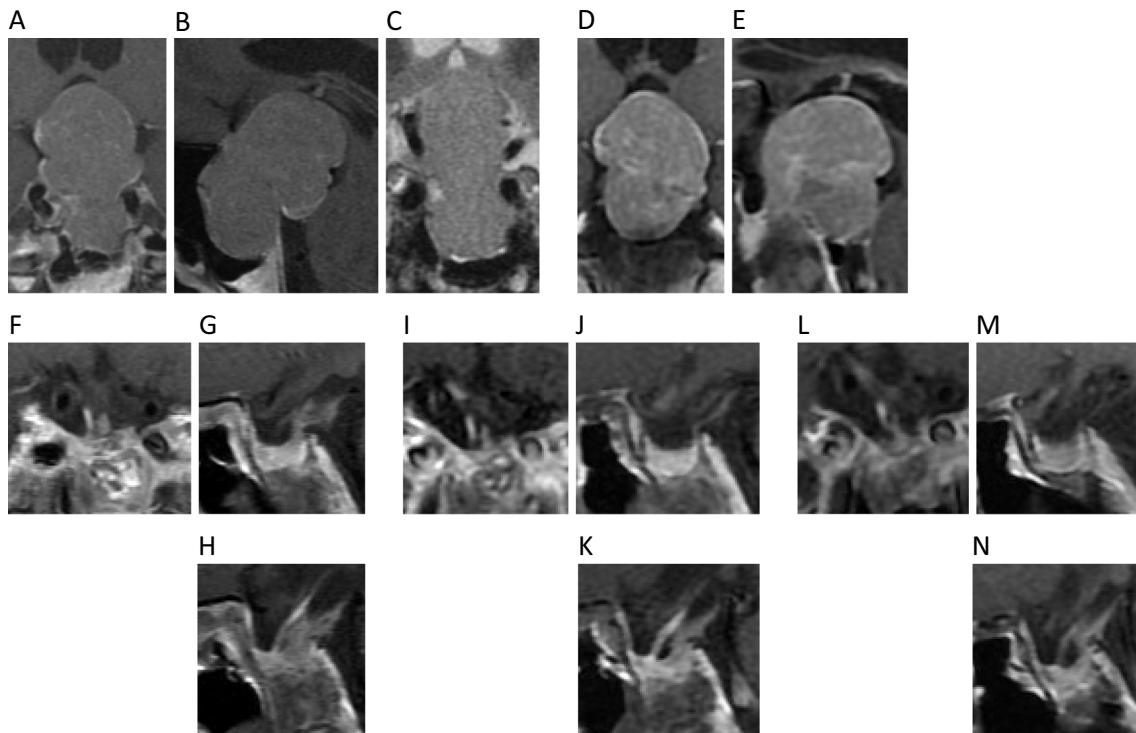


Figure 2. Pituitary MRI images at baseline [coronal T1 gadolinium-contrast enhancement (Gd-CE), A], sagittal T1 Gd-CE (B), T2 coronal (C), after partial resection of GH-secreting adenoma (coronal T1 Gd-CE: D, sagittal T1 Gd-CE: E), after 6 months of treatment with octreotide LAR (coronal T1 Gd-CE: F, sagittal T1 Gd-CE: G, H), after 24 months (coronal T1 Gd-CE: I, sagittal T1 Gd-CE: J, K) and after 30 months (coronal T1 Gd-CE: L, sagittal T1 Gd-CE: M, N).

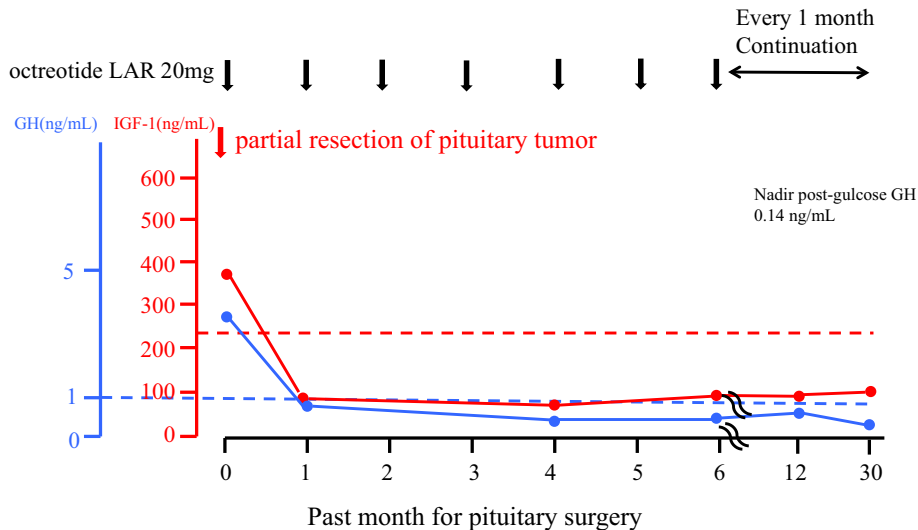


Figure 3. Changes in the serum GH and IGF-1 levels after partial resection of GH-secreting adenoma and during treatment with octreotide LAR. The blue and red broken lines indicate the upper limits of the reference ranges of GH and IGF-1 respectively.

GH-secreting tumors and had a good response to the octreotide suppression test (Table 1). A large tumor size and invasiveness to the cavernous sinus reduce the likelihood of being cured by somatostatin analogues (44).

MRI T2-weighted hypo-intensity of adenoma was associated with densely granulated cells, lower invasiveness and a better response to somatostatin analogues. In contrast, T2-

weighted hyper-intensity imaging suggests a sparse granulation pattern as assessed by immunohistochemistry, with greater invasiveness and a poorer response to somatostatin analogues (45). Our case showed a large tumor without cavernous sinus invasion and T2-weighted iso-intensity. The lack of invasion to the cavernous sinus may have contributed to the good response to octreotide LAR in our case. The

Table 2. Comparison between Our Case and the Previously Reported Cases in which Somatostatin Analogues Induced Complete Tumor Disappearance.

Ref.	Age	Sex	GH (ng/mL)	IGF-1 (ng/mL)	Tumor size	Drug amount (per month)	Duration	Biochemical remission	Note
27)	62	F	20.4	1,446	10×15×21 mm	Oct LAR	60Mo	-	
28)	68	F	25	646	9 mm	Oct LAR 20→30mg	18Mo	Yes	
29)	54	M	21.8	-	-	Oct LAR	6Mo	-	
30)	53	F	12.4	520	micro	Oct LAR 20mg	24Mo	Yes	
30)	70	F	11.5	430	micro	Oct LAR 20mg	24Mo	Yes	
31)	55	F	8.5	650	17×19×14 mm	Lan-SR 60mg	62Mo	No	recurrence
32)	61	F	10.2	753	784.2 mm ³	Lan-ATG 120mg	24Mo	No	
Our case	57	M	4.41	566	26×32×27 mm	Oct LAR 20mg	30Mo	Yes	

Oct LAR: octreotide LAR, Lan-SR: slow-release lanreotide, Lan-ATG: lanreotide autogel, micro: microadenoma, Mo: month

Table 3. Summary of the Predictors for the Effectiveness or Resistance to Somatostatin Analogues.

		Favorable	Unfavorable
Clinical	Gender	Female	Male
	Age	Older	Younger
	<u>basal GH and IGF1</u>	Lower	Higher
	<u>SA suppression test</u>	Lower GH level	No response
	Tumor removal	More than 75%	-
Imaging	Tumor size	Smaller	Larger
	<u>Invasiveness</u>	Negative	Positive
	MRI T2 intensity	Hypo	High
Histopathology	Tumor morphology	Densely granulated	Sparsely granulated
	<u>SSTR2, 5 expression</u>	Higher	Lower
	<u>Ki-67 index</u>	Lower	Higher
	ZAC1 expression	Higher	Lower
	AIP expression	Negative	Positive
Molecular	SSTR5 mutation	-	Arg240Trp, C1004T, T-461C
	SSTR5 truncated isoforms	-	TMD4 and TMD5
	AIP mutation	-	Positive

Underlines indicate the determinants observed in the present case.

SA: somatostatin analogue, SSTR: somatostatin receptor, AIP: aryl hydrocarbon receptor-interacting protein, TMD: transmembrane domains

SSTR expression and Ki-67 index may also be predictors of the efficacy of somatostatin analogues (33). In our case almost all of the tumor cells expressed SSTR2, and the Ki-67 index was low (Fig. 1C, D). These factors may have contributed to the good response to octreotide LAR. Furthermore, cytokeratin staining using the CAM 5.2 antibody showed a mixed pattern (Fig. 1E), which suggested that a non-dot pattern type for GH-secreting tumors is a predictor of a good response to somatostatin analogues (46). We did not check the histopathological or molecular determinants, including the SSTR5 expression, ZAC1 expression, SSTR5 mutation and truncated isoform or AIP gene expression and mutation.

We herein reported a case of acromegaly that showed remarkable shrinkage of a GH-secreting pituitary macroadenoma with biochemical remission induced by octreotide LAR. Further understanding of the clinical, molecular, and

histopathological predictors of the responsiveness to somatostatin analogues will help optimize individualized treatments.

The authors state that they have no Conflict of Interest (COI).

References

- Melmed S. Pathogenesis of pituitary tumors. *Nat Rev Endocrinol* 7: 257-266, 2011.
- Holdaway IM, Bolland MJ, Gamble GD. A meta-analysis of the effect of lowering serum levels of GH and IGF-I on mortality in acromegaly. *Eur J Endocrinol* 159: 89-95, 2008.
- Katznelson L, Laws ER Jr, Melmed S, et al. Acromegaly: an endocrine society clinical practice guideline. *J Clin Endocrinol Metab* 99: 3933-3951, 2014.
- Puig Domingo M. Treatment of acromegaly in the era of personalized and predictive medicine. *Clin Endocrinol (Oxf)* 83: 3-14,

- 2015.
5. Colao A, Pivonello R, Auriemma RS, et al. Beneficial effect of dose escalation of octreotide-LAR as first-line therapy in patients with acromegaly. *Eur J Endocrinol* **157**: 579-587, 2007.
 6. Cozzi R, Montini M, Attanasio R, et al. Primary treatment of acromegaly with octreotide LAR: a long-term (up to 9 years) prospective study of its efficacy in the control of disease activity and tumor shrinkage. *J Clin Endocrinol Metab* **91**: 1397-1403, 2006.
 7. Chanson P, Borson-Chazot F, Kuhn JM, et al. Control of IGF-I levels with titrated dosing of lanreotide Autogel over 48 weeks in patients with acromegaly. *Clin Endocrinol (Oxf)* **69**: 299-305, 2008.
 8. Tutuncu Y, Berker D, Isik S, et al. Comparison of octreotide LAR and lanreotide autogel as post-operative medical treatment in acromegaly. *Pituitary* **15**: 398-404, 2012.
 9. Auriemma RS, Galdiero M, Grasso, et al. Complete disappearance of a GH-secreting pituitary macroadenoma in a patient with acromegaly: effect of treatment with lanreotide Autogel and consequence of treatment withdrawal. *Eur J Endocrinol* **162**: 993-999, 2010.
 10. Colao A, Auriemma RS, Lombardi G, et al. Resistance to somatostatin analogs in acromegaly. *Endocr Rev* **32**: 247-271, 2011.
 11. Davies PH, Stewart SE, Lancranjan L, et al. Long-term therapy with long-acting octreotide (Sandostatin-LAR) for the management of acromegaly. *Clin Endocrinol (Oxf)* **48**: 311-316, 1998.
 12. Colao A, Auriemma RS, Galdiero M, et al. Effects of initial therapy for five years with somatostatin analogs for acromegaly on growth hormone and insulin-like growth factor-I levels, tumor shrinkage, and cardiovascular disease: a prospective study. *J Clin Endocrinol Metab* **94**: 3746-3756, 2009.
 13. Cozzi R, Attanasio R, Montini M, et al. Four-year treatment with octreotide long-acting repeatable in 110 acromegalic patients: predictive value of short-term results? *J Clin Endocrinol Metab* **88**: 3090-3098, 2003.
 14. Mercado M, Borges F, Bouterfa H, et al. A prospective, multicentre study to investigate the efficacy, safety and tolerability of octreotide LAR (long-acting repeatable octreotide) in the primary therapy of patients with acromegaly. *Clin Endocrinol (Oxf)* **66**: 859-868, 2007.
 15. Ayuk J, Clayton RN, Holder G, et al. Growth hormone and pituitary radiotherapy, but not serum insulin-like growth factor-I concentrations, predict excess mortality in patients with acromegaly. *J Clin Endocrinol Metab* **89**: 1613-1617, 2004.
 16. Lancranjan I, Atkinson AB. Results of a European multicentre study with Sandostatin LAR in acromegalic patients. Sandostatin LAR Group. *Pituitary* **1**: 105-114, 1999.
 17. Ghigo E, Biller BM, Colao A, et al. Comparison of pegvisomant and long-acting octreotide in patients with acromegaly naïve to radiation and medical therapy. *J Endocrinol Invest* **32**: 924-933, 2009.
 18. Jallad RS, Musolino NR, Salgado LR, et al. Treatment of acromegaly with octreotide-LAR: extensive experience in a Brazilian institution. *Clin Endocrinol (Oxf)* **63**: 168-175, 2005.
 19. Oki Y, Inoue T, Imura M, et al. Investigation into the efficacy and safety of octreotide LAR in Japanese patients with acromegaly: Shizuoka study. *Endocr J* **56**: 1095-1101, 2009.
 20. Valentim J, Passos V, Matalaveli F, et al. Costeffectiveness analysis of somatostatin analogues in the treatment of acromegaly in Brazil. *Arq Bras Endocrinol Metabol* **52**: 1452-1460, 2008.
 21. Baldelli R, Colao A, Razzore P, et al. Two-year follow-up of acromegalic patients treated with slow-release lanreotide (30 mg). *J Clin Endocrinol Metab* **85**: 4099-4103, 2000.
 22. Verhelst JA, Pedroncelli AM, Abs R, et al. Slow-release lanreotide in the treatment of acromegaly: a study in 66 patients. *Eur J Endocrinol* **143**: 577-584, 2000.
 23. Attanasio R, Baldelli R, Pivonello R, et al. Lanreotide 60 mg, a new long-acting formulation: effectiveness in the chronic treatment of acromegaly. *J Clin Endocrinol Metab* **88**: 5258-5265, 2003.
 24. Giusti M, Ciccarelli E, Dallabonzana D, et al. Clinical results of long-term slow-release lanreotide treatment of acromegaly. *Eur J Clin Invest* **27**: 277-284, 1997.
 25. Chanson P, Leselbaum A, Blumberg J. Efficacy and tolerability of the long-acting somatostatin analog lanreotide in acromegaly. A 12-month multicenter study of 58 acromegalic patients. French Multicenter Study Group on Lanreotide in Acromegaly. *Pituitary* **2**: 269-276, 2000.
 26. Attanasio R, Lanzi R, Losa M, et al. Effects of lanreotide Autogel on growth hormone, insulin-like growth factor 1, and tumor size in acromegaly: a 1-year prospective multicenter study. *Endocr Pract* **14**: 846-855, 2008.
 27. Ozbek M, Erdogan M, Akbal E, et al. Disappearance of a GH secreting macroadenoma, during long-term somatostatin analogue administration. *Exp Clin Endocrinol Diabetes* **117**: 309-311, 2009.
 28. Resmini E, Murialdo G, Giusti M, et al. Pituitary tumor disappearance in a patient with newly diagnosed acromegaly primarily treated with octreotide LAR. *J Endocrinol Invest* **28**: 166-169, 2005.
 29. Harinarayan CV. Primary octreotide LAR therapy in GH-secreting pituitary adenoma. *J Indian Med Assoc* **102**: 258, 260-261, 2004.
 30. Colao A, Ferone D, Marzullo P, et al. Long-term effects of depot long-acting somatostatin analog octreotide on hormone levels and tumor mass in acromegaly. *J Clin Endocrinol Metab* **86**: 2779-2786, 2001.
 31. Livadas S, Hadjidakis DJ, Argyropoulou MI, et al. Disappearance of a growth hormone secreting macroadenoma during long-term somatostatin analogue administration and recurrence following somatostatin withdrawal. *Hormones* **5**: 57-63, 2006.
 32. Auriemma RS, Galdiero M, Grasso LF, et al. Complete disappearance of a GH-secreting pituitary macroadenoma in a patient with acromegaly: effect of treatment with lanreotide Autogel and consequence of treatment withdrawal. *Eur J Endocrinol* **162**: 993-999, 2010.
 33. Cuevas-Ramos D, Fleseriu M. Somatostatin receptor ligands and resistance to treatment in pituitary adenomas. *J Mol Endocrinol* **52**: R223-R240, 2014.
 34. Colao A, Auriemma RS, Lombardi G, et al. Resistance to somatostatin analogs in acromegaly. *Endocr Rev* **32**: 247-271, 2011.
 35. Lee CC, Vance ML, Lopes MB, et al. Stereotactic radiosurgery for acromegaly: outcomes by adenoma subtype. *Pituitary* **18**: 326-334, 2015.
 36. Colao A, Pivonello R, Auriemma RS, et al. Predictors of tumor shrinkage after primary therapy with somatostatin analogs in acromegaly: a prospective study in 99 patients. *J Clin Endocrinol Metab* **91**: 2112-2118, 2006.
 37. Brzana J, Yedinak CG, Gultekin SH, et al. Growth hormone granulation pattern and somatostatin receptor subtype 2A correlate with postoperative somatostatin receptor ligand response in acromegaly: a large single center experience. *Pituitary* **16**: 490-498, 2013.
 38. Gadelha MR, Kasuki L, Korbonits M. Novel pathway for somatostatin analogs in patients with acromegaly. *Trends in Endocrinol Metab* **24**: 238-246, 2013.
 39. Suliman M, Jenkins R, Ross R, et al. Long-term treatment of acromegaly with the somatostatin analogue SR-lanreotide. *J Endocrinol Invest* **22**: 409-418, 1999.
 40. Lucas T, Astorga R, Catalá M, et al. Preoperative lanreotide treatment for GH-secreting pituitary adenomas: effect on tumour volume and predictive factors of significant tumour shrinkage. *Clin Endocrinol (Oxf)* **58**: 471-481, 2003.
 41. Lamberts SW, Uitterlinden P, Schuijff PC, et al. Therapy of acromegaly with sandostatin: the predictive value of an acute test, the value of serum somatomedin-C measurements in dose adjust-

- ment and the definition of a biochemical “cure.” *Clin Endocrinol (Oxf)* **29**: 411-420, 1998.
- 42.** Karavitaki N, Botusan I, Radian S, et al. The value of an acute octreotide suppression test in predicting long-term responses to depot somatostatin analogues in patients with active acromegaly. *Clin Endocrinol (Oxf)* **62**: 282-288, 2005.
- 43.** Halperin I, Nicolau J, Casamitjana R, et al. A short acute octreotide test for response prediction of long-term treatment with somatostatin analogues in acromegalic patients. *Horm Metab Res* **40**: 422-426, 2008.
- 44.** Melmed S. Medical progress: acromegaly. *N Engl J Med* **355**: 2558-2573, 2006.
- 45.** Heck A, Ringstad G, Fougner SL, et al. Intensity of pituitary adenoma on T2-weighted magnetic resonance imaging predicts the response to octreotide treatment in newly diagnosed acromegaly. *Clin Endocrinol* **77**: 72-78, 2012.
- 46.** Bakhtiar Y, Hirano H, Arita K, et al. Relationship between cytokeratin staining patterns and clinic-pathological features in somatotropinomas. *Eur J Endocrinol* **163**: 531-539, 2010.

The Internal Medicine is an Open Access article distributed under the Creative Commons Attribution-NonCommercial-NoDerivatives 4.0 International License. To view the details of this license, please visit (<https://creativecommons.org/licenses/by-nc-nd/4.0/>).

© 2017 The Japanese Society of Internal Medicine
Intern Med 56: 2455-2461, 2017