

Borna Disease Virus-specific T Cells Protect Against or Cause Immunopathological Borna Disease

By J. A. Richt,* A. Schmeel,* K. Frese,† K. M. Carbone,§
O. Narayan§, and R. Rott*

From the *Institut für Virologie; the †Institut für Veterinär-Pathologie, D-35392 Giessen, Germany; and the §The Johns Hopkins University, School of Medicine, Baltimore, Maryland 21205

Summary

In this report we show that passive immunization of Lewis rats with viable CD4⁺, Borna disease virus (BDV)-specific T cells before infection with BDV resulted in protection against BD, whereas inoculation of these T cells after BDV infection induced clinical disease with more rapid onset than seen in BDV control animals. The protective as well as encephalitogenic effector functions of BDV-specific CD4⁺ T cells were mediated only by viable BDV-specific T cells. The protective situation was obtained by passive transfer of BDV-specific T cells into animals inoculated later with virus, whereas the immunopathological situation was observed when virus-specific T cells developed normally or after adoptive transfer, and appeared on the scene after considerable virus replication in the brain.

Borna disease virus (BDV)¹ is an unclassified single-, negative-stranded RNA virus (1, 2) that causes encephalopathy in nature preferentially in horses and sheep. Prominent clinical signs include excitation, ataxia, abnormal behavior, paresis, and paralysis, often leading to death (3, 4). The histopathological lesions consist of a disseminated meningoencephalitis with perivascular infiltrates and pathognomonic intranuclear "Joest-Degen" inclusion bodies in neurons and astrocytes (3–5). Experimentally, BDV causes a persistent infection in the central nervous system (CNS) in a wide range of animal species, ranging from chickens to nonhuman primates. In adult animals infection is restricted to the CNS (4–6). The presence of BDV-specific antibodies in psychiatric patients indicates that BDV might be a possible hazard for man (7).

Studies on pathogenesis of BDV infection in Lewis rats have shown that the disease is mediated by a virus-induced immunopathological reaction. Neurological disorders and inflammation in the CNS did not occur in immunoincompetent animals, such as newborn or athymic-infected rats or rats immunosuppressed by cyclophosphamide or Cyclosporin A in spite of persistent virus replication in the CNS (6, 8–10). The effect of drug-induced immunosuppression, however, was overcome by adoptive transfer of cells from the spleen- or from lymph nodes of acutely infected, syngeneic rats. The

same effect was achieved by injection of syngeneic, BDV antigen-specific CD4⁺ T lymphocytes (NM 1), which had been established in vitro. These BDV-specific NM 1 T cells were able to induce acute Borna disease (BD) and cause severe meningoencephalomyelitis in cyclophosphamide immunosuppressed BDV-infected virus carriers; this T cell transfer did not have any effect in noninfected recipients (11, 12). Furthermore, the BDV-specific T cell line was able to destroy persistently BDV-infected astrocytes in conventional cytotoxicity assays (13). These findings highlight the pivotal role of CD4⁺ T cells in the pathogenesis of BD (11, 12).

In the present study we describe that passive transfer of CD4⁺, BDV-specific T cells into naive syngeneic recipient rats before virus infection conferred a protective immunity against an otherwise fatal virus-induced immunopathological disease of the CNS whereas transfer of these cells beginning on day +3 after intracerebral infection with virus and up to 10 d thereafter resulted in accelerated onset of BD. Thus, treatment of virus-specific CD4⁺ T cells can either induce or prevent clinical BD in BDV infected rats, depending on the time of transfer.

Materials and Methods

BDV and BDV Antigens. BDV stock was prepared from BDV-infected rat brain as 10% homogenates in Glasgow Minimal Essential Medium (GMEM) containing 2% FCS as previously described (14). BDV strain 5/25/92 was used throughout these studies. BDV antigens were purified from BDV-infected rat brains by affinity chromatography using monoclonal and polyclonal antibodies against BDV (12, 15).

Infection and Immunosuppression. 4-wk-old Lewis rats were in-

¹ Abbreviations used in this paper: BDV, Borna disease virus; CNS, central nervous system; GFAP, glial fibrillary acidic protein; IFA, immunofluorescence assay; p.i., post infection; PPD, purified protein derivative; RT-PCR, reverse transcriptase-polymerase chain reaction.

oculated intracerebrally with 0.1 ml of BDV stock homogenate, diluted 1:10 in GMEM/2% FCS. Controls were mock infected intracerebrally with dilution medium only. Immunosuppression was started 1 d after virus inoculation by a single intraperitoneal injection of 150 mg/kg cyclophosphamide (Endoxan; Asta Pharma, Frankfurt, Germany) (6).

Infectivity Assay and Antigen Detection. Virus infectivity was determined in BDV susceptible rabbit embryo brain cells by an indirect immunofluorescence assay (IFA) with a rat anti-BDV immune serum (14). BDV-specific proteins were detected by immunoblotting using polyclonal rat and monoclonal mouse antibodies specific for BDV (15, 16).

Reverse Transcriptase-Polymerase Chain Reaction (RT-PCR) Analysis. RNA was reverse transcribed using BDV-specific primers (p24 specific) and subsequently amplified by the PCR technique as described recently (17). RNA was extracted from brain tissues (frontal cortex) using the acid guanidinium thiocyanate-phenol-chloroform method (18).

T Cell Lines. A purified protein derivative of *Mycobacterium tuberculosis* (PPD)-specific CD4⁺ T cell line, derived from Lewis rats, was kindly provided by Dr. R. Gold (Neurologische Universitätsklinik Würzburg, Germany). The BDV-specific CD4⁺ T cells, NM 1 (11, 12) and AS (Schmeel, A., and J. A. Richt, unpublished results), had been developed by immunization of Lewis rats with BDV antigen as described previously (11, 12). Briefly, adult Lewis rats were immunized with purified BDV-specific antigen in complete Freund's adjuvant into their hind footpads. The regional lymph nodes were homogenized and the bulk cultures stimulated with BDV antigen. The CD4⁺ T cell lines were maintained by alternating cycles of stimulation with antigen in the presence of irradiated, syngeneic APC for 3 d followed by expansion in IL-2 containing medium for 7–10 d. All media were based on RPMI 1640 (Gibco, Eggenstein, Germany).

Adoptive Transfer of T Cells. Naive normal rats (3 wk old) received BDV-specific (NM 1 or AS) or PPD-specific (PPD T cells) CD4⁺ T cells, resuspended in 0.5–1.0 ml HEPES-buffered medium, by intravenous injection of 1–3 × 10⁶ T cells on day 20 and day 5 before intracerebral infection with BDV (day 0). Transfer of these CD4⁺ T cells on days 5 and 20 before infection with BDV was chosen to have a considerable time lag between transfer and infection so that a sufficient number of effector T cells had a good chance for appropriate homing. The adoptive transfer on days +3 and +10 into untreated or cyclophosphamide treated, BDV-infected rats was done with 2.5 × 10⁶ activated BDV-specific (NM 1 or AS) or PPD-specific T cells. In some experiments, the CD4⁺ T cells were inactivated either by two cycles of freezing and thawing or by incubation under UV light at room temperature overnight or irradiation with 6,000 rad before intravenous injection.

Histopathology. Brains were fixed in 4% formalin and embedded in paraffin. Sequential sections were stained with hematoxylin and eosin or with antibodies either specific for the 38/39-kD BDV antigen (murine monoclonal antibody Bo-18; reference 15) or for the astrocyte-specific glial fibrillary acidic protein (anti-GFAP) (polyclonal rabbit antibody; Dako, Hamburg, Germany). Specific reactions were detected with the biotin-avidin-peroxidase system (Vectastain ABC; Vector; Camon, Wiesbaden, Germany).

Results and Discussion

Adoptive Transfer of Live and Inactivated NM 1 T Cells before BDV-infection. Control BDV-infected rats developed signs of BD and significant weight loss after day 24 (±2) post infection (p.i.). The humoral immune response to BDV an-

tigens in these BDV-infected animals started at day 17 p.i. (IFA titer 1:40), reached maximal titers on day 30 p.i. (IFA titer 1:5,120) and was present throughout the entire observation period of 68 d. 10 normal 4-wk-old Lewis rats were injected intravenously twice (on days -20 and -5) with 1–3 × 10⁶ viable BDV-specific NM 1 T cells and challenged later (day 0) by intracerebral inoculation with BDV. None of these animals developed BD during an observation period of more than 1 yr (Table 1). The protective effect of this treatment was also reflected by the body weight of these animals. Rats treated with viable NM 1 T cells had similar growth rates as uninfected, untreated controls and in addition showed normal mating behavior and produced normal litters (data not shown). Antibodies to BDV-specific antigens in these animals protected by NM 1 T cell treatment became detectable 6 d post challenge. The antibody titers in these protected animals after 24 days p.i. were of a similar magnitude as those that developed in BDV-infected control rats. This indicated that the CD4⁺ BDV-specific T cell line NM 1 provided additional specific help for the generation of antibodies by BDV-specific B lymphocytes in vivo. Passive transfer of CD4⁺ control T cells (PPD T cells) or transfer of inactivated NM 1 T cells before BDV challenge resulted in onset of clinical BD, significant weight loss and production of BDV-specific antibodies similar as observed in BDV infected control animals (Table 1). Comparable results were obtained when analogous experiments were carried out with a more virulent BDV strain (strain P2/89), which causes disease of more rapid onset, or another CD4⁺, MHC class II-restricted BDV-specific T cell

Table 1. Adoptive Transfer of CD4⁺ T Cells before Infection with BDV

Treatment	No. of animals	Clinical BD	Encephalomyelitis
Viable NM 1			
T cells	10	0/10	10/10
Inactivated			
NM 1 T cells	3*	3/3	3/3
	3†	3/3	3/3
	4‡	4/4	4/4
Viable PPD			
T cells	4	4/4	4/4
BDV controls	9	9/9	9/9

* NM 1 T cells were inactivated by two rounds of freezing/thawing before intravenous injection.

† NM 1 T cells were inactivated with UV light before intravenous inoculation.

‡ NM 1 T cells were inactivated by irradiation with 6,000 rad before intravenous injection.

CD4⁺ BDV-specific NM 1 T cells were transferred after restimulation with BDV-specific antigen and APCs on days 20 and 5 before BDV infection. As a control, PPD-specific T cells were used.

line (AS). This BDV-specific T cell line, AS, exerts similar *in vivo* and *in vitro* functions as described for the BDV-specific NM 1 T cells (11, 12).

Brain homogenates from T cell-treated animals were analyzed for infectivity, viral antigen, and the presence of viral RNA at various times after virus inoculation. As shown in Table 2, rats treated with viable NM 1 T cells followed by inoculation with BDV became infected although they did not become ill. Infectious virus ($\leq 10^2$ TCID₅₀/ml) was found in brains of these animals between day 9 and day 15 p.i. However, beyond day 15 p.i., infectious virus could not be detected by conventional infectivity assays employing rabbit embryo brain cells (reference 14; Table 2). Similar lack of evidence for infection was obtained when brain homogenates from T cell-treated, protected animals were analyzed for BDV RNA by RT-PCR using BDV p24-specific primers (17). Using this procedure, we detected viral RNA between day 9 and 15 p.i., but no longer beyond day 15 p.i. (data not shown). Similar results were obtained when brain homogenates were analyzed for the presence of viral antigens in Western blots. Here again, at early time points p.i. (days +9 and +12 p.i.), BDV antigens were present in brain sections of NM 1 T cell-treated, protected animals. However, beyond day 15 p.i., BDV-specific antigens were no longer detectable in the T cell-treated, protected group (data not shown). Immunohistological staining of brains from NM 1-treated, protected animals for the presence of BDV antigen confirmed the results obtained by immunoblotting. Here again, only few BDV-specific antigen-expressing cells were detectable in

the brain of these animals at early time points (days 9–15 p.i.) and no BDV-specific staining could be observed at any later time point (beyond day 15 p.i.; Fig. 1 b). The localization of BDV antigen in the NM 1-treated, protected animals was never disseminated; antigen was detected only within neurons of the hippocampus and frontal cortex. In contrast, BDV infected controls or animals adoptively transferred with inactivated BDV-specific or control CD4⁺ T cells followed by virus inoculation developed typical persistent infection and disease. In the latter animals, virus titers started to rise on day 9 p.i., reaching a plateau of maximal infectivity levels on day 27 p.i. which was maintained (± 1 log) during the entire observation period of 68 d (Table 2). BDV-infected control animals had high levels of BDV antigens and BDV RNA as tested by Western blot analysis or RT-PCR at all time points beyond day 9 p.i. (data not shown).

Brain sections of protected animals treated twice with viable BDV-specific T cells before infection had a severe inflammatory response predominantly in the hippocampal area of the CNS and a less prominent reaction in the frontal cortex. This inflammatory reaction started on day 9 p.i. (Table 2). Massive mononuclear perivascular and parenchymal infiltrations were prominent in the CA3-area of the hippocampus. It is interesting to note that many plasma cells were already present at this early stage of infection (day 9 p.i.), a finding that coincided with detectable anti-BDV antibodies. Examination of brain sections from protected animals on day 21 p.i. showed massive encephalitis and astrogliosis (Fig. 1, a and c) which had started earlier than in control animals (Fig. 1, d and f).

Table 2. Summary of Prominent Histopathological Findings and Presence of Antigen and Infectious Virus in the Cerebral Tissue of Protected Rats and Control Animals

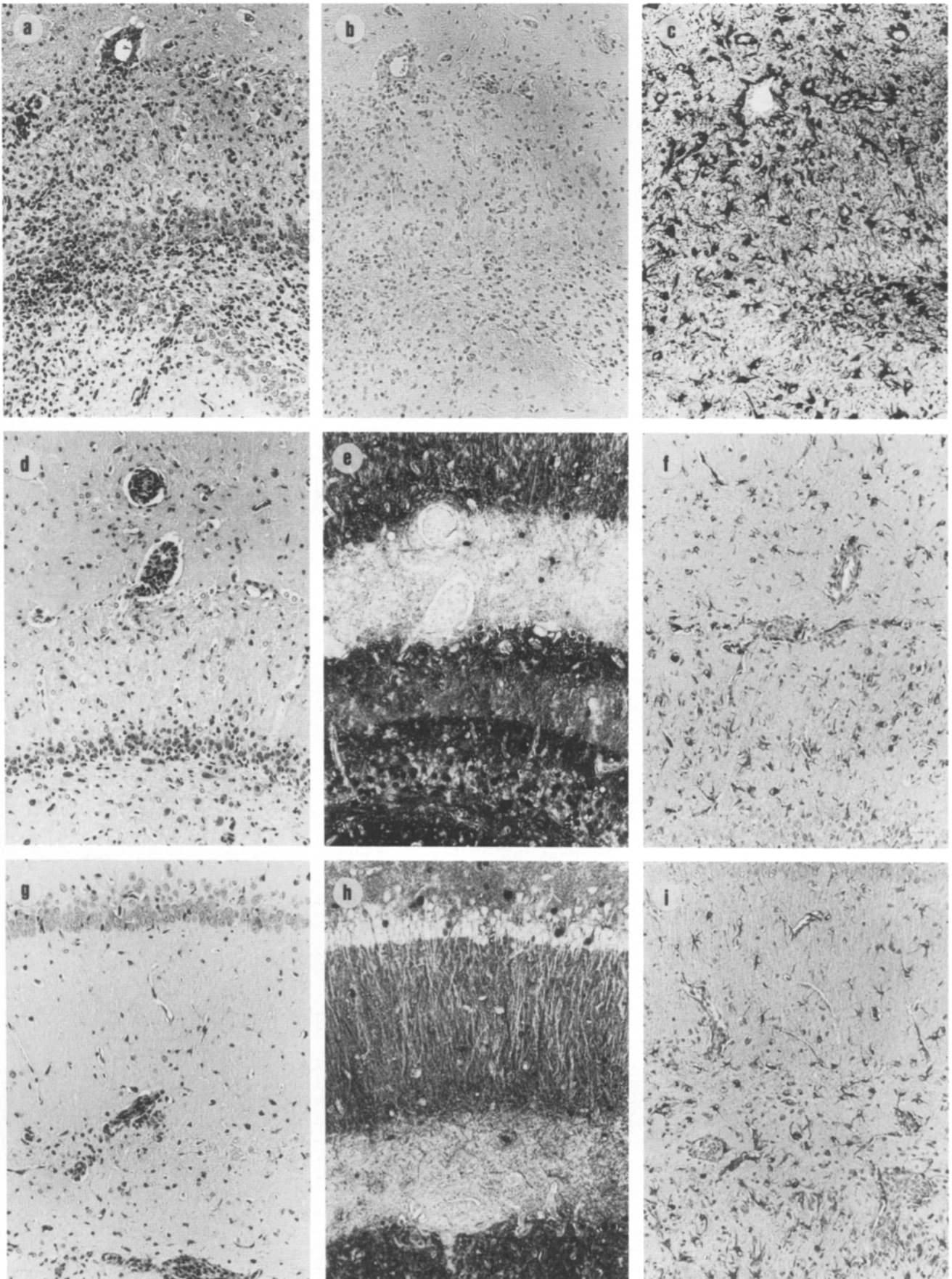
Days p.i.	Histopathology				BDV antigen [§]		Virus infectivity (TCID ₅₀)	
	Encephalitis [*]		Astrogliosis [‡]		Control	Protected	Control	Protected
	Control	Protected	Control	Protected				
								<i>per ml</i>
3	–	–	–	–	–	–	<10 ¹	<10 ¹
6	–	–	–	–	–	–	<10 ¹	<10 ¹
9	–	+	–	+	+	+	10 ¹	10 ²
12	–	++	–	++	+	+	10 ¹	10 ¹
15	±	++	–	+++	+++	+	10 ³	≤10 ¹
21	++	+++	++	+++	+++	–	10 ⁵	<10 ¹
27	+++	+	+++	++	+++	–	10 ⁶	<10 ¹
68	+	–	++	+	+++	–	10 ⁵	<10 ¹

* Encephalitis: ± Very few small perivascular infiltrates. + Few perivascular and parenchymal infiltrates. ++ Few perivascular and more prominent parenchymal infiltrates. +++ Multiple perivascular and massive parenchymal infiltrates.

‡ Astrogliosis: + Few. ++ Moderate. +++ Large numbers of hypertrophic GFAP-reactive astrocytes in lesions.

§ BDV-antigen: – BDV-antigen not demonstrable. + Few immunoreactive neurons (in frontal cortex and hippocampus). ++ Multiple immunoreaction of neurons (in frontal cortex and hippocampus). +++ Massive disseminated immunoreaction of neurons and neuropil.

|| Virus infectivity: Infectivity assays were performed on fetal rabbit brain cells inoculated with the respective virus dilutions as described previously (14).



On day 27, the inflammatory reaction in the hippocampus was still prominent, whereas infiltration in the frontal cortex was rather sparse (Table 2). Inflammation in the brain of NM 1-treated animals began to recede on day 30 p.i., in contrast to maintenance and/or further progression of lesions in the controls (Table 2). Only sparse inflammatory reaction was found at later time points in the CNS of NM 1 T cell-treated, BDV infected rats. Similar results were reported when the F1 generation of Black Hooded X Lewis rats were infected with BDV. In this case, no clinical disease was noticed in spite of cellular infiltrates in the cerebral tissue (19).

In control BDV infected rats, which developed fulminant disease, the time of appearance of inflammatory infiltrates in the brain did not begin until after day 15 (in contrast to day 9 in NM 1 treated, protected animals; see Table 2). At day 15 p.i. sparse perivascular infiltration in the hippocampus of control BDV infected rats was noticed. BDV antigen staining was found as early as day 9 and had become disseminated throughout the brain by day 15 p.i. At day 21 p.i. moderate perivascular and parenchymal infiltrates were seen, especially in the frontal cortex and hippocampus (Fig. 1 *d* and Table 2). At this time, only mild astrogliosis was apparent (Fig. 1 *f*). Similar infiltrations and BDV antigen dissemination as described for day 21 were found on days 27 and 30 p.i. in the brain of control BDV-infected rats (Table 2). Besides participation of mononuclear cells in the inflammatory reaction a moderate astrogliosis became visible, especially in the hippocampus. Animals sacrificed 68 days p.i. still had disseminated patches of BDV antigen and a strong astrogliosis (Table 2). However, the inflammatory reaction in the CNS receded and only sparse parenchymal infiltrates of mononuclear cells were discernible in the cerebral tissue (Table 2). Treatment of naive rats with inactivated BDV-specific CD4⁺ T cells or control PPD T cells and subsequent infection resulted in similar histological alterations described for the untreated BDV-infected controls.

Adoptive Transfer of Live and Inactivated NM 1 T Cells after Infection with BDV. In earlier reports we had shown that activated CD4⁺ NM 1 T cells were able to induce acute clinical disease and severe meningoencephalomyelitis when transferred into rats (on day +10) that had been inoculated with BDV (day 0) and treated with cyclophosphamide (day +1) (11, 12). To determine the time limit for a successful protective transfer of CD4⁺ BDV-specific NM 1 T cells, we conducted adoptive transfer experiments on days +3 and +10 after BDV infection. Recipient rats were either left untreated

or they were treated with cyclophosphamide (150 mg/ml) 1 d after BDV infection. When activated NM 1 T cells were transferred on days +3 or +10 p.i., clinical BD was observed between days 10 and 15 p.i., several days before disease had developed in control BDV-infected animals (day 24 p.i.; Table 3). The incubation period between transfer and onset of BD therefore varied from 4 to 9 d, indicating that dissemination of viral antigen and the presence of an adequate number of effector T cells in the CNS determined the onset of BD (Tables 2 and 3; and Fig. 1, *g-i*). NM 1 T cells, inactivated by x-ray irradiation or freezing and thawing treatment, were not able to induce clinical BD, proving that only viable T cells had encephalitogenic effector functions (Table 3).

In this report we have shown that passive immunization of Lewis rats with viable CD4⁺, BDV-specific T cells before challenge with BDV resulted in protection against BD with an ensuing period of transient virus replication and encephalitis. In contrast, inoculation of these T cells after BDV-infection induced clinical disease with a more rapid onset than seen in BDV infected control animals. The protective as well as encephalitogenic effector functions of BDV-specific CD4⁺ T cells were mediated only by viable BDV-specific T cells. The mechanism of inhibition of virus spread by BDV-specific T cells could be explained by the action of antiviral cytokines, e.g., interferon- γ , tumor necrosis factor α or nitric oxide at the site of viral replication (20, 21). The immediate presence of a relatively high number of BDV responsive T cells would ensure a maximal release of cytokines upon contact with the first BDV antigens produced and subsequent targetting of other immune cells to this site; this would impair further virus replication. In contrast, the response of these CD4⁺ T cells, when administered at time points when viral antigen had disseminated throughout the CNS had no longer the quality of a virostatic effect. The cells rather were responsible for the adverse consequence of promoting the encephalitis, possibly with concomitant lysis of infected neurons and glia cells. There was no definite evidence for a cytolytic effect of T cells, however, since no unequivocal degradation of neurons or glial cell was manifest in the cerebral tissue of these NM 1 T cell-treated animals at this stage of infection. With the methods available and under the experimental conditions employed, it cannot be decided, therefore, whether lysis of such cells by the NM 1 T cells (13) or BDV-specific CD8⁺ T cells (22) would represent the decisive step in pathogenesis.

Results of this study contrast clearly with data obtained

Figure 1. Brain sections from different groups of BDV infected rats. (*a-c*) BDV infected rat, injected with viable NM 1 T cells 20 and 5 d before infection, sacrificed 21 d p.i. (*a*) Massive perivascular and parenchymal mononuclear infiltrations in the hippocampus. (*b*) Subsequent slides with total lack of BDV antigen and (*c*) Prominent astrocytic hypertrophy. (*d-f*) BDV infected control rat, 21 d p.i. (*d*) Moderate perivascular and parenchymal mononuclear infiltration in the hippocampus. (*e*) Subsequent slide exhibiting massive BDV antigen reaction in neurons and neuropil. Lack of immunoreaction in perivascular inflammatory cells and molecular layer. (*f*) Slide from the same hippocampal area with moderate astrocytic hypertrophy. (*g-i*) BDV infected rat after immunosuppression on day 1 p.i. and passive transfer with 2.5×10^6 activated BDV-specific NM 1 T cells on day 10 p.i. and sacrificed 14 days p.i. (*g*) Moderate perivascular and parenchymal mononuclear infiltration in the hippocampus. (*h*) Slide from the same hippocampal area exhibiting massive BDV immunoreaction. Only few positive neurons in the pyramidal layer and weak reaction in the molecular layer. (*i*) Slide from the same hippocampal area with moderate astrocytic hypertrophy. (*a*, *d*, and *g*) Hematoxylin and eosin. (*b*, *e*, and *h*) ABC-stain for BDV antigen with mAb Bo 18 counterstained with hematoxylin. (*c*, *f* and *i*) ABC-stain for GFAP, counterstained with hematoxylin. Magnification $\times 100$.

Table 3. *Adoptive Transfer of CD4⁺ T Cells after Infection with BDV*

Group	CY*	Transfer days p.i.	Onset of BD days p.i.	Encephalitis
BDV	No	No	24 ± 2	8/8
BDV + NM 1 T cells [‡]	No	3	10 ± 2	3/3
BDV + NM 1 T cells [‡]	No	10	14 ± 1	2/2
BDV	Yes	No	No disease	0/8
BDV + NM 1 T cells [‡]	Yes	3	12 ± 2	4/4
BDV + NM 1 T cells [‡]	Yes	10	14 ± 1	10/10
BDV + NM 1 T cells, inactivated [§]	Yes	3	No disease	0/3
BDV + NM 1 T cells, inactivated [§]	Yes	10	No disease	0/4
BDV + PPD T cells	Yes	3	No disease	0/3
BDV + PPD T cells	Yes	10	No disease	0/4

* CY = cyclophosphamide (150 mg/kg).

‡ Animals were inoculated intravenously with 2.5×10^6 activated BDV-specific NM 1 T cells.

§ NM 1 T cells (2.5×10^6 /animal) were inactivated by two rounds of freezing/thawing.

|| Animals were inoculated intravenously with 2.5×10^6 activated PPD-specific T cells.

CD4⁺ BDV-specific (NM 1) or PPD-specific (PPD) T cells were transferred after restimulation with the respective antigens and APCs on days +3 and +10 after BDV infection.

using myelin basic protein-specific CD4⁺ T cell lines to protect rats against immunopathological experimental autoimmune encephalomyelitis. Here, viable as well as inactivated CD4⁺ myelin basic protein-specific T cells were shown to confer a protective immunity against passively or actively induced clinically manifest autoimmune encephalomyelitis in rats (23–26). Our data suggest that presence of a great number of viable antiviral effector cells at a time when relatively few

brain cells were infected results in inhibition of virus spread and protection against clinical disease. This means that in BDV infections of the CNS where lesions are potentially immunopathological in character, the same cells that cause disease can also prevent disease, depending on the dynamics of the virus replication and the time of induction of the T cell response.

J. A. Richt, A. Schmeel, K. Frese, and R. Rott were supported by the Gemeinnützige Hertie-Stiftung and the Deutsche Forschungsgemeinschaft. O. Narayan was supported by startup funds from the Scientific Education Partnership of the Marion Merrell Dow Foundation, and K. M. Carbone was supported by National Institutes of Health grants NS-28599 and MH-48948.

Address correspondence to Dr. Jürgen A. Richt, Institut für Virologie, Justus-Liebig-Universität Giessen, Frankfurterstr. 107, Labor 235, D-35392 Giessen, Germany. O. Narayan's present address is The University of Kansas Medical Center, School of Medicine, 5000 Wahl East, 3901 Rainbow Blvd., Kansas City, KS 66160.

Received for publication 7 December 1993.

References

1. Briese, T., J.C. de la Torre, A. Lewis, H. Ludwig, and W.I. Lipkin. 1992. Borna disease virus, a negative-stranded RNA virus, transcribes in the nucleus of infected cells. *Proc. Natl. Acad. Sci. USA.* 89:11486.
2. Richt, J.A., J.E. Clements, S. Herzog, J. Pyper, K. Wahn, and H. Becht. 1993. Analysis of virus-specific RNA species and proteins in Freon-113 preparations of the Borna disease virus. *Med. Microbiol. Immunol.* 182:271.
3. Ludwig, H., L. Bode, and G. Gosztanyi. 1988. Borna disease. A persistent virus infection of the central nervous system. *Prog. Med. Virol.* 35:107.
4. Richt, J.A., S. Vandewoude, M.C. Zink, J.E. Clements, S. Herzog, L. Stitz, R. Rott, and O. Narayan. 1992. Infection with Borna disease virus: molecular and immunobiological characterization of the agent. *Clin. Infect. Dis.* 14:1240.
5. Heinig, A. 1969. Die Bornasche Krankheit der Pferde und Schafe. In *Handbuch der Virusinfektionen bei Tieren*. H. Röhrer, editor. VEB Fischer Verlag, Jena, Germany. 83.
6. Narayan, O., S. Herzog, K. Frese, H. Scheefers, and R. Rott. 1983. Behavioral disease in rats caused by immunopathological response to persistent Borna disease virus in the brain. *Science (Wash. DC)*. 220:1401.
7. Rott, R., S. Herzog, K. Bechter, and K. Frese. 1991. Borna disease, a possible hazard for man? *Arch. Virol.* 118:143.
8. Herzog, S., C. Kompter, K. Frese, and R. Rott. 1984. Replication of Borna disease virus in rats: age-dependent differences in tissue distribution. *Med. Microbiol. Immunol.* 1273:171.
9. Herzog, S., K. Wonigeit, K. Frese, H.J. Hedrich, and R. Rott. 1985. Effect of Borna disease virus infection in athymic rats. *J. Gen. Virol.* 66:503.
10. Stitz, L., D. Soeder, U. Deschl, K. Frese, and R. Rott. 1989. Inhibition of immune-mediated meningoencephalitis in persistently Borna disease virus infected rats by Cyclosporine A. *J. Immunol.* 143:4250.
11. Richt, J.A., L. Stitz, H. Wekerle, and R. Rott. 1989. Borna disease, a progressive meningoencephalomyelitis as a model for CD4⁺ T cell-mediated immunopathology of the brain. *J. Exp. Med.* 170:1045.
12. Richt, J.A., L. Stitz, U. Deschl, K. Frese, and R. Rott. 1990. Borna disease virus-induced meningoencephalomyelitis caused by virus-specific CD4⁺ T cell-mediated immune reaction. *J. Gen. Virol.* 71:2565.
13. Richt, J.A., and L. Stitz. 1992. Borna disease virus infected astrocytes function in vitro as antigen-presenting and target cells for virus-specific CD4-bearing lymphocytes. *Arch. Virol.* 124:95.
14. Herzog, S., and R. Rott. 1980. Replication of Borna disease virus in cell cultures. *Med. Microb. Immunol.* 173:153.
15. Haas, B., H. Becht, and R. Rott. 1986. Purification and properties of an intranuclear virus-specific antigen from tissues infected with Borna disease virus. *J. Gen. Virol.* 67:235.
16. Thiedemann, N., P. Presek, R. Rott, and L. Stitz. 1992. Antigenic relationship and further characterization of two major Borna disease virus-specific proteins. *J. Gen. Virol.* 73:1057.
17. Richt, J.A., S. Herzog, K. Haberzettl, and R. Rott. 1993. Demonstration of Borna disease virus-specific RNA in secretions of naturally infected horses by the polymerase chain reaction. *Med. Microbiol. Immunol.* 182:293.
18. Chomczynski, P., and N. Sacchi. 1987. Single-step method of isolation by acid guanidinium thiocyanate-phenol-chloroform extraction. *Anal. Biochem.* 162:156.
19. Herzog, S., K. Frese, and R. Rott. 1991. Studies on the genetic control of resistance of black hooded rats to Borna disease. *J. Gen. Virol.* 72:535.
20. Shankar, V., M. Kao, A.N. Hamir, H. Sheng, H. Koprowski, and B. Dietschold. 1992. Kinetics of virus spread and change in levels of several cytokine mRNAs in the brain after intranasal infection of rats with Borna disease virus. *J. Virol.* 66:992.
21. Zheng, Y.M., M.K.-H. Schäfer, E. Weihe, H. Sheng, S. Corisdeo, Z.F. Fu, H. Koprowski, and B. Bietzschold. 1993. Severity of neurological signs and degree of inflammatory lesions in the brains of rats with Borna disease correlate with the induction of nitric oxide synthase. *J. Virol.* 67:5786.
22. Planz, O., T. Bilzer, M. Sobbe, and L. Stitz. 1993. Lysis of major histocompatibility complex class I-bearing cells in Borna disease virus-induced degenerative encephalopathy. *J. Exp. Med.* 178:163.
23. Ben-Nun, A., H. Wekerle, and I.R. Cohen. 1981. Vaccination against autoimmune encephalomyelitis with T lymphocyte line reactive against myelin basic protein. *Nature (Lond.)* 292:60.
24. Steinman, L. 1991. The development of rational strategies for selective immunotherapy against autoimmune demyelinating diseases. *Adv. Immunol.* 49:357.
25. Vandebark, A.A., G. Hashim, and H. Offner. 1989. Immunization with a synthetic T-cell receptor V-region peptide protects against experimental autoimmune encephalomyelitis. *Nature (Lond.)* 341:541.
26. Howell, M.D., S.T. Winters, T. Olee, H.C. Powell, D.J. Carlo, and S.W. Brostoff. 1989. Vaccination against experimental allergic encephalomyelitis with T cell receptor peptides. *Science (Wash. DC)*. 246:668.