

Killing two birds with one stone—MitraClip for flail P2 and systolic anterior motion of mitral valve: a case report

Wong Ningyan, Nadira Hamid, Tang Hak Chiaw, and Yeo Khung Keong*

National Heart Centre Singapore, 5 Hospital Drive, Singapore 169609, Singapore

Received 4 July 2018; accepted 6 November 2018; online publish-ahead-of-print 11 December 2018

Background

The MitraClip system has been used extensively in high-risk patients with severe degenerative mitral regurgitation (MR). Recent reports have demonstrated the feasibility of using the MitraClip device to treat systolic anterior motion (SAM) of the mitral valve in obstructive hypertrophic cardiomyopathy (HOCM).

Case summary

We report the case of a 76-year-old lady who had both symptomatic severe degenerative MR and HOCM that were refractory to medical therapy. Both pathologies were treated successfully using the MitraClip system.

Discussion

In patients who are deemed to be at high risk for open surgery, our case demonstrated the feasibility of a percutaneous avenue, the MitraClip system, to treat not just degenerative MR, but also SAM from HOCM in a single procedure.

Keywords

Mitral regurgitation • Mitral valve prolapse • Hypertrophic obstructive cardiomyopathy • MitraClip • Case report

Learning points

- Transcatheter edge-to-edge repair of the mitral valve using the MitraClip system is effective in treating severe degenerative mitral regurgitation.
- Percutaneous mitral valve plication using the MitraClip system is a feasible treatment alternative for systolic anterior motion of the mitral valve in obstructive hypertrophic cardiomyopathy (HOCM).
- In patients with concomitant HOCM and primary mitral valve disease, the use of MitraClip could be a possible alternative to surgical septal reduction with mitral valve repair/replacement.

Introduction

The use of the MitraClip (Abbott Vascular, Abbott Park, IL, USA) system in patients with severe degenerative mitral regurgitation (MR) and prohibitive surgical risk has been well established.^{1–4}

Percutaneous mitral valve plication using the MitraClip device has recently emerged as a treatment option in patients with symptomatic obstructive hypertrophic cardiomyopathy (HOCM) to eliminate systolic anterior motion (SAM) of the mitral valve and reduce left ventricular outflow tract (LVOT) gradients.^{5–8} We report a patient with

* Corresponding author. Tel: (65) 67048963, E-mail: yeo.khung.keong@singhealth.com.sg

Handling Editor: Georg Goliasch

Peer-reviewers: Riccardo Liga, eugenio caradonna, and Hafiz Naderi

Compliance Editor: Anastasia Vamvakidou

Supplementary Material Editor: Peregrine Green

© The Author(s) 2018. Published by Oxford University Press on behalf of the European Society of Cardiology.

This is an Open Access article distributed under the terms of the Creative Commons Attribution Non-Commercial License (<http://creativecommons.org/licenses/by-nc/4.0/>), which permits non-commercial re-use, distribution, and reproduction in any medium, provided the original work is properly cited. For commercial re-use, please contact journals.permissions@oup.com

both HOCM and severe degenerative MR that were simultaneously treated with the MitraClip device in one procedure.

Timeline

2002	Diagnosis of obstructive hypertrophic cardiomyopathy (HOCM) with systolic anterior motion (SAM) of the mitral valve and mild mitral regurgitation (MR)
2012	Developed atrial fibrillation (AF)
25 November 2017	Development of posterior mitral valve prolapse with flail P2 resulting in severe MR
November 2017 to January 2018	Five admissions for breathlessness on exertion and angina (severe MR and HOCM)
16 January 2018	MitraClip procedure—two clips; first clip for flail P2 and second clip for SAM-related MR

Case summary

A 76-year-old lady with history of dyslipidaemia, cerebrovascular accident, and prior surgical resection of rectal adenocarcinoma was followed up in our centre for HOCM and atrial fibrillation (AF). Her medications included sustained release Verapamil 240 mg once daily, Bisoprolol 2.5 mg once daily, Simvastatin 40 mg every night, and Warfarin titrated to an international normalized ratio target of 2–3. Pre-morbidly, she was functionally in New York Heart Association Classification II–III but spent most of her time at home and experienced no symptoms ambulating around. She had no prior heart failure admissions until the recent 2 months when she was admitted on five occasions for angina and dyspnoea on exertion. Other symptoms included orthopnoea and paroxysmal nocturnal dyspnoea but no giddiness or syncopal episodes. Physical examination showed a pulse rate of 76 b.p.m., blood pressure of 126/72 mmHg, respiratory rate of 16/min, and 98% oxygen saturation. Auscultation revealed a pansystolic murmur over the apex as well as an ejection systolic murmur over the upper left sternal border. There were mild bibasal lung crepitations and no pedal oedema. Gentle intravenous furosemide was given with resolution of the fluid overload state. Her electrocardiogram showed AF as well as left ventricular (LV) hypertrophy with strain (Figure 1). A transthoracic echocardiogram (TTE) done showed asymmetric LV hypertrophy with the basal anteroseptal wall being the thickest at 2.3 cm and a LV mass index of 252 g/m². There was SAM of the anterior mitral valve leaflet (Figure 2A, [Supplementary material online, Video S1](#)) and a LVOT gradient of 76 mmHg at rest (Figure 2B). The gradient remained stable as compared to the previous TTE done 3 years ago. She had normal LV and RV systolic function, but moderate aortic regurgitation (AR) from a degenerative aortic valve as well as raised pulmonary artery systolic pressure of 66 mmHg. However, there was new development of posterior mitral valve prolapse with flail P2 from torn chordae, which was better demonstrated on transoesophageal echocardiogram (Figure 2C,D, [Supplementary material online, Video S2](#)). It resulted in severe

anteriorly directed MR (Figure 2E, [Supplementary material online, Video S3](#)) with a vena contracta of 0.79 cm, effective regurgitant orifice of 0.46 cm² and mitral regurgitant volume of 83 mls. This was different from previous SAM-related MR which was mild and posteriorly directed. Coronary angiogram revealed minor disease. Medical management over the 2 months was difficult due to the effect of diuresis on LVOT obstruction and resultant angina. Surgical management would be complicated in view of the small LVOT size and the need for dual valve replacement (MR and AR). Importantly, several senior surgeons felt that there would be significant interaction between any prosthetic valves and the LVOT. In addition, her logistic EuroSCORE was 7.64%. Alcohol septal ablation and pacing only addresses SAM and not the flail leaflet. After a Heart Team discussion, decision was made to offer transcatheter intervention using the MitraClip system to fix the flail P2. Concomitantly in the same procedure, we could address the issue of SAM and LVOT obstruction and hopefully improve her baseline functional status.

The first clip was placed centrally over the flail P2 segment with reduction of MR grade from 4+ to 2+ (Figure 3, [Supplementary material online, Video S4](#)). The residual MR was located at the A1 segment. The MR jet was posteriorly directed and was SAM-related. Decision was made to deploy a second clip lateral to the first clip. There was initially some difficulty grasping the anterior mitral valve leaflet but after multiple attempts, the second clip was deployed successfully (Figure 4A). This reduced the MR grade further to 1–2+ (Figure 4B, [Supplementary material online, Videos S5–S7](#)) and a reduction in LVOT gradient to 33 mmHg (Figure 4C,D). The systolic blood pressure improved significantly post-procedure from 90 mmHg to 160 mmHg.

Post-procedure, she experienced a significant improvement in symptoms and was discharged well to a step-down facility for continued rehabilitation. Unfortunately, she had repeated admissions for upper gastrointestinal bleeding. After multiple endoscopic evaluations, it was found on capsule endoscopy to be due to jejunal angiodysplasia, and this was successfully treated with double balloon enteroscopy and ablation. Her symptoms improved but she developed AF with rapid ventricular rate which resulted in readmission for chest pain and dyspnoea. Transthoracic echocardiogram at 1 and 6 months showed that both clips were stable with an overall MR grade of 2+. The LVOT gradient remained lower at 38 mmHg, but there was no significant change in pulmonary artery systolic pressures.

Discussion

MitraClip for the treatment of degenerative MR and prohibitive surgical risk is well established and has an excellent safety profile.^{1–4} It has been approved for use in degenerative MR since 2008 in Europe and 2013 in United States (US). In both the European and US guidelines, the use of MitraClip to treat degenerative MR is Class 2B and restricted to patients who are felt by the Heart Team to be at prohibitive surgical risk.^{9,10} As for functional MR, the recently published COAPT trial suggests that MitraClip would have a role in optimally treated heart failure patients with functional MR who continued to have significant symptoms.¹¹ However, its use in HOCM is not listed in either guidelines due to the limited data. Nonetheless, there are

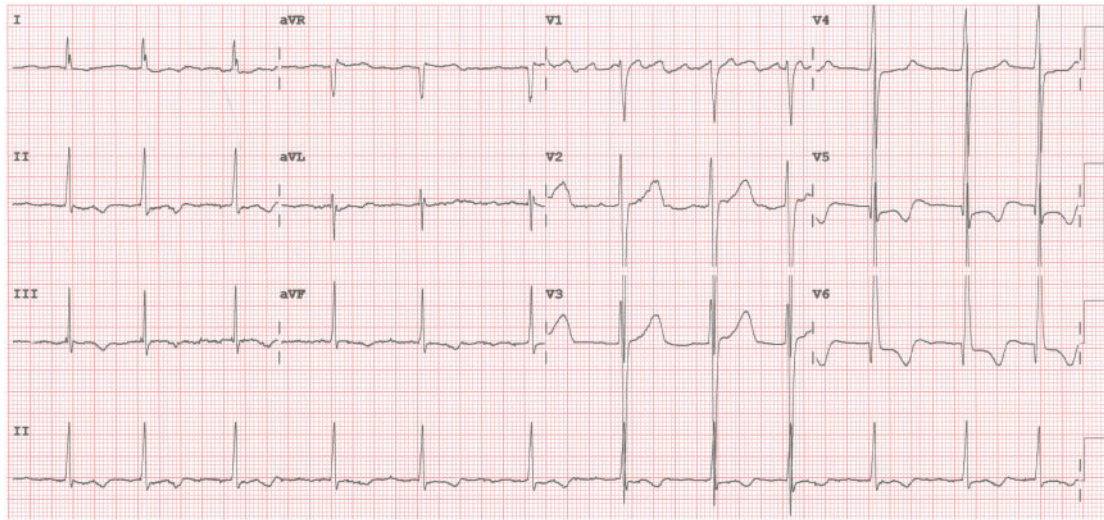


Figure 1 Electrocardiogram showing atrial fibrillation as well as left ventricular hypertrophy with strain.

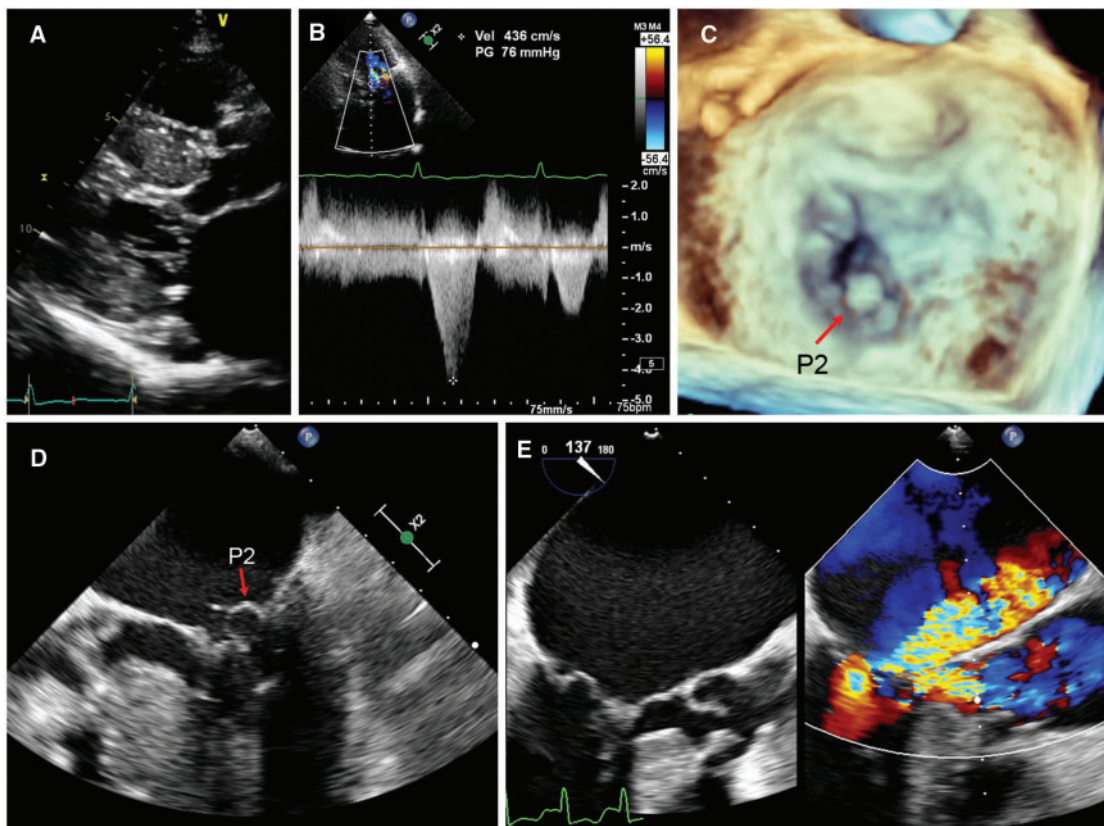


Figure 2 (A) Parasternal long-axis view showing severe left ventricular hypertrophy and systolic anterior motion of the mitral valve. (B) Late-peaking left ventricular outflow tract (LVOT) gradient of 76 mmHg. (C) 3D and (D) 2D transoesophageal echocardiographic mid-oesophageal 4-chamber views showing P2 flail. (E) LVOT view showing severe mitral regurgitation and flow acceleration across the LVOT.

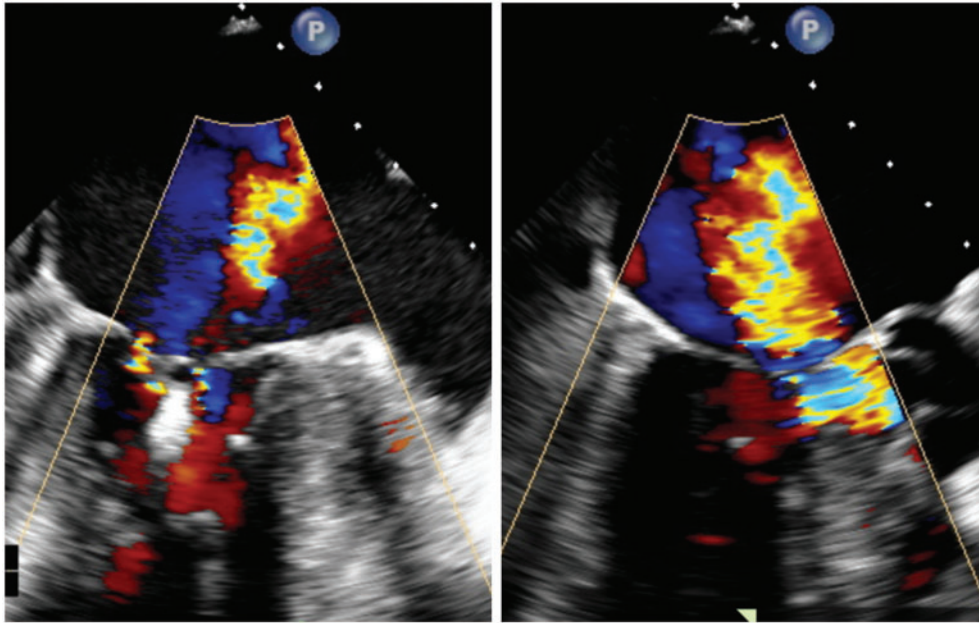


Figure 3 First clip was placed centrally over the flail segment with reduction of the mitral regurgitation grade from 4+ to 2+. Transoesophageal echocardiographic views showing residual posteriorly directed mitral regurgitation at the A1 segment, lateral to the first clip, and was systolic anterior motion-related.

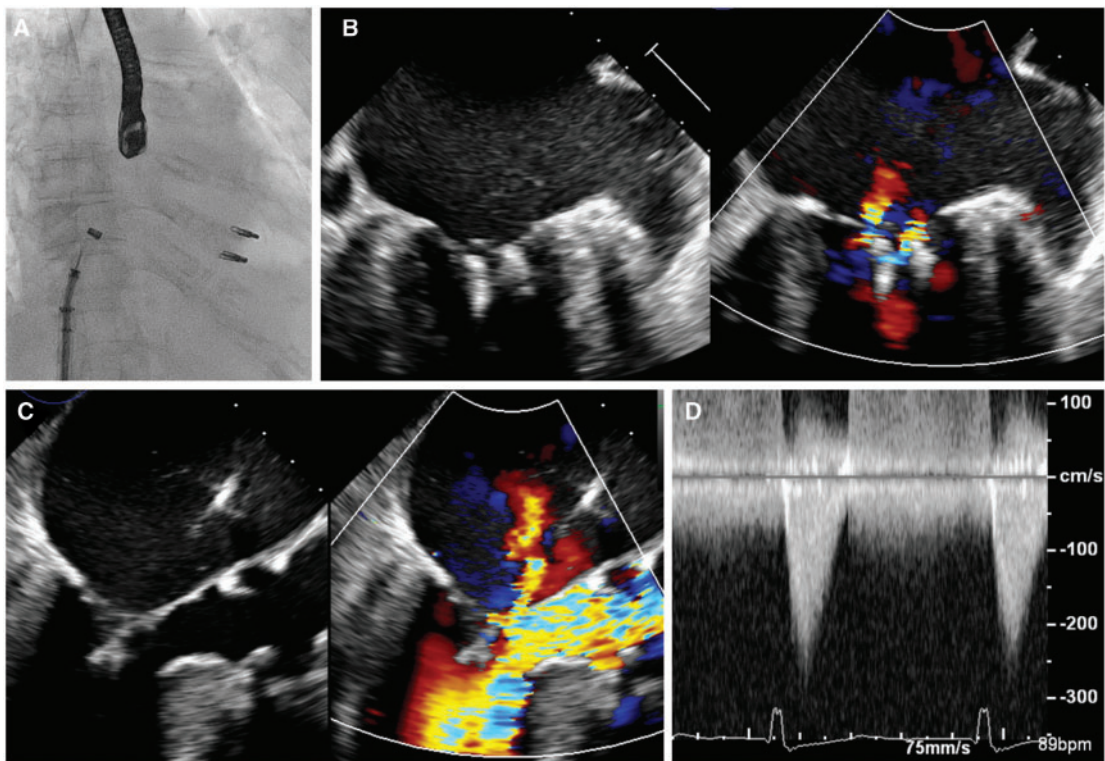


Figure 4 (A) Fluoroscopic view showing second clip deployed lateral to the first clip. Transoesophageal echocardiographic images showing (B) residual 1–2+ mitral regurgitation in the intercommissural view, and (C) reduction of systolic anterior motion-related mitral regurgitation in the left ventricular outflow tract view. (D) The left ventricular outflow tract peak pressure gradient was reduced to 33 mmHg.

case reports which showcase the utility of this treatment in such patients.

In patients with symptomatic HOCM refractory to maximal medical therapy, invasive septal reduction therapy (surgical septal myectomy or alcohol septal ablation) is indicated.¹² Mitral valve repair or replacement may have to be performed at time of septal myectomy in patients with primary mitral valve disease.¹³ In patients who are not candidates for septal reduction therapy or deemed high risk for open heart surgery, percutaneous mitral valve plication with the MitraClip device has emerged in recent years as a potential alternative treatment modality. Firstly, initial reports have demonstrated its efficacy in improving symptoms, LVOT gradient and MR grade.^{5–8} Thomas *et al.*⁸ compiled data of four studies conducted from 2010 to 2016 on 15 patients with symptomatic HOCM who underwent the MitraClip procedure. All patients experienced symptomatic relief, an improvement in MR and resolution of SAM. There was a reduction in mean LVOT gradients from 75.8 ± 39.7 mmHg to 11.0 ± 5.6 mmHg. Secondly, MitraClip may be a safer option compared to alcohol septal ablation in patients who are poor surgical candidates. Alcohol septal ablation is associated with risks of complete heart block,¹⁴ as well as ventricular arrhythmias originating from the infarcted myocardium.¹⁵ Lastly, MitraClip is not dependent on coronary anatomy or degree of septal hypertrophy.

Conclusion

We report a case that demonstrated the feasibility of the MitraClip system to treat not just degenerative MR but also SAM from HOCM in a single procedure.

Supplementary material

Supplementary material is available at *European Heart Journal - Case Reports* online.

Slide sets: A fully edited slide set detailing this case and suitable for local presentation is available online as [Supplementary data](#).

Consent: The author/s confirm that written consent for submission and publication of this case report including image(s) and associated text has been obtained from the patient in line with COPE guidance.

Conflict of interest: K.K.Y.: Abbott Vascular: Honorarium and Proctorship for MitraClip.

References

1. Glower DD, Kar S, Trento A, Lim DS, Bajwa T, Quesada R, Whitlow PL, Rinaldi MJ, Grayburn P, Mack MJ, Mauri L, McCarthy PM, Feldman T. Percutaneous mitral valve repair for mitral regurgitation in high-risk patients: results of the EVEREST II study. *J Am Coll Cardiol* 2014;**64**:172–181.
2. Maisano F, Franzen O, Baldus S, Schäfer U, Hausleiter J, Butter C, Ussia GP, Sievert H, Richardt G, Widder JD, Moccetti T, Schillinger W. Percutaneous mitral valve interventions in the real world: early and 1-year results from the ACCESS-EU, a prospective, multicenter, nonrandomized post-approval study of the MitraClip therapy in Europe. *J Am Coll Cardiol* 2013;**62**:1052–1061.
3. Puls M, Lubos E, Boekstegers P, von Bardeleben RS, Ouarrak T, Butter C, Zuern CS, Bekeredjian R, Sievert H, Nickenig G, Eggebrecht H, Senges J, Schillinger W. One-year outcomes and predictors of mortality after MitraClip therapy in contemporary clinical practice: results from the German Transcatheter Mitral Valve Interventions Registry. *Eur Heart J* 2016;**37**:703–712.
4. Sorajja P, Vemulapalli S, Feldman T, Mack M, Holmes DR, Stebbins A, Kar S, Thourani V, Ailawadi G. Outcomes with transcatheter mitral valve repair in the United States: an STS/ACC TVT Registry report. *J Am Coll Cardiol* 2017;**70**:2315–2327.
5. Schäfer U, Kreidel F, Frerker C. MitraClip implantation as a new treatment strategy against systolic anterior motion-induced outflow tract obstruction in hypertrophic obstructive cardiomyopathy. *Heart Lung Circ* 2014;**23**:e131–e135.
6. Schäfer U, Frerker C, Thielsen T, Schewel D, Bader R, Kuck K-H, Kreidel F. Targeting systolic anterior motion and left ventricular outflow tract obstruction in hypertrophic obstructed cardiomyopathy with a MitraClip. *EuroIntervention* 2015;**11**:942–947.
7. Sorajja P, Pedersen WA, Bae R, Lesser JR, Jay D, Lin D, Harris K, Maron BJ. First experience with percutaneous mitral valve plication as primary therapy for symptomatic obstructive hypertrophic cardiomyopathy. *J Am Coll Cardiol* 2016;**67**:2811–2818.
8. Thomas F, Rader F, Siegel RJ. The use of MitraClip for symptomatic patients with hypertrophic obstructive cardiomyopathy. *Cardiology* 2017;**137**:58–61.
9. Nishimura RA, Otto CM, Bonow RO, Carabello BA, Erwin JP, Fleisher LA, Jneid H, Mack MJ, McLeod CJ, O’Gara PT, Rigolin VH, Sundt TM, Thompson A. AHA/ACC focused update of the 2014 AHA/ACC guideline for the management of patients with valvular heart disease: a report of the American College of Cardiology/American Heart Association Task Force on Clinical Practice Guidelines. *J Am Coll Cardiol* 2017;**70**:252–289.
10. Baumgartner H, Falk V, Bax JJ, De Bonis M, Hamm C, Holm PJ, Iung B, Lancellotti P, Lansac E, Rodriguez Muñoz D, Rosenhek R, Sjögren J, Tornos Mas P, Vahanian A, Walther T, Wendler O, Windecker S, Zamorano JL, Roffi M, Alfieri O, Agewall S, Ahlsson A, Barbato E, Bueno H, Collet J-P, Coman IM, Czerny M, Delgado V, Fitzsimons D, Folliguet T, Gaemperli O, Habib G, Harringer W, Haude M, Hindricks G, Katus HA, Knuuti J, Kolh P, Leclercq C, McDonagh TA, Piepoli MF, Pierard LA, Ponikowski P, Rosano GMC, Ruschitzka F, Shlyakhto E, Simpson IA, Sousa-Uva M, Stepinska J, Tarantini G, Tchétché D, Aboyans V, Windecker S, Aboyans V, Agewall S, Barbato E, Bueno H, Coca A, Collet J-P, Coman IM, Dean V, Delgado V, Fitzsimons D, Gaemperli O, Hindricks G, Iung B, Jüni P, Katus HA, Knuuti J, Lancellotti P, Leclercq C, McDonagh T, Piepoli MF, Ponikowski P, Richter DJ, Roffi M, Shlyakhto E, Simpson IA, Zamorano JL, Zhdryan HK, Mascherbauer J, Samadov F, Shumavets V, Camp GV, Lončar D, Lovric D, Georgiou GM, Linhartova K, Ihlemann N, Abdelhamid M, Pern T, Turpeinen A, Srbinska-Kostovska E, Cohen A, Bakhtashvili Z, Ince H, Vavuranakis M, Temesvári A, Gudnason T, Mylotte D, Kuperstein R, Indolfi C, Pya Y, Bajraktari G, Kerimkulova A, Rudzitis A, Mizariene V, Lebrun F, Demarco DC, Oukerraj L, Bouma BJ, Steigen TK, Komar M, De Moura Branco LM, Popescu BA, Uspenskiy V, Foscoli M, Jovicic L, Simkova I, Bunc M, de Prada JAV, Stagmo M, Kaufmann BA, Mahdhaoui A, Bozkurt E, Nesukay E, Brecker SJD. ESC/EACTS Guidelines for the management of valvular heart disease. *Eur Heart J* 2017;**38**:2739–2791.
11. Stone GW, Lindenfeld J, Abraham WT, Kar S, Mishell JM, Lim DS, Whisenant B, Grayburn PA, Rinaldi M, Kapadia SR, Rajagopal V, Sarembock IJ, Brieke A, Marx SO, Cohen DJ, Weissman NJ, Mack MJ; COAPT Investigators. Transcatheter mitral-valve repair in patients with heart failure. *N Engl J Med* 2018;doi:10.1056/NEJMoa1806640.
12. Alam M, Dokainish H, Lakkis NM. Hypertrophic obstructive cardiomyopathy—alcohol septal ablation vs. myectomy: a meta-analysis. *Eur Heart J* 2009;**30**:1080–1087.
13. Hong JH, Schaff HV, Nishimura RA, Abel MD, Dearani JA, Li Z, Ommen SR. Mitral regurgitation in patients with hypertrophic obstructive cardiomyopathy: implications for concomitant valve procedures. *J Am Coll Cardiol* 2016;**68**:1497–1504.
14. Liebrechts M, Vriesendorp PA, Mahmoodi BK, Schinkel AF, Michels M, ten Berg JM. A systematic review and meta-analysis of long-term outcomes after septal reduction therapy in patients with hypertrophic cardiomyopathy. *J Am Coll Cardiol Heart Fail* 2015;**3**:896–905.
15. Maron BJ, Nishimura RA. Revisiting arrhythmic risk after alcohol septal ablation: is the pendulum finally swinging...back to myectomy? *J Am Coll Cardiol Heart Fail* 2014;**2**:637–640.