

Contents lists available at [ScienceDirect](http://ScienceDirect)

## International Journal of Surgery Case Reports

journal homepage: [www.casereports.com](http://www.casereports.com)An unusual ischiorectal fossa mass<sup>☆</sup>Cillian Clancy<sup>a,\*</sup>, Zafar Iqbal<sup>a</sup>, Margaret Sheehan<sup>b</sup>, Myles R. Joyce<sup>a</sup><sup>a</sup> Department of Colorectal Surgery, University College Hospital Galway, Ireland<sup>b</sup> Department of Histopathology, University College Hospital Galway, Ireland

## ARTICLE INFO

## Article history:

Received 10 September 2013

Received in revised form

22 November 2013

Accepted 25 November 2013

Available online 16 December 2013

## Keywords:

Ischiorectal fossa

Mucinous tumour

## ABSTRACT

**INTRODUCTION:** Peri-anal fistulae commonly present with collections requiring surgical intervention. The most common cause of a peri-anal mass is abscess formation secondary to anal gland sepsis. In certain patient groups such as those over 65 or with atypical presenting symptoms there are other important considerations.

**PRESENTATION OF CASE:** A 70-year old male was referred by his general practitioner with symptoms of obstructed defaecation and a palpable mass in the ischiorectal fossa. He had previously undergone three operations for complex peri-anal fistulae in another hospital. Due to the previous history of surgery, seroma formation was considered and computed tomography guided drainage of the lesion was performed unsuccessfully. Given symptoms of obstructed defaecation and need for histological diagnosis excision was undertaken. The approach was through a right pararectal incision over the bulk of the mass. Skin and pararectal tissue were divided revealing a mucinous lesion with multiple lobules adherent to pararectal tissue. Following histopathological examination a diagnosis of low grade mucinous neoplasm was made.

**DISCUSSION:** Primary mucinous neoplasm in the ischiorectal fossa is very rare. Diagnostic criteria for adenocarcinoma arising from perianal fistulae have previously been established by Rosser et al. but this lesion does not fall into this category. It is categorised as a mucinous cystic neoplasm of uncertain malignant potential. The differential diagnoses are discussed.

**CONCLUSION:** Consideration should be given to a range of pathologies in cases of atypical peri-anal masses.

© 2013 The Authors. Published by Elsevier Ltd on behalf of Surgical Associates Ltd. All rights reserved.

## 1. Introduction

Complex peri-anal fistulae commonly present with peri-anal collections requiring surgical intervention. The most common cause of a peri-anal collection or mass is abscess formation secondary to anal gland sepsis.<sup>1</sup> In certain patient groups such as those over 65 or with a long history of inflammatory bowel disease there are other important considerations. Among the differential diagnoses to be considered are primary tumours such as rectal or anal adenocarcinoma or secondary spread of intra-abdominal origin, developmental disorders including tailgut cysts and inflammatory or traumatic causes.<sup>2</sup> Here we present an unusual case of a 70-year old male presenting with a palpable mass in the right ischiorectal fossa with a history of multiple previous operations for peri-anal fistulae. Due to worsening symptoms of obstructed defaecation, normal colonoscopy and failure of radiological drainage he

underwent excision of a right sided ischiorectal mass revealing a complex mucinous lesion.

## 2. Case report

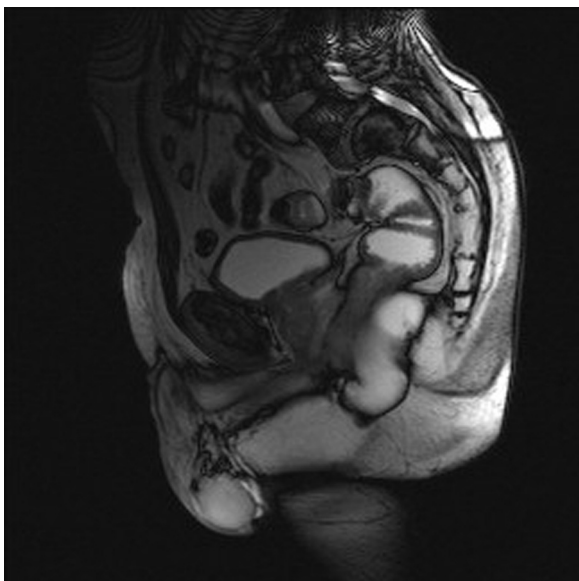A 70-year old male was referred by his general practitioner with symptoms of obstructed defaecation and a palpable mass in the right ischiorectal fossa. He had previously undergone three operations for complex peri-anal fistulae in another hospital four years earlier. Unfortunately no histopathology reports were available. His medical history was significant for ischaemic heart disease and atrial fibrillation.

A check colonoscopy showed diverticular disease but no visible mass. On digital rectal examination he had a palpable swelling in the right ischiorectal fossa compressing the rectum. Magnetic resonance imaging (MRI) showed an 8 cm × 9 cm lobulated fluid collection in the right ischiorectal fossa displacing the rectum (Figs. 1 and 2). There was no evidence of fistulous communication to the collection and no fat stranding or enhancement suggestive of inflammation. Due to the previous history of surgery, seroma formation was considered and computed tomography (CT) guided drainage of the lesion was undertaken. A 17 gauge needle was inserted directly into the lesion in 4 different locations but no fluid was drained. Given symptoms of obstructed defaecation and

<sup>☆</sup> This is an open-access article distributed under the terms of the Creative Commons Attribution-NonCommercial-No Derivative Works License, which permits non-commercial use, distribution, and reproduction in any medium, provided the original author and source are credited.

\* Corresponding author. Tel.: +353 0879910832.

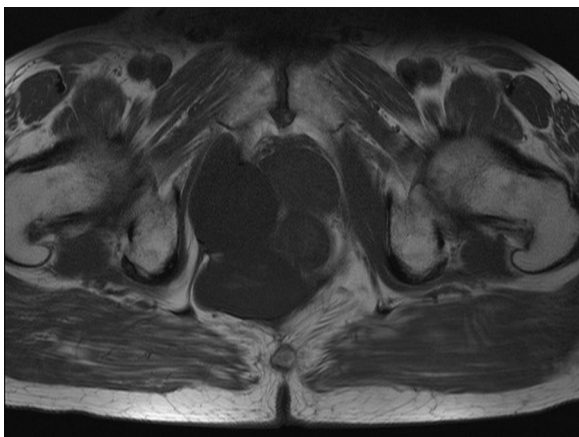
E-mail address: [clancyi@tcd.ie](mailto:clancyi@tcd.ie) (C. Clancy).



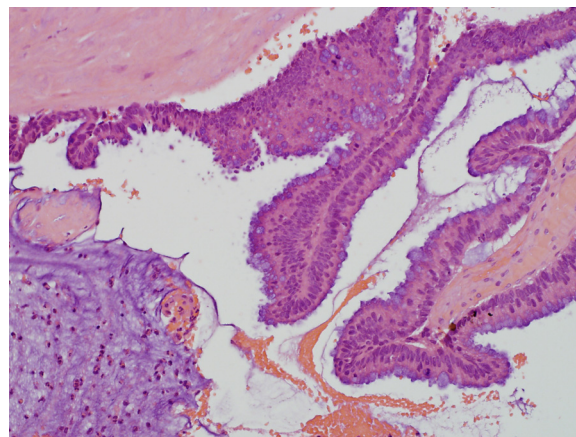
**Fig. 1.** Coronal MR image of lobulated mass displacing the rectum.

need for histological diagnosis the lesion was excised. The surgical approach was through a right para-rectal incision over the bulk of the mass. Skin and pararectal tissue were divided revealing a multi-lobulated mucin containing mass adherent to para-rectal tissue. Differential diagnosis following inspection included a chronic inflammatory process, mucin producing tumour or cyst secondary to previous fistulae and preceding anorectal surgery. The mucin was drained and the associated sac excised from surrounding tissues. No further resection was performed as the lesion was deemed to be fully excised.

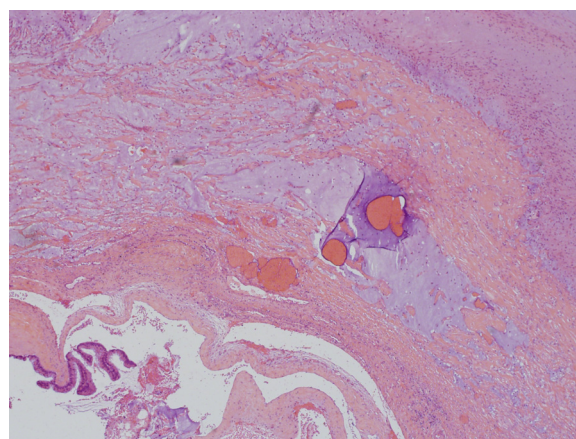
Histopathological examination was undertaken and expert confirmatory opinion from an international centre was sought. The lesion showed focal residual lining of mucin producing neoplastic epithelium with low grade dysplasia (Fig. 3). The luminal mucin dissected into the adjacent peri-rectal fibrous tissue (Fig. 4). Overt invasive adenocarcinoma was not seen. These features are similar to those seen in low grade mucinous neoplasm (of uncertain malignant potential) more frequently seen in sites such as the appendix. Subsequent CT abdomen showed no evidence of an appendicular neoplasm, intra-abdominal mucinous tumour or pseudomyxoma peritonei. The patient was referred to the pseudomyxoma institute at Basingstoke, UK and is recurrence free at 7 months post operatively.



**Fig. 2.** Sagittal MR image of lobulated mass displacing the rectum.



**Fig. 3.** Mucin producing neoplastic epithelium with low grade dysplasia.



**Fig. 4.** Luminal mucin dissecting into adjacent peri-rectal fibrous tissue.

### 3. Discussion

Primary mucin producing epithelial neoplasm arising in the ischio-rectal fossa is rare. Fistula associated peri-anal mucinous adenocarcinoma is an uncommon but recognised occurrence due to malignant transformation of chronic fistula-in-ano.<sup>3</sup> Diagnostic criteria for adenocarcinoma arising from perianal fistulae have previously been established by Rosser. These state that (1) the fistula should precede the carcinoma by a minimum of 10 years, (2) tumour present in the rectum or anal canal should be due to direct extension from carcinoma within the fistula and (3) the internal opening of the fistula should be into the anal canal and not the tumour.<sup>4</sup> In cases fulfilling these criteria the appropriate treatment is abdominoperineal resection with excision of both ischio-rectal fossa and overlying skin as local recurrence is common.<sup>5</sup> While initially considered in the differential diagnosis the lesion described in our case does not fit any of these criteria.

Expert histopathological opinion initially raised the possibility of origin from an intra-abdominal lesion such as a low grade appendiceal mucinous tumour. Intra-abdominal dissemination of mucin and low grade low grade mucinous epithelium is associated with pseudomyxoma peritonei.<sup>6</sup> This diagnosis was excluded clinically and with radiological imaging.

Other possibilities include developmental abnormalities such as tail gut cysts (retrorectal cystic hamartoma) which occur in the retrorectal space but may extend laterally into the ischio-rectal fossa. These may present with peri-anal pain and frequent peri-anal fistulae or abscess formation. These are unilocular or

multicystic masses that adhere to the rectum but do not communicate with the lumen. Malignant degeneration into mucinous carcinoma is a rare complication.<sup>2</sup> Primary neoplasms occurring in the ischioanal fossa have previously been described but are uncommon. Angiomyxoma is a rare neoplasm which can also present with a well defined lobulated mass in the ischioanal fossa but with a different histology to our case.<sup>7</sup>

Detailed imaging excluded primary origin within the abdominal cavity. The histology is neoplastic but not with overt features of adenocarcinoma. It does, histologically show features of a low grade cystic mucinous neoplasm similar to lesions recognised at other sites (e.g. appendix) where they are of uncertain malignant potential. The epithelium of origin of the neoplasm at this site is unclear but could be lining glandular epithelium from a long standing fistula tract or from peri-anal mucin producing glands. The latter, however, is unlikely given the absence of communication/continuity with the anal canal. Due to the rarity and uncertain malignant potential of this lesion, the management is not defined. It has been excised but will require close follow up. Perianal mucinous carcinomas have previously been successfully treated with combinations of external beam radiotherapy and brachytherapy<sup>8</sup> and this is a possible treatment option if the lesion recurs.

Overall this case emphasises that consideration should be given to a wide range of diagnoses in cases of atypical perianal masses. It also reinforces that in patients presenting with obstructed defecation there must be a high index of suspicion for a pelvic lesion. There are no similar reported cases of primary low grade mucinous tumours presenting in the ischioanal fossa and this case represents a challenge in both diagnosis and long term management.

#### Conflicts of interest statement

None.

#### Funding

None.

#### Ethical approval

Written informed consent was obtained from the patient for publication of this case report and accompanying images. A copy of the written consent is available for review by the Editor-in-Chief of this journal on request.

#### Author contributions

Cillian Clancy – writing of manuscript, acquisition of data; Zafar Iqbal – acquisition of data; Margaret Sheehan – acquisition of data, writing of manuscript; Myles Joyce – concept.

#### References

1. Whiteford E. Perianal abscess/fistula disease. *Clin Colon Rectal Surg* 2007;**20**(May (2)):102–9.
2. Llauger J, Palmer J, Perez C, Monill J, Ribé J, Moreno A, et al. The normal and pathological ischioanal fossa at CT and MR imaging. *Radiographics* 1998;**18**(January):62–82.
3. Yang B, Shao W, Sun G, Chen Y, Huang J. Perianal mucinous adenocarcinoma arising from chronic anorectal fistulae: a review from a single institution. *Int J Colorectal Dis* 2009;**24**(September (9)):1001–6.
4. Sierra E, Saenz V, Martinez P, Rocha J. Mucinous adenocarcinoma associated with fistula in ano: a report of a case. *Tech Coloproctol* 2006;**10**:51–3.
5. Sato H, Maeda KM, Maruta M, Kuroda M, Nogaki M, Nogaki M, et al. Mucinous adenocarcinoma associated with chronic anal fistula reconstructed by gracilis myocutaneous flaps. *Tech Coloproctol* 2006;**10**(3):249–52.
6. Panarelli NC, Yantiss RK. Mucinous neoplasms of the appendix and peritoneum. *Arch Pathol Lab Med* 2011;**135**(10):1261–8.
7. Hastak M, Raqhuvanshi S, Sahu S, Vyankatesh A, Ramraje S, Ranjan A, et al. Aggressive angiomyxoma in men. *J Assoc Phys India* 2008;**56**:373–5.
8. Nishimura T, Nozue M, Suzuki K, Imai M, Suzuki S, Sakahara H, et al. Perianal mucinous carcinoma successfully treated with a combination of external beam radiotherapy and high dose rate interstitial brachytherapy. *Br J Radiol* 2000;**73**(870):661–4.

#### Open Access

This article is published Open Access at [scimedirect.com](http://scimedirect.com). It is distributed under the [IJSCR Supplemental terms and conditions](#), which permits unrestricted non commercial use, distribution, and reproduction in any medium, provided the original authors and source are credited.