

POINT OF TECHNIQUE

Modified one-stage dorsal-inlay buccal mucosa graft technique for ventral penile urethral and penile skin erosion: A step-by-step guide



Lennert Van Putte^{a,*}, Gunter De Win^{a,b}

^a Faculty of Medicine and Health science, University of Antwerp, Antwerp, Belgium

^b Department of Urology, Antwerp University Hospital, Antwerp, Belgium

Received 3 July 2016, Received in revised form 23 July 2016, Accepted 21 August 2016

Available online 23 September 2016

KEYWORDS

Urethral erosion;
Urethral laceration;
Penile urethroplasty;
Buccal mucosa;
Graft

Abstract Objective: To demonstrate the use of a modified single-stage technique for the repair of a ventral penile urethral erosion with involvement of the penile skin, as penile urethral erosion is a rare but potential complication of chronic indwelling catheterisation with a lack of available recommendations for reconstructive options.

Patient and methods: A 44-year-old male with paraplegia, neurogenic bladder dysfunction and chronic sacral decubitus, presented with a large mid-penile erosion of the ventral penile shaft and urethra, which was caused by chronic transurethral indwelling catheterisation while being hospitalised in an intensive care unit. The reconstruction involved a single-stage dorsal-inlay buccal mucosa graft urethroplasty (Asopa) in addition to the second stage of a two-stage urethroplasty. The urethroplasty as well as the buccal mucosa graft harvest were performed by a single team.

Results: The modified single-stage urethroplasty procedure had a duration of 158 min with a postoperative hospitalisation of 3 days. At 8-months follow-up, the lesion had fully healed and the patient was back on clean intermittent

* Corresponding author at: Faculty of Medicine and Health Science, University of Antwerp, Berkenlaan 36, 2610 Wilrijk, Antwerp, Belgium. Fax: +32 3 821 44 79.

E-mail address: Lennert.vanputte@gmail.com (L. Van Putte).

Peer review under responsibility of Arab Association of Urology.



Production and hosting by Elsevier

self-catheterisation with solifenacin 10 mg daily. No complications occurred postoperatively.

Conclusion: The modified single-stage dorsal-inlay technique is a viable method for repairing ventral penile urethral erosion with involvement of penile skin.

© 2016 Production and hosting by Elsevier B.V. on behalf of Arab Association of Urology. This is an open access article under the CC BY-NC-ND license (<http://creativecommons.org/licenses/by-nc-nd/4.0/>).

Introduction

For the repair of ventral urethral defects many single-stage techniques exist. The most well-known techniques are probably the transverse preputial island flap technique, as described by Duckett [1], penile/preputial cutaneous island flap urethroplasty as described by Quartey [2], and the penile island flap, as described by Orandi [3]. The use of buccal mucosa in urethral stricture repair has gained increasingly more traction during recent decades because it is readily available in all patients, easy to harvest, and has a thick elastin-rich epithelium. Moreover, it is hairless and has a thin and highly vascular lamina propria. The use of buccal mucosa graft was first introduced by Humby and Higgins [4] in 1941 as a one-stage operation for hypospadias. In 1993, el-Kasaby et al. [5] were the first to report its use in the repair of penile and bulbar strictures in adult men without hypospadias. In the ensuing years, many clinical experiences and experimental studies have contributed to the further development and evolution of the use of buccal mucosal grafts. In 2001, Asopa et al. [6] described the dorsal-inlay technique for the repair of anterior urethral strictures. In more extended cases of penile urethral pathology, e.g. lichen sclerosus or severe hypospadias, a two-stage urethroplasty is indicated as popularised by Bracka [7] in 1995. As ventral penile urethral erosions are rare, a standardised approach for the repair is not yet available. The following procedure presents a step-by-step demonstration of a technique for the repair of

a penile urethral erosion with a modified dorsal-inlay buccal mucosa graft.

Patient and methods

A 44-year-old male with a history of a circumcision, paraplegia, and neurogenic bladder dysfunction, presented with a large mid-penile erosion of the ventral penile shaft and urethra. This was caused by chronic transurethral indwelling catheterisation while being admitted in an intensive care unit because of haemodynamic instability after surgery for chronic sacral decubitus (Fig. 1).

Technique

For the repair, a combination of a one-stage dorsal-inlay buccal mucosa graft urethroplasty (Asopa [6]) and the second stage of a two-stage urethroplasty (Bracka [7]) are used. The procedure should be conducted by a team of at least three: one surgeon, one assistant, and one scrub nurse. Ideally, a second team of at least two members could simultaneously harvest and prepare the buccal mucosa graft, which would reduce the operating time by 30–40 min.

Preoperative preparation with chlorhexidine mouthwash for oral cleansing is started 3 days before surgery. A broad-spectrum antibiotic, e.g. Co-amoxiclav, is administered i.v. during surgery.

The patient is placed supine, disinfected and draped sterilely, with inclusion of the right upper leg to harvest a split thickness graft if necessary. Ideally, a traction suture is placed through the glans (non-cutting 4/0 polypropylene suture).

The urethral plate is separated from the penile skin and dartos tissue: first by an incision at the mucocutaneous junction and subsequently by sharp dissection, as in the second stage of a two-stage repair (Fig. 2.1). Next, the urethral plate is incised at the midline over a length corresponding to the length the defect, which was 5 cm in this case (Fig. 2.2). The length of the incision is noted, as the buccal mucosa graft should be at least 1 cm longer than this. The medial margins of the incised dorsal urethral plate are moved laterally by sharp incisions with a scalpel blade, parallel to the midline incision and down to the tunica albuginea (Fig. 2.3). This creates a suitable elliptical section up to 2 cm over

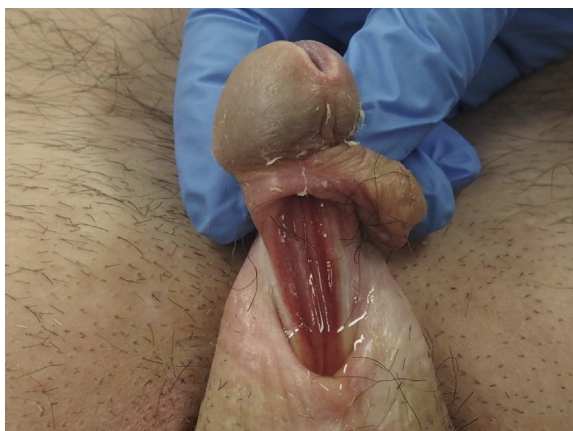

Figure 1 Preoperative situation.

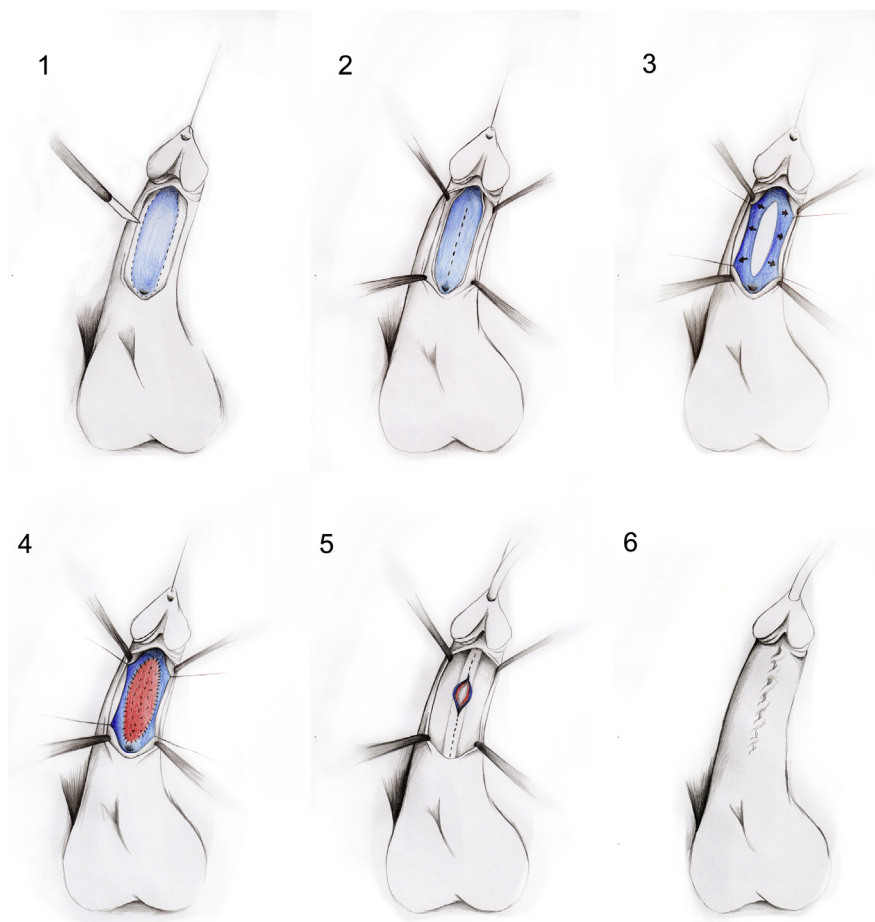


Figure 2 Schematic drawing of the procedure. 1. Dissection of the urethral plate from the penile skin and dartos tissue. 2. Midline incision of the urethral plate over the length of the defect. 3. Moving the medial margins of the incised dorsal urethral plate laterally. 4. Suturing the buccal mucosa graft to the medial margins and quilting the graft to the corporal bodies. 5. Ventrally closing the lateral margins over a 16-F silicone catheter. 6. Mobilising and closing of dartos tissue and penile skin.

the tunica albuginea flanked by the incised medial edges of the urethral plate.

For the harvest of the buccal mucosa graft, the team repositions and makes use of a different sterile surgical equipment set. To be able to perform the harvest by means of two members only, the use of a mouth retractor is advised. Two stay sutures are placed in the cheek. The opening of the parotid duct is marked with a surgical pen. Infiltration with saline results in hydrodissection, which makes subsequent sharp dissection easier and minimises blood loss. The harvest is done with a n°15 blade. A buccal mucosa graft is harvested with the dimensions of 2×6 cm and defatted to ensure plasmatic imbibition.

The graft is first sutured to the medial free urethral margins, with trimming of the edges if necessary (Fig. 2.4). Securely quilting the graft to the corporal bodies with a monofilament 5/0 (polyglactin) ensures capillary inosculation over time. For the tubularisation, the lateral margins of the urethral plate are approximated and closed ventrally over a 16-F silicone catheter

with a monofilament 5/0 continuous inverting suture (Fig. 2.5). A dartos fascial layer is exposed and closed over the urethra, to prevent fistula formation and ensure postoperative penile skin mobility. The skin edges are mobilised and approximated to test for the possibility of tension-free closure, which was possible in our patient. If this was not possible, an additional split-thickness skin graft would have to be taken from the right upper leg. Finally, the penile skin is closed with simple interrupted delayed absorbable sutures, corresponding to the last step of a two-stage repair (Fig. 2.6). It is of primary importance to ensure different suture lines in all three layers, so that none of them actually overlap, to prevent fistula formation.

Afterwards, a soft penile sandwich dressing is applied. The penis and catheter are fixed on the lower abdomen. This prevents catheter pull and friction during nocturnal penile tumescence. A honey-based paste is applied to the buccal wound and an ice bag is applied to the cheek from the outside. Oral broad-spectrum antibiotics, e.g. Co-amoxiclav, are prescribed for the

first 10 days postoperatively, to ensure healthy incorporation of the oral mucosa graft, which contains oral commensals.

Postoperatively, the mouth is rinsed twice daily with a local antiseptic. On the first postoperative day, the patient is allowed to drink cold drinks only. On the second day, soft and cold foods are added. On the second postoperative day, the penile dressing is removed and the wound is inspected. On the third postoperative day, the patient leaves the hospital with the transurethral catheter *in situ*, set for continuous drainage.

The catheter is left *in situ* for 3 weeks. Normally, before removal of the catheter, a voiding cystourethrography would be conducted. However, in this case because of neurogenic bladder dysfunction, this was not performed. Long-term follow-up is needed, especially in the case of ensuing clear intermittent self-catheterisation, to ensure urethral function over time.

Results

The procedure was completed in 158 min. The patient left the hospital in good condition at 3 days postoperatively. The catheter was successfully removed 3 weeks after surgery, after which the patient started clean intermittent self-catheterisation again. Fig. 3 shows the results at 3-months postoperatively. At 8 months after surgery, no complications had occurred and the patient was fully dry with clean intermittent self-catheterisation and solifenacin 10 mg daily.

Discussion

Penile urethral erosion is a potential complication of chronic indwelling catheterisation. Ventral erosion of the penis by indwelling catheter can lead to bleeding from the raw edges of the split urethra, and increased chances of UTI because of a shorter urethra [8]. Most patients have serious comorbidities and a single operation usually does not solve all the problems [9]. The urethral defect requires a substitute, in the form of a flap or a graft, to repair it. Additionally, the erosion of the penile skin, limits the options of repair. The use of a ventral flap (Orandi [3]) is therefore not possible. A prepuceal transverse island flap (Duckett [1]) was not possible because of previous circumcision. Hence, the only option is to make use of a free graft that is placed dorsally to guarantee a well-vascularised underlying tissue, like the corporal bodies, ensuring capillary inosculation over time.

Because of neurogenic bladder dysfunction, a voiding cystourethrography could not be conducted before removal of the catheter. Retrograde pericatheter urethrography was an alternative but we did not conduct this study before removal of the catheter.

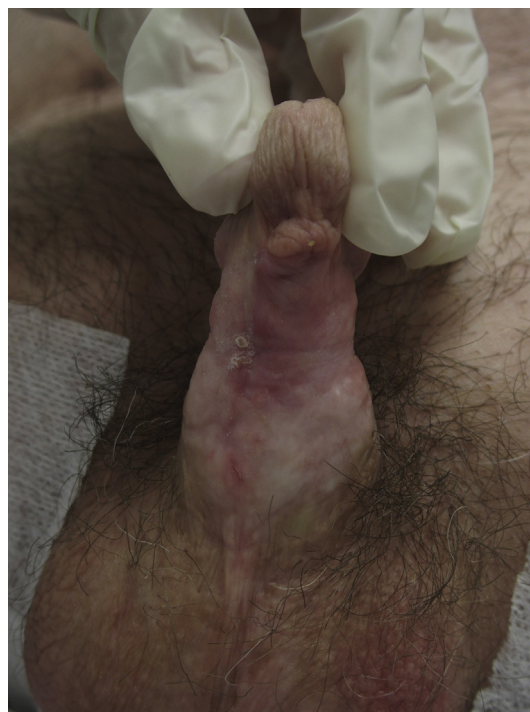

Figure 3 Postoperative situation at 3 months.

One possible problem of the presented technique could be the superposition of the suture lines. When closing primary, both the running urethral tubularisation suture and the skin closure sutures are often situated at the midline and lay on top of each other. This could possibly increase the risk of fistula formation. Normally, when conducting an Asopa reconstruction, penile degloving assures a healthy overlying skin layer on top of the reconstructed urethra-tunica-dartos complex. However, erosion of the ventral penile skin made this step obsolete. This resulted in a skin and dartos gap at the end of the procedure instead of a skin glove. To overcome this issue, the dartos fascia was mobilised from one side only, and sutured to the other side. This resulted in a more laterally placed suture line and therefore no directly overlapping suture lines. At 8 months postoperatively, long after dissolving of the sutures, no fistulisation had occurred.

Conclusions

In conclusion, the modified one-stage buccal mucosa graft-inlay technique is a viable method for repairing penile urethral erosions with involvement of penile skin.

Conflicts of interest

None.

Acknowledgements

We would like to thank Silke Denteneer for the schematic drawing of the procedure.

Appendix A. Supplementary data

Supplementary data associated with this article can be found, in the online version, at <http://dx.doi.org/10.1016/j.aju.2016.08.003>.

References

- [1] Duckett Jr JW. Transverse preputial island flap technique for repair of severe hypospadias. *Urol Clin North Am* 1980;**7**:423–30.
- [2] Quartey JK. One-stage penile/preputial cutaneous island flap urethroplasty for urethral stricture: a preliminary report. *J Urol* 1983;**129**:284–7.
- [3] Orandi A. One-stage urethroplasty. *Br J Urol* 1968;**40**:717–9.
- [4] Humby G, Higgins TT. A one-stage operation for hypospadias. *Br J Surg* 1941;**29**:84–92.
- [5] el-Kasaby AW, Fath-Alla M, Noweir AM, el-Halaby MR, Zakaria MH, el-Beialy MH. The use of buccal mucosa patch graft in the management of anterior urethral strictures. *J Urol* 1993;**149**:276–8.
- [6] Asopa HS, Garg M, Singhal GG, Singh L, Asopa J, Nischal A. Dorsal free graft urethroplasty for urethral stricture by ventral sagittal urethrostomy approach. *Urology* 2001;**58**:657–9.
- [7] Bracka A. Hypospadias repair: the two-stage alternative. *Br J Urol* 1995;**76**(Suppl. 3):31–41.
- [8] Vaidyanathan S, Soni BM, Hughes PL, Singh G, Oo T. Severe ventral erosion of penis caused by indwelling urethral catheter and inflation of Foley balloon in urethra—need to create list of “never events in spinal cord injury” in order to prevent these complications from happening in paraplegic and tetraplegic patients. *Adv Urol* 2010 461539.
- [9] Stoffel JT, McGuire EJ. Outcome of urethral closure in patients with neurologic impairment and complete urethral destruction. *Neurourol Urodyn* 2006;**25**:19–22.