

Case Report

Minimal Invasive Surgical Management of Familial Arteriovenous Malformation

Mokhtar Mamdouh Abdel-Latif¹ and Shankargouda Patil² 

¹Maxillofacial Surgery and Diagnostic Sciences, Division of Oral Surgery, College of Dentistry, Jazan University, Jazan, Saudi Arabia

²Maxillofacial Surgery and Diagnostic Sciences, Division of Oral Pathology, College of Dentistry, Jazan University, Jazan, Saudi Arabia

Correspondence should be addressed to Shankargouda Patil; dr.ravipatil@gmail.com

Received 30 January 2021; Accepted 25 May 2021; Published 10 June 2021

Academic Editor: Pia L. Jornet

Copyright © 2021 Mokhtar Mamdouh Abdel-Latif and Shankargouda Patil. This is an open access article distributed under the Creative Commons Attribution License, which permits unrestricted use, distribution, and reproduction in any medium, provided the original work is properly cited.

Introduction. Familial arteriovenous malformations are exceedingly rare. They are often noted at birth. They can also present during childhood or adolescence. Sclerotherapy has proven to have a favorable outcome. **Case Presentation.** The present case report describes the treatment of arteriovenous malformations on the tongue, labial mucosa, and vermilion border in siblings treated with boiling saline injections. **Conclusion.** Sclerotherapy using boiling saline had shown to effectively treat arteriovenous malformations in the oral region without any significant morbidity.

1. Introduction

“Vascular malformation” is a generalized term used for the description of a set of congenital errors during vascular development, due to anomalous proliferation of vascular (angio/lympho) structures. This condition occurs in about one percent of births and is often very mild and does not require therapy [1]. Currently, Mulliken and Glowacki’s 1982 classification system is still held as a standard for vascular anomalies. The classification system is based on the parameters that include the clinical, histopathological presentation, and biological behavior [2, 3]. Arteriovenous malformations (AVMs) are categorized as malformations with a high-flow capability as they involve arteriovenous communications without the intermediate capillary network [4]. Also, the proliferation of AVM is induced by several other factors such as ischemia secondary to thrombosis, puberty, changes in hormonal levels, trauma, and ectasia. In the case of trauma, only a single vessel is involved in AVM; however, when the condition is familial, multiple vessels are involved [5, 6].

The head and neck are one of the most common sites (nearly 60% cases) for AVM [7]. 4 to 5% of all craniofacial AVMs occur in the gnathic bones. AVMs of the gnathic bones are relatively harder to treat [4]. Familial AVMs are exceedingly rare. RASA1 gene mutation expressing p120-Ras GAP, on chromosome 5q, has been reported to be associated with familial congenital AVM [8]. Most cases of familial AVMs are noted at birth although childhood or adolescence manifestations are not uncommon. Rarely, AVMs can associate with high output cardiac failure and cardiomegaly. The lesions progress gradually and have can potentially manifest in any body part including the oral cavity. Within the oral cavity, the tongue (anterior two-thirds), gingival, palate, and buccal mucosa are the most frequently reported sites of occurrence [9]. Kohout et al. has reported the largest case series of 81 cases of AVM that manifested in the oral cavity. In their case series, 31% occurred in the cheek (31%), 16% in the ears, 10% in the nose and forehead each, 7% in the upper labial mucosa, 5% each in the mandible and neck, and 4% each in the scalp and maxilla [5].

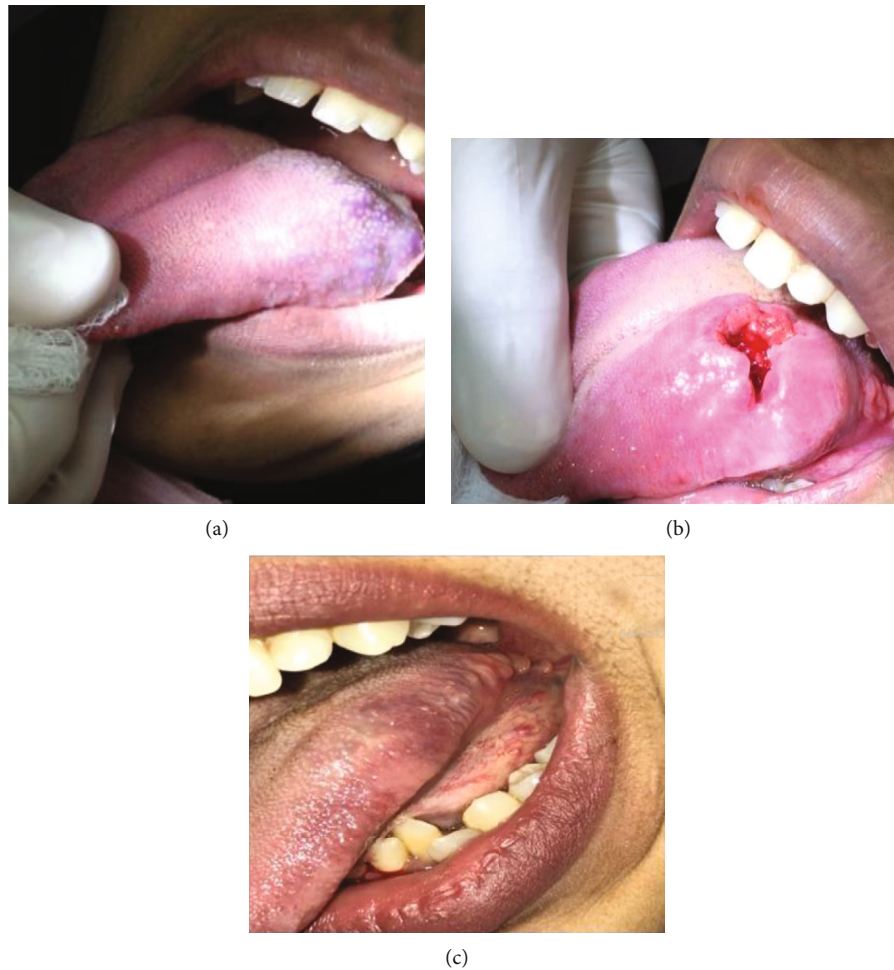


FIGURE 1: (a) Preoperative AVM primary lesion of the left posterior region of the tongue; (b) AVM primary lesion opened after being injected 2 times; (c) follow-up after complete resolution of the primary AVM lesion by 3 years.

Clinically, these lesions occur as a pulsatile mass with a thrill, bruit, and rarely local hyperthermia with bleeding. There is a decreased vascularity leading to decreased nutrition supply resulting in necrosis, ulceration, bleeding, and impairment of function. The skin over the lesions is seen to have a reddish or true port-wine hue [10, 11].

Considering the diagnosis of the condition, the most common diagnostic modalities include radiography, CT (computed tomography scans), MRI (magnetic resonance imaging), and angiography [12]. Given the complex anatomical pathology, the treatment strategy for an AVM often involves multispecialties. The most common conventional therapeutic modalities suggested for AVM are a combination of surgical resection, sclerotherapy, and endovascular embolization techniques [12]. Ramakrishnan et al. in their systematic review have reported that the management of various vascular malformations included AVM. In their review, 6 articles reported various management techniques of AVM [13]. Deng et al. had reported Superselective Intra-Arterial Embolization (SIAE) followed by curettage (CT) or surgical resection (SR) for the management of AVM with complete involution and favorable prognosis [14].

SIAE and CT followed by sclerotherapy with complete involution and absence of recurrence was reported by Chen

et al. [15]. Chen et al. reported 60.7% involution with recurrence and complications associated with sclerotherapy and fractionated radiotherapy [16]. Fan et al. reported 80% involution associated with complications in direct puncture embolization [17], and Zhao et al. reported 100% involution and nil recurrence with sclerotherapy alone [18]. Behnia et al. reported that curettage via proximal osteotomy without complete resection is an effective and less invasive method with more esthetics and better function in comparison with surgical resection [19].

Recently, LASERS, especially CO₂ and Er, Cr:YSGG, have been reported to be a successful tool for the treatment of AVM cases [20]. In the present paper, we present the minimally invasive surgical management of familial soft tissue AVM of the oral cavity reported in siblings.

2. Case Reports

2.1. 1st Case. A female patient 16 years of age reported to the Department of Oral and Maxillofacial Surgery of the College of Dentistry, Jazan University, Jazan, Saudi Arabia. The patient's medical history did not reveal any significant findings. The primary complaint of the patient was a persistent

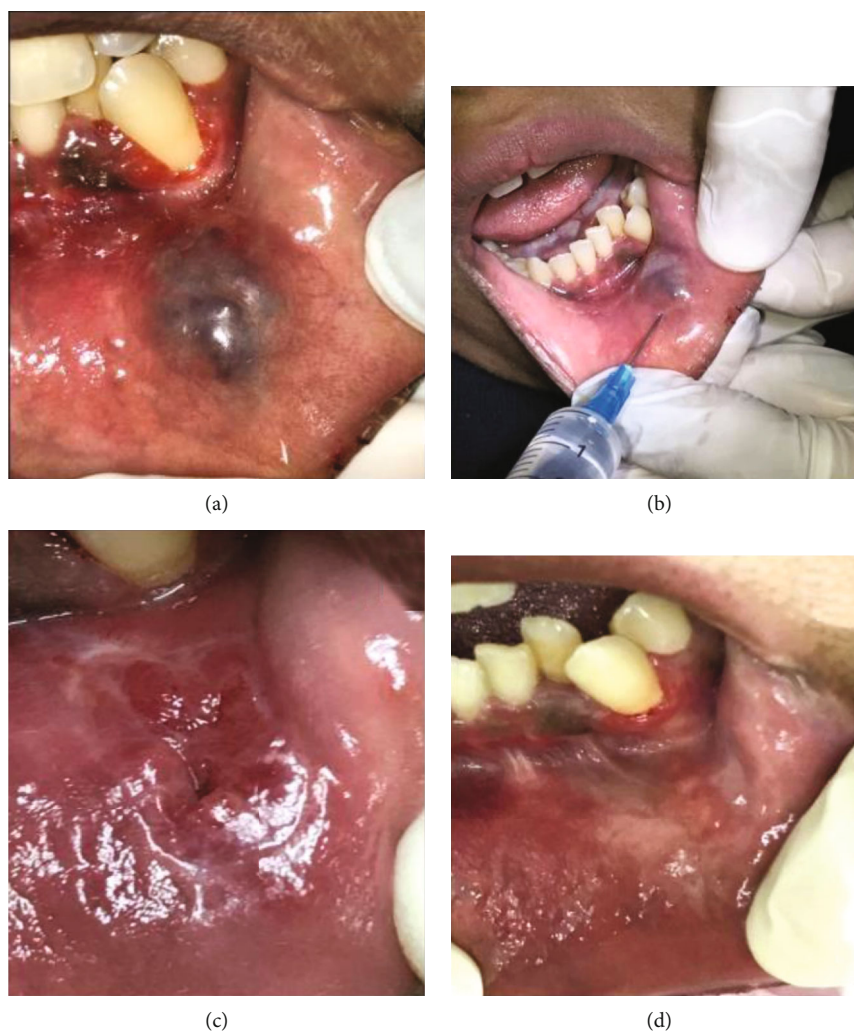


FIGURE 2: (a) Second lesion which appeared after the tongue lesion had resolved by 2 years; (b) boiling saline injection of the second AVM lesion; (c) second AVM lesion on the way to healing after 3 boiling saline injections; (d) second AVM lesion after 1 year of complete healing.

swelling of 10-year duration in the tongue. The swelling was not associated with pain and had been increasing in size gradually. There were no other symptoms associated with the swelling. On examination, the lesion was multilobulated and bluish with intact overlying mucosa and was present along the left lateral border and dorsum of the tongue opposite the mandibular left second molar. The lesion measured 4 cm by 6 cm by 0.7 cm (Figure 1(a)).

The consistency of the swelling was soft. Palpation did not reveal any tenderness. On compression, the swelling blanched. The swelling did not have any significant pulsation. All hematological parameters were within the physiological limit. Potential bone involvement was ruled out with the aid of plain radiographs. The AVM diagnosis was inferred using the findings from the MRI.

The patient was advised conservative surgical management using boiling saline injection. The procedure and possible complications were explained to the patient, and written informed consent was obtained. The patient was injected with 5 ccs of boiling saline after she was given a lingual nerve block, then the pressure was applied to the lesion to control bleeding.

The patient was given postoperative instructions and recalled after two weeks. The same procedure was repeated at the recall appointment. One week later, the lesion was examined, and fibrosis was observed along with an open wound on the surface at the center of the lesion (Figure 1(b)). The patient was prescribed Levofloxacin Tab 500 mg (Sanofi Winthrop industries, 56, route de Choisy au Bac, 60205 Compiègne, France), one tablet a day for 5 days, and Ibuprofen Tab 200 mg (Wyeth Pharmaceuticals Company, Guayama, PR, USA), 2 tablets twice a day for 5 days. The lesion had healed uneventfully three months after the first injection (Figure 1(c)). The patient was followed up for three years, and the tongue lesion was free from any symptoms or recurrence. However, two years into the treatment of the tongue lesion, another arteriovenous malformation at the labial mucosa on the left side opposite the left lower canine tooth was noticed. The lesion was about 4 × 3 cm in size and about 0.5 cm in height (Figure 2(a)). The patient was administered the first boiling saline injection after giving her a mental nerve block (Figure 2(b)).

The saline (4 ccs) was injected around the lesion from different aspects while pointing the needle towards the depth of

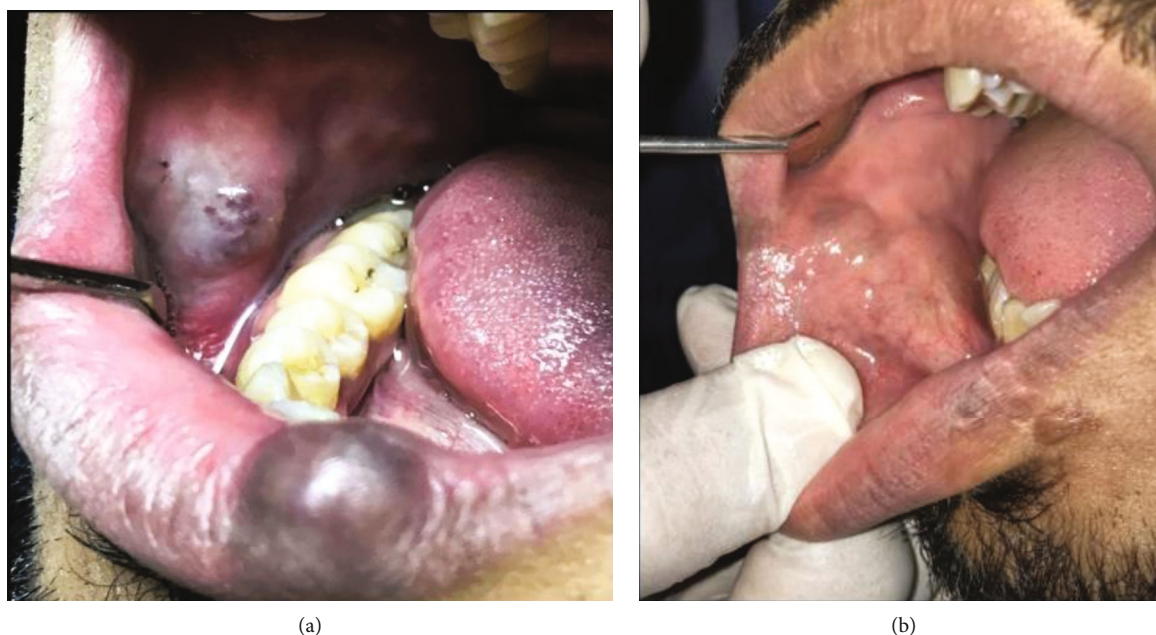


FIGURE 3: (a) Preoperative photograph of both lip and cheek AVM lesions; (b) postoperative photograph of both lip and cheek AVM lesions.

the lesion. For this lesion, the patient was injected with boiling saline on two other occasions that are two and three months after the first injection. The lip lesion started healing uneventfully four months after the first appointment (Figure 2(c)). There were no signs of any complications or recurrence at the six-month and one-year follow-up (Figure 2(d)).

2.2. 2nd Case. The brother of the patient in case 1 was a 23-year-old who used to visit the department with his sister for her appointments. The patient had two AVMs. The first lesion was on the lower vermillion border on the left side and measured 2.5 cm by 1.5 cm. The lesion led to the visible asymmetry of the lower lip. The second lesion was present on the right buccal mucosa opposite to the first lower right molar and extending to the canine tooth, measuring about 4 × 3 cm (Figure 3(a)). The lesions were not associated with pain and had been increasing in size gradually. On examination, the lesion was multilobulated and bluish. The examination did not reveal any discontinuity in the surface mucosa. As reported for the 1st case, palpation revealed that the lesion was soft and nontender and on compression exhibited blanching. No significant pulsation was noted. Hematological parameters were all within the physiological limit. Bone involvement was ruled out with plain radiographs. AVM diagnosis was inferred with the findings from the MRI. Citing cosmetic concerns, treatment was sought for the lesion. After obtaining informed consent, the same treatment plan as used for the sister was advised to the patient. He was injected with 4 ccs of boiling saline around the lip lesion and at different

depths under the mental nerve block. The pressure was applied to the lesion to control bleeding. The patient was given postoperative instructions and recalled after two weeks.

The patient was given three additional injections at one week, four weeks, and six weeks after the first injection. Additionally, the patient was prescribed Panthenol 10% gel (Pamex Pharmaceuticals, Germany) for application on the skin of the lip. The healing was uneventful with no complication or recurrence at the three-month and six-month appointments (Figure 3(b)).

3. Discussion

AVMs frequently noted at birth can manifest in childhood/adolescence [1, 9]. In the present cases, the patients had a history of the AVMs for about ten years and have been constantly growing in size. Kohout et al. reported the location of 81 AVMs in the head and neck. The cheek (31%) was the most common site followed by the ear (16%), nose (10%), upper lip (7%), mandible (5%), neck (5%), scalp (5%), and maxilla (4%) [8]. Within the oral cavity, the AVM's most frequent site is the tongue as in the present case. The lesser-known sites for intraoral AVM include the gingiva, palate, and buccal mucosa. AVM can be a major hurdle during speech, mastication, and deglutition and often get traumatized resulting in ulceration and secondary infection [21, 22]. In our cases, one lesion was on the tongue and two were on the lip (one on the labial mucosa and one on the vermillion border). The patients did not report any symptoms

associated with the lesions and decided to undergo treatment for aesthetic reasons only.

Management of AVMs has always posed a challenge among clinicians because of their unpredictable behavior and high recurrence rate [23, 24]. Over the years, a plethora of approaches, including surgical excision, irradiation, electrocoagulation, cryotherapy, intravascular magnesium or copper needles, systemic corticosteroids, interferon- α , embolization, lasers, and sclerotherapy, has been tried for the management of these lesions. However, there is no universally accepted model of treatment for AVMs [25–27]. Moreover; each method has its limitations and disadvantages. Surgical excision, owing to the complicated anatomy of the face and neck, may result in significant loss of function, aesthetic issues, hemorrhage, or nerve damage [28]. Laser therapy is expensive. Additionally, it may lead to scarring and hyperpigmentation. Similar issues have also been noted with cryotherapy [29, 30]. Corticosteroids have systemic effects like adrenal suppression and weight gain [31].

Sclerotherapy is a conservative and low-cost technique for the effective treatment of vascular lesions of benign nature, including AVMs. It is particularly advantageous in surgically inaccessible areas. Sclerotherapy causes minimal scarring and has relatively fewer complications as compared to surgical excision [32]. Many sclerosing agents, for example, 5% sodium morrhuate, 5% ethanolamine oleate, sodium phyllite, 1% polidocanol, sodium tetradecyl sulfate, quinine urethane, hypertonic saline, and absolute ethanol, alone or in combination, have been used with varying results [24, 27].

In the present cases, boiling saline was used as the sclerosing agent for the treatment. The heat released from the boiling saline dehydrates the endothelial and red blood corpuscles, causing necrosis-induced vessel lumen obliteration, which in turn augments blood coagulation and vessel death. Additionally, it is readily available, acceptable to the patients as it is not a chemical, hypoallergenic, and inexpensive [33–35].

Sclerotherapy has certain potential complications like ulcerations, swelling, infection, transient nerve damage, hemorrhage, and anaphylaxis [35]. However, none of the aforementioned complications were observed in our patients. Eltohami and Abuaffan used hot saline for the treatment of a venous malformation in the tongue with success [33]. Water and hypertonic saline have also been used as means for sclerotherapy in venous malformations by Obuekwe et al. [36] and Oji et al. [37].

4. Conclusion

Arteriovenous malformations of the oral cavity might be associated with several complications apart from being an aesthetic concern. Therefore, prompt diagnosis and treatment are warranted for such lesions. Sclerotherapy with boiling saline provides an effectively safe therapeutic modality for intraoral AVMs. This method resulted in complete remission and alleviation of their symptoms, with no complications. No recurrence of the lesions was observed during the follow-up period.

Ethical Approval

All procedures performed in studies involving human participants were under the ethical standards of the institutional and/or national research committee and with the 1964 Helsinki declaration and its later amendments or comparable ethical standards.

Consent

Consent for publication was obtained for every individual person's data included in the study. Informed consent was obtained from all individual participants included in the study.

Conflicts of Interest

The authors declared no potential conflicts of interest concerning the research, authorship, and/or publication of this article.

Authors' Contributions

Mokhtar Mamdouh Abdel-Latif performed treatment of the cases and contributed to writing the manuscript. Shankargouda Patil diagnosed the case and contributed to writing the manuscript. All the authors approved the final manuscript being submitted here.

References

- [1] F. Martines and V. Immordino, "Arteriovenous malformation of the base of tongue in pregnancy: case report," *Acta Otorhinolaryngologica Italica*, vol. 29, no. 5, pp. 274–278, 2009.
- [2] G. T. Richter and A. B. Friedman, "Hemangiomas and vascular malformations: current theory and management," *International Journal Of Pediatrics*, vol. 2012, Article ID 645678, 10 pages, 2012.
- [3] J. B. Mulliken and J. Glowacki, "Hemangiomas and vascular malformations in infants and children: a classification based on endothelial characteristics," *Plastic and Reconstructive Surgery*, vol. 69, no. 3, pp. 412–420, 1982.
- [4] M. N. Pandhare, D. B. Jyoti, M. S. Mandale, and R. B. Suresh, "Acquired arteriovenous malformation of lip occurring as an occupational hazard: a case report with review of literature," *Journal of Oral and Maxillofacial Pathology*, vol. 22, no. 2, p. 287, 2018.
- [5] M. P. Kohout, M. Hansen, J. J. Pribaz, and J. B. Mulliken, "Arteriovenous malformations of the head and neck: natural history and management," *Plastic and Reconstructive Surgery*, vol. 102, no. 3, pp. 643–654, 1998.
- [6] J. B. Boyd, J. B. Mulliken, L. B. Kaban, J. Upton, and J. E. Murray, "Skeletal changes associated with vascular malformations," *Plastic and Reconstructive Surgery*, vol. 74, no. 6, pp. 789–795, 1984.
- [7] N. Syed, "Vascular lesions of head and neck: a literature review," *Indian Journal of Dental Sciences*, vol. 8, no. 3, p. 176, 2016.
- [8] M. Pujari, S. Bahirwani, B. P. R. Kaul, B. Shah, and D. Daryani, "Arteriovenous malformation of tongue: a case report and

- review of literature,” *Journal of Indian Academy of Oral Medicine and Radiology*, vol. 23, pp. 139–142, 2011.
- [9] S. M. Manjunath, S. Shetty, N. J. Moon et al., “Arteriovenous malformation of the oral cavity,” *Case Reports in Dentistry*, vol. 2014, Article ID 353580, 5 pages, 2014.
- [10] Y. W. Chiu, H. T. Wu, Y. W. Chan, M. T. Lui, and S. Y. L. W. Kao, “A giant venous malformation of face and neck—a case report,” *Taiwan Journal of Oral and Maxillofacial Surgery*, vol. 22, no. 2, pp. 110–117, 2011.
- [11] I. C. Duncan and P. A. Fourie, “Vascular malformations part 2- current classification of vascular malformations,” *South African Journal of Radiology*, vol. 8, no. 1, p. 23, 2004.
- [12] G. Noreau, P. P. Landry, and D. Morais, “Arteriovenous malformation of the mandible: review of literature and case history,” *Journal of the Canadian Dental Association*, vol. 67, no. 11, pp. 646–651, 2001.
- [13] K. Ramakrishnan, I. Palanivel, V. Narayanan, S. Chandran, and P. Gurram, “Management of vascular malformations in the oral and maxillofacial region: a systematic review,” *Journal of Stomatology, Oral and Maxillofacial Surgery*, vol. 20, 2021.
- [14] W. Deng, D. Huang, S. Chen et al., “Management of high-flow arteriovenous malformation in the maxillofacial region,” *The Journal of Craniofacial Surgery*, vol. 21, no. 3, pp. 916–919, 2010.
- [15] W. Chen, J. Ye, L. Xu, Z. Huang, and D. Zhang, “A multidisciplinary approach to treating maxillofacial arteriovenous malformations in children,” *Oral Surgery, Oral Medicine, Oral Pathology, Oral Radiology, and Endodontics*, vol. 108, no. 1, pp. 41–47, 2009.
- [16] W. Chen, J. Wang, J. Li, and L. Xu, “Comprehensive treatment of arteriovenous malformations in the oral and maxillofacial region,” *Journal of Oral and Maxillofacial Surgery*, vol. 63, no. 10, pp. 1484–1488, 2005.
- [17] X. Fan, Z. Zhang, C. Zhang et al., “Direct-puncture embolization of intraosseous arteriovenous malformation of jaws,” *Journal of Oral and Maxillofacial Surgery*, vol. 60, no. 8, pp. 890–896, 2002, discussion 896-7.
- [18] X. Zhao, Z. Huang, W. Chen, Y. Wang, and Z. Lin, “Percutaneous sclerotherapy of arteriovenous malformations of the face using fibrin glue combined with OK-432 and bleomycin after embolisation,” *The British Journal of Oral & Maxillofacial Surgery*, vol. 54, no. 2, pp. 187–191, 2016.
- [19] H. Behnia, I. Ghodoosi, M. H. K. Motamedi, A. Khojasteh, and A. Masjedi, “Treatment of arteriovenous malformations: assessment of 2 techniques – transmandibular curettage versus resection and immediate replantation,” *Journal of Oral and Maxillofacial Surgery*, vol. 66, no. 12, pp. 2557–2565, 2008.
- [20] U. Romeo, A. del Vecchio, C. Russo et al., “Laser treatment of 13 benign oral vascular lesions by three different surgical techniques,” *Medicina Oral, Patología Oral y Cirugía Bucal*, vol. 18, no. 2, pp. e279–e284, 2013.
- [21] M. C. Garzon, J. T. Huang, O. Enjolras, and I. J. Frieden, “Vascular malformations: part I,” *Journal of the American Academy of Dermatology*, vol. 56, no. 3, pp. 353–370, 2007, quiz 371-374.
- [22] R. Modak, R. Modak, A. Mhapuskar, D. Hiremutt, and M. G. S. Hebbale, “Arteriovenous malformation of the oral cavity: a case report,” *Journal of Pharmaceutical and Biomedical Sciences*, vol. 6, no. 9, pp. 514–517, 2016.
- [23] D. Kademani, B. J. Costello, D. Ditty, and P. Quinn, “An alternative approach to maxillofacial arteriovenous malformations with transosseous direct puncture embolization,” *Oral Surgery, Oral Medicine, Oral Pathology, Oral Radiology, and Endodontology*, vol. 97, no. 6, pp. 701–706, 2004.
- [24] I. El-Hakim and A. Alyamani, “Management of palatal vascular malformation using absolute ethanol sclerotherapy,” *Clinics and Practice*, vol. 1, no. 4, pp. 182–184, 2011.
- [25] J. S. Lewin, E. M. Merkle, J. L. Duerk, and R. W. Tarr, “Low-flow vascular malformations in the head and neck: safety and feasibility of MR imaging-guided percutaneous sclerotherapy—preliminary experience with 14 procedures in three patients,” *Radiology*, vol. 211, no. 2, pp. 566–570, 1999.
- [26] Z. P. Li, “Therapeutic coagulation induced in cavernous hemangioma by use of percutaneous copper needles,” *Plastic and Reconstructive Surgery*, vol. 89, no. 4, pp. 613–622, 1992.
- [27] A. C. B. R. Johann, M. C. F. Aguiar, M. A. V. do Carmo, R. S. Gomez, W. H. Castro, and R. A. Mesquita, “Sclerotherapy of benign oral vascular lesion with ethanolamine oleate: an open clinical trial with 30 lesions,” *Oral Surgery, Oral Med Oral Pathol Oral Radiol Endodontology*, vol. 100, no. 5, pp. 579–584, 2005.
- [28] T. Yamaki, M. Nozaki, and K. Sasaki, “Color duplex-guided sclerotherapy for the treatment of venous malformations,” *Dermatologic Surgery*, vol. 26, no. 4, pp. 323–328, 2000.
- [29] B. A. Drolet, N. B. Esterly, and I. J. Frieden, “Hemangiomas in children,” *The New England Journal of Medicine*, vol. 341, no. 3, pp. 173–181, 1999.
- [30] L. Van Doorne, M. De Maeseneer, C. Stricker, R. Vanrensbergen, and M. Stricker, “Diagnosis and treatment of vascular lesions of the lip,” *The British Journal of Oral & Maxillofacial Surgery*, vol. 40, no. 6, pp. 497–503, 2002.
- [31] S. J. Fishman and J. B. Mulliken, “Hemangiomas and vascular malformations of infancy and childhood,” *Pediatric Clinics of North America*, vol. 40, no. 6, pp. 1177–1200, 1993.
- [32] J. L. Orlando, J. G. Mendes Pereira Caldas, H. G. do Amaral Campos, K. Nishinari, and N. Wolosker, “Ethanol sclerotherapy of superficial venous malformation: a new procedure,” *Dermatology*, vol. 220, no. 4, pp. 376–380, 2010.
- [33] Y. I. Eltohami and A. H. Abuaffan, “Venous malformation case report,” *Journal of Hospital & Medical Management*, vol. 2, no. 2, pp. 1–3, 2016.
- [34] S. Wiegand, B. Eivazi, A. P. Zimmermann, A. M. Sesterhenn, and J. A. Werner, “Sclerotherapy of lymphangiomas of the head and neck,” *Head & Neck*, vol. 33, no. 11, pp. 1649–1655, 2011.
- [35] C. L. Dietzek, “Sclerotherapy: introduction to solutions and techniques,” *Perspectives in Vascular Surgery and Endovascular Therapy*, vol. 19, no. 3, pp. 317–324, 2007.
- [36] O. N. Obuekwe, M. A. Ojo, O. Akpata, and B. D. Saheeb, “Haemangiomas of the maxillofacial region in Benin city, Nigeria,” *Annals of Biomedical Sciences*, vol. 1, no. 1, 2008.
- [37] C. Oji, F. Chukwunke, and N. Mgbor, “Tobacco-pouch suture technique for the treatment of vascular lesions of the lip in Enugu, Nigeria,” *British Journal of Oral and Maxillofacial Surgery*, vol. 44, no. 3, pp. 245–247, 2006.