

Coexistence of reticulate acropigmentation of Kitamura and Dowling-Degos disease

Ana Rita Cabral, Felicidade Santiago, José Pedro Reis

Department of Dermatology, Coimbra University Hospital, Coimbra, Portugal

Abstract

Reticulate acropigmentation of Kitamura (RAK) and Dowling-Degos Disease (DDD) are rare genodermatosis inherited as an autosomal dominant trait with variable penetrance. They are part of a spectrum of diseases with hyperpigmented macules coalescing in a reticular pattern, facial and palmoplantar pits, breaks in dermatoglyphics, comedo-like lesions and epidermoid cysts, and a unique histological picture of hyperpigmented digitate epidermal *downgrowths*. The authors describe the case of a 45-year-old female with reticulate acropigmentation of the dorsa of the hands and feet, hyperpigmented macules on the axilla and around the mouth, and palmar pitting. Clinical and histological findings, together with a relevant family history, allowed the authors to consider this case an example of the rare event of an overlap RAK-DDD.

Introduction

Reticulate acropigmentation of Kitamura (RAK) and Dowling-Degos Disease (DDD) are part of a spectrum of rare autosomal dominant genodermatosis, characterized by progressive, symmetric and asymptomatic reticulated pigmented macules affecting the dorsa of the hands, in the former, and the flexures, in the latter. Hyperpigmented lesions in RAK may also involve the flexor aspects of the wrists, neck, eyelids and periorbital areas. Other features include palmoplantar pits, breaks in the epidermal ridge pattern and occasionally, plantar keratoderma and alopecia. RAK's onset is usually in childhood unlike DDD, where the reticulate pigmentation has a late onset, in early adult life.¹

In addition, DDD also present comedo-like lesions and pitted acneiform scars in the face, without palmoplantar pitting. It is very often associated with epidermoid cysts, keratoacanthoma, squamous cells carcinoma, abscess, suppurative hidrosadenitis, seborrheic keratosis and pilonidalis cysts.²

Hypopigmented macules are absent in both diseases.

The histopathology of the hyperpigmented lesions is similar and characteristic in RAK and DDD, with the presence of digitated and filiform elongated rete ridges, with clumps of heavy melanin pigmentation at their tips, thinning of the epidermis and pseudo-cysts.^{3,4,5} This resembles the appearance of a solar lentigo, but with epidermal atrophy, melanin incontinence and perivascular lymphocytic infiltrate.² Accordingly to the similarity in clinical and histological features, many authors consider RAK and DDD different phenotypes of a single disorder.² In literature the authors found only few cases of overlap RAK-DDD (about a dozen), including family cases described until four generations.^{6,7}

Case Report

An otherwise healthy 45-year-old female presented since early childhood, with a progressive and asymptomatic reticulated acropigmentation with brown pigmented macules on the dorsa of the hands, forearms and feet (Figures 1, 2). Hyperpigmented macules, ephelide-like, on both axillae, buttocks and perioral area, also appeared in adulthood (Figure 3). The physical examination revealed as well palmar pits (Figure 4) but no facial pitted scars, breaks in dermatoglyphics, comedo-like papules or alterations in mucous membranes, hair, teeth and nails.

The patient reported similar lesions (mainly the reticulated acropigmentation) on two relatives (mother and aunt) apparently in an autosomal dominant pattern. He refused a genetic study proposed by the authors.

The skin biopsy of a pigmented macule of the back of the hand revealed elongated rete ridges, with increased pigmentation of the basal layer and an increment in the number of melanocytes, characteristic of RAK (Figure 5).

Based on the history, clinical and pathologic findings, the authors believe that this case is

Correspondence: Ana Rita Cabral, Department of Dermatology, Coimbra University Hospital, Praceta Mota Pinto, 3000-075 Coimbra, Portugal. Tel. +351.239.400.420 - Fax: +351.239.400.490. E-mail: ritaca@portugalmail.com

Key words: Reticulate acropigmentation of Kitamura (RAK), Dowling-Degos Disease (DDD), overlap.

Received for publication: 9 August 2011.
Accepted for publication: 10 August 2011.

This work is licensed under a Creative Commons Attribution NonCommercial 3.0 License (CC BY-NC 3.0).

©Copyright A.R. Cabral et al., 2011
Licensee PAGEPress, Italy
Dermatology Reports 2011; 3:e33
doi:10.4081/dr.2011.e33

one more example of the rare event of overlap RAK-DDD, among the few non-asian cases described in literature.

Discussion

Rebora and Crovato⁸ first suggested in 1983 that the two entities, RAK and DDD were different phenotypic expressions of the same genodermatosis. In similarity to the other RAK-DDD overlap cases described in the literature,^{9,10} our patient had typical characteristics of both variants. Concerning RAK, it was possible to perceive the reticulated hyperpigmentation with acral distribution and palmar pits and; in addition, the hyperpigmented lesions on the flexures were typical of DDD. The transmission was autosomal dominant, with other members of the family affected.

The true knowledge of the relationship between RAK and DDD will be possibly achieved, through the clarification of the genetic background of both diseases.

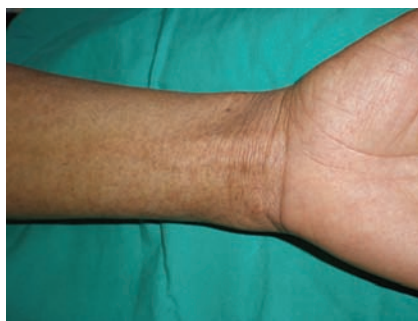

Figure 1. Hyperpigmented macules on the flexor aspect of the forearm.

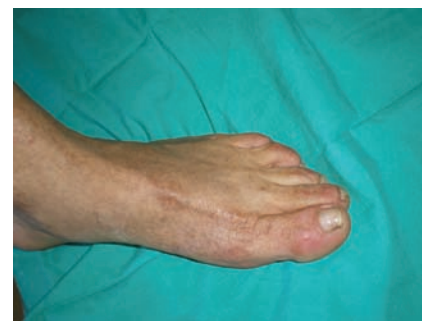

Figure 2. Hyperpigmented macules on the dorsa of the feet.

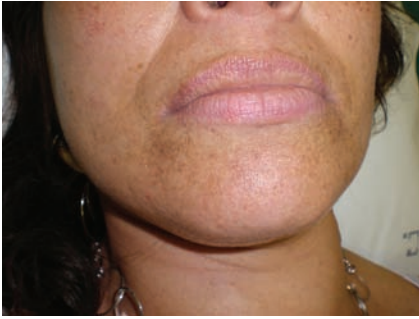

Figure 3. Hyperpigmented, ephelide-like macules around the mouth.

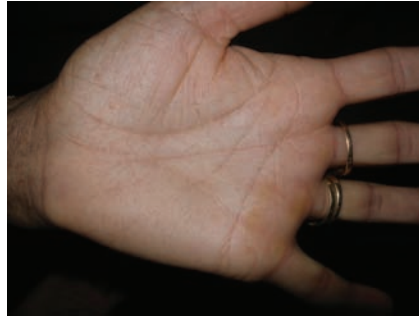

Figure 4. Palmar pits.

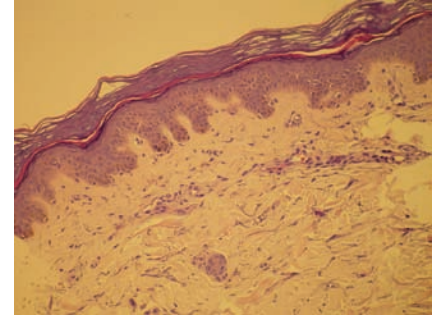


Figure 5. Histopathology of an hyperpigmented lesion of the dorso of the hand.

References

1. Gurer MA, Edali N. Reticulate acropigmentation of Kitamura: two case reports. *Int J Dermatol* 1993;32:726-7.
2. Hohmann CB, Koche B, Bonamigo RR, et al. Case for diagnosis. Dowling-Degos Disease. *An Bras Dermatol* 2010;85:241-3.
3. Kh. Al Aboud, Kh. Al Hawsawi. Reticulate acropigmentation of Kitamura. *Acta Dermatoven APA* 2003;12:151-2.
4. Hawsawi KA, Aboud KA, Alfadley A, Aboud DA. Reticulate acropigmentation of Kitamura-Dowling-Degos disease overlap: a case report. *Int J Dermatol* 2002;41:518-20.
5. Ostlere L, Holden CA. Dowling-Degos Disease associated with Reticulate acropigmentation of Kitamura. *Clin Exp Dermatol* 1994;19:492-5.
6. Thami GP, Jaswal R, Kanwar AJ, et al. Overlap of reticulate acropigmentation of Dohi and Dowling-Degos Disease in four generations. *Dermatology* 1998;196:350-31.
7. Lestringant GG, Masouyé I, Frossard PM, et al. Co-existence of leukoderma with features of Dowling-Degos Disease: Reticulate acropigmentation of Kitamura spectrum in five unrelated patients. *Dermatology* 1997;195:337-43.
8. Rebora A, Crovato F. The spectrum of Dowling-Degos disease. *Br J Dermatol* 1984;110:627-30.
9. Gontijo B, Pereira LB. O espectro doença de Kitamura-doença de Dowling-Degos. Revisão da literatura e apresentação de dois casos. *An Bras Dermatol* 1993;68:89-92.
10. Sharma R, Sharma SC, Radotra BD, Kaur S. Reticulate acropigmentation of Kitamura. *Clin Exp Dermatol* 1989;14:302-3.