



# Periprosthetic Insufficiency Fracture around Radiographically Loose Cemented Stem: A Report of Two Cases

Young Soo Chun, MD, Jung Suk Lee, MD, Yoon Je Cho, MD\*, Kee Hyung Rhyu, MD

*Department of Orthopaedic Surgery, Kyung Hee University Hospital at Gangdong, Seoul, Korea  
Department of Orthopaedic Surgery, Kyung Hee University Hospital, Seoul, Korea\**

As the osteoporotic patient population grows, various periprosthetic fractures that cannot be classified appropriately can occur around the femur after hip arthroplasty. We experienced two cases of periprosthetic insufficiency fractures at subtrochanteric area of the femurs around radiographically loose cemented femoral stems. The ages of the patients were 75 years and 83 years. Both patients could not recall any history of trauma before the onset of pain. Both were treated non-operatively. Both healed uneventfully and did not recur after two years of follow up. When the osteoporotic patient with cemented stem showed sudden hip or thigh pain without a history of trauma, great attention should be focused to find this lesion.

**Key Words:** Hip, Periprosthetic, Insufficiency fracture

Vancouver system has been successfully used to classify and treat a periprosthetic fracture of the femur after hip arthroplasty. However, there is a concern about the possibilities that insufficiency fracture around the implant can occur. This concern is growing because of increased number of elderly patients with osteoporosis who received hip arthroplasty<sup>1)</sup>.

To date, there have been a few reports about atypical

fractures at the distal part of femoral stem<sup>2-5)</sup>. However, report of periprosthetic insufficiency fracture in subtrochanteric area were not frequent. Recently, we observed two cases of insufficiency fractures at the lateral cortex of subtrochanteric area around the radiographically loose cemented femoral component.

## CASE REPORT

### 1. Patient 1

A 75-year-old woman underwent cemented total hip arthroplasty, and made regular follow up for 32 years without any clinical symptoms. Although the patient did not recall the exact date that she started medication, her family remembered that she has been taking oral bisphosphonate for at least 10 years. In May 2011, she presented with acute pain on her ipsilateral thigh. She did not recall any history of trauma except mild bump into the entrance bar at the subway. Radiograph taken at that time showed protruded lateral cortex of the

**Submitted:** May 21, 2015 **1st revision:** August 4, 2015

**Final acceptance:** August 11, 2015

**Address reprint request to**

**Kee Hyung Rhyu, MD**

Department of Orthopaedic Surgery, Kyung Hee University  
Hospital at Gangdong, 892 Dongnam-ro, Gangdong-gu, Seoul  
05278, Korea

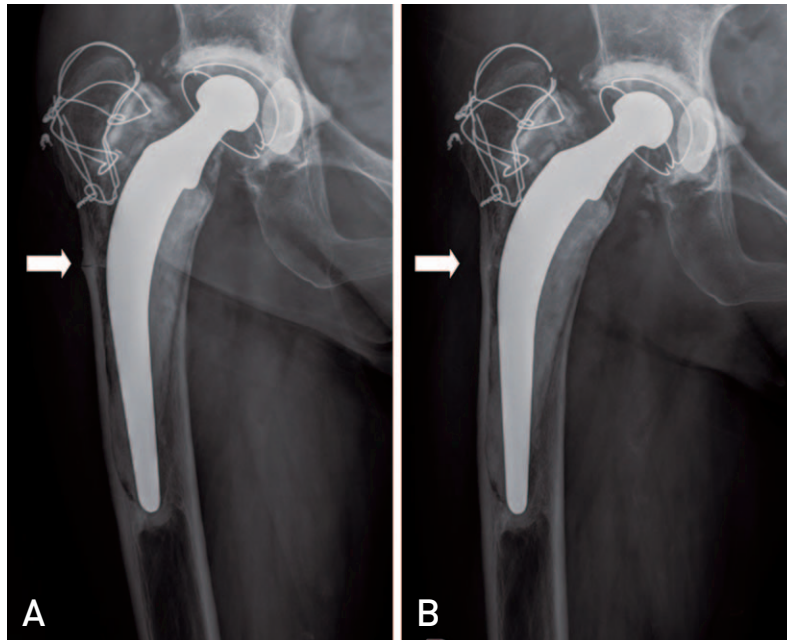
**TEL:** +82-2-440-6156 **FAX:** +82-2-440-7498

**E-mail:** khrhyu@gmail.com

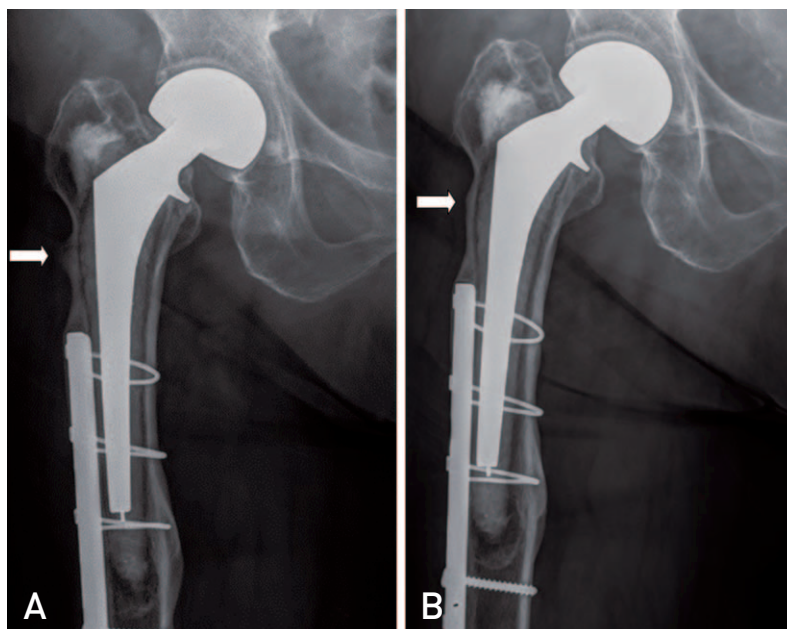
This is an Open Access article distributed under the terms of the Creative Commons Attribution Non-Commercial License (<http://creativecommons.org/licenses/by-nc/4.0>) which permits unrestricted non-commercial use, distribution, and reproduction in any medium, provided the original work is properly cited.

subtrochanteric area of the femur with short transverse uni-cortical fracture line (Fig. 1A). The patient was instructed to discontinue all medication containing bisphosphonate and to use protected weight bearing

using two crutches. Also, she was prescribed subcutaneous teriparatide (Forteo; Lilly, Indianapolis, IN, USA) injection for four months, until she did not complain hip pain. Eight months after the onset of initial pain, she



**Fig. 1.** (A) Anteroposterior radiograph of right hip of patient 1 shows a thickened lateral cortex with a transverse uni-cortical fracture (arrow) at the subtrochanteric region. (B) The radiograph taken 8 months after the index symptom shows complete healing of previous fracture (arrow).



**Fig. 2.** (A) Anteroposterior radiograph of right hip of patient 2 shows marked thickening at lateral cortex with a transverse incomplete fracture (arrow) at the subtrochanteric region. (B) The radiograph taken 12 months after the index symptom shows complete healing of previous fracture (arrow).

could bear weight without assistance and reported no pain in her right hip. Radiographs taken at that time showed evidence of a healed fracture (Fig. 1B).

## 2. Patient 2

A 85-year-old woman who has history of taking oral bisphosphonate for more than 5 years underwent cemented bipolar endoprosthesis in 1998. Her initial diagnosis leading to operation was intertrochanteric fracture of right femur. She experienced Vancouver type C periprosthetic fracture at the ipsilateral femur in 2007. It was treated with open reduction and internal fixation. Since that time, the patient has been treated with 35 mg risedronate weekly for another 4 years. Forty one months after the union of periprosthetic fracture, she complained sharp pain on right hip during weight-bearing. She did not recall any history of trauma. The radiographs showed protruded lateral cortex with transverse, uni-cortical fracture line at subtrochanteric area around the radiographically loose cemented stem (Fig. 2A). Bone scan showed new increased focal uptake at the right subtrochanteric region of the femur. The patient was instructed to discontinue risedronate and to use two crutches with non-weight bearing. She was prescribed daily subcutaneous teriparatide injection for four months. Seven month after the initial treatment, her pain was markedly improved. Radiographs showed evidence of a healed fracture. One year after the onset of pain, her pain had resolved and the fracture was consolidated on the radiographs (Fig. 2B). She was allowed to bear weight as tolerated and had returned to her previous household ambulatory activity level.

## DISCUSSION

There is a concern about the possibilities that periprosthetic insufficiency fractures can occur due to recently increased number of elderly patients with osteoporosis<sup>1)</sup>. The occurrence of atypical femoral fractures in patients receiving long-term bisphosphonates therapy was well described in many reports<sup>5-8)</sup>. But regarding a periprosthetic fracture, there have been only a few reports that the fractures occur at distal part of a stable cementless stem. However, in contrast with those reports, our cases showed subtrochanteric fracture around the radiographically loose cemented stems with otherwise pain-free hip. In this regards, we believe that

the clinical pattern of these fractures could not be easily classified as atypical or stress fractures. Because the fractures were found at the same area in elderly patients with almost identical clinical situation without any history of trauma and they were definitely different from commonly reported atypical fractures, we considered them as peri-prosthetic insufficiency fractures. Although a number of classification systems in periprosthetic fracture have been proposed in the past, the presence of these fractures and other reports with distal atypical fractures can challenge the current classification of periprosthetic femoral fractures.

Most atypical fractures were reported as having poor results with only conservative treatment. Withdrawing bisphosphonates therapy should be considered if investigations show early signs of such a fracture<sup>6-12)</sup>. Potent anabolic agent such as teriparatide may be an option in symptomatic patients before complete fracture<sup>13,14)</sup>. In our cases, both cases were treated non-surgically with teriparatide injection, protected weight-bearing, and discontinued bisphosphonates. The authors did not assure whether teriparatide critically accelerated healing of these fractures or not. However, both patients successfully escaped surgery with the same protocol, suggesting that the teriparatide might play a clinical role. After two years of follow up, fractures did not recur.

Because there are many elderly patient with osteoporosis who are undergoing hip replacement, surgeons should consider the possibility of periprosthetic insufficiency fractures when the osteoporotic patient with cemented stem showed sudden hip or thigh pain without a history of trauma. Although we are not convinced that our protocol is the only method to deal with this type of fracture, we believe that it can be treated non-operatively if it is not displaced.

## REFERENCES

1. Duncan CP, Masri BA. *Fractures of the femur after hip replacement. Instr Course Lect.* 1995;44:293-304.
2. Black DM, Cummings SR, Karpf DB, et al. *Randomised trial of effect of alendronate on risk of fracture in women with existing vertebral fractures. Fracture Intervention Trial Research Group. Lancet.* 1996;348:1535-41.
3. Cross MB, Nam D, van der Meulen MC, Bostrom MP. *A rare case of a bisphosphonate-induced peri-prosthetic femoral fracture. J Bone Joint Surg Br.* 2012;94:994-7.
4. Curtin BM, Fehring TK. *Bisphosphonate fractures as a cause of painful total hip arthroplasty. Orthopedics.* 2011;

- 34:e939-44.
5. Capeci CM, Tejwani NC. *Bilateral low-energy simultaneous or sequential femoral fractures in patients on long-term alendronate therapy.* *J Bone Joint Surg Am.* 2009;91:2556-61.
  6. Kwek EB, Goh SK, Koh JS, Png MA, Howe TS. *An emerging pattern of subtrochanteric stress fractures: a long-term complication of alendronate therapy?* *Injury.* 2008;39:224-31.
  7. Neviasser AS, Lane JM, Lenart BA, Edobor-Osula F, Lorch DG. *Low-energy femoral shaft fractures associated with alendronate use.* *J Orthop Trauma.* 2008;22:346-50.
  8. Odvina CV, Zerwekh JE, Rao DS, Maalouf N, Gottschalk FA, Pak CY. *Severely suppressed bone turnover: a potential complication of alendronate therapy.* *J Clin Endocrinol Metab.* 2005;90:1294-301.
  9. Goh SK, Yang KY, Koh JS, et al. *Subtrochanteric insufficiency fractures in patients on alendronate therapy: a caution.* *J Bone Joint Surg Br.* 2007;89:349-53.
  10. Ha YC, Cho MR, Park KH, Kim SY, Koo KH. *Is surgery necessary for femoral insufficiency fractures after long-term bisphosphonate therapy?* *Clin Orthop Relat Res.* 2010;468:3393-8.
  11. Koh JS, Goh SK, Png MA, Kwek EB, Howe TS. *Femoral cortical stress lesions in long-term bisphosphonate therapy: a herald of impending fracture?* *J Orthop Trauma.* 2010;24:75-81.
  12. Lenart BA, Neviasser AS, Lyman S, et al. *Association of low-energy femoral fractures with prolonged bisphosphonate use: a case control study.* *Osteoporos Int.* 2009;20:1353-62.
  13. Finkelstein JS, Hayes A, Hunzelman JL, Wyland JJ, Lee H, Neer RM. *The effects of parathyroid hormone, alendronate, or both in men with osteoporosis.* *N Engl J Med.* 2003;349:1216-26.
  14. Neer RM, Arnaud CD, Zanchetta JR, et al. *Effect of parathyroid hormone (1-34) on fractures and bone mineral density in postmenopausal women with osteoporosis.* *N Engl J Med.* 2001;344:1434-41.