

Cricothyroidotomy needle length is associated with posterior tracheal wall injury

A randomized crossover simulation study (CONSORT)

Atsuko Katayama, MD^a, Kunitaro Watanabe, MD, PhD^a, Joho Tokumine, MD, PhD^{a,*}, Alan Kawai Lefor, MD MPH, PhD^b, Harumasa Nakazawa, MD, PhD^a, Ippei Jimbo, MD^a, Tomoko Yorozu, MD, PhD^a

Abstract

Background: Cricothyroidotomy is the final strategy in the “cannot intubate, cannot oxygenate” scenario, but half of needle cricothyroidotomy attempts result in failure. The most frequent complication in needle cricothyroidotomy is posterior tracheal wall injury. We hypothesized that needle length is related to posterior wall injury and compared needle cricothyroidotomy with a commercial kit to a modified shorter needle to evaluate success and posterior wall injury rates.

Methods: The commercial kit has a needle stopper to prevent posterior wall injury, with a penetrating length of 25 mm. We made long stopper to shorten the length by 5 mm (net 20 mm penetrating length). Residents were recruited, received a lecture about cricothyroidotomy and practiced needle cricothyroidotomy using the commercial kit on a simulator. They then performed cricothyroidotomy using the commercial kit or the shorter needle on an *ex-vivo* porcine larynx covered with artificial skin. An intra-tracheal endoscope recorded the procedure. The video was evaluated for success/failure or posterior wall injury by independent evaluators. Larynxes with a distance from the outer surface to the inner lumen exceeding 13 mm were excluded. The distance in each larynx was measured by dissection after the study. Success and posterior wall injury rates were analyzed using Fisher exact test ($P < .05$ was statistically significant).

Results: Forty-seven residents participated in the study. Data for two residents were excluded. There was no statistically significant difference in success rate between the commercial kit (100%, 45/45) and the shorter needle (91%, 41/45, $P = .12$). Failure was defined if the needle tip did not reach the lumen in four trials. Cannulated but complicated by posterior wall injury occurred in 33% (15/45) with the commercial kit and 5% (2/43) with the shorter needle ($P < .01$).

Conclusion: During needle cricothyroidotomy, force is needed for the needle to penetrate the cricothyroid ligament. The advancing needle sometimes cannot be stopped after penetrating the cricothyroid ligament. These data suggest that needle length is associated with posterior wall injury.

Abbreviations: 3D = three-dimensional, BMI = body mass index, PWI = posterior tracheal wall injury.

Keywords: needle cricothyroidotomy, posterior tracheal wall injury, QuickTrach, simulation study

Editor: Chien-Kun Ting.

The authors have no conflicts of interest to disclose.

^a Department of Anesthesiology, Kyorin University School of Medicine, Sinkawa, Mitaka, Tokyo, ^b Department of Surgery, Jichi Medical University, Tochigi-ken, Japan.

* Correspondence: Joho Tokumine, Department of Anesthesiology, Kyorin University School of Medicine, Sinkawa, Mitaka, Tokyo 181-8611, Japan (e-mail: ii36469@wa2.so-net.ne.jp).

Copyright © 2020 the Author(s). Published by Wolters Kluwer Health, Inc. This is an open access article distributed under the terms of the Creative Commons Attribution-Non Commercial License 4.0 (CCBY-NC), where it is permissible to download, share, remix, transform, and build up the work provided it is properly cited. The work cannot be used commercially without permission from the journal.

How to cite this article: Katayama A, Watanabe K, Tokumine J, Lefor AK, Nakazawa H, Jimbo I, Yorozu T. Cricothyroidotomy needle length is associated with posterior tracheal wall injury: A randomized crossover simulation study (CONSORT). *Medicine* 2020;99:9(e19331).

Received: 20 August 2019 / Received in final form: 20 January 2020 / Accepted: 23 January 2020

<http://dx.doi.org/10.1097/MD.00000000000019331>

1. Introduction

Difficult airway management guidelines recommend cricothyroidotomy as the final strategy in the “cannot intubate, cannot oxygenate” situation.^[1,2] However, the fourth National Audit Project on major airway complications reported that half of needle cricothyroidotomy attempts result in failure.^[3] Complications of needle cricothyroidotomy include securing a false airway, bleeding, and posterior tracheal wall penetration, which can lead to esophageal injury, mediastinal bleeding, and pneumothorax.^[3] A previous simulation study showed that posterior tracheal wall injury (PWI) occurs frequently during needle cricothyroidotomy.^[4] Simulation training did not decrease the incidence of PWI, despite operators being made especially aware of PWI. During the study it was noticed that operators could not stop the needle just after penetrating the cricothyroid membrane.

We hypothesized that the length of the needle has a direct effect on the rate of PWI and constructed a shorter needle, considering the minimum needle length needed to perform cricothyroidotomy.

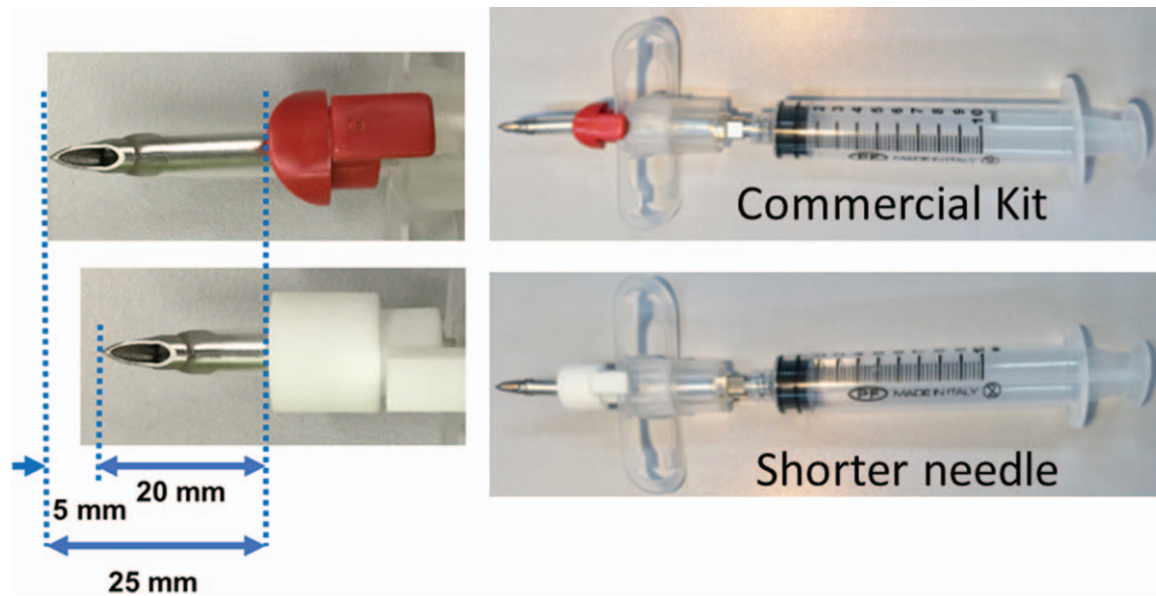


Figure 1. Commercial cricothyroidotomy kit and the shorter needle QuickTrach ITM: (upper image) The original stopper (red) is equipped to prevent posterior tracheal wall injury, with an effective penetrating needle length of 25 mm. Shorter needle: (lower image) The long stopper (white) was made with a 3D printer, 5 mm longer than the original. The long stopper was designed with three-dimensional design software “Microsoft 3D Builder” (Microsoft Co, Washington, USA) and was ordered from a company (DMM.com Co. Ltd, Tokyo, Japan). The effective penetrating needle length is 20 mm.

Needle cricothyroidotomy using the needle in a commercially available kit was compared to using the modified shorter needle to evaluate the rates of success and PWI.

2. Methods

This simulation study was designed as a randomized cross-over trial. This study was approved by the Ethics Committee of Kyorin University (no.1095 and no. 1218) and registered in University Hospital Medical Information Network – Clinical Trials Registry, (R000037843).

2.1. Constructing a shorter needle for cricothyroidotomy

QuickTrach ITM (Smiths Medical Japan Ltd., Tokyo, Japan), a commercially available cricothyroidotomy kit was used and a shorter needle constructed by modifying the needle from the QuickTrach ITM. The QuickTrach ITM kit has a needle stopper to prevent PWI which sets the needle penetration depth, from the needle tip to the stopper, at 25 mm (Fig. 1).

To determine the length of the needle needed to penetrate the cricothyroid membrane, data of the depth from the skin surface to the inner tracheal lumen at the level of the cricothyroid membrane was collected from patient imaging data (imaging data of one-hundred patients over 20 years of age undergoing general anesthesia from April 1, 2016 to March 31, 2018 was analyzed). The depth of the cricothyroid membrane in patients with a BMI < 25 was 10.4 [8.5–13.8] mm. Considering the depth of the cricothyroid membrane at the 75th percentile and depth of the cricothyroid membrane in non-obese patients, we chose a depth of 15 mm for this simulation study. The usual thickness of the cricothyroid membrane of an ex-vivo porcine larynx was from 8 to 12 mm (unpublished data, preliminary measurement of 10 ex-vivo larynxes). A 3 mm thick piece of artificial skin (BioSKIN, Regina Fashion Supply Co. Ltd., Saitama, Japan) was used to

cover the larynx for a total depth of 11 to 15 mm as a wet cricothyroidotomy simulator. Based on previous data, the distance to the lumen at the cricothyroid membrane should be 15 mm or less considering the thickness of the ex-vivo porcine larynx (≤ 12 mm) and the 3 mm piece of artificial skin.

The length from the tip of the inner metal needle to the outer cannula was 5 mm. Since a needle length of 20 mm was desired, we made a 5 mm longer stopper using a 3D printer to increase the penetrating length to 20 mm (Fig. 1).

2.2. Success and PWI rates for cricothyroidotomy using the commercial kit or the shorter needle

Residents (enrolled in year one or two of a mandatory two-year rotating general residency which commences immediately after graduation from medical school) volunteered to participate in this study and written informed consent was obtained from all participants. All participants had no prior clinical experience with cricothyroidotomy. Participants were given a lecture to review the relevant anatomy and details of performing a needle cricothyroidotomy, and practiced needle cricothyroidotomy using the commercial kit^[5,6] on a cricothyroidotomy simulator Cricoid Stick TrainerTM (Laerdal Medical Japan Ltd, Tokyo, Japan, Fig. 2) 10 times and then using an ex-vivo porcine larynx (Fig. 3). Cricothyroidotomy was performed once only using the ex-vivo porcine larynx as final practice before participating in the study. A luminal view of the needle tip was shown to participants to emphasize the need for caution to avoid PWI.

After the practice session, the shorter needle was introduced to the participants. After examining the shorter needle, participants performed needle cricothyroidotomy on an ex-vivo porcine larynx with the commercial kit or the shorter needle. The porcine larynx was placed and stabilized in a box and covered with artificial skin (Fig. 3). To evaluate the presence of a PWI, an endoscope was inserted into the trachea, and the luminal view

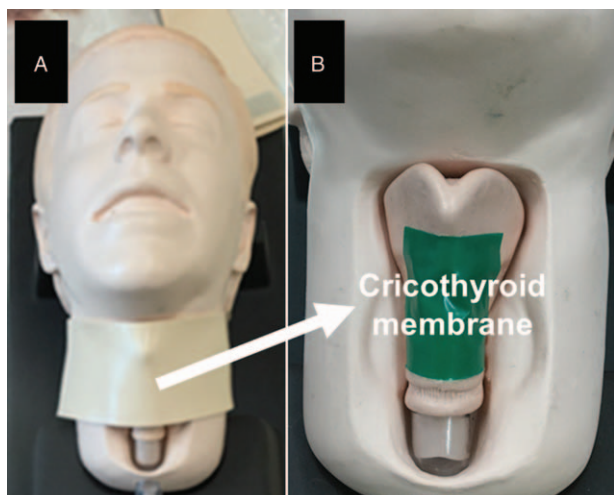


Figure 2. Dry simulator for training. Panel A: The Cricoid Stick Trainer™. Panel B: The cricothyroid membrane is covered with commercial plastic tape (Laerdal Medical Japan Ltd).

recorded.^[4] The video was recorded with sequential numbers, and two non-participating investigators observed and evaluated the success rate and presence or absence of a PWI. A new porcine larynx was used for each participant, and the order of using the commercial kit or the shorter needle first was randomized using a random number table. A new QuickTrach I™ was used for 4 trials. The same long stopper made with a 3D printer was used throughout the study. Success was defined as cannulation performed by the end of procedure without considering complications. Complications were considered to have occurred if the needle penetrated unintended tissues or organs. PWI was considered as a complication.

After the trial, the porcine larynxes were dissected to measure the distance from the anterior surface (there is no skin) to the tracheal lumen at the level of the cricothyroid membrane. Data

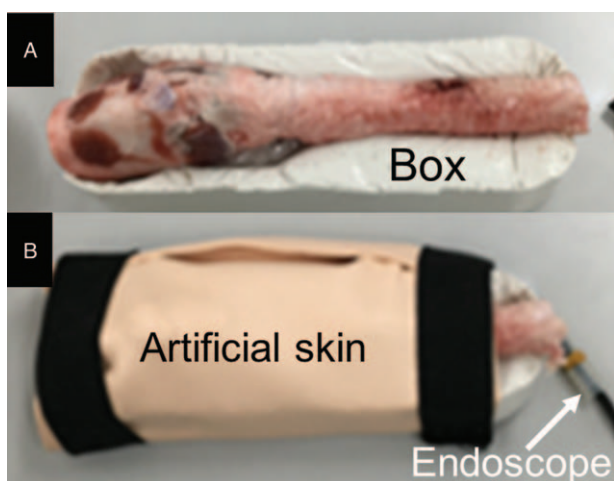


Figure 3. Porcine larynx and endoscopic observation. Panel A: The ex-vivo porcine larynx is fixed in a box. Panel B: The larynx and box are covered with artificial skin. An endoscope is inserted into the tracheal lumen to observe during cricothyroidotomy, and the internal view recorded.

obtained using a larynx of 13 mm or more was excluded due to exceeding the pre-determined depth of 15 mm.

2.3. Sample size and statistical analysis

As a preliminary study, 8 anesthesiologists performed needle cricothyroidotomy using the shorter needle in a porcine larynx covered with artificial skin. Cannulations were successful in all attempts, but one PWI occurred. In a previous study, the PWI rate using a commercial cricothyroidotomy kit and an ex-vivo porcine larynx was 35%.^[4] Based on these data, we predicted the PWI rate would be about 10% using the shorter needle. The sample size required for 80% power at $\alpha = 0.05$ was estimated to be 43 participants. In this study, we recruited 47 participants to account for dropouts and exclusions.

The success rate for cricothyroidotomy, complication rate, and PWI rate were analyzed using Fisher exact test calculated with R software (version 3.4.4., open-source software).

3. Results

Forty-seven residents participated in the study (Fig. 4). All residents asked were willing to participate and there were no dropouts. Data for 2 participants were excluded due to excessive thickness of the cricothyroid membrane. The success rate for cricothyroidotomy using the commercial kit was 100%, but using the shorter needle was 91% (Table 1), with no statistically significant difference ($P = .12$). Four trials using the shorter needle failed, caused by failure to penetrate the cricothyroid membrane (Fig. 5). The inner mucosa of the trachea remained unpenetrated. There was a statistically significant difference in the rate of PWI between the commercial kit (33%) and the shorter needle (4%) ($P < .01$).

4. Discussion

This study showed that the standard needle in a commercial needle cricothyroidotomy kit frequently caused PWI, due to the length of the needle. Previous studies revealed that strong insertion force caused a PWI. This study adds further information of the mechanism of a PWI, and to prevent it we should a needle of appropriate length. Ultrasound-guided identification of the cricothyroid membrane may assist in this procedure, since the distance from the skin to the tracheal lumen can be readily measured. The availability of needles of various lengths would allow selection of an appropriate needle, sufficient to penetrate the cricothyroid membrane without a PWI. This study suggests that needles of various lengths should be available.

All trainees and practicing clinicians in anesthesia, surgery and emergency medicine need training in anterior neck airway access.^[7] Anesthesiologists, as airway management experts, must be proficient in performing cricothyroidotomy, but this procedure is unfamiliar to many anesthesiologists because it is not routinely performed.^[8] A surgical cricothyroidotomy is performed by incising the cricothyroid membrane using a scalpel, and has been considered the standard technique, rather than needle cricothyroidotomy.^[1,9,10] However, the surgical cricothyroidotomy can be accompanied by bleeding due to the vasculature in the cricothyroid membrane area.^[11,12] A recent meta-analysis did not show superiority of a surgical cricothyroidotomy over a needle cricothyroidotomy, with regard to success rate or procedure time.^[13,14] Needle cricothyroidotomy

CONSORT 2010 Flow Diagram

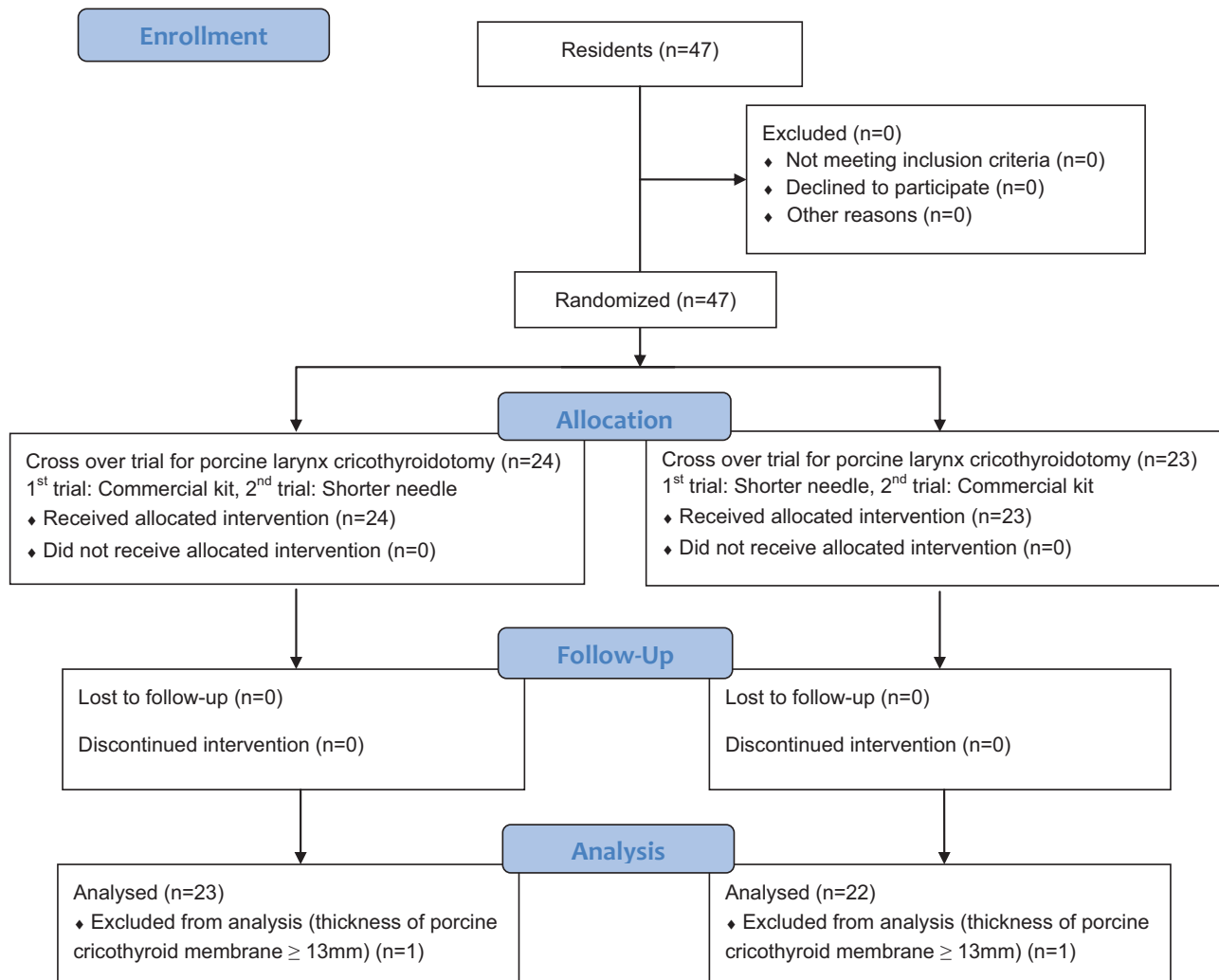


Figure 4. CONSORT 2010 flow diagram.

with a narrow bore cannula and jet ventilation are in clinical use, with a reported low failure rate and more rapid access compared to a surgical cricothyroidotomy in a simulation study.^[15] While some have concluded that surgical cricothyroidotomy is the preferred technique, the importance of facility with needle

cricothyroidotomy has also been stated^[16] Further study is needed to clarify the utility of needle cricothyroidotomy.

PWI may cause esophageal injury, mediastinal bleeding, and pneumothorax and these complications may be lethal.^[3] Needle cricothyroidotomy with a narrow bore cannula using the Seldinger technique was reported to be less traumatic than using a wide bore cannula in a simulation study.^[17] It was reported that the greater force needed to insert the needle caused PWI and that using a small pilot needle to insert the guidewire reduced the incidence of PWI.^[18] Excessive force may deform the tracheal cavity thus decreasing the anteroposterior diameter which can lead to PWI. In the present study, we show that using a shorter needle instead of the long needle supplied in the commercial kit reduces the rate of PWI.

The stopper in the QuickTrach I™ kit is provided to prevent PWI. The instruction manual supplied with the QuickTrach I™ explains that the stopper is not provided to prevent PWI when puncturing the cricothyroid membrane, but is to be used when placing the needle with a cannula into the tracheal lumen.^[5,6]

Table 1
Success rate and posterior tracheal wall injury rate in the commercial kit or shorter needle.

	Commercial kit, 25 mm needle, (n = 45)	Shorter needle, 20 mm needle, (n = 45)	P value
Success rate % (n)	100% (45)	91% (41)	.12
Failure to penetrate the cricothyroid membrane % (n)	0% (0)	9% (4)	.12
Posterior tracheal wall injuries % (n)	33% (15)	4% (2)	< .01

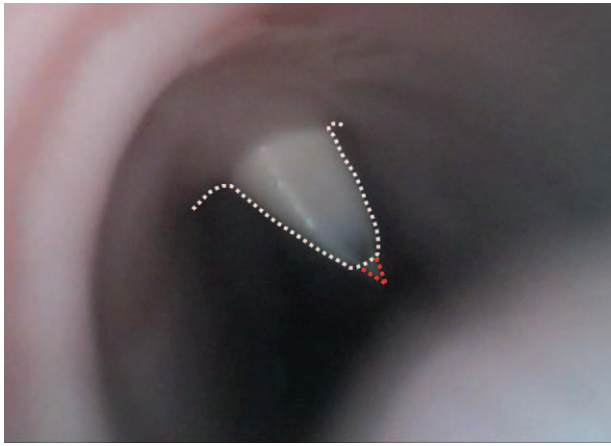


Figure 5. Failure to penetrate the cricothyroid membrane. This representative image shows no penetration of the cricothyroid membrane by the needle. The white dotted line shows the needle protruding into the lumen (tenting), but the needle is still beneath the tracheal mucosa. The red triangle indicates the needle tip, which is just penetrating the tracheal mucosa, but the bevel of the needle tip has not yet reached the lumen. Aspiration to determine the position of the cannula cannot be performed at this time.

Intra-tracheal views using an endoscope suggested that most PWI occur while puncturing the cricothyroid membrane (Fig. 6). This is the reason that the shorter needle limits the incidence of PWI. However, there is a limitation to the experimental model because an ex-vivo porcine larynx may have a different elasticity compared to the human larynx.

The inner diameter of human tracheas (collected from imaging data of one-hundred patients over 20 years of age undergoing general anesthesia from April 1, 2016 to March 31, 2018 was analyzed) was a mean of 22.2 ± 2.3 mm in males and 18.5 ± 3.3 mm in females. The mean inner diameter of porcine tracheas was 18.4 ± 2.2 mm, similar to a human female, but smaller than a human male. The absolute result of this study may be extrapolated to human females, but not necessarily to human males. This factor may partially account for the difference between the rate of posterior tracheal wall injuries in this study and previous clinical reports. Despite this, in the porcine model, there were fewer posterior wall injuries with the shorter needle, suggesting that needle length is one contributing factor.

These data may not be directly related to the clinical practice but this study does suggest one plausible explanation for PWI. A study reported that needle cricothyroidotomy by less experienced operators using the QuickTrach ITM on 55 fresh cadavers resulted in a 13% rate of PWI (2 posterior wall injuries and 5 esophageal perforations).^[6] The investigators reported that 24/55 attempts (44%) were performed with a pre-procedure skin incision because of difficulty of skin penetration by the needle.^[6] Therefore, we would expect a higher rate of PWI if it is performed without a preoperative skin incision. We estimated that the PWI rate of needle cricothyroidotomy using the QuickTrach ITM in patients may reach 30% based on a cadaver study. There may be other factors leading to PWI including extent of tissue damage from a simple puncture of the posterior tracheal wall leading to esophageal penetration.

In the present study, 4 trials failed due to inability to penetrate the cricothyroid membrane (Table 1, Fig. 6). Statistically, there was no significant difference in success rate comparing the

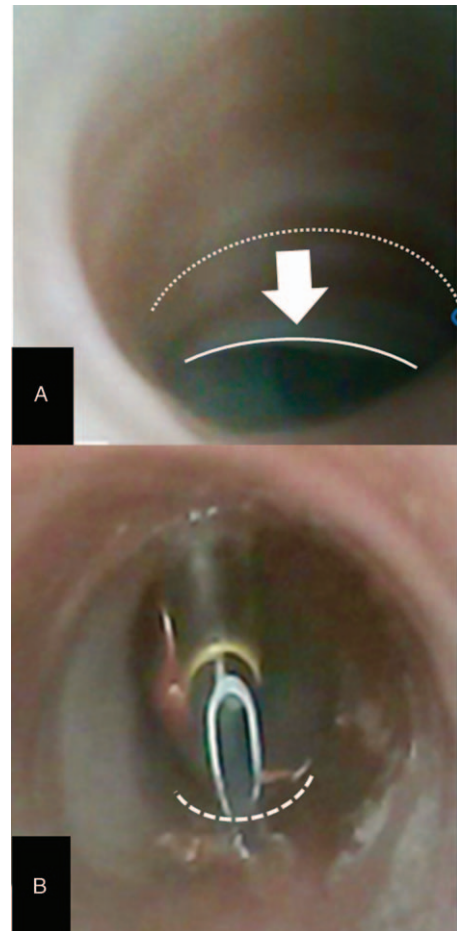


Figure 6. Mechanism of posterior tracheal wall injury. Application of force on the needle results in displacement of the anterior wall toward the posterior wall. If the needle penetrates the anterior wall, continued force before the operator is aware of the penetration results in the needle tip moving toward the posterior wall. Panel A: The anterior tracheal wall is displaced posteriorly by the force on the needle. The white dotted line indicates the anterior tracheal wall without displacement by the needle. The solid white line shows the displaced anterior tracheal wall. Panel B: The needle penetrates the posterior wall. The white dashed line shows the posterior tracheal wall. The needle tip is into the posterior wall.

commercial kit and the shorter needle. The appropriate needle length in the failed trials without penetrating the cricothyroid membrane may need to be longer than 20 mm. In 1 study, the depth of the cricothyroid membrane was associated with BMI. It was reported that the depth of the cricothyroid membrane is closely related to BMI in obese patients.^[19] In that report, depth of the cricothyroid membrane in obese patients was from 12 mm to 18 mm. The needle in the QuickTrach ITM is long enough to perform needle cricothyroidotomy in obese patients. This study did not assess success rates with a deeper than normal cricothyroid membrane as might be found in an obese patient and/or a patient with an anatomically abnormal neck. Particularly in these types of patients, needle cricothyroidotomy may have higher failure rates, which is likely to be higher with the use of a shorter needle. This study concludes that one should use an appropriate length needle, not just a shorter needle. It is expected that the use of ultrasound for difficult airway management may guide the selection of a needle of appropriate length.

During needle cricothyroidotomy, force is applied for the needle to penetrate the cricothyroid ligament. The advancing needle sometimes cannot be stopped after penetrating the cricothyroid ligament. This study suggests that using an appropriate length needle for a cricothyroidotomy may limit the incidence of a PWI. However, currently available kits include just one size needle. Point-of-care ultrasound to identify the cricothyroid membrane and measuring the distance from the skin to the tracheal lumen may help reduce the incidence of PWI in the future.

Acknowledgments

We would like to express our gratitude to the residents who participated in the study.

Author contributions

Conceptualization: Atsuko Katayama, Kunitaro Watanabe, Joho Tokumine.

Data curation: Tomoko Yorozu.

Formal analysis: Joho Tokumine, Ippei Jimbo.

Investigation: Atsuko Katayama, Harumasa Nakazawa.

Methodology: Atsuko Katayama, Kunitaro Watanabe.

Project administration: Joho Tokumine.

Software: Atsuko Katayama, Kunitaro Watanabe.

Supervision: Tomoko Yorozu.

Validation: Atsuko Katayama, Kunitaro Watanabe, Ippei Jimbo.

Writing – review & editing: Joho Tokumine, Alan Kawarai Lefor. Joho Tokumine orcid: 0000-0003-3481-2085.

References

- [1] Apfelbaum JL, Hagberg CA, Caplan RA, et al. Practice guidelines for management of the difficult airway: an updated report by the American Society of Anesthesiologists Task Force on Management of the Difficult Airway. *Anesthesiology* 2013;118:251–70.
- [2] Frerk C, Mitchell VS, McNarry AF, et al. Difficult Airway Society intubation guidelines working group: Difficult Airway Society 2015 guidelines for management of unanticipated difficult intubation in adults. *Br J Anaesth* 2015;115:827–48.
- [3] Cook TM, Woodall N, Harper J, et al. Fourth National Audit Project. Major complications of airway management in the UK: results of the Fourth National Audit Project of the Royal College of Anaesthetists and the Difficult Airway Society. Part 2: intensive care and emergency departments. *Br J Anaesth* 2011;5:632–42.
- [4] Katayama A, Nakazawa H, Tokumine J, et al. A high-fidelity simulator for needle cricothyroidotomy training is not associated with increased proficiency compared with conventional simulators: A randomized controlled study. *Medicine (Baltimore)* 2019;98:e14665.
- [5] VBM Cricothyrotomy, Instruction manual of percutaneous cricothyrotomy, Medizintechnik GmbH, Germany. Available at: http://ftp.vbm-medical.de/Mediathek/Literatur/FLY009/FLY009_EN.pdf. Accessed August 20, 2019.
- [6] Frei FJ, Meier PY, Lang FJ, et al. Cricothyrotomy using the Quicktrach coniotomy instrument set. *Anasth Intensivther Notfallmed* 1990;25 (Suppl 1):44–9.
- [7] Aho JM, Thiels CA, AlJamal YN, et al. Every surgical resident should know how to perform a cricothyrotomy: an inexpensive cricothyrotomy task trainer for teaching and assessing surgical trainees. *J Surg Educ* 2015;72:658–61.
- [8] Wong DT, Mehta A, Tam AD, et al. A survey of Canadian anesthesiologists' preferences in difficult intubation and "cannot intubate, cannot ventilate" situations. *Can J Anaesth* 2014;61:717–26.
- [9] Kanji H, Thirsk W, Dong S, et al. Emergency cricothyroidotomy: a randomized crossover trial comparing percutaneous techniques: classic needle first versus "incision first". *Acad Emerg Med* 2012;19:E1061–7.
- [10] Asai T. Surgical cricothyrotomy, rather than percutaneous cricothyrotomy, in "cannot intubate, cannot oxygenate" situation. *Anesthesiology* 2016;2:269–71.
- [11] Little CM, Parker MG, Tarnopolsky R. The incidence of vasculature at risk during cricothyroidotomy. *Ann Emerg Med* 1986;15:805–7.
- [12] Dover K, Howdieshell TR, Colborn GL. The dimensions and vascular anatomy of the cricothyroid membrane: relevance to emergent surgical airway access. *Clin Anat* 1996;9:291–5.
- [13] Langvad S, Hyldmo PK, Nakstad AR, et al. Emergency cricothyrotomy—a systematic review. *Scand J Trauma Resusc Emerg Med.* 2013;21:43. Available at: <http://www.sjtem.com/content/21/1/43>. Accessed August 20, 2019.
- [14] Hubble MW, Wilfong DA, Brown LH, et al. A meta-analysis of prehospital airway control techniques part II: alternative airway devices and cricothyrotomy success rates. *Prehosp Emerg Care* 2010;14:515–30.
- [15] Rees KA, O'Halloran LJ, Wawryk JB, et al. Time to oxygenation for cannula- and scalpel-based techniques for emergency front-of-neck access: a wet lab simulation using an ovine model. *Anaesthesia* 2019;74:1153–7.
- [16] Marshall SD. Evidence is important: safety considerations for emergency catheter cricothyroidotomy. *Acad Emerg Med* 2016;23:1074–6.
- [17] King W, Teare J, Vandrevalla T, et al. Evaluation of a novel Surgicric[®] cricothyroidotomy device for emergency tracheal access in a porcine model. *Anaesthesia* 2016;71:177–84.
- [18] Abbrecht PH, Kyle RR, Reams WH, et al. Insertion forces and risk of complications during cricothyroid cannulation. *J Emerg Med* 1992;10: 417–26.
- [19] Gadd K, Wills K, Harle R, et al. Relationship between severe obesity and depth to the cricothyroid membrane in third-trimester non-labouring parturients: a prospective observational study. *Br J Anaesth* 2018;120: 1033–9.