

## Vestibular Incision Subperiosteal Tunnel Access with Titanium-Prepared Platelet-Rich Fibrin – A Golden Approach for Treating Multiple Recession Defects in Esthetic Zone

### Abstract

Gingival recession is defined as apical migration of marginal gingival tissue causing the exposure of root surface. Abnormal brushing techniques, trauma, anatomical presence of tooth, caries, and improper oral hygiene measures are some of the problems leading to gingival recession. Several treatment modalities such as coronary advanced flaps and free gingival grafts have been used for the treatment of gingival recession defects and showed good results. However, while treating multiple gingival recessions, some new treatment modalities were introduced in literature. Vestibular incision subperiosteal tunnel access (VISTA) as a minimally invasive technique for root coverage was introduced with various advantages such as no secondary surgical site needed for harvestment of donor tissue and it provides excellent esthetic results with decreased patient morbidity. The present case report emphasizes on the treatment of multiple gingival recessions in the maxillary anterior teeth region using VISTA with titanium-prepared platelet-rich fibrin.

**Keywords:** *Gingival recession, minimally invasive technique, root coverage, vestibular incision subperiosteal tunnel access technique*

### Introduction

Gingival recession treatment in the field of esthetics poses a great challenge for a periodontist.<sup>[1]</sup> Root hypersensitivity, esthetics, trauma, anatomical factors, inadequate oral hygiene maintenance, and inadequate width of attached gingiva are the main concerns requiring periodontal plastic surgeries.<sup>[2]</sup> Several surgical techniques such as coronary advanced flap with connective tissue grafts, platelet concentrates, and free gingival grafts have been used and achieved good results. However, some drawbacks such as patient morbidity, compliance, second surgical sites, and lower predictability led to the development of newer treatment modalities.<sup>[3]</sup> Treatment of a single-tooth gingival recession is easier than multiple teeth. Thus, there are some modifications in surgical techniques such as envelope<sup>[4]</sup> or pouch techniques for the treatment of multiple recession defects, with some limitations. The present case report introduces a novel surgical minimally invasive technique called vestibular incision subperiosteal tunnel access (VISTA)

This is an open access journal, and articles are distributed under the terms of the Creative Commons Attribution-NonCommercial-ShareAlike 4.0 License, which allows others to remix, tweak, and build upon the work non-commercially, as long as appropriate credit is given and the new creations are licensed under the identical terms.

For reprints contact: reprints@medknow.com

technique<sup>[5]</sup> for the treatment of multiple gingival recessions in the anterior region. It provides access for coronal reposition of gingival margin for root coverage.

### Case Report

A 42-year-old, systemically healthy, nonsmoker male patient came to the Department of Periodontology and Implantology, Institute of Dental Sciences, Bareilly, Uttar Pradesh, India, with a chief complaint of receding gums in the upper front tooth region and sensitivity to cold in the same for 3 months. On examination, there were Miller's Class I and Class II gingival recessions ranging from 4 to 5 mm in the maxillary anterior teeth region, i.e., from 12 to 22, and cervical caries in the same region. Hence, VISTA technique was planned. The patient underwent Phase I therapy and modified Stillman's brushing technique was advocated to prevent further recession. After 2 weeks of observation, the procedure was explained to the patient, informed consent was obtained, the patient underwent routine blood investigations, and surgical procedure was performed.

**How to cite this article:** Agarwal MC, Rathore P, Gummaluri SS, Agarwal P, Kumari S. Vestibular incision subperiosteal tunnel access with titanium-prepared platelet-rich fibrin – A golden approach for treating multiple recession defects in esthetic zone. *Contemp Clin Dent* 2019;10:682-5.

**Manvi Chandra Agarwal, Priyansha Rathore, Shiva Shankar Gummaluri, Prerna Agarwal, Sanju Kumari**

*Department of Periodontology and Implantology, Institute of Dental Sciences, Bareilly, Uttar Pradesh, India*

**Address for correspondence:**  
Dr. Priyansha Rathore,  
Department of Periodontology and Implantology, Institute of Dental Sciences, Philibit Bypass Road, Bareilly - 243 006, Uttar Pradesh, India.  
E-mail: priyansha.rathore@gmail.com

#### Access this article online

**Website:**  
[www.contempclindent.org](http://www.contempclindent.org)

**DOI:** 10.4103/ccd.ccd\_2\_19

#### Quick Response Code:



After achieving profound anesthesia, cervical caries were restored with glass ionomer cement (GIC) filling, and then VISTA was begun with a vestibular access incision in the maxillary frenum region which gave access to the entire anterior region of the maxilla. For creating subperiosteal tunneling, incision was extended through the periosteum using a periosteal elevator between periosteum and bone through the vestibular access incision. The tunneling was extended one or two teeth beyond to that of teeth being treated. For elimination of residual tension in the flap and for proper coronal advancement, tunneling was extended beyond the mucogingival junction above and interproximal region of each papilla below without any additional incisions. After tunnel preparation, a titanium-prepared platelet-rich fibrin (T-PRF) membrane was prepared using Tunali's protocol.<sup>[6]</sup> Then, the T-PRF clot was made into a membrane and adjusted according to the surgical site, and its width was maintained beyond the bony dehiscence overlying the root surface. The membrane was passed through the vertical incision to fit the subperiosteal tunnel and placed below the gingival margin. After that, the total gingival complex along with the membrane was coronally advanced and sutured in its new position with a horizontal mattress sutures. They were placed and anchored 2–3 mm below the gingival margin in the mid-coronal portion of the tooth with light

cure composite stops. Lastly, the vertical incision was approximated with interrupted sutures. In this technique, the 4-0 silk suture material was used. Then, a periodontal pack was placed on the surgical site and was recalled after 14 days for suture removal. The patient was prescribed capsule amoxicillin 500 mg thrice daily and diclofenac sodium + paracetamol twice daily for 3 days with 0.12% chlorhexidine mouthwash for 2 weeks postoperatively. Finally, the patient was kept on a follow-up period of 6 months. After the follow-up period, an adequate amount of root coverage was obtained. Figures 1-3 depict the surgical treatment.

### Discussion

Treating multiple gingival recessions is a challenging task for any periodontist. Initially, Allen<sup>[7]</sup> gave a supraperiosteal tunneling technique for the treatment of multiple gingival recessions. This was modified by Zabalegui *et al.*,<sup>[8]</sup> where they eliminated the internal bevel incision. Generally, making a supra- or subperiosteal tunneling through gingival sulcus causes problems such as difficulty in proper graft or membrane placement, increased risk of tearing, or perforation of flaps, thus leading to improper healing of marginal gingival tissues. For eliminating these problems, Zadeh<sup>[5]</sup>

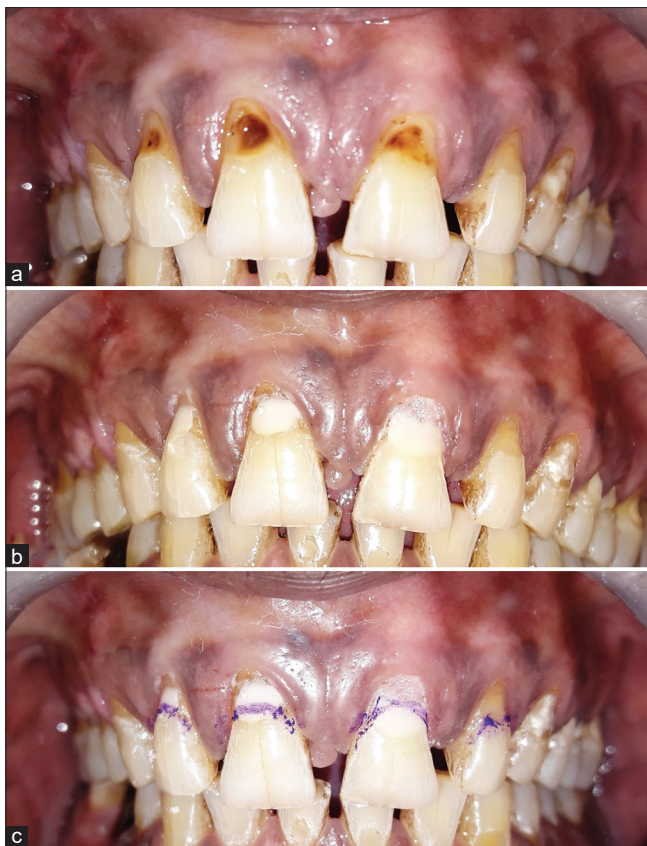

Figure 1: (a) Preoperative view. (b) After GIC filling. (c) After cementoenamel junction marking

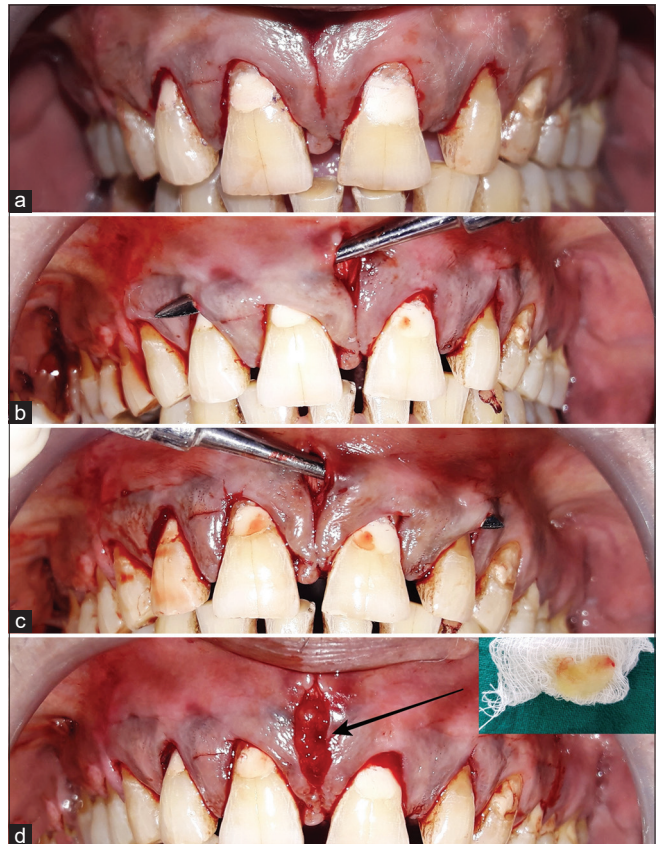
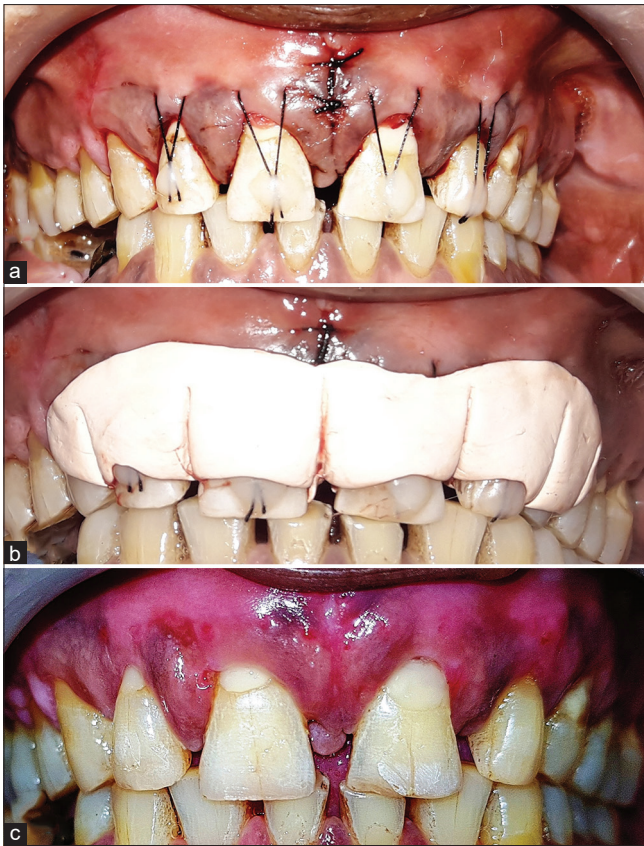

Figure 2: (a) Initial vestibular access incision made. (b) Subperiosteal tunnel preparation in relation to 11 and 12. (c) Subperiosteal tunnel preparation in relation to 21 and 22. (d) Titanium-prepared platelet-rich fibrin membrane placed



**Figure 3:** (a) Suturing done with 4-0 silk suture. (b) Periodontal pack placed. (c) Six-month postoperative view showing good recession coverage

introduced VISTA technique in 2011 where he has obtained the subperiosteal tunneling from maxillary frenum for the treatment of multiple anterior gingival recession defects. This initial incision prevents the scar formation, thus increasing the maximum outcome regarding esthetics. The major difference between this VISTA and others was the way of coronary advancement and stabilization of tissue by suturing. Suturing prevents the micromotion of gingival tissue that may be increased during facial movements. It reduces the muscle pull and maintains the papillary integrity as interdental papilla is not reflected (no sulcular incisions), making treatment outcomes predictable.<sup>[5]</sup> Moreover, VISTA has an additional advantage of treating multiple gingival recessions without any additional secondary surgical sites, thus eliminating postoperative pain and morbidity. In a similar way, the present case has shown predictable outcomes regarding the recession coverage and achieved good results 6 months postoperatively.

Studies by Gupta *et al.*<sup>[9]</sup> and Dandu and Murthy<sup>[10]</sup> have used PRF, periosteal pedicle graft, or GEM21S in association with VISTA and achieved good results. In the present case, we have used T-PRF membrane which was made in medical-grade titanium tubes, as it helps in soft-tissue healing by increasing vascularization and thus

leading to early wound repair as titanium activates blood much better than silica and more cells are entrapped with better fibrin structure.<sup>[6]</sup> This technique helps in a tension-free coronary advancement due to the tunneling extension beyond mucogingival junction.

## Conclusion

The present case report showed that VISTA is one of the novel approaches and a good alternative in the treatment of multiple gingival recession defects as it eliminates second surgical site and decreases patient's morbidity and improves patient's compliance. Moreover, better percentage of root coverage and esthetic results were achieved in the present case. Thus, more studies are needed to be carried out for determining the long-term stability of this technique.

## Declaration of patient consent

The authors certify that they have obtained all appropriate patient consent forms. In the form the patient(s) has/have given his/her/their consent for his/her/their images and other clinical information to be reported in the journal. The patients understand that their names and initials will not be published and due efforts will be made to conceal their identity, but anonymity cannot be guaranteed.

## Financial support and sponsorship

Nil.

## Conflicts of interest

There are no conflicts of interest.

## References

1. Wennstrom JL. Mucogingival surgery. In: Lang NP, Karring T. editors. Proceedings of the 1<sup>st</sup> European Workshop on Periodontology. London: Quintessence International; 1994. p. 193-209.
2. Baker DL, Seymour GJ. The possible pathogenesis of gingival recession. A histological study of induced recession in the rat. *J Clin Periodontol* 1976;3:208-19.
3. Oates TW, Robinson M, Gunsolley JC. Surgical therapies for the treatment of gingival recession. A systematic review. *Ann Periodontol* 2003;8:303-20.
4. Vergara JA, Caffesse RG. Localized gingival recessions treated with the original envelope technique: A report of 50 consecutive patients. *J Periodontol* 2004;75:1397-403.
5. Zadeh HH. Minimally invasive treatment of maxillary anterior gingival recession defects by vestibular incision subperiosteal tunnel access and platelet-derived growth factor BB. *Int J Periodontics Restorative Dent* 2011;31:653-60.
6. Tunali M, Özdemir H, Küçükodacı Z, Akman S, Yaprak E, Toker H, *et al.* A novel platelet concentrate: Titanium-prepared platelet-rich fibrin. *Biomed Res Int* 2014;2014:1-7.
7. Allen AL. Use of the supraperiosteal envelope in soft tissue grafting for root coverage. I. Rationale and technique. *Int J Periodontics Restorative Dent* 1994;14:216-27.
8. Zabalegui I, Sicilia A, Cambra J, Gil J, Sanz M. Treatment of

- multiple adjacent gingival recessions with the tunnel subepithelial connective tissue graft: A clinical report. *Int J Periodontics Restorative Dent* 1999;19:199-206.
9. Gupta G, Puri K, Bansal M, Khatri M, Kumar A. Platelet-rich fibrin-reinforced vestibular incision subperiosteal tunnel access technique for recession coverage. *Clin Adv Periodontics* 2015;4:248-53.
  10. Dandu SR, Murthy KR. Multiple gingival recession defects treated with coronally advanced flap and either the VISTA technique enhanced with GEM 21S or periosteal pedicle graft: A 9-month clinical study. *Int J Periodontics Restorative Dent* 2016;36:231-7.