

Does Ambroxol alleviate kidney ischemia-reperfusion injury in rats?

Çağrı Gültekin^{1*}, Serkan Sayiner², Şule Çetinel³, Ahmet Özer Şehirli⁴

¹ Department of Surgery, Faculty of Veterinary Medicine, Near East University, 99138, Nicosia, Cyprus

² Department of Biochemistry, Faculty of Veterinary Medicine, Near East University, 99138, Nicosia, Cyprus

³ Department of Histology and Embryology, School of Medicine, Marmara University, 34722 Istanbul, Turkey

⁴ Department of Pharmacology, Faculty of Dentistry, Near East University, 99138, Nicosia, Cyprus

ARTICLE INFO

Article type:

Original

Article history:

Received: Mar 11, 2022

Accepted: Aug 6, 2022

Keywords:

Ambroxol

Distant organ effect

Kidney ischemia reperfusion

Pro-inflammatory cytokines

Rat

ABSTRACT

Objective(s): Ischemia-reperfusion injury is a life-threatening clinical problem that can occur after transplantation or a number of clinical procedures. The purpose of the study was to investigate the effects of Ambroxol on kidney damage caused by experimentally induced ischemia-reperfusion injury in rats.

Materials and Methods: Wistar albino rats were divided into 3 groups: Control (CTR, n=6), Kidney ischemia-reperfusion (K-IR, n=6), And kidney ischemia reperfusion+Ambroxol (K-IR+AMB, n=6). In K-IR+AMB group, Ambroxol (30 mg/kg) was administered orally 30 min before the ischemia period. K-IR and K-IR+AMB groups underwent 45 min of kidney ischemia followed by a 6-hour reperfusion period. At the end of the reperfusion period, blood and kidney tissue samples were collected after euthanasia. From the blood samples, BUN and creatinine levels were determined to assess kidney function, and TNF- α and IL-1 β concentrations were evaluated to determine inflammatory response.

Results: While serum BUN, creatinine activities, and TNF- α and IL-1 β concentrations were higher in both IR groups compared with the CTR group, these values were found to be lower in the K-IR+AMB group compared with the K-IR group. Histopathological examination revealed that interstitial edema and desquamation of tubular cells in the K-IR group were more severe than in the K-IR+AMB group.

Conclusion: Ambroxol treatment alleviated the production of pro-inflammatory cytokines and the harmful cellular effects in the tubular cells.

► Please cite this article as:

Gültekin Ç, Sayiner S, Çetinel Ş, Şehirli AÖ. Does Ambroxol alleviate kidney ischemia-reperfusion injury in rats? Iran J Basic Med Sci 2022; 25: 1037-1041. doi: <https://dx.doi.org/10.22038/IJBMS.2022.64330.14148>

Introduction

Ischemia-Reperfusion (IR) is defined as the damage caused by the temporary interruption of blood flow to tissues or an organ, following the restoration of blood flow (1). IR injury is a crucial clinical and surgical problem affecting many different organs such as the kidney, brain, heart, liver, lung, and intestine (2-4). Kidney IR injury can be caused by sepsis, shock, hydronephrosis, open renal stone surgery, partial nephrectomy, transplantation, bleeding, and resuscitation (5). Tumor necrosis factor- α (TNF- α) is a critical pro-inflammatory cytokine in kidney IR (K-IR) injury. Excessive production of TNF- α causes a variety of damage to kidney cells, including cell apoptosis, glomerular endothelial damage, fibrin deposition, cellular infiltration, and renal failure (6). After K-IR injury, the renal tubular epithelium produces pro-inflammatory cytokines such as interleukin-1 β (IL-1 β) which potentiate inflammation (7, 8).

One of the strategies to reduce IR damage involves the administration of pharmacological agents. Many antioxidant agents that act through different mechanisms have been tested clinically and experimentally against K-IR (9). Ambroxol (2-amino-3,5-dibromo-N-[trans-4-hydroxycyclohexyl] benzylamine) is a drug used in respiratory tract diseases due to its mucolytic and secretory properties (10). The effectiveness of Ambroxol on pro and anti-inflammatory cytokines has previously been demonstrated (11, 12). Ambroxol reduces lipopolysaccharide-induced cytokine

synthesis in macrophages, attenuates LPS-stimulated superoxide anion and hydrogen peroxide production, and reduces LPS-induced nitric oxide production. It has been reported that the anti-inflammatory effect of Ambroxol reduces TNF- α and neutrophil infiltration in the lungs of rats (13). In addition, Ambroxol also reduces the release or production of cytokines such as IL-1 β (14).

Renal ischemia-reperfusion damage, which can occur for a variety of reasons, is a common cause of acute renal failure with a high mortality risk due to elevated cytokine production. Therefore, investigations including the testing of new therapeutic medicines in treatment protocols are critical. In this study, the effects of Ambroxol, with known anti-inflammatory properties, on pro-inflammatory cytokines were used in a rat kidney ischemia-reperfusion damage model to investigate its efficacy in the treatment of renal ischemia-reperfusion injury.

Materials and Methods

Ethical statement

Approval for the study protocol was obtained from the local animal ethics committee of Near East University (Protocol no: 2019-97). The laboratory staff was blinded to the groups and the administration protocols allocated to the rats. The number of animals used in the experiment was determined to use the least number of animals that would provide statistically significant results.

*Corresponding author: Çağrı Gültekin. Department of Surgery, Faculty of Veterinary Medicine, Near East University, 99138, Nicosia, Cyprus. Tel: +90 (0 392) 675 10 00/ 3136; Email: cagri.gultekin@neu.edu.tr

Animals

Eighteen outbred Wistar albino rats, with a weight between 200 and 250 g, including both sexes, were enrolled in the study. All rats were housed in a controlled environment, (humidity (60%), temperature-controlled ($22 \pm 2^\circ\text{C}$) with a 12-hr light/dark cycle), using conventional cages (solid plastic, rectangular shaped, 20 cm high with a wire mesh lid). Pelleted rat food and water were provided *ad libitum*.

Experimental model

Rats were divided into three groups: control group (CTR, n=6) (rats operated without treatment), kidney ischemia-reperfusion group (K-IR, n=6), and kidney ischemia/reperfusion + Ambroxol group (K-IR+AMB, n=6). Exclusion criteria were determined as rats dying during ischemia and/or reperfusion period. No rats were excluded from this study. A liquid form of Ambroxol was obtained from Bilim İlaç San.ve Tic. A.Ş., Turkey and was administered at 30 mg/kg orally in K-IR and K-IR+AMB groups 30 mins before anesthesia (15). All groups were anesthetized by intraperitoneal injection using a mixture of Ketamine (10% Ketamine, Dutchfarm®, 100 mg/kg) and Xylazine (2% Vetaxyl, Vetagro®, 10 mg/kg) and fixed in a supine position. Access to the abdominal cavity was performed via a ventral midline incision. In the K-IR and K-IR+AMB groups, the right kidneys were removed. The renal artery and veins of the left kidney were ligated for 45 min to induce ischemia until a color change in the left kidney was observed. The kidneys were reperused for 6 hr by opening the ligature (16). At the end of the reperfusion period, the rats were euthanized with an overdose of Xylazine+Ketamine anesthesia. The left kidneys were excised, and blood samples were collected into serum separator tubes. All procedures were performed by the same veterinary surgeon in the experimental working unit under the conditions of the housing room.

Biochemical analysis

Blood samples were centrifuged at 1500 g x 10 min following coagulation. Then, sera were separated and kept at a temperature of -20°C until analyzed. Alkaline phosphatase (ALP, U/l), lactate dehydrogenase (LDH, U/l) enzyme activities, blood urea nitrogen (BUN, mg/dl), and creatinine (mg/dl) levels were quantified to assess renal function. Assays were performed using an automated analyzer (BS120, Mindray, Shenzhen, China) and ready-to-use commercial test kits.

Concentrations of TNF- α (pg/ml) and IL-1 β (pg/ml) in sera were determined by rat-specific ELISA assay kits (Rat TNF- α ELISA Kit Catalog No: E-EL-R0019; Rat IL-

1 β Catalog No: E-EL-R001, Elabscience Biotechnology Inc., TX, USA). Assays were carried out following the manufacturer's directions.

Histopathological analysis

For light microscopic investigations, the removed kidneys were fixed in 10% neutral-buffered formalin solution, dehydrated in alcohol concentration series, cleared in toluene, and embedded in paraffin blocks. The kidney sample paraffin blocks were serially sectioned at an average thickness of 5 μm . Histopathological analyses were conducted on hematoxylin-eosin-stained samples using the bright field mode of a light microscope (Zeiss-Axio Scope A1, Carl Zeiss, Gottingen, Germany).

Statistical Analysis

Statistical analyses were carried out using GraphPad Prism 9.1.2 (GraphPad Software, San Diego, CA, USA). All results are expressed as the means \pm 1SD. One-way analysis of variance (ANOVA) was used to compare quantified parameters between experimental groups. Tukey's test was used for further analysis of binary comparisons. *P*-values below 0.05 were regarded as significant.

Results

ALP and LDH activities (Table 1) were measured as mediators of kidney injury to assess the effects of IR injury on renal cells, as well as the reducing effect of Ambroxol. After the IR injury, a significant elevation in ALP and LDH activities in the K-IR group was detected in comparison with the CTR group (respectively, $P<0.01$ and $P<0.001$). However, in the Ambroxol administrated group (K-IR+AMB) ALP and LDH activities significantly decreased compared with the K-IR group ($P<0.05$).

BUN and creatinine parameters were quantified as indirect indicators of glomerular filtration rates, thus addressing kidney function (Table 1). The IR injury provoked rising BUN and creatinine levels in the K-IR group compared with the CTR group (both $P<0.0001$). However, Ambroxol administration (K-IR+AMB) significantly decreased BUN and creatinine levels compared with the K-IR group (both $P<0.01$).

The pro-inflammatory markers, TNF- α and IL-1 β , were measured to assess inflammatory response against IR injury and the effect of Ambroxol administration. Rats in the K-IR group secreted significantly higher levels of TNF- α ($P<0.001$) and IL-1 β ($P<0.01$) than rats in the CTR group. Nevertheless, TNF- α and IL-1 β levels decreased in the K-IR+AMB group compared with the K-IR group, $P<0.01$ and $P<0.05$, respectively (Figure 1).

The histopathological findings show that the kidney

Table 1. Plasma BUN, creatinine, ALP, and LDH activities in the control (CTR), kidney ischemia/reperfusion (K-IR), and kidney ischemia/reperfusion +Ambroxol (K-IR+AMB) groups of rats

| | CTR | K-IR | K-IR+AMB |
|--------------------|------------------|-----------------------|-----------------------------------|
| ALP (U/l) | 91.4 \pm 3.3 | 125.2 \pm 7.4 ** | 100.7 \pm 4.6 ⁺ |
| LDH (U/l) | 3050 \pm 463 | 5987 \pm 456 *** | 4313 \pm 212 ⁺ |
| BUN (mg/dl) | 21.69 \pm 0.81 | 32.25 \pm 1.54 **** | 25.78 \pm 0.66** |
| creatinine (mg/dl) | 0.68 \pm 0.02 | 1.18 \pm 0.04 **** | 0.94 \pm 0.04 *** ⁺⁺ |

** $P<0.01$; *** $P<0.001$; and **** $P<0.0001$, compared with the control (CTR) group. + $P<0.05$ and ++ $P<0.01$, compared with the K-IR group
BUN: Blood urea nitrogen; ALP: Alkaline phosphatase; LDH: Lactate dehydrogenase

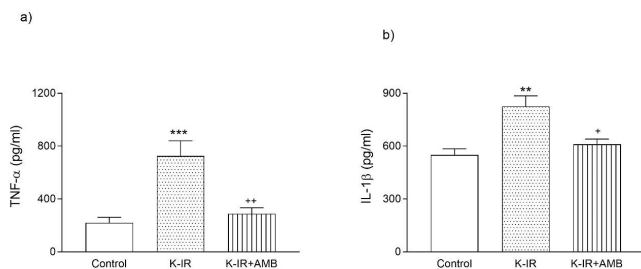


Figure 1. Plasma TNF- α (a) and IL-1 β (b) activities in the control (CTR), kidney ischemia/reperfusion (K-IR), and kidney ischemia/reperfusion +Ambroxol (K-IR+AMB) groups in rats. ** $P<0.01$ and *** $P<0.001$, compared with the control (CTR) group. + $P<0.05$ and ++ $P<0.01$, compared with the K-IR group of rats

tissue exhibited regular glomeruli and tubuli in the CTR group (Figure 2a), whereas the K-IR and K-IR+AMB groups had dilated tubuli, edema in the interstitium, and desquamated tubular cells (Figure 2b). On the other hand, interstitial edema and desquamation of tubular cells were found to be decreased in the K-IR+AMB group (Figure 2c).

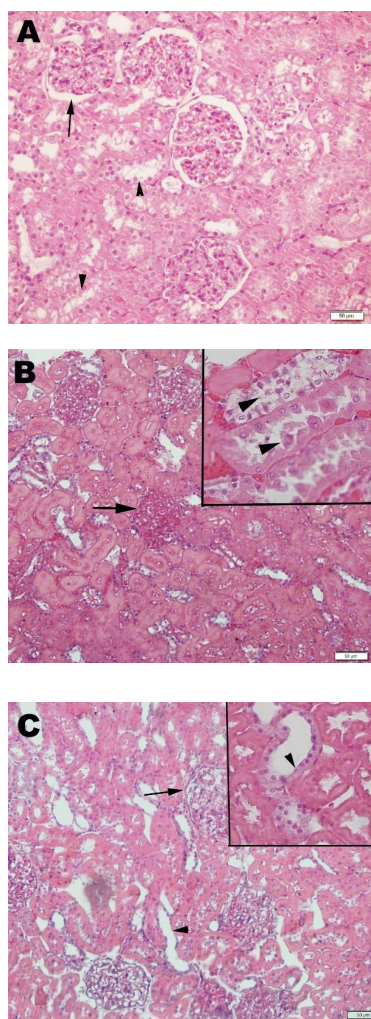


Figure 2. (a) Regular morphology in kidney glomerulus (arrow) and tubuli (arrowheads) of rats in the control group. (b) In the rats of the ischemia-reperfusion group, heavy interstitial edema which constricts glomeruli (arrow), dense desquamation of tubular cells (arrowheads). (c) In the rats of the ischemia-reperfusion and Ambroxol group, regression of interstitial edema (arrow) and re-establishment of tubular cells (arrowheads). HE staining, inset (20 μm)

Discussion

In the pathophysiological mechanisms of IR injury, many factors play an important role, such as cytokine formation, cellular damage, and inflammation, involving complex signaling pathways. Although there are many different approaches to the use of drugs against IR injury, the main goal in the management of IR injury is to protect cells or minimize cellular damage (17). Therefore, we investigated the effects of Ambroxol on kidney damage caused by IR injury in this study.

BUN and creatinine are metabolites excreted by glomerular filtration, and their plasma concentrations increase in cases where glomerular filtration is affected, such as acute renal failure, intoxication, and kidney transplant rejection (18). K-IR injury causes tubular and glomerular dysfunction, especially during the reperfusion phase, such as tubular cell necrosis and damage, glomerular damage, and decreased glomerular filtration rate (16, 19). In this study, BUN and creatinine levels were measured to detect kidney damage due to glomerular and tubular damage. According to BUN, creatinine levels, and histopathological examination results we demonstrated that ischemia-reperfusion injury impaired glomerular and tubular structures and functions in both groups. Although this deterioration was observed to be more severe in the K-IR group, it was less severe in the Ambroxol group, indicating that Ambroxol is effective in preserving renal tubular and glomerular structures.

In K-IR injury, the release of inflammatory cytokines such as IL-1 β , which induces the mobilization of leukocytes and determines inflammatory activation, and TNF- α , which provides neutrophil infiltration, increases kidney injury and contributes to inflammation in tubular cells (1, 20, 21). In some studies, it has been shown that Ambroxol affects inflammatory cytokines and reduces TNF- α and IL-1 β levels (13, 14). In this study, the levels of inflammatory cytokines TNF- α and IL-1 β were measured to determine K-IR injury. Our results show that Ambroxol reduced the harmful effects of K-IR injury on kidney tissue by decreasing the levels of TNF- α and IL-1 β , which are essential inflammatory cytokines in K-IR injury. In studies on cytokine expression, Ambroxol has been shown to reduce TNF- α and IL-1 β levels, especially in inflammation models (22, 23). However, the effects of Ambroxol on K-IR injury have not been evaluated to date. This study demonstrated the protective effect of Ambroxol against the harmful effects of pro-inflammatory cytokines TNF- α and IL-1 β after kidney ischemia-reperfusion injury.

In acute renal failure, multiple organ failure and secondary diseases can often be seen and concomitant diseases usually determine the severity of the condition. Furthermore, elevated levels of pro-inflammatory cytokines and K-IR damage in the liver have been shown to raise serum LDH and ALP activities (24-28). Besides, recent research suggests that the activity of ALP and LDH enzymes is also a good marker for detecting renal cellular damage in acute kidney injury (29-31). Thus, LDH and ALP activities were considered to assess the effects of K-IR injury on the liver and kidney. LDH and ALP values in the K-IR group were higher than those in the K-IR+AMB group, similar to prior findings. According to these results, Ambroxol protects against K-IR injury both directly by lowering cytokine levels and indirectly by lowering LDH and ALP levels on kidney cells or liver cells, which provide compensation in the body against cytokines generated after K-IR injury.

Conclusion

In this study, we investigated the effects of Ambroxol on TNF- α and IL-1 β , which cause histopathological changes, after experimentally induced K-IR injury. Our findings were that Ambroxol reduced the release of TNF- α and IL-1 β , thus reducing the effects of IR on the kidney. The effects of Ambroxol at different doses and on other pathophysiological mechanisms that occur with ischemia-reperfusion are subjects that need to be investigated, and our future studies aim to investigate these issues. In conclusion, in line with the findings obtained from the study, Ambroxol can be used as one of the preventive, therapeutic approaches to the effects of K-IR injury.

Authors' Contributions

ÇG, AÖŞ, and SS Provided study conception and design; ÇG and AÖŞ Performed experiments; SS, ŞÇ, and AÖŞ Analyzed data; ÇG, AÖŞ, and SS Interpreted the results and wrote the manuscript.

Acknowledgment

The authors received no financial support for the research, authorship, and/or publication of this article.

Funding

The authors received no financial support for the research, authorship, and/or publication of this article.

Data Statement

The data presented in this study are available via the corresponding author's e-mail.

Conflicts of Interest

The authors declared no potential conflicts of interest with respect to the research, authorship, and/or publication of this article.

References

1. Eraslan E, Tanyeli A, Polat E, Yetim Z. Evodiamine alleviates kidney ischemia reperfusion injury in rats: a biochemical and histopathological study. *J Cell Biochem* 2019; 120:17159-17166.
2. Linfert D, Chowdhry T, Rabb H. Lymphocytes and ischemia-reperfusion injury. *Transplant Rev* 2009; 23: 1-10.
3. Liu JH, Xie CJ, Li L. Effects of ambroxol on renal function in children undergoing cardiopulmonary bypass. *Zhongguo Dang Dai Er Ke Za Zhi* 2009; 11: 656-658.
4. Elfouli MM, Said ME, Emam HT, Abu-raia NH, Metwally MA. Effect of ambroxol on experimentally induced acute oxidative stress in the heart, kidney, and intestine in rats. *Benha Med J* 2018; 35: 317-325.
5. Altintas R, Parlakpınar H, Beytur A, Vardi N, Polat A, Sagir M, *et al.* Protective effect of dexpanthenol on ischemia-reperfusion-induced renal injury in rats. *Kidney Blood Press Res* 2012; 36: 220-230.
6. Erkasap S, Erkasap N, Koken T, Kahraman A, Uzun K, Yazihan N, *et al.* Effect of leptin on renal ischemia-reperfusion damage in rats. *J Physiol Biochem* 2004; 60: 79-84.
7. Bonventre JV, Zuk A. Ischemic acute renal failure: an inflammatory disease? *Kidney Int* 2004; 66: 480-485.
8. Sehirli O, Sener E, Cetinel S, Yüksel M, Gedik N, Sener G. Alpha-lipoic acid protects against renal ischaemia-reperfusion injury in rats. *Clin Exp Pharmacol Physiol* 2008; 35: 249-255.
9. Pisoschi AM, Pop A. The role of anti-oxidants in the chemistry of oxidative stress: a review. *Eur J Med Chem* 2015; 97: 55-74.
10. Kantar A, Klimek L, Cazan D, Sperl A, Sent U, Mesquita M.

An overview of efficacy and safety of ambroxol for the treatment of acute and chronic respiratory diseases with a special regard to children. *Multidiscip. Respir Med* 2020; 15: 511-522.

11. Lee CS, Jang YY, Song JS, Song JH, Han ES. Ambroxol inhibits peroxynitrite-induced damage of α 1-antitrypsinase and free radical production in activated phagocytic cells. *Pharmacol Toxicol* 2002; 91: 140-149.
12. Yoshida S, Yokohira M, Yamakawa K, Nakano-Narusawa Y, Kanie S, Hashimoto N, *et al.* Effects of the expectorant drug ambroxol hydrochloride on chemically induced lung inflammatory and neoplastic lesions in rodents. *J Toxicol Pathol* 2018; 31: 255-265.
13. Malerba M, Ragnoli B. Ambroxol in the 21st century: pharmacological and clinical update. *Expert Opin Drug Metab Toxicol* 2008; 4: 1119-1129.
14. Beeh KM, Beier J, Esperester A, Paul LD. Anti-inflammatory properties of Ambroxol. *Eur J Med Res* 2008; 13: 557-562.
15. Stetinová V, Herout V, Kvetina J. *In vitro* and *in vivo* antioxidant activity of ambroxol. *Clin Exp Med* 2004; 4: 152-158.
16. Kabasakal L, Sehirli AO, Cetinel S, Cikler E, Gedik N, Sener G. Mesna (2-mercaptoethane sulfonate) prevents ischemia/reperfusion induced renal oxidative damage in rats. *Life Sci* 2004; 75: 2329-2340.
17. Soares RO, Losada DM, Jordani MC, Évora P, Castro-e-Silva O. Ischemia/reperfusion injury revisited: an overview of the latest pharmacological strategies. *Int J Mol Sci* 2019; 20: 5034-5079.
18. Braun JP, Lefebvre HP. *Kidney Function and Damage*. In: Kaneko JJ, Harvey JW, Bruss ML eds. *Clinical Biochemistry of Domestic Animals*. 6th ed., Elsevier Academic Press, Burlington, MA, USA, 2008: 485-529.
19. Korkmaz A, Kolankaya D. The protective effects of ascorbic acid against renal ischemia-reperfusion injury in male rats. *Ren Fail* 2009; 31: 36-43.
20. Sehirli OA, Sener G, Ercan F. Protective effects of pycnogenol against ischemia reperfusion-induced oxidative renal injury in rats. *Ren Fail* 2009; 31: 690-697.
21. Güvenç M, Cellat M, Uyar A, Özkan H, Gokcek İ, İslar CT, *et al.* Nobiletin protects from renal ischemia-reperfusion injury in rats by suppressing inflammatory cytokines and regulating iNOS-eNOS expressions. *Inflammation* 2020; 43: 336-346.
22. Wang Y, Wang FY, Pan Z, Dai YY, Xu HJ, Jin KK, *et al.* Effects of ambroxol combined with low-dose heparin on TNF- α and IL-1 β in rabbits with acute lung injury. *Chin J Physiol* 2011; 27: 231-235.
23. Lin X, Fan Y, Wang X, Chi M, Li X, Zang X, *et al.* Correlation between tumor necrosis factor- α and interleukin-1 β in exhaled breath condensate and pulmonary function. *Am J Med Sci* 2017; 354: 388-394.
24. Serteser M, Koken T, Kahraman A, Yilmaz K, Akbulut G, Dilek ON. Changes in hepatic TNF- α levels, anti-oxidant status, and oxidation products after renal ischemia/reperfusion injury in mice. *J Surg Res* 2002; 107: 234-240.
25. Golab F, Kadkhodae M, Zahmatkesh M, Hedayati M, Arab H, Schuster R, *et al.* Ischemic and non-ischemic acute kidney injury cause hepatic damage. *Kidney Int* 2009; 75: 783-792.
26. Kehinde EO, Al-Awadi KA, Al-Hunayan A, Mojiminiyi OA, Memon A, Abdul-Halim H, *et al.* Anti-oxidant therapy is associated with a reduction in the serum levels of mediators of renal injury following lithotripsy for renal calculi. *J Endourol* 2008; 22: 2537-2545.
27. Akbari G. Role of zinc supplementation on ischemia/reperfusion injury in various organs. *Biol Trace Elem Res* 2020; 196: 1-9.
28. Cienfuegos-Pecina E, Ibarra-Rivera TR, Saucedo AL, Ramírez-Martínez LA, Esquivel-Figueroa D, Domínguez-Vázquez I, *et al.* Effect of sodium (S)-2-hydroxyglutarate in male, and succinic acid in female wistar rats against renal ischemia-

reperfusion injury, suggesting a role of the HIF-1 pathway. *Peer J* 2020; 8: 1-33.

29. Zager RA, Johnson AC, Becker K. Renal cortical lactate dehydrogenase: A useful, accurate, quantitative marker of *in vivo* tubular injury and acute renal failure. *PLoS One* 2013; 8: 1-12.

30. Peters E, Heemskerk S, Masereeuw R, Pickkers P. Alkaline phosphatase: a possible treatment for sepsis-associated acute

kidney injury in critically ill patients. *Am J Kidney Dis* 2014; 63: 1038–1048.

31. Nielsen PM, Laustsen C, Bertelsen LB, Qi H, Mikkelsen E, Kristensen MLV, *et al.* In situ lactate dehydrogenase activity: a novel renal cortical imaging biomarker of tubular injury? *Am J Physiol Renal* 2017; 312: 465-473.