

CASE REPORT

Advanced lung cancer presenting with malignant pericardial effusion

Abid M. Sadiq^{1,2}  | Adnan M. Sadiq^{2,3} | Gilbert Z. Nkya^{2,4}

¹Department of Internal Medicine, Kilimanjaro Christian Medical Centre, Moshi, Tanzania

²Kilimanjaro Christian Medical University College, Moshi, Tanzania

³Department of Radiology, Kilimanjaro Christian Medical Centre, Moshi, Tanzania

⁴Department of Pathology, Kilimanjaro Christian Medical Centre, Moshi, Tanzania

Correspondence

Abid M. Sadiq, Department of Internal Medicine, Kilimanjaro Christian Medical Centre, P.O. Box 3010, Moshi, Tanzania.
Email: abid.physician@gmail.com

Abstract

Irregular pericardial wall thickening, mediastinal lymph nodes, and pericardial fluid analysis are helpful to identify metastasis to the pericardium though it is a marker of advanced disease and poor prognosis.

KEYWORDS

atypical epithelioid cells, cardiac tamponade, lung malignancy, malignant pericardial effusion, pericardiocentesis

1 | INTRODUCTION

The normal pericardium has a visceral and parietal layer which are separated by a small quantity (15–50 mL) of fluid.¹ Malignancy may affect the pericardium by mass effect or by causing pericardial effusion (PE). The effusion may develop by tumor, lymphatic, and surface involvement affecting the normal reabsorption process or increased production of fluid.²

Malignancy can be associated with severe cardiac complications such as PE and cardiac tamponade. Chronic PE may present with gradual exercise intolerance and exertional dyspnea. If they are acute, they may cause cardiac tamponade with an acute hemodynamic compromise which requires urgent intervention.³

We present a middle-aged female with pericardial effusion and a left lung mass, accompanied with images of chest x-ray, chest and abdomen computed tomography (CT) scan, and pericardial fluid cytology.

2 | CASE REPORT

A 66 year-old woman presented with progressively worsening difficulty in breathing over 3 months. She had a productive cough, orthopnea, and left-sided chest pain. Apart from her reported weight loss, she did not have fever or excessive night sweats. Her past medical history was unremarkable but reported that she used to cook indoors using firewood.

On examination, she had labored breathing at rest and lower limb edema with no conjunctival or palmer pallor and no finger clubbing. She had a weak pulse, blood pressure of 135/78 mmHg, and raised jugular venous pressure (JVP). There was a dull percussion note on both lung field with diffuse bronchial breathing. The cardiac apex was displaced with normal heart sounds.

The hemoglobin and erythrocyte sedimentation rate were 14.6 g/L and 28 mm/hr respectively. The chest X-ray showed complete consolidation of the left lung (Figure 1). She was thought to either have an infectious versus malignant process.

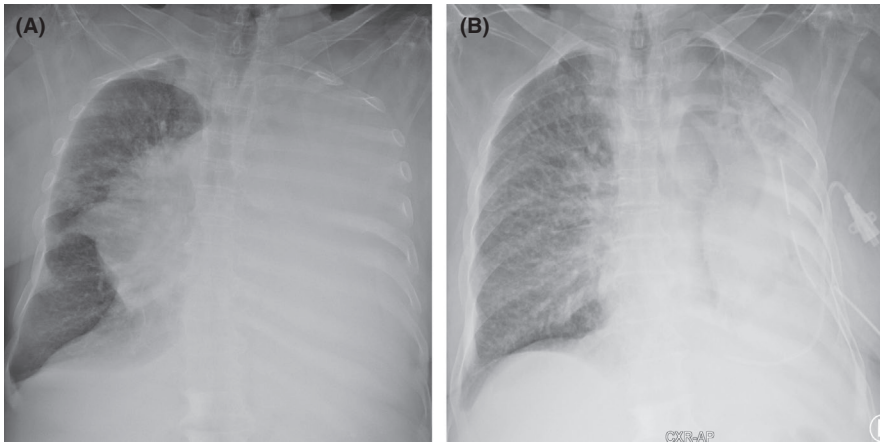


FIGURE 1 Chest x-ray shows A, complete left lung consolidation and B, control chest x-ray post pleural and pericardial fluid drainage

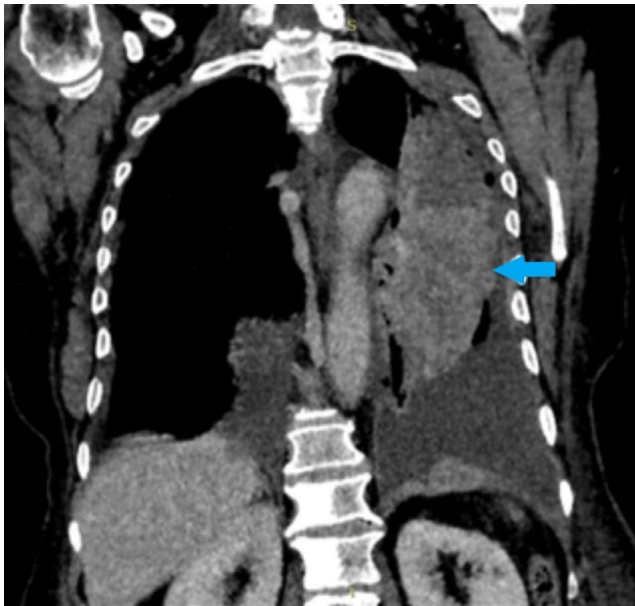


FIGURE 2 Coronal chest CT shows a poorly margined enhancing mass (blue arrow) in the left upper lobe abutting to the left pericardium with metastatic pericardial effusion and bilateral pleural effusion. Also showing multiple osteoblastic vertebral metastasis

Sputum analysis was negative for *Mycobacterium tuberculosis*. Left pleurocentesis was done draining over a liter of yellowish fluid which was exudative and cytology analysis showed scattered degenerating lymphoid cells consistent with an inflammatory process.

Within 2 days after admission, she developed a low blood pressure of 89/54 mmHg and muffled heart sounds together with the raised JVP. She was suspected to have pericardial effusion as she was in cardiac tamponade. Bedside echocardiography was done revealing a 3 cm pericardial effusion. And an electrocardiogram showed a slight low voltage sinus rhythm with poor R-wave progression. An urgent pericardiocentesis was done revealing a hemorrhagic effusion which drained over a liter in the course of her hospital stay.

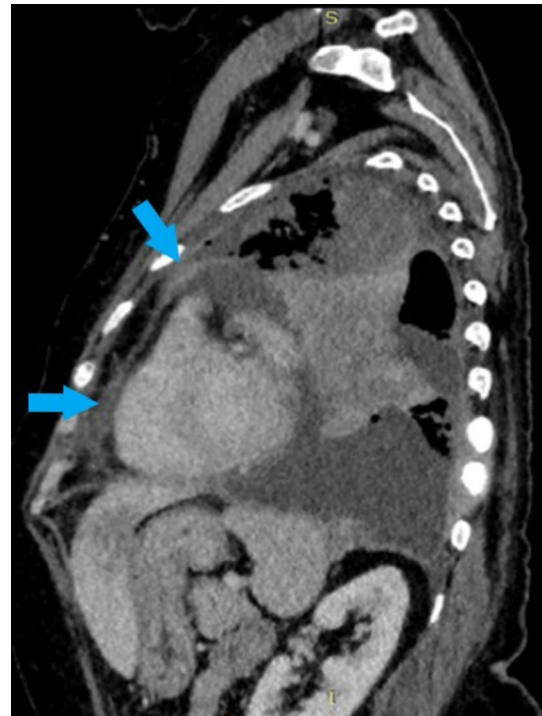


FIGURE 3 Sagittal chest CT shows anterior and superior pericardial wall thickening (blue arrow)

The fluid was taken for cytology analysis, and a CT was ordered.

A CT of the chest and abdomen showed a large enhancing spiculated mass in the left superior and inferior lingula segments of the lung measuring 8.5 cm × 5.6 cm × 14 cm (Figure 2). There were ipsilateral and contralateral mediastinal lymph nodes seen in keeping with lung metastasis. There was a thick 1.7 cm right-sided pericardial effusion noted with bilateral pleural effusion (Figure 3 & Figure 4). The liver showed multiple hypodense masses in segments II, III, IVA, and V suggestive of hepatic metastasis (Figure 5). The cervical and thoraco-lumbar spine showed multiple osteoblastic bone metastases (Figure 2). This was evident for metastatic

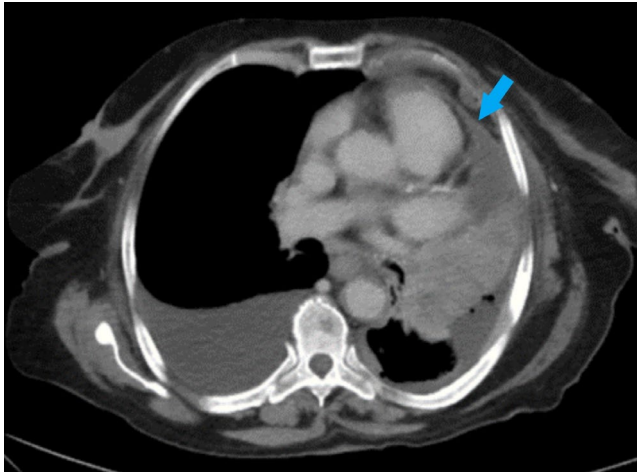


FIGURE 4 Axial chest CT shows pericardial wall thickening (blue arrow)

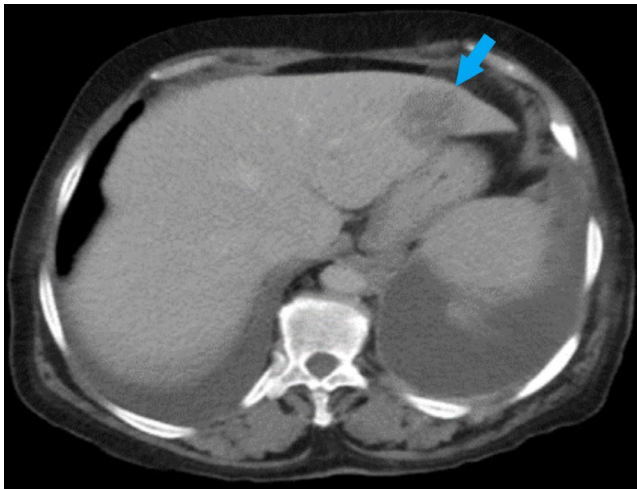


FIGURE 5 Axial upper abdomen CT shows segment II hepatic metastasis (blue arrow)

lung malignancy. The pericardial fluid cytology analysis showed a numerous cluster of atypical epithelioid cells with marked nuclear pleomorphism suggesting malignant cells (Figure 6 & Figure 7).

Apart from the left pleural and pericardial fluid drainage, she was also managed with diuretics and antipain. As she had symptomatic relief, she was discharged and referred for treatment of the suspected metastatic lung malignancy, but unfortunately, she passed away because of the advanced disease.

3 | DISCUSSION

The consequences of PE depend on the fluid volume, pericardial wall compliance, and rate of exudation. The management and clinical course of malignant PE depend on the

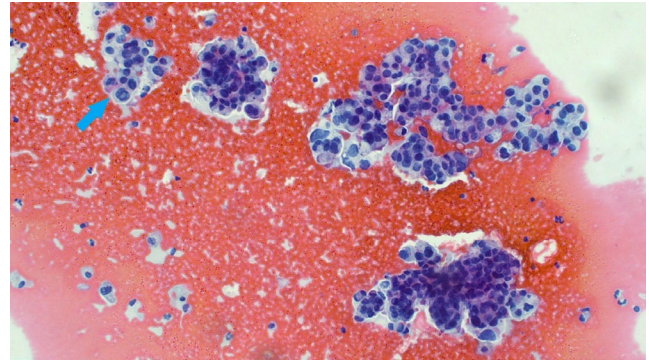


FIGURE 6 Clusters of atypical epithelioid cells with marked atypia, nuclear vacuoles, and bizarre mitotic figures are evident (blue arrow)

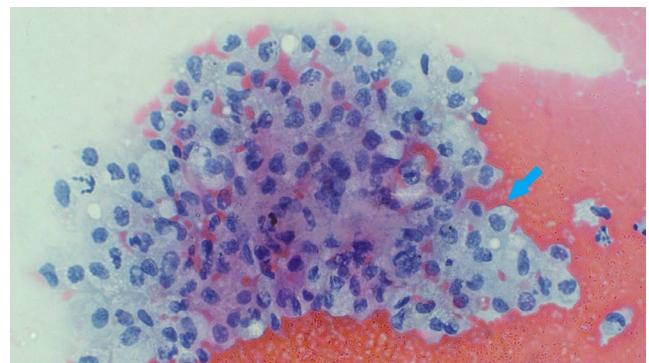


FIGURE 7 Atypical epithelioid cells with glandular differentiation (blue arrow)

underlying clinical status of the patient, and the extent and type of the underlying malignancy. In our case, we suspected the patient to have a primary lung malignancy with liver, bone, and pericardial metastasis. The patient initially was not in tamponade and presented with left-sided pleural effusion. Soon after, the patient developed tamponade and an urgent pericardiocentesis was done. Chest CT scan showed a left lung mass with mediastinal lymph nodes and pericardial thickening. The pericardial fluid analysis confirmed malignant cells likely from the lung mass, though the pleural fluid did not. Unfortunately, the patient was suspected to have advanced malignancy with a poor prognosis.

An estimated 42,000 new cases of cancer were identified in Tanzania in 2018. The incidence of lung cancer was 2.0% for both sexes, with a mortality rate of 2.8%.⁴ A retrospective study reported that lung cancer death occurred twice in males than females at 3.0% and 1.6% respectively.⁵ Within Northern Tanzania, the rate of cancer death is 7.3%, of those 4.7% are lung cancer.⁵

PE resulting from malignancy is uncommon as incidence is approximately 10% in autopsy patients with known malignancies.⁶ Primary lung malignancy is the most common associated with PE (approximately 30%), followed by malignancy

of breast (approximately 25%), leukemia, and lymphoma (approximately 15%).^{6,7} There have been reports of other malignant organ systems causing PE such as esophageal, gastric, and ovarian.

In this case, we suspected an infectious cause of the pleural effusion and tested for *M. tuberculosis* which turned out to be negative. Tuberculosis is the most common cause of pericardial diseases in Africa among HIV-infected and HIV-uninfected patients. Around 80% of tuberculous pericarditis patients present with effusive pericarditis.⁸

Irregular pericardial thickening together with mediastinal lymphadenopathy is specific findings for malignant pericardial disease.⁹ Irregular pericardial thickening can be seen in patients with tuberculosis of the pericardium, and therefore, pericardial fluid analysis is important to differentiate the two diagnoses. The presence of mediastinal lymphadenopathy occurs as most pericardial metastases develop via the mediastinal lymph nodes.¹⁰

Pericardiocentesis is indicated in patients with moderate to large PE and clinical suspicion of malignancy.¹¹ Symptomatic PE is typically managed with pericardiocentesis for both diagnostic and therapeutic purpose. Pericardiocentesis alone is inadequate for long-term palliation, with high recurrence rates. Surgery is usually reserved in cases of rapid accumulation or inadequate pericardiocentesis.¹² Adjuncts to pericardiocentesis such as sclerosing agents found no benefit but instead caused side effects leading to death.²

Pericardial fluid cytology has a better diagnostic value in detecting malignancy than pericardial biopsy.¹³ Pericardial fluid cytology has 100% specificity with varying sensitivity. Over half of pericardial fluid cytology in malignant patients have shown nonmalignant cells, likely caused by chemotherapy, radiation, or opportunistic infections.²

Malignant PE is usually a marker of advanced malignancy. The median survival for patients with positive malignant pericardial fluid cytology has been ranging from 7 to 15 weeks.^{2,12} Nonmalignant pericardial fluid cytology has a much higher median survival.

In conclusion, we present a case of malignant pericardial effusion with a fatal outcome. The case highlights the importance of understanding the likelihood of malignant pericardial effusion. Identifying irregular pericardial wall thickening and mediastinal lymph nodes on CT are markers of pericardial metastasis, coupled with malignant cells in pericardial fluid analysis suggest advanced disease.

ACKNOWLEDGMENTS

We thank the patient and her family for their patience and co-operation.

CONFLICT OF INTEREST

The authors have no conflicts of interest to declare.

AUTHOR CONTRIBUTIONS

AS, AS, and GN: involved with patient management; AS and GN: reviewed the inherent literature; AS: prepared the manuscript; AS, AS, and GN: edited the manuscript; all authors approved the final version of the manuscript.

ETHICAL STATEMENT

The need for ethics approval for this case report was waived.

WRITTEN INFORMED CONSENT

Written informed consent was obtained from the patient's daughter for publication of this case report and any accompanying images.

DATA AVAILABILITY STATEMENT

The data that support the findings of this study are available from the corresponding author upon request.

ORCID

Abid M. Sadiq  <https://orcid.org/0000-0002-7812-8042>

REFERENCES

- Braunwald E. Pericardial Disease. In: Kasper DL, Hauser SL, Jameson JL, Fauci AS, Longo DL, Loscalzo J, eds. *Harrison's Principles of Internal Medicine*, 19 edn. McGraw-Hill Education; 2015:1571-1577.
- Schusler R, Meyerson SL. Pericardial disease associated with malignancy. *Curr Cardiol Rep*. 2018;20(10):92. <https://doi.org/10.1007/s11886-018-1040-5>
- Ghosh AK, Crake T, Manisty C, Westwood M. Pericardial disease in cancer patients. *Curr Treat Options Cardiovasc Med*. 2018;20(7):60. <https://doi.org/10.1007/s11936-018-0654-7>.
- International Agency for Research in Cancer. *United Republic of Tanzania: Cancer Statistics*. 2019;pp 1–2; <https://gco.iarc.fr/today/data/factsheets/populations/834-tanzania-united-republic-of-factsheets.pdf>.
- Lyimo EP, Rumisha SF, Mremi IR, et al. Cancer mortality patterns in tanzania: a retrospective hospital-based study, 2006–2015. *JCO Glob Oncol*. 2020;6(6):224-232. <https://doi.org/10.1200/JGO.19.00270>.
- Griguolo G, Guarneri V. Cardiac Complications of Cancer and Anticancer Treatment. In: Pulla M, ed. *ESMO Handbook of Oncological Emergencies*, 2 edn. European Society for Medical Oncology; 2016:3-16.
- Jeon H, Cho D, Park J, et al. Prognostic factors affecting survival of patients with cancer-related pericardial effusion managed by surgery. *World J Surg Oncol*. 2014;12(1):249. <https://doi.org/10.1186/1477-7819-12-249>
- Noubiap JJ, Agbor VN, Ndoadougou AL, et al. Epidemiology of pericardial diseases in Africa: a systematic scoping review. *Heart*. 2019;105(3):180-188. <https://doi.org/10.1136/heartjnl-2018-313922>.
- Sun JS, Park KJ, Kang DK. CT findings in patients with pericardial effusion: differentiation of malignant and benign disease. *Am J Roentgenol*. 2010;194(6):489-494. <https://doi.org/10.2214/AJR.09.2599>.

10. Szturmowicz M, Pawlak-Ciešlik A, Fijałkowska A, et al. The value of the new scoring system for predicting neoplastic pericarditis in the patients with large pericardial effusion. *Support Care Cancer*. 2017;25(8):2399-2403. <https://doi.org/10.1007/s00520-017-3645-4>.
11. Adler Y, Charron P, Imazio M, et al. 2015 ESC Guidelines for the diagnosis and management of pericardial diseases. *Eur Heart J*. 2015;36(42):2921-2964. <https://doi.org/10.1093/eurheartj/ehv318>.
12. Gornik HL, Gerhard-Herman M, Beckman JA. Abnormal cytology predicts poor prognosis in cancer patients with pericardial effusion. *J Clin Oncol*. 2005;23(22):5211-5216. <https://doi.org/10.1200/JCO.2005.00.745>.
13. Dragoescu EA, Liu L. Pericardial fluid cytology: an analysis of 128 specimens over a 6-year period. *Cancer Cytopathol*. 2013;121(5):242-251. <https://doi.org/10.1002/ency.21246>.

How to cite this article: Sadiq AM, Sadiq AM, Nkya GZ. Advanced lung cancer presenting with malignant pericardial effusion. *Clin Case Rep*. 2021;9:e04179. <https://doi.org/10.1002/ccr3.4179>