

Received: 2017.03.08
Accepted: 2017.04.19
Published: 2017.05.12

Usefulness of Contrast-Enhanced Ultrasonography for Predicting Esophageal Varices in Patients with Hepatitis B Virus (HBV)-Related Cirrhosis

Authors' Contribution:
Study Design A
Data Collection B
Statistical Analysis C
Data Interpretation D
Manuscript Preparation E
Literature Search F
Funds Collection G

BCD 1,2 **Jun Li**
CEF 3 **Jin-Chun Feng**
AG 3 **Xin-Yu Peng**
AD 3 **Xiang-Wei Wu**
BC 2 **Ting-Ting Du**
BE 2 **Jia-Jia Wang**
BD 4 **Shu-Xin Tian**
AEG 2 **Gui-Lin Lu**

1 Department of Ultrasound, Tongji Hospital, Tongji Medical College, Huazhong University of Science and Technology, Wuhan, Hubei, P.R. China
2 Department of Ultrasound, The First Affiliated Hospital, Shihezi University School of Medicine, Shihezi, Xinjiang, P.R. China
3 Department of Hepatobiliary Surgery, The First Affiliated Hospital, Shihezi University School of Medicine, Shihezi, Xinjiang, P.R. China
4 Department of Gastroenterology-Hepatology, The First Affiliated Hospital, Shihezi University School of Medicine, Shihezi, Xinjiang, P.R. China

Corresponding Author: Gui-Lin Lu, e-mail: 15809930955@163.com

Source of support: This study was funded by the Science and Technology Program of the Xinjiang Production and Construction Corps (2014AB051)

Background: The aim of this study was to investigate the usefulness of contrast-enhanced ultrasonography (CEUS) in predicting of esophageal varices (EV) and assessing high-risk EV in patients with hepatitis B virus (HBV)-related cirrhosis.


Material/Methods: Patients with HBV-related cirrhosis who had undergone endoscopy were prospectively recruited. Hepatic dynamic CEUS was performed. Regions of interest (ROI) were drawn on the hepatic artery, hepatic vein, portal vein, and liver parenchyma to measure the corresponding features, such as arrival times. Spearman's correlation analysis was used to determine the relations between several dynamic CEUS features and the degree of EV. Receiver operating characteristics (ROC) curves were constructed to investigate the diagnostic performance of CEUS in assessing the presence of EV and high-risk EV.

Results: Fifty-eight patients (44 men; mean age 51.3 years) were included in this study. Of these, 18 (31.0%), 12 (20.7%), 11 (19.0%), and 17 (29.3%) of patients had grade 0, 1, 2, and 3 EV, respectively. Grade 2 and grade 3 EV were considered high-risk EV. Among the CEUS features, the area under the ROC curves of intrahepatic transit time (HV-HA, i.e., the difference between hepatic vein arrival time and hepatic artery arrival time) both for assessment of the presence of EV and high-risk EV (0.883 and 0.915, respectively) were larger than the other indices. HV-HA was negatively correlated with the grade of EV. An HV-HA of under 8.2 s indicated the presence of EV and under 7 s indicated high-risk EV.

Conclusions: Dynamic CEUS imaging is useful in assessing the presence of EV and high-risk EV in patients with HBV-related cirrhosis.


MeSH Keywords: **Esophageal and Gastric Varices • Liver Cirrhosis • Ultrasonography**

Full-text PDF: <http://www.medscimonit.com/abstract/index/idArt/904227>

 2586

 5

 3

 37



Background

Cirrhosis is a global public health concern that results from chronic liver damage due to viral infection, alcohol abuse, autoimmune disease, and non-alcoholic steatohepatitis [1]. In cirrhotic patients, the development of esophageal varices (EV) is one of the major complications. Its prevalence is 30–60% [2,3]. Moreover, gastroesophageal variceal hemorrhage occurs in 5–15% of patients with EV [4]. The mortality rate of patients with initial episodes of variceal hemorrhage is up to 20%, and the recurrence rate of bleeding in survivors is high [5,6]. Therefore, screening endoscopy for EV in all patients with cirrhosis is recommended in the current guidelines to identify patients who need prophylactic treatment [7].

However, at any given point in time, approximately 75% to 85% of cirrhotic patients undergoing endoscopy have no EV or only have mild EV, which do not need medical intervention [8]. Therefore, all patients with cirrhosis undergoing periodic endoscopy might unnecessarily increase the burden for both the medical service and patients. Nevertheless, endoscopy is invasive, uncomfortable, and requires anesthesia. Accordingly, in recent years, alternative ways to predict EV, such as those that use spleen length, Child-Pugh class, platelet count, portal vein diameter, elastography, or a combination of these indices, have been developed to reduce unnecessary endoscopy [8–14]. However, these reported indices were various and the cut-off values of the same index were different; therefore, the previous results are unreliable and further validation is necessary [10].

Recently, contrast-enhanced ultrasonography (CEUS) has been widely used in liver imaging, such as characterizing focal lesions. Compared with contrast-enhanced CT and contrast-enhanced MRI, CEUS is low cost [15,16], repeatable, safer, and can be controlled by operators in real-time during the measurements. Moreover, previous studies have demonstrated that hepatic dynamic CEUS features are correlated with severity of chronic liver diseases (CLD) [17], degree of liver fibrosis [18], and portal pressure [19,20]. In patients with cirrhosis, the occurrence of EV is a consequence of portal hypertension (PH). However, the usefulness of liver dynamic CEUS features for assessing the EV has not been evaluated.

The present study aimed to investigate the usefulness of CEUS in predicting esophageal varices (EV) and assessing high-risk EV in patients with HBV-related cirrhosis.

Material and Methods

Patients

Between Oct 2014 and Dec 2016, consecutive patients with HBV-related cirrhosis who had undergone endoscopy and agreed to participate in this study were recruited. The diagnosis of liver cirrhosis was based on liver biopsy according to the METAVIR scoring system. Patients had to meet the following inclusion criteria: (1) more than 18 years old; (2) the interval between endoscopy and CEUS imaging was less than 60 days; and (3) HBsAg-positive. Exclusion criteria were: (1) focal liver lesions; (2) a history of EV ligation or endoscopic injection sclerotherapy; (3) a use of vasoactive drugs within 2 weeks before the CEUS measurements; (4) portal vein thrombosis; (5) cavernous transformation of portal vein; (6) co-infection with HCV or HIV; and (7) a history of severe heart disease.

This study was approved by the institutional review board of the First Affiliated Hospital of Shihezi University School of Medicine. All participants signed a written informed consent.

CEUS measurements

HI VISION Ascendus (Hitachi Aloka Medical, Tokyo, Japan) with a C715 convex probe (1–5 MHz) was used in this study. A sonologist (Jun Li) with more than 10 years of experience in abdominal ultrasonography performed the CEUS. All of the participants fasted more than 8 h and were placed in the supine position with the right arm extended above the head. Conventional B-mode ultrasonography and Doppler ultrasonography were performed on the right lobe of the liver before the CEUS imaging in order to choose an appropriate cross-section that contained the hepatic artery, hepatic vein, and portal vein simultaneously.

CEUS was performed with a mechanical index of 0.09. Injection of contrast agent was administered by a single researcher (Ting-Ting Du). A bolus injection of 2.4 ml contrast agent (SonoVue; Bracco S.P.A., Milan, Italy) was administered through a 20-gauge catheter at the left antecubital fossa, followed by a rapid injection of 5 ml of normal saline. Dynamic contrast harmonic imaging was recorded from 10 s before SonoVue injection to 2 min after injection. The timer was started at the beginning of injection. Patients were requested to breathe gently during the process (Figure 1).

The software for CEUS image analysis was embedded in the ultrasound device. Regions of interest (ROIs) were drawn on the hepatic artery, hepatic vein, portal vein, and liver parenchyma. For the vessels, the ROIs were kept within the vascular structures, for the liver parenchyma, a ROI of 200 mm² was set approximately 5 cm to 8 cm in depth under the transducer

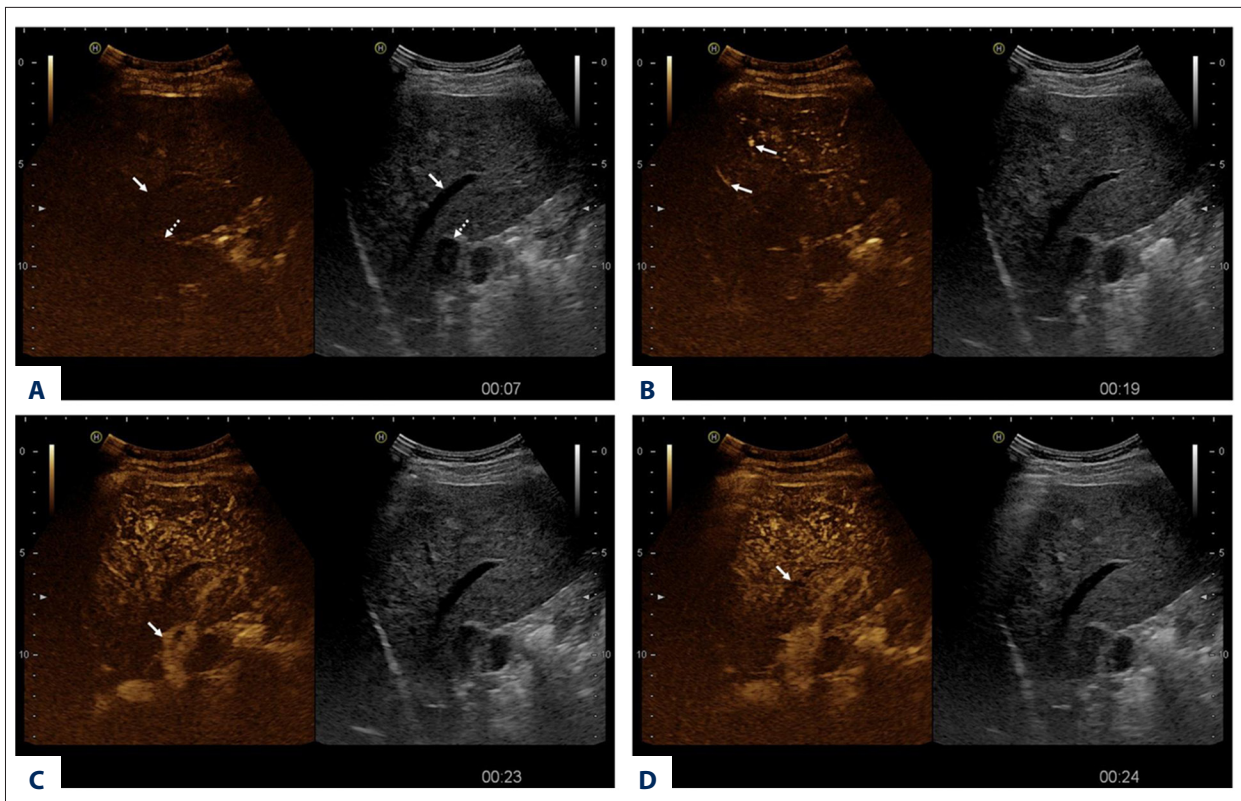


Figure 1. Typical phases of hepatic CEUS in a 57-year-old man with HBV-related cirrhosis without esophageal varices. Arrival times in the hepatic artery, portal vein, and hepatic vein were 15.5, 20.6, and 24.2 s, respectively. (A) Hepatic vein (arrow) and portal vein (dotted arrow) at baseline. (B) Contrast has arrived in the hepatic artery (arrows). (C) Contrast has arrived in the portal vein (arrow). (D) Contrast has arrived in the hepatic vein (arrow).

and more than 3 cm under the capsule, as well as to avoid including any large vascular structures. The motions in the video caused by breaths during the measurements were corrected by the motion-correction algorithms of the analysis software. All the ROIs which been drawn in the videos were checked by 2 of the authors to ensure that a time-intensity curve could be computed accurately. In the analysis software, the intensity of the CEUS image was expressed as grey-scale (range, 0 to 255). The time-intensity curve can be also quantified and outputted in Microsoft Excel for ease of interpretation and further analysis. The interface of the analysis software and corresponding time-intensity curves are shown in Figure 2.

The mean value of the first 10 s of the video (before the contrast agent injection) was defined as the baseline intensity. Hepatic artery arrival time (HAAT), hepatic vein arrival time (HVAT), and portal vein arrival time (PVAT) were defined as the interval between SonoVue injection and when the signal intensity exceeded 10% of the baseline in the corresponding ROI [19,21]. PSI was the difference between the peak signal intensity in the liver parenchyma and baseline intensity; moreover, TTP was defined as the time interval between injection and liver parenchyma peak time [18,21]. To lessen the impact

of variations in the blood circulation time, HV-HA (HVAT minus HAAT) and PV-HA (PVAT minus HAAT) were calculated [20,21]. The time from 10% to 90% of liver parenchyma peak signal intensity was expressed as the rise time [22].

Endoscopic assessment of EV

Endoscopy was performed by 1 of 4 gastroenterologists. EV was diagnosed according to the published criteria [23]: grade 0, no varices; 1, straight small varices; 2, beaded medium-sized varices; and 3, nodular, tortuous, and tumor-like large varices. The grades 0 and 1 EV patients were defined as a low-bleeding-risk group and grades 2 and 3 patients were considered at a high-risk of EV bleeding [24].

Statistical analysis

Data were presented as mean \pm standard deviation if they were normally distributed, or expressed as median (interquartile range). Data were compared between groups using Student *t*-test or χ^2 test, as appropriate. Correlations between CEUS features and EV grade were tested by Spearman's correlation coefficients. The area under the receiver operating

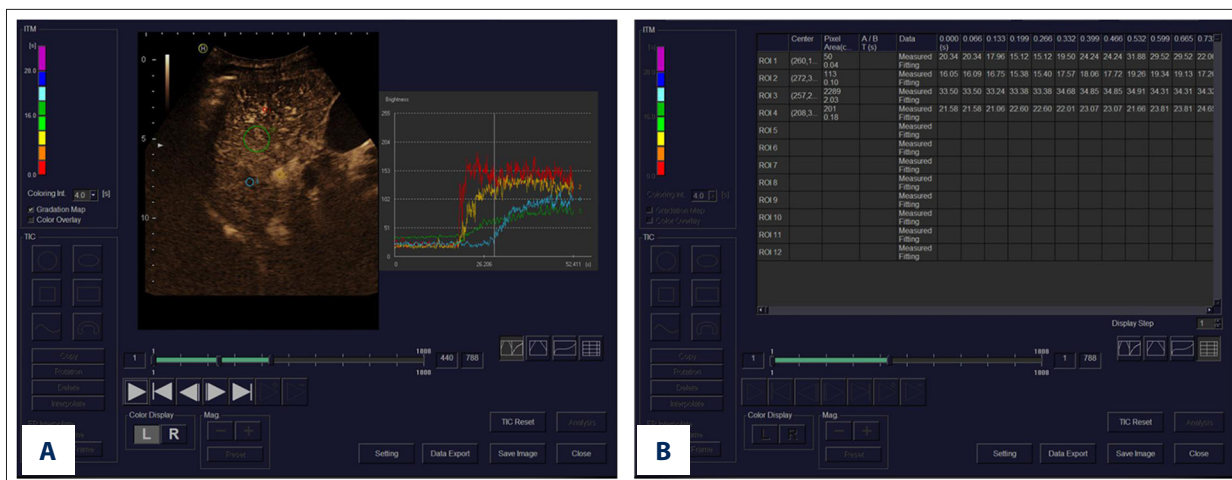

Figure 2. Interface of the analysis software. (A) Regions of interest (ROI) were drawn on the hepatic artery (red circle), hepatic vein (blue circle), portal vein (yellow circle), and liver parenchyma (green circle) to measure the corresponding features, and time-intensity curves are shown. (B) Corresponding quantitative data of the time-intensity curves from a 58-year-old cirrhotic man without esophageal varices.

Table 1. Characteristics of included participants.

Variable	All patients (n=58)	EV group and non-EV group			High- and low-risk group		
		Non-EV group (n=18)	EV group (n=40)	p value	Low-risk group (n=30)	High-risk group (n=28)	p value
Mean age, year (range)	51.3±7.6 (36–66)	49.8±7.6 (36–66)	51.9±7.5 (37–65)	0.321	49.7±6.9 (36–66)	52.9±8.0 (37–65)	0.104
sex, male/female	44/14	3m15d	11m29d	0.513	5m25d	9m19d	0.224
BMI (kg/m ²)	24.0±2.7	24.3±2.7	23.9±2.8	0.573	24.7±2.6	23.3±2.7	0.06
AST (U/L)	48.2±33.0	49.1±46.9	47.9±25.2	0.914	48.9±39.4	47.5±25.1	0.877
ALT (U/L)	59.0±51.2	61.9±67.5	57.7±42.9	0.775	64.6±59.2	53.0±41.2	0.395
Albumin (g/L)	31.9±6.0	36.6±3.2	29.8±5.7	<0.001	35.7±3.4	27.8±5.4	<0.001
Total bilirubin (umol/L)	21.0±9.3	14.4±2.0	23.9±9.8	<0.001	15.7±3.8	26.7±10.2	<0.001
Platelet count (10 ⁹ /L)	111.7±44.6	151.1±35.6	93.9±36.4	<0.001	137.9±37.3	83.5±33.6	<0.001
Prothrombin time (INR)	1.16±0.22	1.04±0.08	1.22±0.25	0.006	1.08±0.08	1.26±0.29	0.003
Child-Pugh score (range)	6.7±1.7 (5–11)	5.8±0.9 (5–8)	7.1±1.8 (5–11)	<0.001	5.9±1.1 (5–9)	7.6±1.9 (5–11)	<0.001
Child-Pugh class (A/B/C)	34/19/5	15/3/0	19/16/5	0.037	24/6/0	10/13/5	0.001

Data are given as mean ±SD. EV – esophageal varices; ALT – alanine aminotransferase; AST – aspartate aminotransferase; BMI – body mass index; INR – international normalized ratio.

characteristic curve (AUROC) was computed to explore the diagnostic performance of CEUS features. DeLong’s test was used for pairwise comparison of the AUROCs. SPSS 17.0 software (Chicago, IL) and Medcalc 12.7.0.0 software (Mariakerke, Belgium) were used in this study. P<0.05 was considered statistically significant.

Results

In this prospective study, CEUS was performed on 63 eligible patients; of them, 5 (7.9%) participants were excluded because of poor respiratory cooperation (n=3, 4.8%), rib shadow (n=1, 1.6%), and a severely atrophic liver (n=1, 1.6%). Finally, 58 patients were included in the data analysis and their characteristics are shown in Table 1. Of the 58 patients, 18 patients

Table 2. Results of CEUS features in different groups.

Variable	EV group and non-EV group			High- and low-risk group		
	Non-EV group (n=18)	EV group (n=40)	p value	Low-risk group (n=30)	High-risk group (n=28)	p value
Hepatic artery arrival time (s)	14.04±1.34	13.49±1.23	0.129	13.78±1.20	13.54±1.36	0.479
Portal vein arrival time (s)	18.04±2.38	19.26±2.18	0.061	18.21±2.14	19.61±2.27	0.019
Hepatic vein arrival time (s)	23.07±2.09	20.12±2.20	<0.001	22.40±2.02	19.58±2.25	<0.001
TTP (s)	34.33±4.55	32.28±6.75	0.245	33.92±4.57	31.84±7.49	0.214
HV-HA (s)	9.03±1.33	6.63±1.57	<0.001	8.62±1.31	6.04±1.39	<0.001
PV-HA (s)	4.00±2.01	5.77±2.13	0.004	4.43±1.79	6.07±2.39	0.004
Rise time (s)	15.69±4.88	15.58±5.94	0.945	15.81±4.50	15.40±6.64	0.79
PSI (grey-scale, range 0 to 255)	60.30±12.82	50.68±12.71	0.01	57.81±12.01	49.22±13.59	0.013

EV – esophageal varices; TTP – the time interval between injection and liver parenchyma peak time; HV-HA – the difference between hepatic vein arrival time and hepatic artery arrival time; PV-HA – the difference between portal vein arrival time and hepatic artery arrival time; Rise time – the time from 10% to 90% of liver parenchyma peak signal intensity; PSI – the difference between liver parenchyma peak signal intensity and baseline intensity.

Table 3. Correlation coefficients between the parameters and esophageal varices grade.

Features	Correlation coefficients (r)*	p value
Hepatic artery arrival time (s)	-0.031	0.817
Portal vein arrival time (s)	0.246	0.062
Hepatic vein arrival time (s)	-0.589	<0.001
TTP (s)	-0.166	0.213
HV-HA (s)	-0.737	<0.001
PV-HA (s)	0.296	0.024
Rise time (s)	-0.062	0.646
PSI (grey-scale, range 0 to 255)	-0.337	0.01

* Spearman correlation coefficients. TTP – the time interval between injection and liver parenchyma peak time; HV-HA – the difference between hepatic vein arrival time and hepatic artery arrival time; PV-HA – the difference between portal vein arrival time and hepatic artery arrival time; Rise time – the time from 10% to 90% of liver parenchyma peak signal intensity; PSI – the difference between liver parenchyma peak signal intensity and baseline intensity.

(31.0%) had no EV, and 12 (20.7%), 11 (19.0%), and 17 (29.3%) patients had grade 1, 2, and 3 EV, respectively. Age, body mass index, and sex were not significantly different between groups.

The obtained CEUS indices are shown in Table 2. Compared with the non-EV group, the HVAT, HV-HA, and PSI were significantly decreased in the EV groups ($P<0.001$, $P<0.001$, $P=0.010$, respectively), and PV-HA increased significantly ($P=0.024$). Similar results were observed in the high-risk group compared with the low-risk group ($P<0.001$ for HVAT, $P<0.001$ for HV-HA, $P=0.013$ for PSI, respectively). Furthermore, PVAT increased

significantly in the high-risk group compared with the low-risk group ($P=0.019$).

The correlations of the indices with EV grade are shown in Table 3. HVAT, HV-HA, and PSI were negatively correlated with the grade of EV. On the contrary, PV-HA was positively correlated with EV grade.

ROC curves were computed to evaluate the diagnostic performance of features with significant correlation with the grade of EV (Table 4, Figure 3). For the assessment of the presence of

Table 4. Diagnostic performance of contrast-enhanced ultrasonography in assessing the presence of esophageal varices and high-risk esophageal varices.

Features	AUC (95% Confidence Interval)	Cut-off Value	Sensitivity (%)	Specificity (%)	+LR	-LR	PPV (%)	NPV (%)	Accuracy (%)
Presence of esophageal varices									
Hepatic vein arrival time	0.838 (0.718 to 0.922)	≤22s	85.00	72.22	3.06	0.21	87.18	68.42	81.03
HV-HA	0.883 (0.771 to 0.952)	≤8.2s	85.00	77.78	3.83	0.19	89.48	70.00	82.76
PV-HA	0.726 (0.593 to 0.835)	≥5.4s	60.00	77.78	2.70	0.51	85.72	46.66	48.28
PSI	0.710 (0.516 to 0.821)	≤67.5	95.00	38.89	1.55	0.13	77.56	77.77	77.59
High-risk esophageal varices									
Hepatic vein arrival time	0.840 (0.720 to 0.923)	≤20.8s	82.14	80.00	4.11	0.22	79.31	82.75	81.03
HV-HA	0.915 (0.812 to 0.972)	≤7.0s	82.14	90.00	8.21	0.20	88.46	84.37	86.21
PV-HA	0.714 (0.581 to 0.825)	≥5.4s	67.86	70.00	2.26	0.46	67.86	70.00	51.72
PSI	0.672 (0.536 to 0.790)	≤43	42.86	90.00	4.29	0.63	80.00	62.79	65.12

HV-HA – the difference between hepatic vein arrival time and hepatic artery arrival time; PV-HA – the difference between portal vein arrival time and hepatic artery arrival time; PSI – the difference between liver parenchyma peak signal intensity and baseline intensity; +LR – positive likelihood ratio; -LR – negative likelihood ratio; PPV – positive predictive value; NPV – negative predictive value; the unit of PSI is grey-scale.

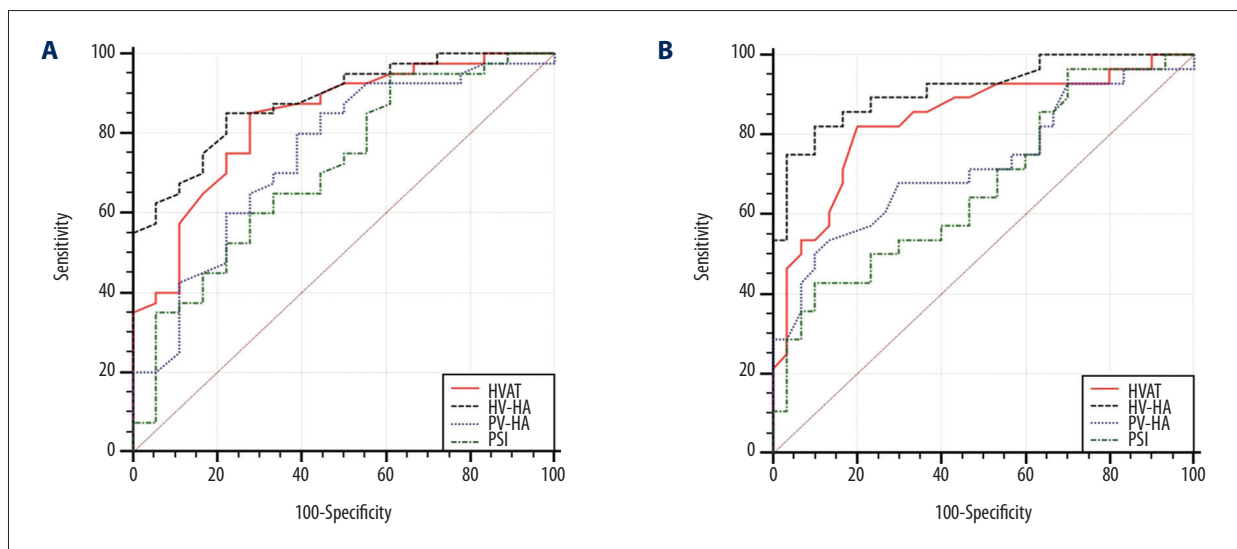


Figure 3. Receiver operating characteristic curves of contrast-enhanced ultrasound parameters for assessing presence of: (A) esophageal varices and (B) high-risk esophageal varices. HVAT, hepatic vein arrive time; HV-HA – the difference between hepatic vein arrive time and hepatic artery arrive time; PV-HA – the difference between portal vein arrive time and hepatic artery arrive time; PSI – the difference between liver parenchyma peak signal intensity and baseline intensity.

Table 5. Proportion of misdiagnosed patients when the optimal cut-offs were applied.

	Hepatic vein arrival time	HV-HA	PV-HA	PSI
Presence of esophageal varices				
True-positive	34	34	24	38
True-negative	13	14	14	7
False-positive	5	4	4	11
False-negative	6	6	16	2
High-risk esophageal varices				
True-positive	23	23	19	11
True-negative	24	27	21	27
False-positive	6	3	9	3
False-negative	5	5	9	17

HV-HA – the difference between hepatic vein arrival time and hepatic artery arrival time; PV-HA – the difference between portal vein arrival time and hepatic artery arrival time; PSI – the difference between liver parenchyma peak signal intensity and baseline intensity.

EV and high-risk EV, the AUROCs of HV-HA were greater than that of the other indices. For the diagnosis of the presence of EV, the AUROC was 0.883, and the optimal cut-off value of HV-HA was 8.2 seconds with a sensitivity of 85% and a specificity of 78%. For the diagnosis of high-risk EV, the AUROC was 0.915, and the optimal cut-off value of HV-HA was 7.0 s with a sensitivity of 82% and a specificity of 90%. In this case, the false-positive and false-negative rates of HV-HA were relatively low (Table 5).

In pairwise comparison of the AUROCs, for evaluating the presence of EV, the differences between features were not significant; for the evaluation of high-risk EV, HV-HA allowed better assessment of high-risk EV compared with HVAT, PV-HA, and PSI ($P=0.006$, $P=0.009$, $P=0.006$, respectively). No significant differences were found between the other features.

Discussion

CEUS is widely used in CLD patients, such as in assessing the severity of liver fibrosis and PH [18,19], and theoretically, CEUS features may correlate with EV. Under this assumption, we conducted a pilot study utilizing CEUS to predict the presence of EV and high-risk EV to relieve the burden on patients and medical service providers by reducing unnecessary endoscopy. This study focused on cirrhotic patients with HBV and showed that several CEUS features were closely correlated with the grade of EV; moreover, the HV-HA index had the best diagnostic performance.

HVAT has been reported in previous studies to be useful for evaluating portal pressure and staging liver fibrosis [19,25], because the structure of intrahepatic vasculature is changed by

fibrous tissue, leading to arteriovenous shunting [19,25], and to some extent, arteriovenous shunting and arterIALIZATION of the sinusoidal bed, which may elevate the portal pressure [19]. EV as a result of PH was developed to relieve the high portal pressure and help the obstructed portal venous system to bypass the liver and flow into the systemic circulation. Therefore, earlier HVAT could reflect PH and EV. This study showed that the HVAT was closely negatively correlated with the grade of EV ($r=-0.589$, $P<0.001$); therefore, HVAT can be a good indicator for predicting the presence of EV and assessing high-risk EV (AUROC: 0.838 and 0.840), with the cut-off values of 22 s and 20.8 s, respectively. However, HVAT is vulnerable to patient individual circulation time, how the contrast agent is injected, and when the timer is started. In clinical practice, HVAT is easy to perform but is less reliable than HV-HA.

The HV-HA index had been used in many studies to correct the differences of participants' blood circulation time [20,21,26]. As expected, the AUROCs of HV-HA was larger than that of HVAT (0.883 vs. 0.838 for assessing presence of EV and 0.915 vs. 0.840 for assessing high-risk EV). Previous studies consistently reported that HV-HA is a valuable index in assessing liver fibrosis and PH [21,25,27]. Using HV-HA to assess the grade of EV may broaden its application. In addition, this index seems to be more reliable than HVAT and is also feasible as a clinical tool.

The correlation between PVAT and grade of EV was not significant. Moreover, although PV-HA was significantly correlated with EV grade ($r=0.296$, $P=0.024$), its performance was insufficient for assessing the presence of EV and high-risk EV (AUROC, 0.726 and 0.714, respectively).

PSI was negatively correlated with the degree of EV ($r=-0.337$, $P=0.010$). We hypothesized that this CEUS feature would tend to reflect the blood content of the liver in the different stages of CLD. The liver is rich in blood, like a blood-pool; however, fibrosis and regenerative nodules increase with the progression of CLD; therefore, the blood-pool space is reduced. In the CEUS images, reduced content of microbubble-filled blood-pool produces a reduction in signal intensity. On the other hand, although not conclusive, hepatic arterial buffer response may decrease when the compensation of collateral circulation reaches a peak [22]. The decreased blood perfusion results in a lower signal intensity. The AUROCs of PSI were 0.710 for assessing the presence of EV and 0.672 for evaluating the high-risk EV. Compared with HV-HA, the diagnostic accuracy of PIS was significantly lower ($P=0.006$).

TTP and rise time did not play a role in the present study. TTP has been used to evaluate the severity of PH in cirrhosis, but its performance was unsatisfactory [21]. In addition, another study reported a disappointing result of rise time for assessing PH in patients with cirrhosis [22].

Numerous noninvasive methods for assessing EV have been reported. Although spleen length and portal vein diameter are easy to measure, a systematic review showed that they are not accurate enough to predict EV [28]. Laboratory tests are correlated with the grade of EV, but are not sufficient [29]. Serum tests are popular to use in diagnosing EV of liver cirrhosis, but the indexes, including APRI, AAR, FIB-4, Lok, and Forns scores, had low-to-moderate diagnostic accuracy in predicting EV in liver cirrhosis [30,31]. On the other hand, CT was reported to diagnose EV in liver cirrhosis with high accuracy [32], but CT cannot be used for patients with renal failure due to the adverse effect of radiocontrast agent. In addition, CT has high cost, static imaging (non-dynamic), and radioactive by-effects. In addition, MRI [33] is not a dynamic imaging system, which was reported as "the robustness of PV flow measurement on only 1 slice at a specific time point". Moreover, these methods can be affected by factors unrelated to the liver [1]. Doppler indexes have been used to diagnose EV for many years, but the results are unsatisfactory even today [28]. Liver stiffness measured by transient elastography showed a good correlation with the severity of EV, and this approach is simple and reproducible. However, the cut-off values vary between studies (range, 13.9 kPa to 21.5 kPa for predicting the presence of EV); thus, it has not been used in clinical practice [34]. Qiu et al. [35] examined the lower esophagus by CEUS directly and found the thickness of mucosa and submucosa was strongly correlated with the grade of EV, with an AUROC of 0.987 for detecting large EV (the criteria

for EV grade were not provided). This approach is direct and interesting, but has a few disadvantages: it cannot detect the middle and upper esophagus, and it is vulnerable to overlying gastrointestinal gas; in addition, the contraction of the lower esophageal sphincter in the resting state may squash the varicose esophageal veins. Qiu et al. [35] included 25 control participants, and 9, 13, and 34 patients with small, medium, and large EV, respectively, but did not include cirrhotic patients without EV. To some extent, this proportion of patients may increase the diagnostic performance. In addition, the number of participants was small and further studies are needed to confirm this approach. Compared with the above-mentioned techniques, intrahepatic transit time (i.e., HV-HA) was accurate, easy to detect, widely studied, and directly and closely correlated with the distortion of hepatic vascular architecture that may lead to PH and EV.

In this study, the interval between endoscopy and CEUS imaging was limited to within 60 days. According to previous studies on noninvasive assessment of EV, a 180-day interval is considered acceptable [36,37]. Good respiratory cooperation was needed in this CEUS imaging process in order to avoid losing the target vessel, especially near the arrival time. Although participants had been briefly trained before the measurement, a 4.8% failure rate was still obtained. To the best of our knowledge, manual injection of the contrast agent was the common method in CEUS imaging; however, a mechanical device may be more accurate and feasible in clinical work.

This pilot study has some limitations. First, the sample size of this study was small. Large sample sizes and multi-center studies with various etiologies are needed. Second, all the CEUS imaging data were analyzed by 1 researcher; thus, reader variability may be a drawback of this study. However, the process for CEUS imaging analysis in this study was standardized and the results were computed automatically, thereby minimizing variability between different readers.

Conclusions

In conclusion, dynamic CEUS may be used for the assessment of EV, and HV-HA is the best index in predicting EV. Considering the results of previous studies, HV-HA may provide a comprehensive assessment for patients with CLD in many aspects, such as the degree of fibrosis, the severity of PH, and the grade of EV. Although dynamic CEUS imaging may not replace endoscopy completely, this technique is helpful in evaluating whether patients with HBV-related cirrhosis, particularly those who present a high risk of EV, should undergo endoscopy.

References:

1. Ferraioli G, Filice C, Castera L et al: WFUMB guidelines and recommendations for clinical use of ultrasound elastography: Part 3: Liver. *Ultrasound Med Biol*, 2015; 41: 1161-79
2. Bosch J, Berzigotti A, Garcia-Pagan JC, Abraldes JG: The management of portal hypertension: Rational basis, available treatments and future options. *J Hepatol*, 2008; 48(Suppl. 1): S68-92
3. Merli M, Nicolini G, Angeloni S et al: Incidence and natural history of small esophageal varices in cirrhotic patients. *J Hepatol*, 2003; 38: 266-72
4. Jensen DM: Endoscopic screening for varices in cirrhosis: Findings, implications, and outcomes. *Gastroenterology*, 2002; 122: 1620-30
5. Carbonell N, Pauwels A, Serfaty L et al: Improved survival after variceal bleeding in patients with cirrhosis over the past two decades. *Hepatology*, 2004; 40: 652-59
6. Chalasani N, Kahi C, Francois F et al: Improved patient survival after acute variceal bleeding: a multicenter, cohort study. *Am J Gastroenterol*, 2003; 98: 653-59
7. Garcia-Tsao G, Sanyal AJ, Grace ND, Carey W: Practice Guidelines Committee of the American Association for the Study of Liver Diseases; Practice Parameters Committee of the American College of Gastroenterology. Prevention and management of gastroesophageal varices and variceal hemorrhage in cirrhosis. *Hepatology*, 2007; 46: 922-38
8. Kim BK, Han KH, Park JY et al: A liver stiffness measurement-based, noninvasive prediction model for high-risk esophageal varices in B-viral liver cirrhosis. *Am J Gastroenterol*, 2010; 105: 1382-90
9. Barrera F, Riquelme A, Soza A et al: Platelet count/spleen diameter ratio for non-invasive prediction of high risk esophageal varices in cirrhotic patients. *Ann Hepatol*, 2009; 8: 325-30
10. Berzigotti A, Gilabert R, Abraldes JG et al: Noninvasive prediction of clinically significant portal hypertension and esophageal varices in patients with compensated liver cirrhosis. *Am J Gastroenterol*, 2008; 103: 1159-67
11. Castéra L, Le Bail B, Roudot-Thoraval F et al: Early detection in routine clinical practice of cirrhosis and oesophageal varices in chronic hepatitis C: Comparison of transient elastography (FibroScan) with standard laboratory tests and non-invasive scores. *J Hepatol*, 2009; 50: 59-68
12. Kazemi F, Kettaneh A, N'kontchou G et al: Liver stiffness measurement selects patients with cirrhosis at risk of bearing large oesophageal varices. *J Hepatol*, 2006; 45: 230-35
13. Sharma SK, Aggarwal R: Prediction of large esophageal varices in patients with cirrhosis of the liver using clinical, laboratory and imaging parameters. *J Gastroenterol Hepatol*, 2007; 22: 1909-15
14. Shin SU, Lee JM, Yu MH et al: Prediction of esophageal varices in patients with cirrhosis: Usefulness of three-dimensional MR elastography with echo-planar imaging technique. *Radiology*, 2014; 272: 143-53
15. Isik A, Soyuturk M, Süleyman S et al: Correlation of bowel wall thickening seen using computerized tomography with colonoscopies: A preliminary study. *Surg Laparosc Endosc Percutan Tech*, 2017 [Epub ahead of print]
16. Isik A, Gursul C, Peker K et al: Metalloproteinases and their inhibitors in patients with inguinal hernia. *World J Surg*, 2017; 41(5): 1259-66
17. Liu D, Qian L, Wang J et al: Hepatic perfusion parameters of contrast-enhanced ultrasonography correlate with the severity of chronic liver disease. *Ultrasound Med Biol*, 2014; 40: 2556-63
18. Orlacchio A, Bolacchi F, Petrella MC et al: Liver contrast enhanced ultrasound perfusion imaging in the evaluation of chronic hepatitis C fibrosis: preliminary results. *Ultrasound Med Biol*, 2011; 37: 1-6
19. Kim MY, Suk KT, Baik SK et al: Hepatic vein arrival time as assessed by contrast-enhanced ultrasonography is useful for the assessment of portal hypertension in compensated cirrhosis. *Hepatology*, 2012; 56: 1053-62
20. Zhang CX, Hu J, Hu KW et al: Noninvasive analysis of portal pressure by contrast-enhanced sonography in patients with cirrhosis. *J Ultrasound Med*, 2011; 30: 205-11
21. Jeong WK, Kim TY, Sohn JH et al: Severe portal hypertension in cirrhosis: Evaluation of perfusion parameters with contrast-enhanced ultrasonography. *PLoS One*, 2015; 10: e0121601
22. Qu EZ, Zhang YC, Li ZY et al: Contrast-enhanced sonography for quantitative assessment of portal hypertension in patients with liver cirrhosis. *J Ultrasound Med*, 2014; 33: 1971-77
23. Chinese Medical Association: Trial scheme of diagnosing and treating gastroesophageal varices under endoscopy (2003). *Chin J Dig Endosc*, 2004; 21: 149-51
24. Beppu K, Inokuchi K, Koyanagi N et al: Prediction of variceal hemorrhage by esophageal endoscopy. *Gastrointest Endosc*, 1981; 27: 213-18
25. Lim AK, Taylor-Robinson SD, Patel N et al: Hepatic vein transit times using a microbubble agent can predict disease severity non-invasively in patients with hepatitis C. *Gut*, 2005; 54: 128-33
26. Sugimoto H, Kaneko T, Hirota M et al: Earlier hepatic vein transit-time measured by contrast ultrasonography reflects intrahepatic hemodynamic changes accompanying cirrhosis. *J Hepatol*, 2002; 37: 578-83
27. Li N, Ding H, Fan P et al: Intrahepatic transit time predicts liver fibrosis in patients with chronic hepatitis B: Quantitative assessment with contrast-enhanced ultrasonography. *Ultrasound Med Biol*, 2010; 36: 1066-75
28. Binjınan A, Chira RI, Mircea PA: Non-invasive ultrasound-based diagnosis and staging of esophageal varices in liver cirrhosis. A systematic review of the literature published in the third millennium. *Med Ultrason*, 2013; 15: 116-24
29. de Franchis R, Dell'Era A: Invasive and noninvasive methods to diagnose portal hypertension and esophageal varices. *Clin Liver Dis*, 2014; 18: 293-302
30. Deng H, Qi X, Peng Y et al: Diagnostic accuracy of APRI, AAR, FIB-4, FI, and King Scores for diagnosis of esophageal varices in liver cirrhosis: A retrospective study. *Med Sci Monit*, 2015; 21: 3961-77
31. Deng H, Qi X, Guo X: Diagnostic accuracy of APRI, AAR, FIB-4, FI, King, Lok, Forns, and Fibrolindex Scores in predicting the presence of esophageal varices in liver cirrhosis: A systematic review and meta-analysis. *Medicine (Baltimore)*, 2015; 94(42): e1795
32. Han D, Xingshun Q, Xiaozhong G: Computed tomography for the diagnosis of varices in liver cirrhosis: A systematic review and metaanalysis of observational studies. *Postgrad Med*, 2017; 129: 318-28
33. Morisaka H, Motosugi U, Ichikawa T et al: MR-based measurements of portal vein flow and liver stiffness for predicting gastroesophageal varices. *Magn Reson Med Sci*, 2013; 12(2): 77-86
34. Castéra L, Pinzani M, Bosch J: Non invasive evaluation of portal hypertension using transient elastography. *J Hepatol*, 2012; 56: 696-703
35. Qiu L, Zhang X, Liu D et al: Contrast-enhanced ultrasonography diagnostic evaluation of esophageal varices in patients with cirrhosis. *Ultrasound Q*, 2016; 32: 136-43
36. Morishita N, Hiramatsu N, Oze T et al: Liver stiffness measurement by acoustic radiation force impulse is useful in predicting the presence of esophageal varices or high-risk esophageal varices among patients with HCV-related cirrhosis. *J Gastroenterol*, 2014; 49: 1175-82
37. Tamosiunas A, Speiciene D, Irnius A et al: Application of color doppler ultrasound for diagnosis of liver cirrhosis gastroesophageal varices. *Med Sci Monit*, 1999; 5(5): MT966-69