

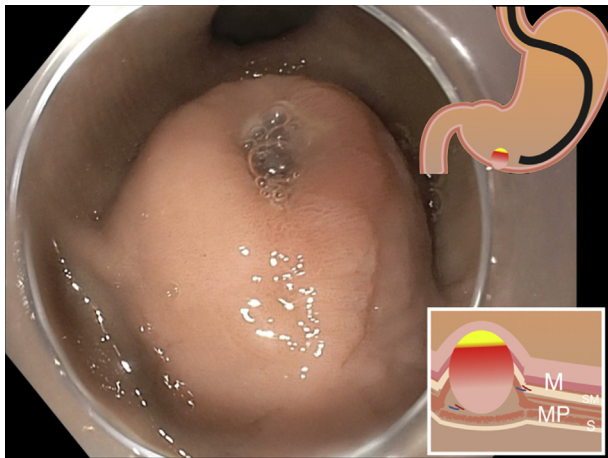
# Managing endoscopic challenges on the road to resect a large ulcerated gastric GI stromal tumor



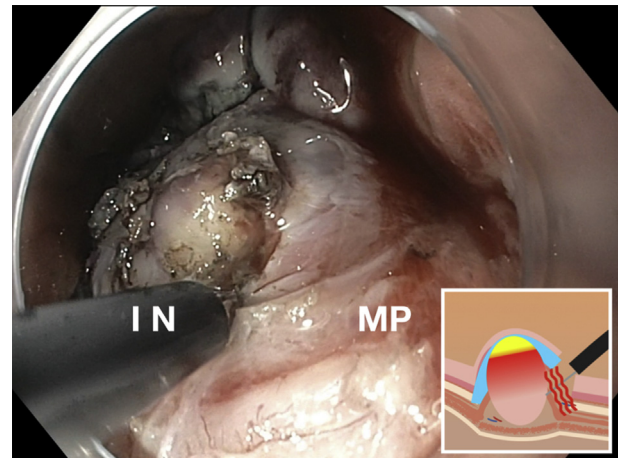
Jorge Perales, MD, Kavel Visrodia, MD, Amrita Sethi, MD, FASGE

Gastrointestinal stromal tumors (GISTs) are the most common mesenchymal neoplasm in the GI tract. The classic presentation is of a gastric submucosal bulge with normal mucosa on EGD, arising from the fourth layer (muscularis propria) on EUS. The overlying mucosa can be completely normal or can present with ulceration that

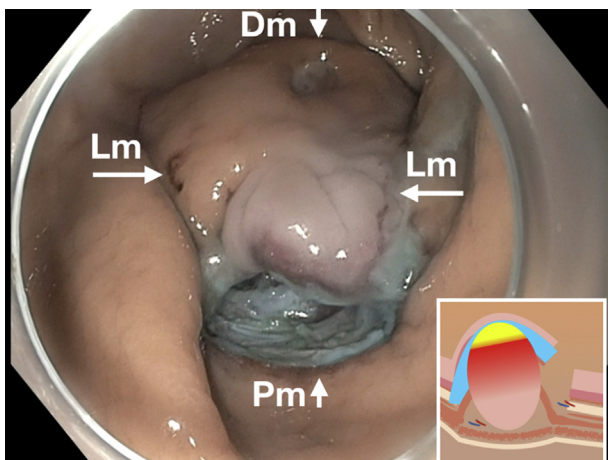
causes obscure bleeding, resulting in iron-deficiency anemia. When the lesion is >2 cm or symptomatic, it can be considered for either surgical or endoscopic resection.<sup>1,2</sup> Other possible high-risk features are irregular borders, echogenic foci, anechoic spaces, lymph nodes, and rapid growth during follow-up.<sup>3,4</sup>



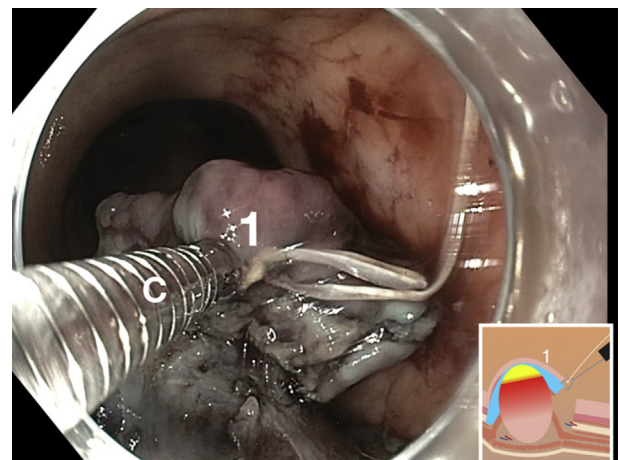
**Figure 1.** Tumor with central ulceration within the wall of the distal body arising from the muscularis propria. EUS measures 3.5 cm × 2.2 cm.



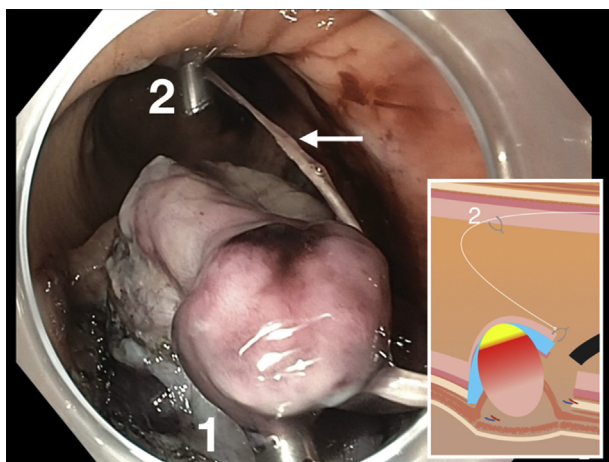
**Figure 3.** As the submucosal endoscopic excavation on the muscularis propria (MP) was performed, oozing bleeding from the tumor occurred and was successfully treated with epinephrine using an endoscopic injection needle (IN).



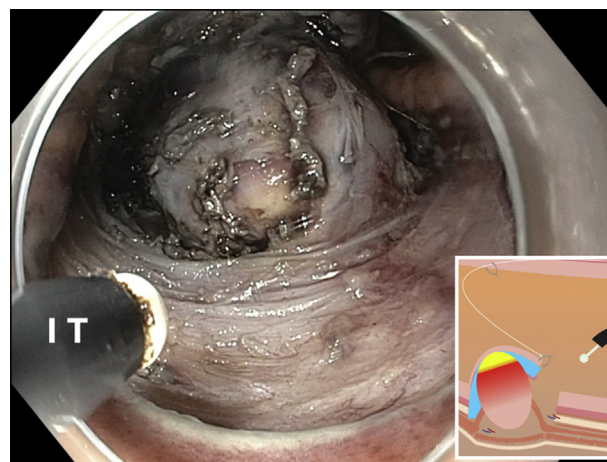**Figure 2.** After delimiting the distal (Dm) and proximal (Pm) margins, lateral incisions were made to limit the lateral edges of the lesion (Lm) and perform endoscopic submucosal dissection, excavation, and finally exposed resection.



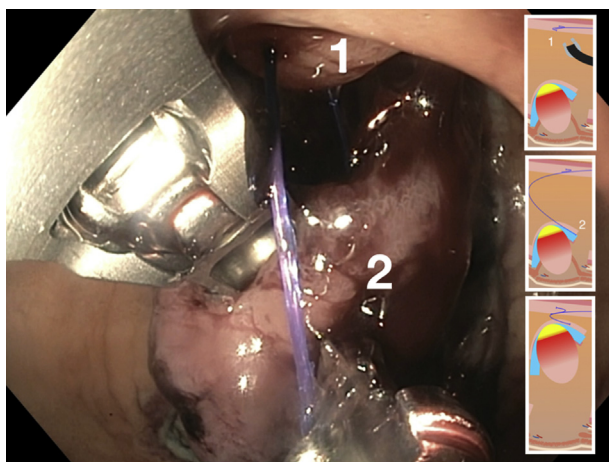
**Figure 4.** At first, the clip-in-line technique was used with the first hemoclip (C,1) tied with dental floss placed at the mucosal flap



**Figure 5.** A second hemoclip (2) was placed at the contralateral gastric wall (lesser curve), and the line (arrow) was pulled transorally to expose the tumor base (1, first hemoclip).



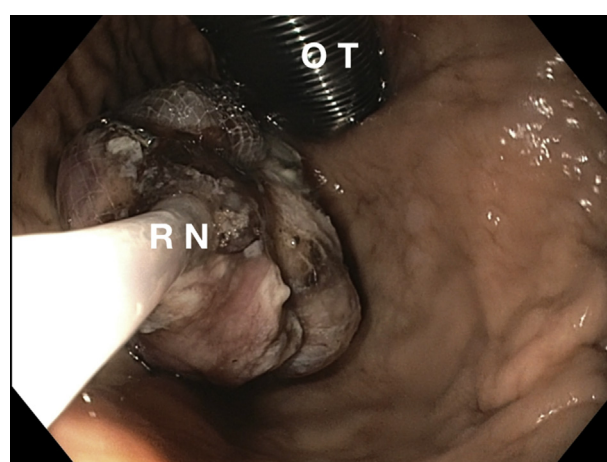
**Figure 6.** The clip-in-line technique with dental floss provided adequate exposure for a few minutes. A second attempt at countertraction then was performed with sutures using the endoscopic suturing device in a similar fashion (1, first stitch on contralateral wall. 2, second stitch on lesion).



**Figure 7.** With adequate exposure, the submucosal excavation on the muscularis propria was continued with an insulated tip knife (IT).

Endoscopic submucosal dissection (ESD) is a technique that facilitates the resection of lesions involving the mucosal and superficial submucosal layers, leaving the muscularis propria (MP) intact to maintain the integrity of the GI wall; hence, stromal tumors arising from the MP were considered a contraindication for endoscopic resection. Therefore, endoscopic techniques have been developed from ESD principles and are proven to be effective and safe to treat these tumors. They include submucosal tunneling endoscopic resection, exposed endoscopic full-thickness resection, and endoscopic submucosal excavation (ESE).<sup>5-7</sup> The major difference between ESD and ESE is the depth of resection. During ESE, an insulated-tip knife is usually recommended to avoid or reduce unintentional injury to the MP, whereas in ESD, dual knife and hook knife can be used.<sup>8</sup>

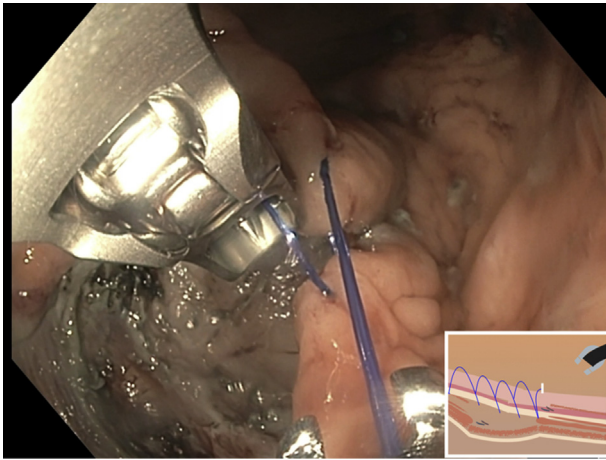
Challenges to endoscopic resection can include bleeding, perforation, and incomplete resection, often



**Figure 8.** En bloc resection of the tumor was completed. We attempted to directly pull the specimen transorally with the suture placed for countertraction but could not traverse the upper esophageal sphincter. An overtube (OT) was inserted to achieve successful retrieval with a foreign body Roth net (RN) holding the specimen.

because of technical factors, such as poor distinction of tissue planes from scarring of previous biopsy, difficult location, and larger size.<sup>1,9,10</sup> Rapid management of these issues may require innovative use of available devices to perform techniques for hemostasis, traction, closure, and extraction to achieve successful and safe resection.<sup>10-12</sup> Currently, endoscopic resection is not a common practice worldwide because it is technically demanding and may carry a greater risk of recurrence or metastasis if complete resection is not achieved; therefore, surgery continues to be standard in most centers.<sup>13</sup>

We report a case of endoscopic resection of an ulcerated, bleeding, gastric GIST in a 77-year-old woman, which resulted in symptomatic anemia requiring multiple transfusions. The lesion had been diagnosed 4 years earlier as an



**Figure 9.** After specimen retrieval, the mucosal defect was fully closed with running suture using the endoscopic suturing device.

incidental finding in the gastric body; it was hypoechoic, arising from muscularis mucosae on the EUS examination, 19 × 16 mm in size, and had no other high-risk features.<sup>2,4</sup> Given an increase in size, fine-needle biopsy was used to confirm a GIST (c-Kit+) and ulceration with bleeding. Therefore, resection was recommended; the patient elected for an endoscopic approach.

In this case, ulcerated mucosa prevented the submucosal tunneling endoscopic resection approach (Fig. 1). Therefore, an ESE with creation of a mucosal flap was planned and avoided cutting through ulcerated mucosa. Distal and limited lateral incisions were made, resulting in a mucosal flap above the lesion (Fig. 2). Submucosal dissection was used initially to expose the tumor base, which was found at the MP, not muscularis mucosae. The location along the greater curve and size prevented the use of gravity to assist with dissection. Significant bleeding from the tumor capsule occurred and was controlled by epinephrine injection into the tumor itself (Fig. 3). Countertraction was achieved using the clip-in-line technique (Figs. 4 and 5) and an endoscopic suturing device (Fig. 6) with help of the created mucosal flap.<sup>10,12</sup> This allowed for the exposure of the planes and full resection of the lesion preserving the serosa (Fig. 7). Extraction was achieved with the use of an overtube and a foreign body net (Fig. 8). The resection bed was closed using the endoscopic suturing system (Fig. 9).

The patient was started on a clear diet and was discharged after 2 days with no adverse events. Final pathology reported an epithelioid type GIST, low histological grade, mitotic count of <5 per high power fields, size of 2.5 × 2.4 × 2 cm, with a 0.1-cm free margin (R0). The resolution of this case combined endoscopic resection techniques that have been proven to be effective and safe. Every difficulty that occurred was successfully resolved by keeping in mind the available toolbox at all times (Video 1, available online at [www.VideoGIE.org](http://www.VideoGIE.org)).

## DISCLOSURE

*Dr Perales received the 2019 Endoscopic Training award from the American Society for Gastrointestinal Endoscopy. Dr Sethi is a consultant for Boston Scientific, Olympus America, and Fujifilm Medical Systems. All other authors disclosed no financial relationships.*

*Abbreviations: ESD, endoscopic submucosal dissection; ESE, endoscopic submucosal excavation; GIST, gastrointestinal stromal tumor; MP, muscularis propria.*

## REFERENCES

1. Van Weyenberg SJB, Pohl J. Gastric gastrointestinal stromal tumor. *VideoGIE* 2013;1:168-9.
2. Riphaut A, Pech O, Steckstor M, et al. Gastrointestinal stromal tumors (GIST) – endoscopic image, endoscopic ultrasound, and value of endoscopic-guided fine-needle aspiration. *VideoGIE* 2013;1:183-4.
3. Akahoshi K, Oya M, Koga T, et al. Current clinical management of gastrointestinal stromal tumor. *World J Gastroenterol* 2018;24:2806-17.
4. Chen H, Li B, Li L, et al. Current status of endoscopic resection of gastric subepithelial tumors. *Am J Gastroenterol* 2019;114:718-25.
5. Aslanian HR, Sethi A, Bhutani MS, et al. ASGE guideline for endoscopic full-thickness resection and submucosal tunnel endoscopic resection. *VideoGIE* 2019;4:343-50.
6. Huang LY, Cui J, Lin SJ, et al. Endoscopic full-thickness resection for gastric submucosal tumors arising from the muscularis propria layer. *World J Gastroenterol* 2014;20:13981-6.
7. Huberty V, Verset L, Deviere J. Endoscopic full-thickness resection of a gastric GI stromal tumor. *VideoGIE* 2019;4:120-2.
8. Tan Y, Tan L, Lu J, et al. Endoscopic resection of gastric gastrointestinal stromal tumors. *Transl Gastroenterol Hepatol* 2017;2:115.
9. Lu J, Jiao T, Zheng M, et al. Endoscopic resection of submucosal tumors in muscularis propria: the choice between direct excavation and tunneling resection. *Surg Endosc* 2014;28:3401-7.
10. Suzuki S, Gotoda T, Kobayashi Y, et al. Usefulness of a traction method using dental floss and a hemoclip for gastric endoscopic submucosal dissection: a propensity score matching analysis (with videos). *Gastrointest Endosc* 2016;83:337-46.
11. Parsi MA, Schulman AR, Aslanian HR, et al. Devices for endoscopic hemostasis of nonvariceal GI bleeding (with videos). *VideoGIE* 2019;4:285-99.
12. Aihara H, Abidi W, Thompson CC. Countertraction in endoscopic submucosal dissection. *VideoGIE* 2016;1:36-7.
13. Landi B, Blay JY, Bonvalot S, et al. Gastrointestinal stromal tumours (GISTs): French Intergroup Clinical Practice Guidelines for diagnosis, treatments and follow-up (SNFGE, FFCG, GERCOR, UNICANCER, SFCD, SFED, SFRO). *Dig Liver Dis* 2019;51:1223-31.

Columbia University Medical Center, New York Presbyterian Hospital, New York, New York.

If you would like to chat with an author of this article, you may contact Dr Perales at [jorgeperalesmd@yahoo.com](mailto:jorgeperalesmd@yahoo.com).

Copyright © 2021 American Society for Gastrointestinal Endoscopy. Published by Elsevier Inc. This is an open access article under the CC BY-NC-ND license (<http://creativecommons.org/licenses/by-nc-nd/4.0/>).

<https://doi.org/10.1016/j.vgie.2021.01.003>