


Pregnancy Counseling in a Young Woman With Left Ventricular Non-Compaction

Journal of Investigative Medicine High Impact Case Reports
Volume 9: 1–4
© 2021 American Federation for Medical Research
DOI: 10.1177/23247096211053713
journals.sagepub.com/home/hic


Saif El Naser H. M. El Nawaa, MD¹, Wasawat Vutthikraivit, MD², and Leighann Jenkins, MD, FACC¹

Abstract

Left ventricular noncompaction (LVNC) is an uncommon form of cardiomyopathy. Its prevalence in adults is 1:5000. In the differential diagnosis of congestive heart failure, it is rarely the etiology. The etiology of LVNC may be genetic or acquired. There are not guidelines regarding pregnancy planning or outcome in women with this disease. In this presentation, we bring the issue of genetics and pregnancy counseling in women with left ventricular noncompaction.

Keywords

cardiology, pregnancy counseling, myocardium, heart failure, inherited cardiac disease, left ventricular non-compaction

Introduction

Left ventricular noncompaction (LVNC) is a rare form of myocardial disease with estimated prevalence in adults of 1:5000.¹ It is characterized by the presence of prominent ventricular trabeculations with deep recesses between the trabeculae. These trabeculae communicate with the left ventricular cavity and not with the coronary arteries.^{2,3} Noncompaction can affect both the right and left ventricles. It can also be present in an isolated area rather than widespread.^{4,5} The pathogenesis is believed to be caused by the failure of ventricular compaction during embryogenesis.⁶ This hypothesis may explain typical or congenital LVNC cardiomyopathy but doesn't explain the acquired reversible form of the disease.^{7,8}

We report a case of 28-year-old female asymptomatic patient with reported history of Endocardial Fibroelastosis (EFE) who presents for pregnancy counseling and was found to have LVNC with low left ventricular ejection fraction (LVEF).

Case Presentation

A 28-year-old female with reported diagnosis of EFE who was born full term and had a patent ductus arteriosus, which closed spontaneously. Her symptoms of fatigue and dyspnea on feeding started when she was 12 weeks old. She was admitted for acute congestive heart failure (CHF). Her transthoracic echocardiography (TTE) showed a LVEF of 11%, dilated left ventricle, abnormal mitral valve motion, increased endocardial echogenicity, and mild mitral regurgitation, suggestive of EFE. She was reported to have a thrombus in her

apex. Her chest x-ray showed mild cardiomegaly with a globular heart. She had further admissions in her first year. She was managed on digoxin, captopril, and furosemide. She continued to see pediatric cardiology and at age 21 was told her LVEF was in the 60s and her medications were discontinued.

She married and was having a routine follow-up TTE when she was told by the echo technician that her LVEF was not in the 60s. She obtained a second opinion from an adult cardiologist and was told her LVEF was in the 40s but no mention was made of alternative etiology. As she was seeking advice from high risk Ob/Gyn in our institution she was referred to our clinic. She denied any dyspnea on exertion, orthopnea, paroxysmal nocturnal dyspnea (PND) or edema. She is active, works as a travel agent, scuba dives and visited Machu Picchu (el. 7972 ft). She does not take any medication other than contraception. She does not smoke, take illicit drugs or drink alcohol excessively. Her physical exam showed normal vital signs, normal first and second heart sounds with no murmurs. The

¹Division of Cardiology, Texas Tech University Health Sciences Center, Lubbock, USA

²Department of Internal Medicine, Texas Tech University Health Sciences Center, Lubbock, USA

Received April 25, 2021. Revised September 24, 2021. Accepted September 28, 2021.

Corresponding Author:

Leighann Jenkins, MD, FACC, Division of Cardiology, Texas Tech University Health Sciences Center, Lubbock Campus, 3601 4th Street, MS 9410, Lubbock, TX 79430, USA.
Email: Leighann.Jenkins@ttuhsc.edu



rest of the exam was unremarkable. Her basic lab tests were normal. Her electrocardiogram (EKG) was normal. Her TTE showed LVEF of 40% to 44%, global hypokinesis, Grade 1 diastolic dysfunction and no valve disease. The left ventricle showed evidence of noncompaction, most prominent in the apex, with ratio of noncompacted to compacted myocardium of 4.8, strongly suggesting noncompacted left ventricle Images 1 and 2.

We diagnosed the patient with noncompaction cardiomyopathy, not EFE. She agreed to testing for gene mutations commonly observed in familial cardiomyopathies. Direct DNA sequencing revealed a mutation in ACTC1 gene (actin alpha cardiac muscle 1), a new heterozygous missense mutation variant p.P34R (also known as c.101C>G) which is not reported in the literature and was labeled as a variant of unknown significance. She was advised against pregnancy due to high risk of heart failure exacerbation during pregnancy. She was encouraged to enroll in a noncompaction clinical trial at Indiana University and was referred to their genetic clinic for further advice about disease inheritance.

Discussion

On the basis of current knowledge, Arbustini et al classified LVNC into 3 main groups based on the possible causes: (1) isolated LVNC with normal left ventricular size and function, (2) genetic LVNC: isolated, as a part of syndromes, cardiomyopathies, and (3) acquired LVNC, which may be reversible and has been reported in athletes, hemoglobinopathies, peripartum, and chronic kidney disease.⁹

The diagnostic criterion of LVNC is based on the LV morphology using cardiac imaging modalities: transthoracic echocardiography, cardiac computed tomography(CT), and magnetic resonance imaging (CMR).¹⁰ Echocardiography is the initial test of choice and is widely used. Many diagnostic criteria have been proposed; there is no gold standard test for LVNC. The most widely used criteria were proposed by Frischknecht et al¹¹ and Jenni et al¹² These criteria are as follows: (1) segmental thickening of myocardial wall of left ventricle with 2 layers: a thin, compacted outer layer and a thick non-compacted inner layer with prominent trabeculations and deep recesses. The maximum end systolic ratio of non-compacted to compacted myocardium is $> 2:1$, (2) color Doppler echocardiographic evidence of deeply perfused intertrabecular recesses which, in contrast to myocardial sinusoids, these recesses do not communicate with coronary circulation, (3) the trabeculae are located in the left ventricular apex and mid-ventricular area of both inferior and lateral left ventricular wall, and (4) absence of coexisting myocardial abnormalities.² CMR can be used for diagnosing LVNC. It is more helpful in patients for whom good quality images cannot be obtained on transthoracic echocardiogram. A ratio of non-compacted to compacted myocardium in diastole > 2.3 is suggestive of pathologic non-compaction. Compared to echocardiography, CMR provides a better

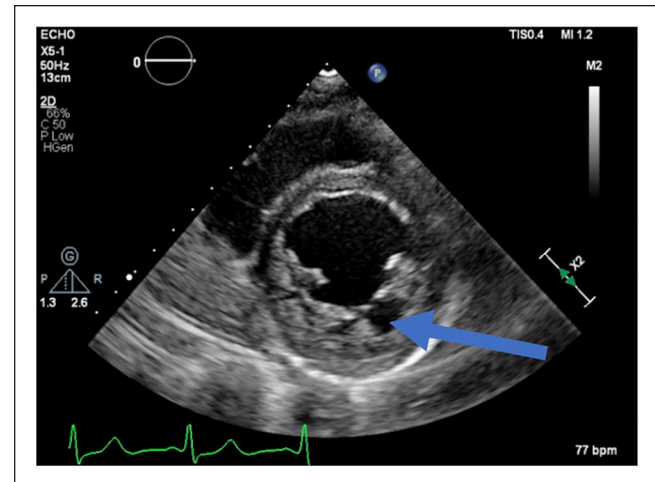


Image 1. Echocardiogram, parasternal, short axis view showing left ventricular non-compaction (arrow).

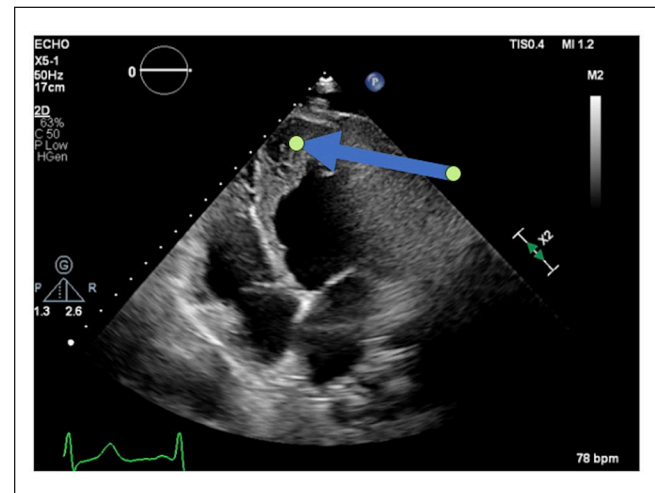


Image 2. Echocardiogram, apical 3 chambers view showing apical left ventricular non-compaction (arrow).

estimation of the degree of left ventricular non-compaction in the apical region of the left ventricle that otherwise cannot be seen on echocardiogram.¹⁰ Another advantage of CMR is measuring fractal dimension (FD) and global peak longitudinal strain (GPLS) which have unique pattern in LVNC. Using CMR FD and GPLS in conjunction can add a high diagnostic accuracy for LVNC.¹³ Ultrafast CT scan provides high resolution imaging comparable to CMR; however, it has not been widely used and unlikely to be used in the future.²

The clinical manifestation of LVNC is varied, and ranges from asymptomatic to symptomatic, including heart failure, arrhythmia, thromboembolic events, and sudden cardiac death. Management should be decided on a case by case basis. Patients who have heart failure should be treated with standard guideline therapy for heart failure.¹⁴ Antiarrhythmic therapy, both medications and implantable defibrillators, is

recommended in patients who present with symptomatic and life threatening arrhythmia.¹⁴ In addition, anticoagulation is recommended in patients with an ejection fraction of less than 40%, prior history of thromboembolic events, or history of atrial flutter or fibrillation.¹⁵ Routine follow-up in asymptomatic patients is encouraged because of possible future complications.^{16,17} The prognosis of patients with LVNC depends on the course of heart failure symptoms, presence of arrhythmias or systemic thromboembolic occurrence.¹⁰ Our patient's prognosis during her pregnancy is not clear based on the limited data available about the course of LVNC in pregnancy. In general, during pregnancy there is an overall increased hemodynamic demand on the cardiovascular system, and this may add more stress on a non-compacted left ventricle which may lead to increased adverse outcome.¹⁸ There are scoring systems which predict adverse outcomes on the fetus as well as the mother. These scoring systems have been studied on cardiomyopathies other than peripartum. However, there were very few patients with LVNC who were involved in these studies. For example, Billebeau et al, performed a retrospective study to evaluate predictors of cardiac events in women with cardiomyopathies during pregnancy, not including peripartum cardiomyopathy. Their cardiomyopathies included dilated, tachycardia-induced, hypertrophic, and LVNC. In this study out of the 36 women, only 1 pregnant patient had a diagnosis of isolated LVNC and the only adverse outcome noted was premature delivery.¹⁸

The diagnosis of LVNC requires genetic counseling since timely screening and diagnosis of at-risk relatives is important.¹⁹ LVNC can be transmitted in X linked, autosomal dominant or autosomal recessive fashion.²⁰ Genetic testing for relatives is recommended once a specific LVNC gene mutation is detected in a patient.²⁰ It is suggested that distinguishing genetic from nongenetic LVNC might play a role in the prediction of outcome and to guide management of patients.¹⁹ There are multiple genes reported to contribute to the development of noncompaction.⁹ ACTC1 gene (actin alpha cardiac muscle 1), a sarcomere encoding gene which was detected in our patient, is one of the identified genes in the LVNC population. Other sarcomere encoding genes examples are myosin binding protein-C (MYBPC3), cardiac troponin T (TNNT2), and Beta- myosin heavy chain (MYH7).²⁰ The mutation noted in our patient, a missense mutation variant p.P34R (also known as c.101C>G), has not been reported in the literature based on our search. This could represent a newly discovered mutation related to genetic LVNC.

In our case, her LVNC was diagnosed during her pregnancy counseling leading to 2 major questions: (1) Will pregnancy worsen her cardiomyopathy? and (2) Will LVNC be inherited by her child with her mutation in ACTC1 gene with an autosomal dominant pattern? Pregnancy may be one of the potentially reversible causes of LVNC and was found in about 25% of normal pregnancies.^{8,20} This transient increase in trabeculation could worsen prognosis. This is

often complicated by worsening heart failure and arrhythmia; but mortality has never been reported.^{21,22} Currently, there are no specific antepartum or peripartum guidelines in patients with LVNC cardiomyopathy. The decision about pregnancy should be individualized based on the patient's symptoms and severity of heart failure. The pattern of autosomal dominant inheritance is observed with variable penetrance causing difficulty in calculating the possibility of disease transmission to the next generation.¹⁹

In conclusion, further studies are necessary to establish standard diagnostic criteria and management of this disease, including in pregnancy. In addition, research is needed to confirm the genotype-phenotype correlation and guide genetic counseling in LVNC patients and their families.

Declaration of Conflicting Interests

The author(s) declared no potential conflicts of interest with respect to the research, authorship, and/or publication of this article.

Funding

The author(s) received no financial support for the research, authorship, and/or publication of this article.

Ethics Approval

Our institution does not require ethical approval for reporting individual cases or case series.

Informed Consent

Verbal consent was obtained from the patient for their anonymized information to be published in this article.

References

1. Ichida F. Left ventricular noncompaction: risk stratification and genetic consideration. *J Cardiol*. 2020;75(1):1-9. doi:10.1016/j.jjcc.2019.09.011.
2. Jenni R, Oechslin EN, van der Loo B. Isolated ventricular noncompaction of the myocardium in adults. *Heart*. 2007;93(1):11-15.
3. Maron BJ, Towbin JA, Thiene G, et al. Contemporary definitions and classification of the cardiomyopathies: an American Heart Association Scientific Statement from the Council on Clinical Cardiology, Heart Failure and Transplantation Committee; Quality of Care and Outcomes Research and Functional Genomics and Translational Biology Interdisciplinary Working Groups; and Council on Epidemiology and Prevention. *Circulation*. 2006;113(14):1807-1816.
4. Ranganathan A, Ganesan G, Sangareddi V, Pillai AP, Ramasamy A. Isolated noncompaction of right ventricle: a case report. *Echocardiography*. 2012;29(7):E169-E172.
5. Ulusoy RE, Kucukarslan N, Kirilmaz A, Demiralp E. Noncompaction of ventricular myocardium involving both ventricles. *Eur J Echocardiogr*. 2006;7(6):457-460.
6. Samsa LA, Yang B, Liu J. Embryonic cardiac chamber maturation: trabeculation, conduction, and cardiomyocyte proliferation. *Am J Med Genet C Semin Med Genet*. 2013;163C(3):157-168.

7. Caselli S, Attenhofer Jost CH, Jenni R, Pelliccia A. Left ventricular noncompaction diagnosis and management relevant to pre-participation screening of athletes. *Am J Cardiol.* 2015;116(5):801-808.
8. Gati S, Papadakis M, Papamichael ND, Zaidi A, et al. Reversible de novo left ventricular trabeculations in pregnant women: implications for the diagnosis of left ventricular noncompaction in low-risk populations. *Circulation.* 2014;130(6):475-483.
9. Arbustini E, Favalli V, Narula N, Serio A, Grasso M. Left Ventricular noncompaction: a distinct genetic cardiomyopathy? *J Am Coll Cardiol.* 2016;68(9):949-966.
10. Rosa LV, Salemi VM, Alexandre LM, Mady C. Noncompaction cardiomyopathy: a current view. *Arq Bras Cardiol.* 2011;97(1):e13-e19.
11. Frischknecht BS, Attenhofer Jost CH, Oechslin EN, et al. Validation of noncompaction criteria in dilated cardiomyopathy, and valvular and hypertensive heart disease. *J Am Soc Echocardiogr.* 2005;18(8):865-872.
12. Jenni R, Oechslin E, Schneider J, Attenhofer Jost C, Kaufmann PA. Echocardiographic and pathoanatomical characteristics of isolated left ventricular non-compaction: a step towards classification as a distinct cardiomyopathy. *Heart.* 2001;86(6):666-671.
13. Zheng T, Ma X, Li S, et al. Value of cardiac magnetic resonance fractal analysis combined with myocardial strain in discriminating isolated left ventricular noncompaction and dilated cardiomyopathy. *J Magn Reson Imaging.* 2019;50(1):153-163.
14. Bennett CE, Freudemberger R. The current approach to diagnosis and management of left ventricular noncompaction cardiomyopathy: review of the literature. *Cardiol Res Pract.* 2016;2016:5172308.
15. Kido K, Guglin M. Anticoagulation therapy in specific cardiomyopathies: isolated left ventricular noncompaction and peripartum cardiomyopathy. *J Cardiovasc Pharmacol Ther.* 2019;24(1):31-36.
16. Bhatia NL, Tajik AJ, Wilansky S, Steidley DE, Mookadam F. Isolated noncompaction of the left ventricular myocardium in adults: a systematic overview. *J Card Fail.* 2011;17(9):771-778.
17. Greutmann M, Mah ML, Silversides CK, et al. Predictors of adverse outcome in adolescents and adults with isolated left ventricular noncompaction. *Am J Cardiol.* 2012;109(2):276-281.
18. Billebeau G, Etienne M, Cheikh-Khelifa R, et al. Pregnancy in women with a cardiomyopathy: outcomes and predictors from a retrospective cohort. *Arch Cardiovasc Dis.* 2018;111(3):199-209. doi:10.1016/j.acvd.2017.05.010.
19. Van Waning JI, Caliskan K, Hoedemaekers YM, et al. Genetics, clinical features, and long-term outcome of noncompaction cardiomyopathy. *J Am Coll Cardiol.* 2018;71(7):711-722.
20. Ackerman MJ, Priori SG, Willems S, et al. HRS/EHRA expert consensus statement on the state of genetic testing for the channelopathies and cardiomyopathies: this document was developed as a partnership between the Heart Rhythm Society (HRS) and the European Heart Rhythm Association (EHRA). *Europace.* 2011;13(8):1077-1109.
21. Ueda Y, Kamiya CA, Nakanishi A, et al. Cardiomyopathy phenotypes and pregnancy outcomes with left ventricular noncompaction cardiomyopathy. *Int Heart J.* 2018;59(4):862-867.
22. Sarma RJ, Chana A, Elkayam U. Left ventricular noncompaction. *Prog Cardiovasc Dis.* 2010;52(4):264-273.