

Exploring the globe salvaging treatment options in patients of COVID-19-associated mucormycosis with orbital involvement

Praveen Khare, Yogita Chaurasia, Shweta Bhatnagar¹

Purpose: To explore the various globe salvaging treatment strategies for patients with coronavirus disease 2019-associated mucormycosis (CAM). **Methods:** This was a prospective interventional analytical study conducted at a Medical College in rural India. A total of 84 patients of CAM admitted between May 2021 and August 2021 were enrolled for the study. Patients with histologically proven CAM with clinical and/or radiological evidence of orbital involvement were divided into three treatment categories based on the site and extent of the lesion. Re-assessment was performed after 7 days. For patients who worsened with the primary approach, orbital exenteration was considered based on a Sion Hospital Scoring System. A novel approach to intra-orbital anti-fungal therapy, site-centered peri-bulbar injection of amphotericin B (SCPeriAmB), was also explored. All the patients were followed up for at least 3 months. Convenience sampling with descriptive statistics was used. **Results:** Six patients had to finally undergo exenteration by the end of the study period. The rest of the patients were reported to be stable or improved. No mortalities were reported on delaying the exenteration. No adverse events were noted in patients who were given SCPeriAmB. **Conclusion:** Globe salvaging treatment options should be advocated as a primary approach in patients with CAM. Site-centered peri-bulbar injections can be considered as an approach for delivering intra-orbital anti-fungal therapy in selected patients.

Key words: COVID-19-associated mucormycosis, exenteration, peri-bulbar amphotericin, retrobulbar amphotericin, TRAMB

A surge in the cases of CAM was noted after the second wave of the pandemic in India.^[1,2] The known treatment options were surgical debridement, transcutaneous retrobulbar amphotericin B (TRAMB) injections, systemic anti-fungal therapy, and exenteration,^[3-5] and there were a few existing guidelines regarding treatment protocols.^[6,7]

Although considered life-saving, orbital exenteration is a disfiguring surgery that some patients may not accept.

We used a combination of globe salvaging treatments as our primary approach to management and also explored a novel way of delivering site-centered peri-bulbar amphotericin B (SCPeriAMB) injections instead of TRAMB in selected patients.

Methods

A prospective analytical interventional study was conducted at a medical college in rural India between May 2021 and August 2021. A total of 84 patients with coronavirus disease 2019 (COVID-19)-associated mucormycosis who were admitted to the mucor ward during this period were enrolled in the study. All the patients presenting with signs of ocular involvement either clinically or radiologically along with microbiologically proven diagnosis were included in the study after taking informed consent. Patients who were

admitted post orbital exenteration performed elsewhere and who denied consent for participating in the study were excluded [Fig. 1].

All the patients underwent a comprehensive ophthalmological, otorhinolaryngological, and maxillofacial evaluation. Routine serological investigations and physician checks were performed periodically for every patient. Radiological evaluation was performed in the form of computed tomography (CT)/magnetic resonance imaging (MRI) at an interval of every seventh to tenth day.

Shah *et al.*^[6] developed a scoring system based on visual symptoms, fundus findings, and the extent of radiological involvement called SHSS (Sion Hospital Scoring System), and a score of more than 22 is considered to be the indication for orbital exenteration.

The SHSS scores were calculated for every patient in the present study.

The clinically visible ptosis, eyelid edema, chemosis, the range of extra-ocular movements, and vision along with the extent of radiological involvement were taken as outcome measures.

This is an open access journal, and articles are distributed under the terms of the Creative Commons Attribution-NonCommercial-ShareAlike 4.0 License, which allows others to remix, tweak, and build upon the work non-commercially, as long as appropriate credit is given and the new creations are licensed under the identical terms.

For reprints contact: WKHLRPMedknow_reprints@wolterskluwer.com

Cite this article as: Khare P, Chaurasia Y, Bhatnagar S. Exploring the globe salvaging treatment options in patients of COVID-19-associated mucormycosis with orbital involvement. *Indian J Ophthalmol* 2022;70:3638-42.

Access this article online

Website:

www.ijo.in

DOI:

10.4103/ijo.IJO_938_22

Quick Response Code:



Departments of Ophthalmology and ¹Dentistry, Bundelkhand Medical College, Sagar, Madhya Pradesh, India

Correspondence to: Dr. Yogita Chaurasia, Shanti Nagar Colony, Sagar Road, Chhatarpur 471001, Madhya Pradesh, India. E-mail: yogis.dr.17@gmail.com

Received: 11-Apr-2022

Revision: 11-Jun-2022

Accepted: 10-Aug-2022

Published: 30-Sep-2022

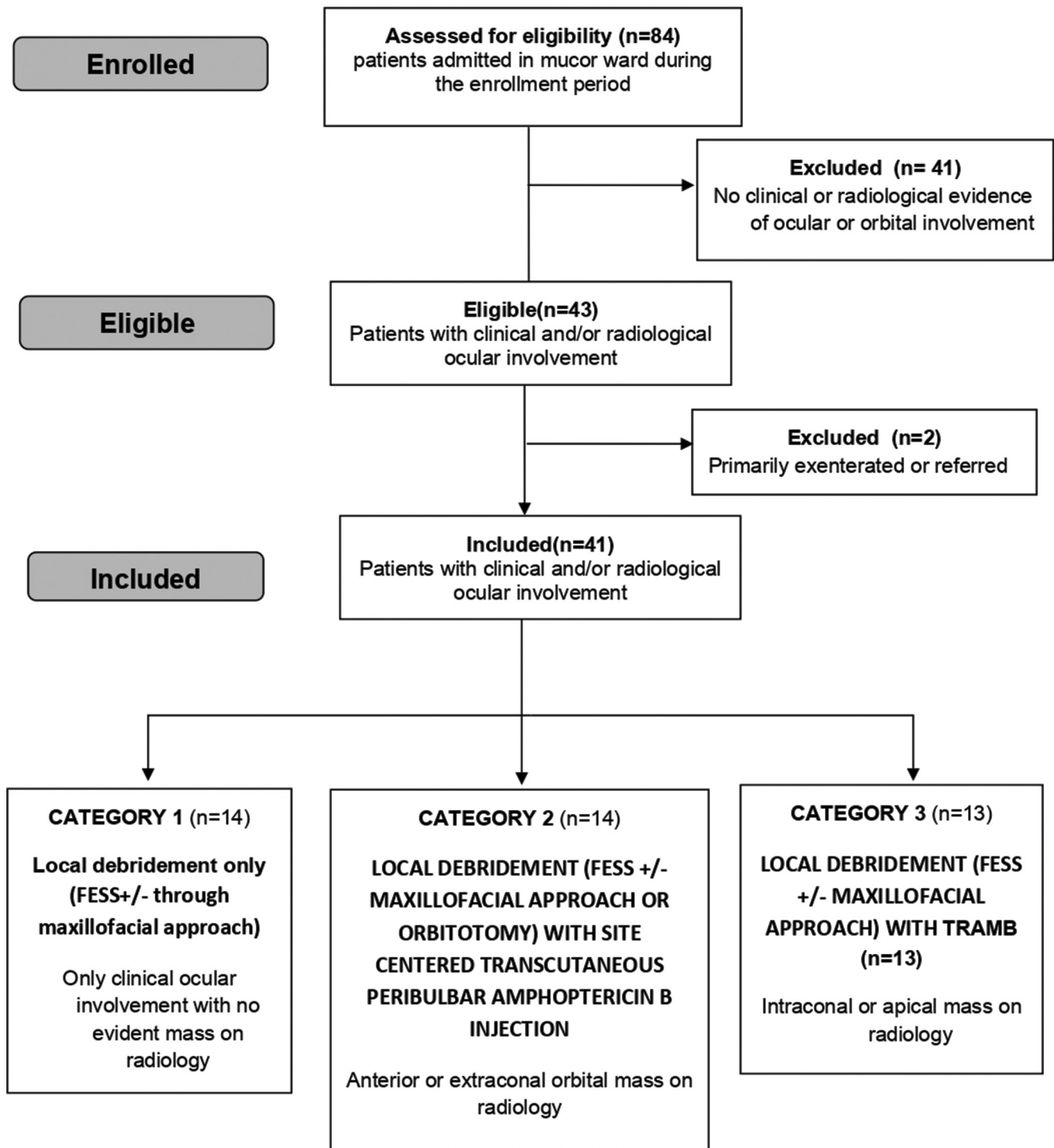


Figure 1: Flow chart of study design

The patients were provided one or more of the following treatment options as per indications:

1. Systemic anti-fungal medications: depending on the availability, all the patients were given injections of liposomal amphotericin B and/or oral posaconazole.
2. Local debridement: Depending on the site of visible fungal mass on radiology and extent of involvement, one or more of the following three approaches were used: functional endoscopic sinus surgery (FESS)

with debridement for endonasal sinuses and mass involving the anteromedial orbit, orbitotomy, and debridement for anteriorly located extraconal orbital mass and maxillectomy or palatal resection when the mass predominantly involved maxillary sinuses, palate, or alveolar socket and also in some cases of fungal mass located on the orbital floor.

3. TRAMB: for posteriorly located or intra-conal mass lesions, retrobulbar injections of 1 ml of 3.5 mg/ml

liposomal amphotericin B were given transcutaneously using a 24G intravenous cannula once a day for 7 consecutive days.

4. SCPeriAMB: for anteriorly placed extra-conal orbital fungal lesions, 1 ml of 3.5 mg/ml injection liposomal amphotericin B was given using half an inch 26 G needle centered locally over the site of involvement seen radiologically once a day for 7 days and up to 10 days in patients showing marked response. In cases of lesions at multiple sites, multiple site-centered injections were given with a cumulative dose of 1 ml.
5. Exenteration: In patients where worsening of signs was observed with any of the globe salvaging treatment routes and SHSS was above 23, exenteration was considered.

Patients were allocated to one of these three treatment categories in addition to systemic anti-fungal therapy:

1. Category 1: Local debridement only: Patients with clinical signs of ocular involvement but no evidence of orbital mass lesion on radiological scans – debridement was performed with FESS or maxillectomy depending on the site of involvement.

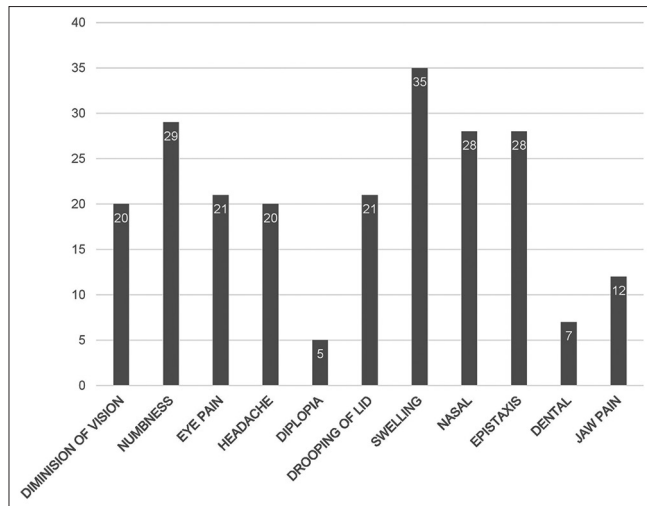


Figure 2: Bar diagram showing frequencies of presenting symptoms in patients of CAM with ocular involvement (n = 43)

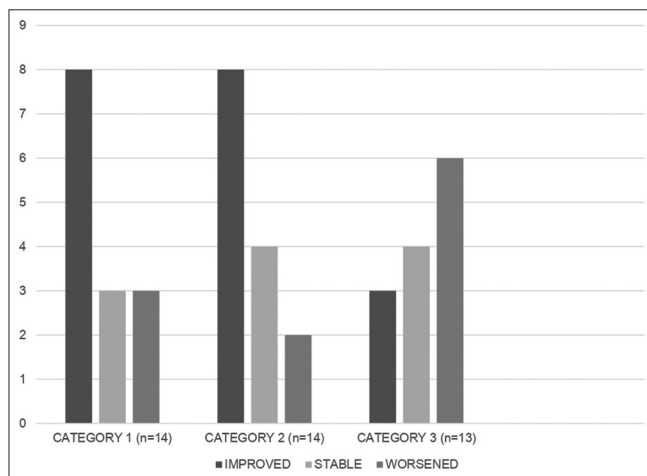


Figure 3: Outcomes of patients in three treatment categories at the end of the study period (n = 41)

2. Category 2: Local debridement with SCPeriAMB: for patients with radiologically evident anterior and extra-conal orbital lesion – local debridement performed with FESS or maxillectomy or orbitotomy along with site-centered peri-bulbar amphotericin therapy.
3. Category 3: Local debridement with TRAMB – in patients with intra-conal or apical orbital mass which could not be accessed through the peri-bulbar route, retrobulbar amphotericin B therapy was given along with local debridement via FESS or maxillectomy. The orbitotomy route was not used for orbital debridement in these patients.

The patients were assessed 7 days after starting the therapy clinically and radiologically. They were deemed as worsened if they developed new signs or symptoms; their existing signs and symptoms increased or the extent of involvement was found to be increasing on radiological scans. Depending on the site of involvement and their SHSS scores, these patients were then considered for repeat local debridement, conservative management, or exenteration. Patients who were found to be stable or improving were followed up with clinical and radiological assessments till the end of 3 months period. Systemic anti-fungal therapy was continued as per the protocol and availability.

Results

The age range of patients in our study was between 37 and 84 years with a median age of 58 years. Out of 43 patients with ocular involvement, 29 were male and 14 were female.

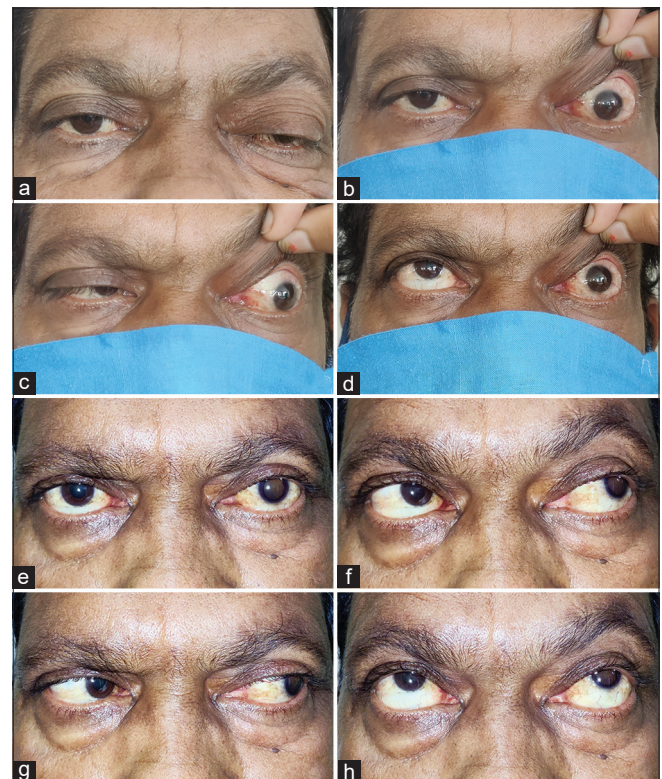

Figure 4 : A patient in category 2 with left-sided ocular involvement presenting with (a). moderate ptosis, (b). proptosis and chemosis, (c). restriction of abduction, and (d). restriction of elevation. Post-treatment (e). Resolution of ptosis, chemosis, and proptosis with recovered extra-ocular movements (f). Levoelevation, (g). abduction, and (h). elevation

The frequencies of presenting symptoms are shown in Fig. 2. Patients most commonly presented with complaints of swelling over the face and eye ($n = 35$) and numbness over the involved side of the face ($n = 29$) because of the involvement of branches of the trigeminal nerve. Other frequent complaints were ptosis ($n = 21$) and eye pain ($n = 21$).

The SHSS scores of patients were calculated, and 11 patients had an SHSS score of more than 23, which is an indication for exenteration.

The outcomes of the patients in three categories at the end of the study period are shown in Fig. 3.

Out of 14 patients in Category 1, eight showed improvement in clinical signs with the resolution of facial/eyelid edema and ptosis in all the patients and partial or full recovery of extra-ocular movements in some patients. Three patients were stable and required no ocular interventions. Three patients were reported to have worsened and required repeat local debridement. None of the patients in this category underwent exenteration.

In the second category of patients who received SCPeriAmb therapy along with local surgical debridement, eight out of 14 patients showed improvement in their clinical signs along with the resolution of orbital mass on radiology. Four patients were found to be stable with no new evidence of involvement, and out of two patients who worsened, one underwent repeat local debridement and the other had to undergo exenteration [Fig. 4].

In category 3, six out of 13 patients were found to be worsened, and based on their SHSS scores, five underwent exenteration. Four patients were found to be stable at the end of the study, whereas three patients showed improvement.

Discussion

The management of mucormycosis essentially comprises surgical debulking to reduce the fungal load and anti-fungal therapy. In addition to the systemic anti-fungal therapy and paranasal sinus and maxillary debridement, proposed treatment strategies for orbit involving disease are local surgical debridement via orbitotomy, exenteration, and TRAMB.^[8]

Based on the European Confederation of Medical Mycology (ECMM) and the Mycoses Study Group Education and Research Consortium (MSG ERC) guidelines,^[9] Honavar^[7] proposed a staging system and management protocol for CAM. The orbital involvement was considered stage 3; in the early Stage 3, local debridements were considered the preferred surgical intervention, and exenteration is suggested for advanced stage 3 disease with extensive orbital involvement. Previously explored globe-sparing treatment options for these patients are local surgical debridement^[10] and TRAMB.^[4,11,12] Additionally, we explored the peri-bulbar route to deliver site-centered amphotericin, and for selecting suitable patients, we categorized them based on their clinical and radiological extent of disease.

In category A patients, the most common clinical presentations were ptosis, eyelid edema, and restriction of extra-ocular movements. As there was no radiologically visible fungal mass in the orbit, these patients have been treated with systemic amphotericin and endonasal sinus debridement. Endoscopic sinus surgery is indicated in all patients with

sinonasal involvement for taking a biopsy and for sinus debridement.^[13] Of the 14 patients in this category, three needed to repeat endonasal debridement and were improved after the second surgery. Ramamurthy *et al.*^[12] developed a scoring system based on signs, symptoms, fundus findings, and MRI findings and concluded that the patients with lower scores have a better prognosis. Similarly, in our study, no exenterations were needed for this subset of patients.

The patients with anterior and extra-conal orbital involvement were put in category B. The surgical approach was based on the location of the mass. Medial orbital mass was approached through either FESS or anterior orbitotomy, and the debridement was performed as much as possible. In cases with inferior orbital involvement with adjacent hard and soft tissues, Rapidis AD^[14] followed an aggressive approach with resection of involved tissues of the face, maxillary and ethmoid sinuses, necrotic tissues of the temporal area and infratemporal fossa, and orbital exenteration. Ramdorai *et al.*^[15] recommended orbital floor preservation along with maxillectomy in most cases. In our study, we performed the maximum possible debridement of the inferior orbital area along with the removal of the partial or complete orbital floor along with maxillectomy through an intra-oral approach. This converted the closed orbit into an open space and prevented compartment syndrome. Anterior orbitotomy and orbital debridement is a standard approach^[3,7] and was performed whenever needed.

We explored a novel way of delivering intra-orbital amphotericin B in this subset of patients via the peri-bulbar route centered on the site of orbital involvement (SCPeriAMB). Localized delivery of amphotericin has an amplified effect as the fungi cause endothelial damage and angioinvasion, limiting the delivery of systemic amphotericin.^[16] Intra-orbital injections of amphotericin have been explored earlier as TRAMB and have been indicated in the early stages of orbital involvement in current practice.^[4] It has been proved to be a beneficial adjunct to systemic anti-fungal therapy and surgical debulking. However, there is a notable risk of inciting orbital inflammation, increasing intra-orbital pressure, or compartment syndrome leading to visual loss.^[17] The peri-bulbar route of drug delivery is considered safer and technically easier to perform.^[18] As the injections were given after the surgical debridement, the risk of compartment syndrome and intra-orbital pressure rise was minimal. Although the majority of patients in this sub-group improved with this treatment, two patients still progressed and one needed exenteration; however, there was no mortality. In these two cases, the full extent of the orbital lesion was not approachable for debridement and was left to treat with systemic and local anti-fungal agents which may be the cause of progression. No major adverse effects were noted with the peri-bulbar injections.

A total of 13 patients were in category C with apical or intra-conal mass. They were treated with TRAMB and maximum possible surgical debulking. This group of patients presented with severe signs of orbital involvement and poor visual prognosis, and the majority had an SHSS score of more than 23, indicating their potential need for exenteration. Based on our treatment protocol, only five patients had to finally undergo exenteration. Ramamurthy *et al.*^[12] mentioned that the patients with worse scores at presentation were more likely to need an orbital exenteration, but TRAMB therapy

can lead to improvement in some patients. Compared to other immuno-suppressive diseases, COVID-19-associated mucormycosis is a result of temporary immuno-suppression because of the virus itself^[19,20] or because of the use of drug therapy, and we observed that once the immunity recovered, the disease became less debilitating. Therefore, we aimed our interventions at reducing the fungal load to give time for recovery in conjunction with strict metabolic control and promoting a semi-active lifestyle with a good diet.

Early exenteration is advocated to reduce mortality in these patients. We did not report any mortality on deferring exenteration for the initial 7 days in these patients. However, these observations are of a smaller size and could not be statistically significant. We recommend close and thorough multi-disciplinary care for these patients and including a physician in the team for keeping an eye on the general well-being of the patient.

Conclusion

COVID-19-associated mucormycosis is because of temporary immuno-suppression; therefore, globe salvaging treatment options should be advocated as a primary approach whenever possible. Site-centered peri-bulbar injections can be a new modality of treatment that is an effective and safe method to give adjunctive local anti-fungal therapy in patients with anterior and extra-conal orbital involvement.

Financial support and sponsorship

Nil.

Conflicts of interest

There are no conflicts of interest.

References

1. Patel A, Agarwal R, Rudramurthy SM, Shevkani M, Xess I, Sharma R, *et al.* Multicenter epidemiologic study of coronavirus disease-associated mucormycosis, India. *Emerg Infect Dis* 2021;27:2349-59.
2. Rocha ICN, Hasan MM, Goyal S, Patel T, Jain S, Ghosh A, *et al.* COVID-19 and mucormycosis syndemic: Double health threat to a collapsing healthcare system in India. *Trop Med Int Health* 2021;26:1016-8.
3. Murthy R, Bagchi A, Gote YS. Role of medial orbital wall decompression in COVID-19-associated rhino-orbital mucormycosis management. *Indian J Ophthalmol* 2021;69:3795-6.
4. Nair AG, Dave TV. Transcutaneous retrobulbar injection of amphotericin B in rhino-orbital-cerebral mucormycosis: A review. *Orbit* 2021;41:275-86.
5. Songu M, Unlu HH, Gunhan K, Ilker SS, Nese N. Orbital exenteration: A dilemma in mucormycosis presented with orbital apex syndrome. *Am J Rhinol* 2008;22:98-103.
6. Shah K, Dave V, Bradoo R, Shinde C, Prathibha M. Orbital exenteration in rhino-orbital-cerebral mucormycosis: A prospective analytical study with scoring system. *Indian J Otolaryngol Head Neck Surg* 2019;71:259-65.
7. Honavar SG. Code mucor: Guidelines for the diagnosis, staging, and management of rhino-orbital-cerebral mucormycosis in the setting of COVID-19. *Indian J Ophthalmol* 2021;69:1361-5.
8. Kalin-Hajdu E, Hirabayashi KE, Vagefi MR, Kersten RC. Invasive fungal sinusitis: Treatment of the orbit. *Curr Opin Ophthalmol* 2017;28:522-33.
9. Cornely OA, Alastruey-Izquierdo A, Arenz D, Chen SCA, Dannaoui E, Hochhegger B, *et al.* Global guideline for the diagnosis and management of mucormycosis: An initiative of the European confederation of medical mycology in cooperation with the Mycoses Study Group Education and Research Consortium. *Lancet Infect Dis* 2019;19:e405-21.
10. Murthy R, Gote YS, Bagchi A. Localized surgical debridement for the management of orbital mucormycosis. *Indian J Ophthalmol* 2022;64:9-52.
11. Singh P, Gupta A, Sanepalli SR, Raj A. Transcutaneous retrobulbar amphotericin-B (TRAMB) injection in orbital mucormycosis. *BMJ Case Rep* 2022;15:e246307.
12. Ramamurthy LB, Bhandari R, Kanakpur S, Thejaswini P. Outcome of transcutaneous retrobulbar injection of liposomal amphotericin B in post-COVID-19 rhino-orbital-cerebral mucormycosis: Our experience. *Indian J Ophthalmol* 2022;70:1019-24.
13. Jiang RS, Hsu CY. Endoscopic sinus surgery for rhinocerebral mucormycosis. *Am J Rhinol* 1999;13:105-9.
14. Rapidis AD. Orbitomaxillary mucormycosis (zygomycosis) and the surgical approach to treatment: Perspectives from a maxillofacial surgeon. *Clin Microbiol Infect* 2009;15:98-102.
15. Ramadorai A, Ravi P, Narayanan V. Rhinocerebral mucormycosis: A prospective analysis of an effective treatment protocol. *Ann Maxillofac Surg* 2019;9:192-6.
16. Ibrahim AS, Spellberg B, Avanesian V, Fu Y, Edwards JE. *Rhizopus oryzae* adheres to, is phagocytosed by, and damages endothelial cells in vitro. *Infect Immun* 2005;73:778-83.
17. Hirabayashi KE, Kalin-Hajdu E, Brodie FL, Kersten RC, Russell MS, Vagefi MR. Retrobulbar injection of amphotericin B for orbital mucormycosis. *Ophthal Plast Reconstr Surg* 2017;33:e94-7.
18. Alhassan MB, Kyari F, Ejere HO. Peribulbar versus retrobulbar anaesthesia for cataract surgery. *Cochrane Database Syst Rev* 2015;2015:CD004083.
19. Liu Y, Li Y, Xu D, Zhang J, Peng Z. Severe COVID-19: Immunosuppression or hyperinflammation? *Shock* 2021;56:188-99.
20. Tian W, Zhang N, Jin R, Feng Y, Wang S, Gao S, *et al.* Immune suppression in the early stage of COVID-19 disease. *Nat Commun* 2020;11:5859.